

Solomon Technique Versus Selective Coagulation for Twin–Twin Transfusion Syndrome

Femke Slaghekke and Dick Oepkes

Division of Fetal Medicine, Department of Obstetrics, Leiden University Medical Centre, the Netherlands

Monochorionic twin pregnancies can be complicated by twin-to-twin transfusion syndrome (TTTS). The best treatment option for TTTS is fetoscopic laser coagulation of the vascular anastomoses between donor and recipient. After laser therapy, up to 33% residual anastomoses were seen. These residual anastomoses can cause twin anemia polycythemia sequence (TAPS) and recurrent TTTS. In order to reduce the number of residual anastomoses and their complications, a new technique, the Solomon technique, where the whole vascular equator will be coagulated, was introduced. The Solomon technique showed a reduction of recurrent TTS compared to the selective technique. The incidence of recurrent TTTS after the Solomon technique ranged from 0% to 3.9% compared to 5.3–8.5% after the selective technique. The incidence of TAPS after the Solomon technique ranged from 0% to 2.9% compared to 4.2–15.6% after the selective technique. The Solomon technique may improve dual survival rates ranging from 64% to 85% compared to 46–76% for the selective technique. There was no difference reported in procedure-related complications such as intrauterine infection and preterm premature rupture of membranes. The Solomon technique significantly reduced the incidence of TAPS and recurrent TTTS and may improve survival and neonatal outcome, without identifiable adverse outcome or complications; therefore, the Solomon technique is recommended for the treatment of TTTS.

■ **Keywords:** Solomon technique, fetoscopic laser surgery, twin-twin transfusion syndrome, TTTS, twin anemia polycythemia sequence, TAPS, residual anastomoses

Monochorionic twin pregnancies are associated with a perinatal mortality rate of 11% (Hack et al., 2008; Lewi et al., 2008). Most complications, such as TTTS, can be attributed to the presence of inter-twin vascular anastomoses on the monochorionic placenta. If left untreated, TTTS can result in an overall mortality rate of 73–100% (Berghella & Kaufman, 2001).

The preferred treatment for TTTS is fetoscopic laser coagulation of the vascular anastomoses, which is associated with survival rates of both fetuses of 35–69% (Akkermans et al., 2015; Senat et al., 2004; Slaghekke, Lopriore et al., 2014). Among the surviving children, 4–16% have signs of cerebral injury, and 13–17% have neurodevelopmental morbidity (Rossi et al., 2011; Spruijt et al., 2012; van Klink et al., 2013).

The goal of fetoscopic laser surgery is to coagulate all of the placental vascular anastomoses. However, in up to 33% of treated pregnancies inter-twin vascular connections may remain patent (Lewi et al., 2006; Lopriore et al., 2007). These residual patent anastomoses can cause severe complications such as TAPS and/or recurrent TTTS in up to 21% of pregnancies (Robyr et al., 2006; Slaghekke, Lopriore et al., 2014).

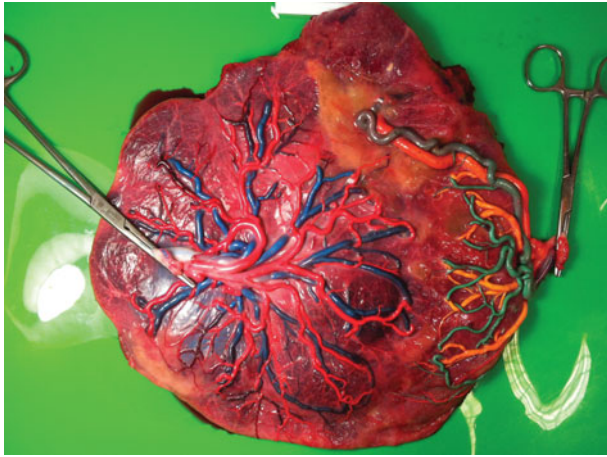
To minimize the occurrence of residual anastomoses and their complications, a modified fetoscopic laser surgery technique called the ‘Solomon technique’ was introduced, in which the entire vascular equator is coagulated. The rationale of the Solomon technique is coagulating the whole vascular equator, including tiny anastomoses that might not be visualized. This review compares the two different techniques for the treatment of TTTS.

Solomon Technique Versus Selective Technique

With the selective technique, only the visible anastomoses between donor and recipient are identified and coagulated one by one. Figure 1 shows a placenta treated with the

RECEIVED 27 January 2016; ACCEPTED 10 March 2016.

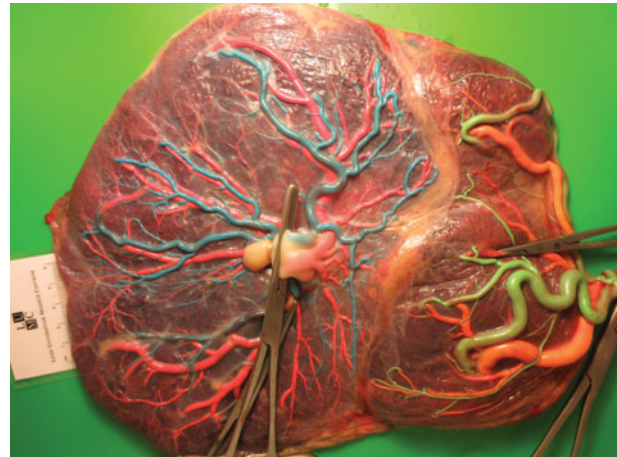
ADDRESS FOR CORRESPONDENCE: F. Slaghekke, MD, PhD, Department of Obstetrics, Leiden University Medical Center, K6, Albinusdreef 2, 2333 ZA Leiden, the Netherlands. E-mail: f.slaghekke@lumc.nl

**FIGURE 1**

(Colour online) A color dye injected TTTS placenta that was treated using the standard technique. Blue and green dye was used to stain the arteries, and pink and yellow dye was used to stain the veins. Individual laser spots between donor and recipient are seen.

selective technique. With the Solomon technique, after coagulation of all visible anastomoses, a thin line of tissue at the placental surface was coagulated from one edge of the placenta to the other, connecting the white areas that resulted from coagulation of the anastomoses. The purpose of coagulating along this line is to completely separate the two parts of the chorionic surface of the placenta at the level of the vascular equator (Figure 2).

One randomized controlled trial (RCT; Slaghekke, Lopriore et al., 2014) and two cohort studies (Baschat et al., 2013, Ruano et al., 2013) compared the two laser techniques for the treatment of TTTS. The Solomon RCT was conducted from March 2008 till July 2012, and 272 patients were analyzed: 137 patients in the Solomon group and 135 patients in the selective group. In a retrospective cohort study, Baschat et al., (2013) compared the outcome of 71 patients treated using the Solomon technique with 76 standard-treated patients in the time period from 2005 to 2011. Between 2005 and 2008, all cases were treated with the intention of using the selective technique, whereas from 2008 to 2011 the intention was to use the Solomon technique. Also in a retrospective cohort study, Ruano et al., (2013) compared 26 pregnancies treated with the Solomon technique to 76 pregnancies treated with the selective technique. Data were collected between January 2010 and July 2012 from four different centers, including one center not performing the Solomon technique. The TTTS cases treated with the Solomon technique were the more recent cases in the cohort. In both retrospective studies, this may have introduced a learning curve or selection bias, as in the second time period, the more difficult cases may have been treated with the selective technique when the Solomon technique was not feasible.

**FIGURE 2**

(Colour online) A colour dye injected TTTS placenta that was treated using the Solomon technique. Blue and green dye was used to stain the arteries, and pink and yellow dye was used to stain the veins. After identification and coagulation of each individual anastomosis, the complete vascular equator was coagulated from one placental margin to the other.

All studies included patients till 26 weeks gestation. Quintero stage 1 cases were included in the RCT (Slaghekke, Lopriore et al., 2014) in case of clinical symptoms secondary to polyhydramnios. Baschat et al., (2013) also included Quintero stage 1 cases but did not report on whether there were clinical symptoms in these cases. Ruano et al., (2013) did not include Quintero stage 1 cases, but only stage 2 to 4.

Recurrent TTTS

The definition of recurrent TTTS is based on the same parameters used to define TTTS. TTTS is defined as anhydramnios in the donor and polyhydramnios in the recipient, with a cut-off for the deepest vertical pocket (DVP) of amniotic fluid in the donor ≤ 2 cm and, in addition, a cut-off for the DVP in the recipient of ≥ 8 cm within the first 20 weeks of gestation or ≥ 10 cm after week 20.

The use of the Solomon technique reduces recurrent TTTS. While Baschat et al., (2013) and Ruano et al., (2013) showed only a favorable trend towards the Solomon technique, the Solomon RCT (Slaghekke, Lopriore et al., 2014) showed a significant reduction in recurrent TTTS: from 7% in the selective group to 1% in the Solomon group. Baschat et al. showed a reduction of 8.5% to 3.9% using the Solomon technique versus the selective technique. Ruano et al. did not report any recurrence of TTTS in the Solomon group, compared to 5.3% in the selective group.

TAPS

TAPS is characterized by the presence of a large intertwin hemoglobin (Hb) difference without the amniotic fluid differences, as in TTTS. TAPS can be diagnosed antenatally and

postnatally. Antenatal diagnosis is based on Doppler ultrasound abnormalities, showing an increase in middle cerebral artery — peak systolic velocity (MCA–PSV) of >1.5 multiples of the median (MoM) in the donor (suggestive of anemia) that coincided with a decrease in MCA–PSV of <0.8 MoM in the recipient (suggestive of polycythemia), in the absence of the oligo-polyhydramnios sequence. Postnatal TAPS is based on an inter-twin Hb difference of ≥ 8 g/dL at birth and at least one of the following criteria: reticulocytosis in the donor, with an inter-twin reticulocyte count ratio >1.7 , and/or the presence of only small (<1 mm in diameter) residual anastomoses seen at the time of postnatal placental injection studies (Slaghekke et al., 2010). These additional criteria are to distinguish between TAPS, which is a chronic form of slow (blood) transfusion, and acute TTTS, which is an acute form of transfusion through large (residual) anastomoses, both resulting in large Hb differences.

The Solomon technique showed a reduction of TAPS in all studies. The smaller cohort studies showed a trend towards favoring the Solomon technique of 4.2% to 2.6% (Baschat et al., 2013) and 7.9% to 0%. The Solomon RCT (Slaghekke, Lopriore et al., 2014) showed a significant reduction of TAPS of 15.6% in the Solomon group compared to 2.9% in the selective group. The higher incidence of TAPS in the RCT (Slaghekke, Lopriore et al., 2014) is probably due to the low rate of loss to follow-up in this trial. In the design of the trial, prenatally all pregnancies were followed at least fortnightly and the Hb levels of all neonates were measured postnatally, which might not have been the standard of care in the cohort studies, resulting in a lower incidence of TAPS in the cohort studies.

Perinatal Outcome and Survival

The Solomon technique may improve survival. Baschat et al., (2013) reported an improved dual survival rate for the Solomon technique of 84% compared to 76% for the selective technique. Also, Ruano et al., (2013) showed an improved dual survival rate of 85% for the Solomon technique compared to 46% for the selective technique. This improvement could not be confirmed with the Solomon RCT (Slaghekke, Lopriore et al., 2014), where dual survival was 64% for the Solomon technique compared to 60% for the standard technique. However, the randomized trial was not designed to detect difference in mortality rates. The improvement Ruano et al. and Baschat et al. observed could be due to the increased experience with fetoscopic laser in general and not to the use of the Solomon technique.

Gestational age at birth was comparable between the different studies and did not differ between the two laser techniques. Gestational age at birth for the Solomon technique varied from 32.0 to 33.0 weeks gestation and for the selective technique it varied from 31.2 to 32.3 weeks' gestation.

Severe neonatal morbidity was reported in the Solomon RCT (Slaghekke, Lopriore et al., 2014) and defined as the presence of at least one of the following: chronic lung disease (defined as oxygen dependency at 36 weeks' gestational age), patent ductus arteriosus requiring medical therapy or surgical closure, necrotizing enterocolitis grade 2 or higher, retinopathy of prematurity stage III or higher, ischemic limb injury, amniotic band syndrome or severe cerebral injury. A trend towards improvement was seen. Although it did not meet a statistically significant reduction, neonatal morbidity was 13% in the selective group and reduced to 8% in the Solomon group. Since the primary outcome of the Solomon RCT was a composite outcome, it was not powered to show a reduction in neonatal morbidity.

Baschat et al., (2013) and Ruano et al., (2013) reported on the perinatal mortality but did not report on the incidence of severe neonatal morbidity.

Long-Term Outcome

The two cohort studies only reported on survival and not on short- or long-term neonatal outcome. Van Klink et al., (2016) analyzed the long-term neurodevelopmental outcome of the Solomon randomized trial. Neurodevelopmental impairment (NDI) was defined as the presence of at least one of the following: cerebral palsy (GMFCS II-V), a cognitive composite score of less than 85 (>-1 SD), a motor composite score of less than 85 (>-1 SD), and bilateral blindness, or bilateral deafness requiring hearing aids. A total of 94% of the survivors were assessed using standardized tests to evaluate neurological, cognitive, and motor development. There was no difference in survival without NDI between the Solomon and standard laser technique. Overall, NDI was detected in 10% (22/206) of survivors, that is, 11% in the Solomon group, and 9% in the standard group.

Although the Solomon laser technique strongly reduces the risk of TAPS and recurrent TTTS (Slaghekke, Lopriore et al., 2014), the effect on the long-term neurodevelopmental outcome appears negligible. Several explanations can be considered to explain the lack of difference between the two treatment groups in this follow-up study. First, the Solomon trial was primarily designed and powered to detect a difference in short-term outcome based on a composite outcome. A second explanation could be that timely detection and adequate management and treatment in highly specialized fetal therapy centers (intrauterine transfusion, laser surgery re-intervention), reduced the risk for long-term impairment.

Procedure-Related Complications

The main procedure-related complications in monochorionic twin pregnancies are preterm, prelabor rupture of membranes (PPROM) and intra-uterine infections. Two studies (Baschat et al., 2013; Slaghekke, Lopriore et al., 2014) reported on the incidence of these complications.

There were no differences in the PPRM and intra-uterine infection. The incidence of chorioamnionitis and intra-uterine infection varied from 0% to 1.4%. The incidence of PPRM varied from 1.3% (Solomon) and 2.8% (selective) reported by Baschat (2013), compared to 41.6% (Solomon) and 34.1% (selective) by Slaghekke, Lopriore et al., (2014). The differences of PPRM rates in these studies were probably due to the difference in definition, since the gestational ages at birth were comparable between the different studies and did not differ between the two laser techniques. The Solomon RCT (Slaghekke, Lopriore et al., 2014) also reported on the following complications, but no differences were seen: iatrogenic monoamniocity, amniondehiscence, and bleeding at the introduction site or at the placental surface. Also, the procedure details were analyzed and showed no difference in procedure time, only an increase in the total amount of energy that was used.

Residual Anastomoses

In a secondary analysis of the Solomon RCT (Slaghekke, Lewi et al., 2014), the injected placentas were analyzed. A total of 151 placentas, treated in the time period between March 2011 and July 2012 were injected. Reasons for lost to follow-up were maceration after fetal demise and damaged placentas. A significant reduction of residual anastomoses was seen after using the Solomon technique. Residual anastomoses were detected in 19% (14/74) of placentas in the Solomon group compared to 34% (26/77) in the Standard group ($p = .04$). Also, a subgroup analyses was performed in cases in which laser surgery was recorded as complete by the surgeon. This subgroup analyses showed an even larger reduction of residual anastomoses: 12% (8/65) in the Solomon group compared to 32% (22/69) in the standard group ($p < .01$).

This secondary analysis showed that in case of residual anastomoses, the overall incidence of recurrent TTTS was 13% and TAPS was 48%. The incidence of residual anastomoses in the two cohort studies is not known.

The Solomon RCT (Slaghekke, Lopriore et al., 2014) and the secondary analysis (Slaghekke, Lewi et al., 2014) showed that even with the use of the Solomon technique, a small percentage of residual anastomoses was still observed, and may present as TAPS and recurrent TTTS. This information should be considered by clinicians when planning ongoing surveillance of patients: close monitoring (including serial MCA-PSV measurements) remains necessary until delivery.

Conclusion

Fetoscopic laser coagulation of the entire vascular equator (Solomon technique) significantly reduced the incidence of TAPS and recurrent TTTS in monochorionic pregnancies complicated by TTTS and may improve survival and neonatal outcome. Importantly, the Solomon technique does not appear to be associated with an increase in any identifiable

adverse outcome or complication, and therefore the use of the Solomon technique is recommended for the treatment of TTTS.

The Solomon technique reduces the amount of residual anastomoses; however, even after the use of the Solomon technique, residual anastomoses were reported and therefore close monitoring, including MCA-PSV Doppler measurements, at least biweekly, remain important.

Disease-free survival is the most important outcome in fetal therapy, and long-term studies powered to detect difference in neurodevelopmental outcome are needed to show an improvement in disease free survival.

References

- Akkermans, J., Peeters, S. H., Klumper, F. J., Lopriore, E., Middeldorp, J. M., & Oepkes, D. (2015). Twenty-five years of fetoscopic laser coagulation in twin-twin transfusion syndrome: A systematic review. *Fetal Diagnosis and Therapy*, 38, 241–253.
- Baschat, A. A., Barber, J., Pedersen, N., Turan, O. M., & Harman, C. R. (2013). Outcome after fetoscopic selective laser ablation of placental anastomoses vs equatorial laser dichorionization for the treatment of twin-to-twin transfusion syndrome. *American Journal of Obstetrics and Gynecology*, 209, 234.e1–8.
- Berghella, V., & Kaufmann, M. (2001). Natural history of twin-twin transfusion syndrome. *Journal of Reproductive Medicine*, 46, 480–484.
- Hack, K. E., Derks, J. B., Elias, S. G., Franx, A., Roos, E. J., Voerman, S. K., . . . Visser, G. H. (2008). Increased perinatal mortality and morbidity in monochorionic versus dichorionic twin pregnancies: Clinical implications of a large Dutch cohort study. *BJOG*, 115, 58–67.
- Lewi, L., Jani, J., Blickstein, I., Huber, A., Gucciardo, L., Van Mieghem, T., . . . Deprest, J. (2008). The outcome of monochorionic diamniotic twin gestations in the era of invasive fetal therapy: A prospective cohort study. *American Journal of Obstetrics and Gynecology*, 199, 514–518.
- Lewi, L., Jani, J., Cannie, M., Robyr, R., Ville, Y., Hecher, K., . . . Deprest, J. (2006). Intertwin anastomoses in monochorionic placentas after fetoscopic laser coagulation for twin-to-twin transfusion syndrome: Is there more than meets the eye?. *American Journal of Obstetrics and Gynecology*, 194, 790–795.
- Lopriore, E., Middeldorp, J. M., Oepkes, D., Klumper, F. J., Walther, F. J., & Vandenbussche, F. P. (2007). Residual anastomoses after fetoscopic laser surgery in twin-to-twin transfusion syndrome: Frequency, associated risks and outcome. *Placenta*, 28, 204–208.
- Robyr, R., Lewi, L., Salomon, L. J., Yamamoto, M., Bernard, J. P., Deprest, J., & Ville, Y. (2006). Prevalence and management of late fetal complications following successful selective laser coagulation of chorionic plate anastomoses in twin-to-twin transfusion syndrome. *American Journal of Obstetrics and Gynecology*, 194, 796–803.
- Rossi, A. C., Vanderbilt, D., & Chmait, R. H. (2011). Neurodevelopmental outcomes after laser therapy for

- twin-twin transfusion syndrome: A systematic review and meta-analysis. *Obstetrics & Gynecology*, 118, 1145–1150.
- Ruano, R., Rodo, C., Peiro, J. L., Shamshirasaz, A. A., Haeri, S., Nomura, M. L., . . . Belfort, M. A. (2013). Fetoscopic laser ablation of the placental anastomoses in twin-twin transfusion syndrome using the 'Solomon technique'. *Ultrasound in Obstetrics and Gynecology*, 42, 434–439.
- Senat, M. V., Deprest, J., Boulvain, M., Paupe, A., Winer, N., & Ville, Y. (2004). Endoscopic laser surgery versus serial amnioreduction for severe twin-to-twin transfusion syndrome. *New England Journal of Medicine*, 351, 136–144.
- Slaghekke, F., Kist, W. J., Oepkes, D., Pasman, S. A., Middeldorp, J. M., Klumper, F. J., . . . Lopriore, E. (2010). Twin anemia-polycythemia sequence: Diagnostic criteria, classification, perinatal management and outcome. *Fetal Diagnosis and Therapy*, 27, 181–90.
- Slaghekke, F., Lewi, L., Middeldorp, J. M., Weingertner, A. S., Klumper, F. J., Dekoninck, P., . . . Lopriore, E. (2014). Residual anastomoses in twin-twin transfusion syndrome after laser: The Solomon randomized trial. *American Journal of Obstetrics and Gynecology*, 211, 285.e1–7.
- Slaghekke, F., Lopriore, E., Lewi, L., Middeldorp, J. M., van Zwet, E. W., Weingertner, A. S., . . . Oepkes, D. (2014). Fetoscopic laser coagulation of the vascular equator versus selective coagulation for twin-to-twin transfusion syndrome: An open-label randomised controlled trial. *Lancet*, 383, 2144–2151.
- Spruijt, M., Steggerda, S., Rath, M., van Zwet, E., Oepkes, D., Walther, F., & Lopriore, E. (2012). Cerebral injury in twin-twin transfusion syndrome treated with fetoscopic laser surgery. *Obstetrics & Gynecology*, 120, 15–20.
- Van Klink, J. M., Koopman, H. M., van Zwet, E. W., Oepkes, D., Walther, F. J., & Lopriore, E. (2013). Cerebral injury and neurodevelopmental impairment after amnioreduction versus laser surgery in twin-twin transfusion syndrome: A systematic review and meta-analysis. *Fetal Diagnosis and Therapy*, 33, 81–89.
- Van Klink, J. M., Slaghekke, F., Balestrieri, M. A., Scelsa, B., Introvini, P., Rustico, M., . . . Lopriore, E. (2016). Neurodevelopmental outcome at 2 years in twin-twin transfusion syndrome survivors randomized for the Solomon trial. *American Journal of Obstetrics and Gynecology*, 214, 113.e1–7.