

## Letters to the Editor

### A novel method for replacement of a blocked fine-bore nasogastric tube. *J Laryngol Otol* 2003;117:883–4

Dear Sirs,

We read with interest the paper written by Panagamuwa about the method for replacing obstructed fine-bore nasogastric tubes as a part of our ENT journal club meeting on 12 January 2004.

It is of significance, however, that there are a few points that we would like to bring to your attention.

- (1) Inserting a guide wire fully into the pre-existing blocked fine-bore nasogastric tube has in itself a possibility of perforating through the tube and into the upper aero-digestive tract.
- (2) The instructions from the manufacturer states that the guide wire should not be re-inserted into the fine-bore nasogastric tube as it may have the possibility of perforation as stated on their website.
- (3) On any account, we feel that a chest radiograph is essential following any kind of gastric tube placement to ensure correct positioning before usage; incorrect placement could lead to serious consequences.
- (4) The main problems with fine-bore tubes are that they are more frequently pulled out rather than being blocked.
- (5) We feel that patients with long-term feeding problems would rather benefit from a PEG placement and that fine-bore tubes are being used more to overcome short-term feeding problems.
- (6) It has been noted clinically that it is difficult to get the guide wire back into the nasogastric tube. We would therefore like to bring into view that the technique is not totally safe and would need further discussions and trials before it is universally accepted.

Raju K. Puttaswamy, SHO,  
C. Lee, SpR,  
S. Clarke, Consultant,  
Department of Otolaryngology,  
Pindersfields General Hospital,  
Wakefield, WF1 4AD, UK.

### Total necrosis of tongue due to severe haemorrhage

Dear Sirs,

In cases of advanced cancer involving the upper airway, severe spontaneous bleeding from the tumour can be lethal due to asphyxia and blood loss.<sup>1</sup> A 60-year-old man with a huge tongue base cancer was admitted to our hospital. The tumour bled severely and an emergency vascular embolization was performed. Digital subtraction angiography showed the large tumour stain and a pooling of extra-vasated contrast material (Figure 1). At first, the left lingual artery was embolized selectively with gelfoam. Since the bleeding still continued, the right lingual artery was also embolized and then complete haemostasis was obtained. One week after the embolization the anterior two-thirds of the tongue became necrotic, total glossectomy with bilateral modified radical neck dissection was performed with a delayed reconstruction. Disruption of the lingual artery by a malignant tumour can result in profuse haemorrhage.<sup>2</sup> Lingual arteries anastomoses across the midline septum are limited to a

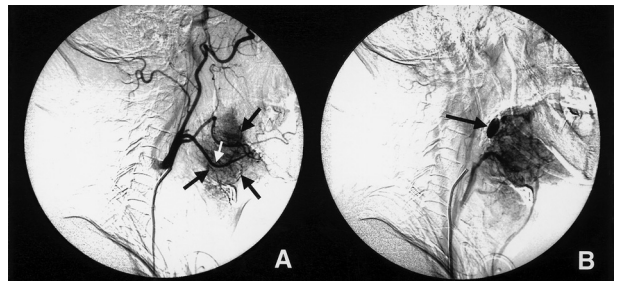


FIG. 1

Digital subtraction angiography of left external carotid artery. (a) A large tumour stain (black arrows) was observed at the tongue base and supraglottic larynx. Both the left lingual (white arrow) and facial arteries can be seen running through the stain. (b) Extra-vasated contrast material (black arrow) was observed at the tongue base in a venous phase.

few small vessels only at the base and tip of the tongue,<sup>1,2</sup> so that haemorrhage can usually be controlled with occlusion of the ipsilateral lingual artery. In our case, since the tumour was huge and supplied by bilateral lingual arteries, bleeding could not be controlled with unilateral lingual artery embolization.<sup>3</sup> Although the procedure was inevitable under a life-saving situation, the tongue necrosis might have been avoided by super-selective embolization of the responsible lingual artery branches.

Toshiro Nishimura, M. D.,  
Yoshinori Shimizu, M. D.,  
Jyunichiro Sanada, M. D.\*,  
Mitsuru Furukawa, M. D.,  
Department of Otolaryngology-Head and Neck Surgery  
and Radiology\*,  
Kanazawa University School of Medicine,  
3-1 Takaramachi, Kanazawa,  
Japan 920-8641.

Fax: +81-76-234-4265

E-mail: nishimut@orl.m.kanazawa-u.ac.jp

### References

- 1 Martin HE, Munster H, Sugarbaker ED. Cancer of the tongue. *Surgery* 1940;41:888–936
- 2 Zimmerman RA, McLean G, Freiman D, Golestaneh Z, Perez M. The diagnostic and therapeutic role of angiography in lingual arterial bleeding. *Radiology* 1979; 133:639–43
- 3 Demuth RJ, Miller SH, Keller F. Complications of embolization treatment for problem cavernous hemangiomas. *Ann Plast Surg* 1984;13:135–44

### Type of drug abuse in patients with psychogenic cough

Dear Sirs,

We would like to draw your readers' attention to some research that we have undertaken in our institution that has shown that there are psychological problems and a considerable abuse of medication in patients who present with a psychogenic cough. A psychogenic cough is a respiratory tic.<sup>1–3</sup> We have studied 50 such patients over a