


Botulinum Toxin-Associated Prolonged Remission of Idiopathic Cervical Dystonia

Gerard Saranza , Kai-Hsiang Stanley Chen, Christos Ganos, Lorraine V. Kalia, Robert Chen, Anthony E. Lang

Abstract: Prolonged remission of dystonia occurs rarely; however, well-documented cases are lacking. We report the clinical characteristics and course of four patients with botulinum toxin (BoNT)-associated prolonged remission of idiopathic cervical dystonia. Mean age at onset was 40 years. All had a relatively short duration of symptoms (mean 10.3 months), and with remission occurring after ≤ 3 treatments with BoNT. At last examination, the remission duration was 2–5 years. In the two cases that subsequently relapsed after 4–5 years, there was an altered phenomenology and worsened severity than at the onset. Recognizing this rare phenomenon has valuable clinical implications.

RÉSUMÉ : Association entre la toxine botulique et la rémission de la dystonie cervicale primaire. On constate rarement une rémission prolongée de la dystonie. Des cas bien documentés sur le sujet font toutefois défaut. Nous voulons donc faire état des caractéristiques cliniques et de l'évolution de l'état de santé de 4 patients dont la rémission prolongée des symptômes de la dystonie cervicale primaire est associée à un traitement à la toxine botulique. L'âge moyen de ces patients lors de l'apparition de leurs premiers symptômes était de 40 ans. Tous ces symptômes ont été présents pendant relativement peu de temps (en moyenne 10,3 mois) alors que leur rémission est survenue après 3 traitements ou plus de toxine botulique. Au moment d'un dernier examen médical, la durée de leur rémission avait varié entre 2 et 5 ans. Dans le cas de 2 patients ayant expérimenté une rechute au bout de 4 et 5 ans, on a pu noter une phénoménologie altérée et une aggravation de la gravité des symptômes par rapport au début. Reconnaître ce phénomène rare peut ainsi sous-tendre des implications cliniques fort utiles.

Keywords: Botulinum toxin, Remission, Cervical dystonia, Dystonia, Relapse

doi:10.1017/cjn.2020.280

Can J Neurol Sci. 2021; 48: 864–868

Abnormal muscle contraction resulting in involuntary movements and sustained postures of the neck, shoulder, and head characterize cervical dystonia (CD). Botulinum toxin (BoNT) is the first line of treatment, with an average duration of therapeutic benefit of approximately 12 weeks.¹ Although prolonged symptomatic remission in idiopathic CD, either spontaneously or with treatment, is recognized,² thorough documentation of this rare but real phenomenon is lacking. A review of the records in our center revealed four cases of BoNT-associated prolonged remission of idiopathic CD. Table 1 summarizes the clinical features, treatment received, and the patients' course.

A 42-year-old previously healthy woman complained of an 8-month history of neck discomfort of insidious onset, eventually accompanied by pain and torticollis. Touching her forehead or occiput served as sensory tricks. Oral medications, including clonazepam, tizanidine, and trihexyphenidyl, did not provide symptomatic relief. On examination, she had right torticollis and right shoulder elevation (Video 1, segment 1). She received a single treatment with 150 units (U) of incobotulinumtoxin-A (incoBoNT-A), distributed as follows: left sternocleidomastoid

(SCM): 50 U, right splenius capitis (SC): 75 U, right trapezius (TRAP): 25 U. She subsequently reported symptom improvement after 10 days, and complete symptom relief a month later (Video 1, segment 2). Subsequent examination after 7, 13, and 18 months (Video 1, segments 3–5) showed the absence of any overt dystonic posturing and a full range of motion in all directions. To date, 24 months post-treatment, she has not had any symptom recurrence.

Seven months into remission, electrophysiology studies were performed to examine for evidence of subclinical dystonia. Background activity was normal. Since she was asymptomatic, she was asked to perform neck rotation toward or opposite to her known previous null point (i.e., rightward). On turning leftward, normal surface electromyographic (sEMG) activities were seen, with a peak frequency of coherence at 9–12 Hz between the right SCM and left SC muscles (Figure 1A). On turning rightward, the peak frequency of coherence between the left SCM and right SC muscles was at 5–9 Hz (Figure 1B and C).

A 34-year-old man with an unremarkable neurologic history presented with a 7-month history of gradually progressive neck

From the Edmond J. Safra Program in Parkinson's Disease and the Morton and Gloria Shulman Movement Disorders Clinic, Toronto Western Hospital, Toronto, Ontario, Canada (GS, KHSC, LVK, RC, AEL); Section of Neurology, Department of Medicine, Chong Hua Hospital, Cebu City, Philippines (GS); Department of Neurology, National Taiwan University Hospital Hsin-Chu Branch, Hsinchu, Taiwan (KHSC); Department of Neurology, Charité University Medicine, Berlin, Germany (CG); and Division of Neurology, Department of Medicine, University of Toronto, Toronto, Ontario, Canada (LVK, RC, AEL)

RECEIVED NOVEMBER 28, 2020. FINAL REVISIONS SUBMITTED DECEMBER 19, 2020. DATE OF ACCEPTANCE DECEMBER 23, 2020.

Correspondence to: Anthony E. Lang, Movement Disorders Clinic, Toronto Western Hospital, 399 Bathurst Street, Toronto, Ontario M5T 2S8, Canada. Email: anthony.lang@uhnresearch.ca

Table 1: Clinical features of the patients with botulinum toxin-associated prolonged remission of cervical dystonia[#]

Case number	1	2	3	4
AAO (years)/sex	42/F	34/M	39/F	45/F
Phenomenology at onset	Right torticollis, right shoulder elevation, limited AROM to the left	Left torticollis	Right torticollis, mild retrocollis; occasional “no-no” tremor	Prominent “no-no” dystonic neck tremor [†]
Sensory tricks	Present	Present	Present	Present
Disease duration prior to first BoNT injections (months)	8	8	24	1
No. of BoNT injections sets before remission	1	3	2	1
Toxin type, total dose, and distribution of BoNT injection set prior to remission	incoBoNT-A: 150 U; Left SCM: 50 U, Right SC: 75 U, Right TRAP: 25 U	onaBoNT-A: 200 U; Right SCM: 60 U, Left SC: 100 U, Left TRAP: 30 U, Right TRAP: 10 U	incoBoNT-A: 150 U; Left SCM: 75 U, Right SC: 20 U, Right TRAP: 25 U, Left SC: 30 U	onaBoNT-A: 150 U; Right SC: 100 U, Left SC: 50 U
Degree of remission	Complete	Complete	Complete	Partial
Duration of remission* (years)	2 [*]	5	4	5 [*]
Relapse	No [*]	Yes	Yes	No [*]
ALE (years)	45	59	50	49
Phenomenology at relapse/comments	N/A	Worse than onset; phenomenology changed: prominent retrocollis and dystonic neck tremor; mild left torticollis and right laterocollis	Worse than onset; phenomenology changed: left torticollis, mild left shoulder, irregular coarse tremor	Subtle “no-no” dystonic neck tremor; mild left torticollis, right laterocollis, left shoulder elevation
Current treatment for CD	N/A	Regular BoNT injections in the last 13 years	Regular BoNT injections in the last 1.5 years	None

AAO = age at onset; ALE = age at last examination; AROM = active range of motion. BoNT = botulinum toxin; CD = cervical dystonia; incoBoNT-A = incobotulinum toxin-A; N/A = not applicable; onaBoNT-A = onabotulinum toxin-A; SC = splenius capitis; SCM = sternocleidomastoid; TRAP = trapezius; U = units.

[#]Secondary causes of dystonia, including drug exposure, were ruled out.

[†]Incomplete information as patient was not seen prior to BoNT injections.

*As of last follow-up.

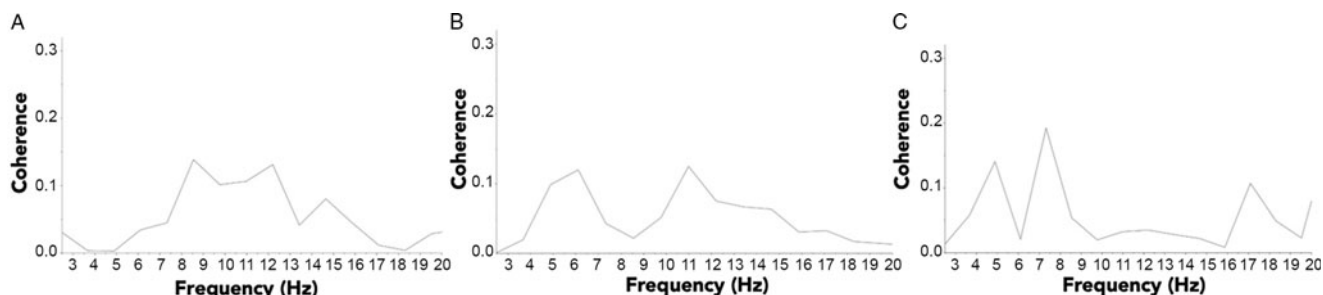


Figure 1: Coherence pattern of agonistic muscle pairs: sternocleidomastoid and splenius capitis. (A) On turning to the left (i.e., opposite to the direction of the null point), the surface electromyography (sEMG) recordings from the right sternocleidomastoid (SCM) and left splenius capitis (SC) muscles showed normal peak frequency of coherence at 9–12 Hz. (B) On turning to the right (i.e., in direction of the null point), the sEMG recordings from the left SCM and the right SC had a peak frequency of coherence at 5–9 Hz, similar to those reported in cervical dystonia. (C) Spectral analysis was repeated using sEMG in the left SCM and needle EMG in the right SC. The peak frequency of coherence was also at 5–9 Hz. These findings suggest that she had subclinical dystonia and that there might be mechanisms that prevent the abnormal motor output from manifesting as overt dystonic symptoms. Further studies in other patients with apparent full clinical remission will be required to determine whether this evidence of subclinical dystonia is a consistent finding.

pain and left torticollis. Touching the back of his head transiently improved the abnormal posturing. Trihexyphenidyl did not provide symptom relief. Two sets of 200 U of onabotulinumtoxin-A (onaBoNT-A) provided a near-complete resolution of his symptoms. The toxin was distributed as follows: right SCM: 60 U, left SC: 100 U, left TRAP: 30 U, and right TRAP: 10 U. After the third set of injections of the same dose and muscle pattern, he had a complete resolution of his CD for 5 years. However, his

symptoms gradually returned. Upon relapse, his dystonia was notably worse compared to the onset, and the phenomenology changed, with prominent retrocollis and dystonic neck tremors. He has remained responsive to higher doses of BoNT injections.

A 41-year-old previously healthy woman complained of a 2-year history of gradually progressive right torticollis, retrocollis, and occasional neck tremor. Touching her chin temporarily kept her head in a midline position. She received 100 U

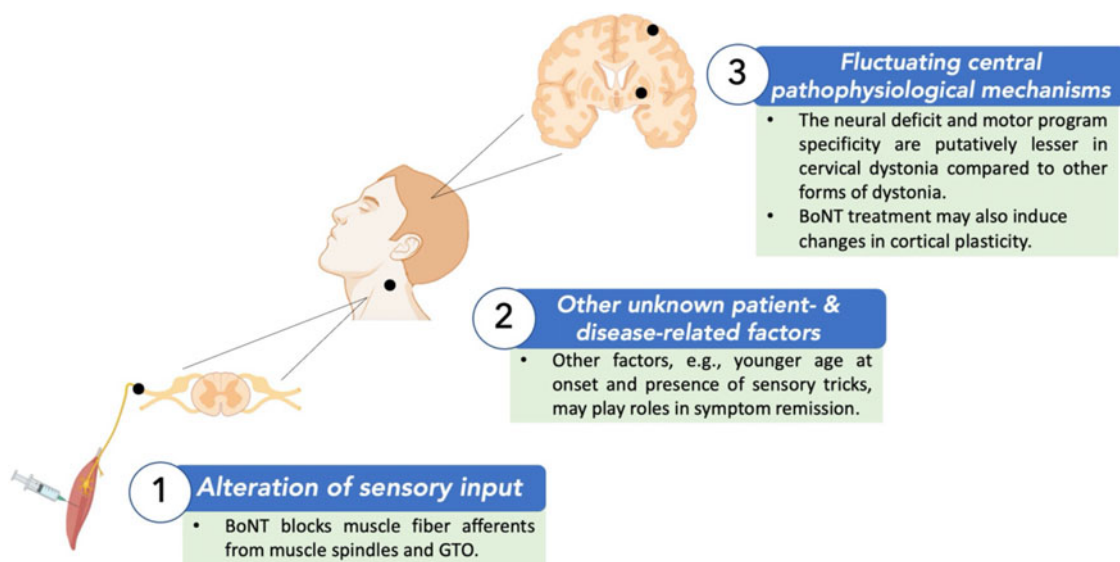


Figure 2: Possible hypotheses to explain remission in cervical dystonia with botulinum toxin (BoNT) treatment. BoNT is known to have central effects through its alteration of sensory input by blocking muscle fiber afferents, affecting cortical excitability. BoNT has also been shown to induce changes in cortical plasticity. Compared to other forms of dystonia, cervical dystonia may be associated with less severe neural deficit and motor program specificity, especially among those with a younger age at onset. Other disease- and patient-related characteristics, which have not yet been completely elucidated, may also contribute to symptom remission. BoNT = botulinum toxin; GTO = Golgi tendon organ.

of incoBoNT-A (left SCM: 75 U, right SC: 20 U, right TRAP: 25 U, and left SC: 30 U), with modest improvement of the dystonic posturing and neck tremor. The dose was then increased to 150 U, with marked symptom relief, but with mild neck weakness. Nonetheless, she went into remission for about 4 years. The symptoms gradually recurred, much worse than at the onset and with left torticollis. Since then, she has been receiving regular toxin injections with a higher dose and different muscle pattern.

A 45-year-old previously healthy woman presented with an insidious onset of a 'no-no' head tremor, which temporarily improved upon touching her chin and with head rotation to the right or left. She denied having upper limb or vocal tremors but had mild neck posturing on examination. She was diagnosed with CD, and 1 week after receiving 150 U of onaboNT-A (right SC: 100 U and left SC: 50 U), she reported symptom improvement. Four months later, she only had non-disabling head tremor and subtle neck posturing. The benefit has been sustained since then, and she has not required any form of treatment to date, 5 years after the single treatment with BoNT.

Dystonia remission is rare, occurring in about 16.2% of cases as reported in a recent review.² This prevalence rate is higher than what we have observed in our clinic, where prolonged remission was only seen in an estimated 0.3% and 1% of all dystonia and CD cases, respectively, from 2000 to 2020. The paucity of well-documented cases demonstrating dystonia remission possibly stems from the lack of operational criteria. Diagnostic criteria have recently been proposed, qualifying remission based on the degree (complete vs. partial), onset (spontaneous vs. post-treatment), and minimum duration (≥ 6 months for spontaneous vs. ≥ 12 months for post-treatment).²

Remission usually occurs in patients with younger age at onset, early in the disease course (within 4.5 years after symptom

onset) and is seen most commonly in idiopathic CD, followed by blepharospasm, and less frequently with generalized and embouchure dystonia.² All patients in our cohort had idiopathic CD, with a mean age at onset of 40 years, had a relatively short duration of symptoms (1–24 months; mean 10.3), and with remission occurring after 1–3 BoNT injection treatments. The remission duration was 2–5 years at their last examination, meeting the criteria for post-treatment remission. Interestingly, the phenomenology changed in the two cases that relapsed.

Although the observed remissions could simply represent a coincidental temporal association between treatment and a spontaneous remission, treatment with BoNT may have induced remission in our patients. It is possible that a similar response might occur when other therapies (e.g., oral medications³ or the unlikely application of early deep brain stimulation) are applied early in the disease course. Figure 2 summarizes the possible hypotheses to explain CD remission with BoNT treatment. BoNT has been shown to induce changes in cortical plasticity.⁴ Since peripherally mediated sensory input can affect cortical excitability, muscle chemodenervation with BoNT may act via the same mechanisms as sensory tricks in improving dystonic symptoms. Our patients had sensory tricks, which suggests that their dystonic symptoms can be improved with alterations in sensory input. BoNT can alter sensory input mechanisms by blocking muscle fiber afferents from muscle spindles and Golgi tendon organs.⁵ Future studies of remission in CD should document whether sensory tricks were present or absent just before the remission.

While CD is the most common focal dystonia, its prevalence does not exclusively explain why remission is more common in CD. Other suggested hypotheses include a less severe putative neural deficit associated in cases with a younger age at onset, and a decreased probability of occurrence of the specific motor programs that are also part of the dystonic manifestation.² Indeed,

compared to other focal forms of dystonia (e.g., task-specific focal hand dystonia), where specific motor programs are also involved in dystonic symptoms (e.g., writing), motor program specificity is a less salient feature in CD, possibly increasing the likelihood of remission.² Loss of cortical inhibition, impaired somatosensory integration, and altered homeostatic plasticity are mechanisms underlying dystonia.^{6,7} These pathophysiological mechanisms may not be well established especially early in the disease course, possibly explaining why most remissions occur within 2 years of symptom onset and the changes in the phenomenology upon relapse.

sEMG in case 1 demonstrated electrophysiological findings consistent with dystonia although she was asymptomatic at the time of testing. When turning in the direction of the null point, the peak frequency of coherence was at 5–9 Hz between dystonic agonistic muscle pairs, similar to that reported in CD.⁸ This was not observed with head turn in the opposite direction. These findings suggest that she might have had subclinical dystonia and that there might be mechanisms that prevent the abnormal motor output from manifesting as overt dystonic symptoms. However, another study failed to confirm that intermuscular electromyography coherence analysis can reliably discriminate patients from controls⁹ and so this finding needs to be interpreted with caution. Further similar studies in controls and other CD patients with and without apparent full clinical remission will be required to determine the meaning and utility of this electrophysiological finding.

Although spontaneous or treatment-associated remission could be a feature suggestive of the possibility of a functional movement disorder (FMD), our patients had no clinical features of FMD, including abrupt symptom onset, antecedent events, unstable psychiatric comorbidities, fixed posturing, or absence of *geste antagoniste*.¹⁰ Furthermore, our patients had an onset of benefit similar to patients with idiopathic CD whereas, when FMD patients are treated with BoNT, they may have an immediate dramatic response, suboptimal subjective response, transient benefit, and need for repeated trials.¹⁰

In summary, we described four cases of idiopathic CD with BoNT-associated prolonged remission, occurring within 2 years of symptom onset, and lasting for as long as 5 years. In the two cases that relapsed, subsequent symptoms remained responsive to regular BoNT injections. Considering the rarity of dystonia remission, thorough reporting is needed, preferably applying the recently proposed criteria.² The mechanism underlying BoNT-associated remission of idiopathic CD could be related to the ability of BoNT to alter sensory input by blocking muscle spindle afferents. However, there is no certainty whether the observed remission was induced by BoNT injections as spontaneous remission is also a known, albeit rare, phenomenon in dystonia. Further studies are needed to completely elucidate factors that lead to remission and its underlying mechanisms. Finally, BoNT-associated remission also has valuable clinical and economic implications. Patients with prolonged treatment benefit can delay follow-up visits and subsequent injections for as long as they remain asymptomatic, minimizing the risk of complications and reducing healthcare costs.

ACKNOWLEDGMENT

The authors would like to thank the patients for their cooperation, and Ms. Deborah Mancini for her help in this project.

FUNDING

This study was supported in part by the Parkinson's Foundation and the Edmond J. Safra Program in Parkinson's Disease through its support of the fellowship training of GS.

DISCLOSURES

The fellowship training of Dr. Gerard Saranza is supported by the Parkinson's Foundation. Dr. Kai-Hsiang Stanley Chen has nothing to disclose. Dr. Christos Ganos holds a research grant from the VolkswagenStiftung (Freigeist Fellowship) and received honoraria from Lundbeck and Actelion Pharmaceuticals. Dr. Lorraine V. Kalia is supported by a Canadian Institutes of Health Research Clinician Scientist Award and received honoraria from the National Institutes of Health and Takeda. Dr. Robert Chen is a consultant for Allergan, Merz and Ipsen. Dr. Lang reports personal fees from AbbVie, personal fees from AFFiRis, personal fees from Janssen, personal fees from Biogen, personal fees from Merck, personal fees from Sun Pharma, personal fees from Corticobasal Solutions, personal fees from Sunovion, personal fees from Paladin, personal fees from Lilly, personal fees from Medtronic, personal fees from Theravance, personal fees from Lundbeck, personal fees from Retrophin, personal fees from Roche, personal fees from PhotoPharmics, outside the submitted work.

STATEMENT OF AUTHORSHIP

Dr. Gerard Saranza managed case 1, acquired data for the other cases, and drafted the manuscript for intellectual content. Dr. Kai-Hsiang Stanley Chen performed the electrophysiology studies for case 1 and revised the manuscript for intellectual content. Dr. Christos Ganos revised the manuscript for intellectual content. Dr. Lorraine Kalia managed case 4 and revised the manuscript for intellectual content. Dr. Robert Chen performed the electrophysiology studies for case 1 and revised the manuscript for intellectual content. Dr. Anthony Lang managed case 1, conceptualized the study, and revised the manuscript for intellectual content.

ETHICAL COMPLIANCE STATEMENT

The authors confirm that this study was approved by the University Health Network Research Ethics Board (Reference No. 20-5896). Informed consent was not necessary for the patients to be included in the case series. Informed consent was obtained for the videos taken as part of the clinical evaluation as per standard policy in the Toronto Western Hospital Movement Disorders Clinic. We confirm that we have read the journal's position on issues involved in ethical publication and affirm that this work is consistent with those guidelines.

SUPPLEMENTARY MATERIAL

To view supplementary material for this article, please visit <https://doi.org/10.1017/cjn.2020.280>.

REFERENCES

1. Dressler D, Tacik P, Adib Saberi F. Botulinum toxin therapy of cervical dystonia: duration of therapeutic effects. *J Neural Transm.* 2015;122(2):297–300.

2. Mainka T, Erro R, Rothwell J, Kühn AA, Bhatia KP, Ganos C. Remission in dystonia – systematic review of the literature and meta-analysis. *Park Relat Disord*. 2019;66:9–15.
3. Lang AE, Marsden CD. Alphamethylparatyrosine and tetrabenazine in movement disorders. *Clin Neuropharmacol*. 1982;5(4): 375–87.
4. Kojovic M, Caronni A, Bologna M, Rothwell JC, Bhatia KP, Edwards MJ. Botulinum toxin injections reduce associative plasticity in patients with primary dystonia. *Mov Disord*. 2011;26(7):1282–9.
5. Caron G, Marqueste T, Decherchi P. Long-term effects of botulinum toxin complex type a injection on mechano- and metabo-sensitive afferent fibers originating from gastrocnemius muscle. *PLoS One*. 2015;10(10):e0140439.
6. Quartarone A, Hallett M. Emerging concepts in the physiological basis of dystonia. *Mov Disord*. 2013;28(7):958–67.
7. Avanzino L, Tinazzi M, Ionta S, Fiorio M. Sensory-motor integration in focal dystonia. *Neuropsychologia*. 2015;79(Pt B):288–300.
8. Tijssen MAJ, Marsden JF, Brown P. Frequency analysis of EMG activity in patients with idiopathic torticollis. *Brain*. 2000;123(4): 677–86.
9. Nijmeijer SWR, de Bruijn E, Forbes PA, et al. EMG coherence and spectral analysis in cervical dystonia: discriminative tools to identify dystonic muscles? *J Neurol Sci*. 2014;347(1–2):167–73.
10. Ganos C, Edwards MJ, Bhatia KP. The phenomenology of functional (psychogenic) dystonia. *Mov Disord Clin Pract*. 2014;1(1): 36–44.