

Nitrous Oxide (N₂O)-Induced Acute Psychosis

Sophia L. Wong, Rebecca Harrison, Andre Mattman, Ging-Yuek R. Hsiung

doi:10.1017/cjn.2014.30

Can J Neurol Sci. 2014; 41: 672-674

Nitrous oxide (N₂O), commonly referred to as laughing gas, is a colourless, non-flammable, inorganic volatile with psychedelic effects. It has assorted uses among diverse fields: in medicine and dentistry, N₂O provides a source of dissociative anaesthesia and analgesia; in the food and automobile industries, N₂O serves as a propellant in whipped cream canisters and as an engine booster, respectively.

N₂O is inexpensive and readily available at supermarkets as gas cylinders and dispensers for soda streams and whipped cream. It is among the top five most common inhalants abused by adolescents in the United States of America.¹ A questionnaire-based study completed in New Zealand noted that 12% of first-year students at the University of Auckland inhaled N₂O recreationally, and 3% used it at least monthly.² Even though most people have an unremarkable, or even unpleasant, experience with N₂O intoxication, some find the dissociative encounter euphoric, with associated sensations of “floating”, body tingling, warmth and numbness.

Various cases of N₂O abuse have surfaced in the literature, although isolated psychiatric presentations are uncommon. As cessation from N₂O exposure and treatment with vitamin B₁₂ usually lead to complete resolution of psychiatric symptoms, it is important to consider such a precipitant when a patient presents with neuropsychiatric manifestations of an uncertain etiology, especially when N₂O use is obtained on history.

CASE REPORT

A man in his 30s presented with new-onset psychotic symptoms and personality changes a few days after inhaling N₂O for several (<10) hours. He described having demons in his head, and expressed concerns over his family's safety for no apparent reason. Those around him noted that he was perseverating, repeating words and short phrases. He had also become rude and verbally aggressive.

The patient's past medical and psychiatric history were unremarkable. There were no psychiatric disorders on family history. No other causes or precipitants for physical or mental illnesses could be identified. He denied use of any medications or supplements, illicit drug abuse, or exposure to toxins. There was a history of intermittent N₂O use for several years, including three episodes within two weeks.

On evaluation, the patient was alert and appeared his stated age. Vital signs were stable. He was emotionally labile, easily angered, and smiled inappropriately throughout the interview. Commands were followed inconsistently. He was easily distractible and paranoid about his safety. Cranial nerve examination was normal. Paratonia was present and he was strong in all four extremities. Sensory and gait examinations were initially deferred due to poor cooperation, but were found to be normal the following day.

Laboratory investigations were mostly unremarkable with regard to hematological cell counts and morphology, except for slight neutrophilia. Extended electrolytes, liver, renal and thyroid

functions were normal. Toxicology screen was negative. Immunometric vitamin B₁₂ level was 148 pmol/L (normal 156-672 pmol/L), and holotranscobalamin concentration was 36 pmol/L (normal 32-125 pmol/L). Functional measures of cobalamin activity were markedly abnormal, with elevations of both homocysteine and methylmalonic acid at 48.0 μmol/L (normal <15.5 μmol/L) and 1.7 μmol/L (normal 0.05-0.27 μmol/L), respectively. Computed tomography (CT) and magnetic resonance imaging (MRI) of the brain did not reveal any significant findings.

On the night of admission, the patient was started on intravenous thiamine, oral folic acid, intramuscular cobalamin 1000 μg daily, and an anti-psychotic medication. Three days later, his mental status was back to baseline and he was discharged with a prescription for parenteral, followed by oral, vitamin B₁₂. No further psychiatric manifestations had developed or recurred in a follow-up appointment several months later.

DISCUSSION

Vitamin B₁₂, or cobalamin, is a collection of chemical compounds characterized by a central cobalt ion surrounded by a corrin ring. Cobalamin plays a key role in two essential metabolic pathways (Figure): in the mitochondria, *adenosylcobalamin* serves as a co-factor for methylmalonyl-coenzyme A mutase in the synthesis of succinyl-coenzyme A from methylmalonyl-coenzyme A. In the cytosol, *methylcobalamin* is a co-factor for methionine synthase in the reduction of homocysteine (HC) to methionine. Methionine synthase is involved in the generation of methyl groups for DNA and RNA synthesis. In cobalamin deficiency, both methylmalonic acid (MMA) and HC concentrations are elevated due to reduced metabolism.

N₂O abuse is a rare, but known, cause of functional cobalamin deficiency. N₂O inactivates vitamin B₁₂ via an irreversible oxidation of the cobalt core from the monovalent to the trivalent state.³ Inhibition of the methylmalonyl-coenzyme A mutase enzyme leads to an accumulation of methylmalonate and propionate; these compounds appear to provide an atypical source of substrate for fatty acid synthesis, leading to the integration of aberrant fatty acids into the myelin sheath. In the second pathway, impediment of methionine and ultimately S-adenosyl methionine synthesis precludes the methylation of myelin sheath phospholipids, thereby diminishing myelin formation.⁴

The precise pathophysiology behind the development of psychiatric abnormalities in N₂O users remains unknown. Tym

From the Division of Medical Biochemistry (SLW, AM), Department of Pathology and Laboratory Medicine; Division of Neurology (RH, GRH), Department of Medicine, University of British Columbia, Vancouver, BC, Canada.

RECEIVED FEBRUARY 19, 2014. FINAL REVISIONS SUBMITTED APRIL 1, 2014.

Correspondence to: Sophia L. Wong, UBC Department of Pathology and Laboratory Medicine, 855 West 12th Avenue, Vancouver, British Columbia, V5Z 1M9, Canada. Email: SWong6@providencehealth.bc.ca

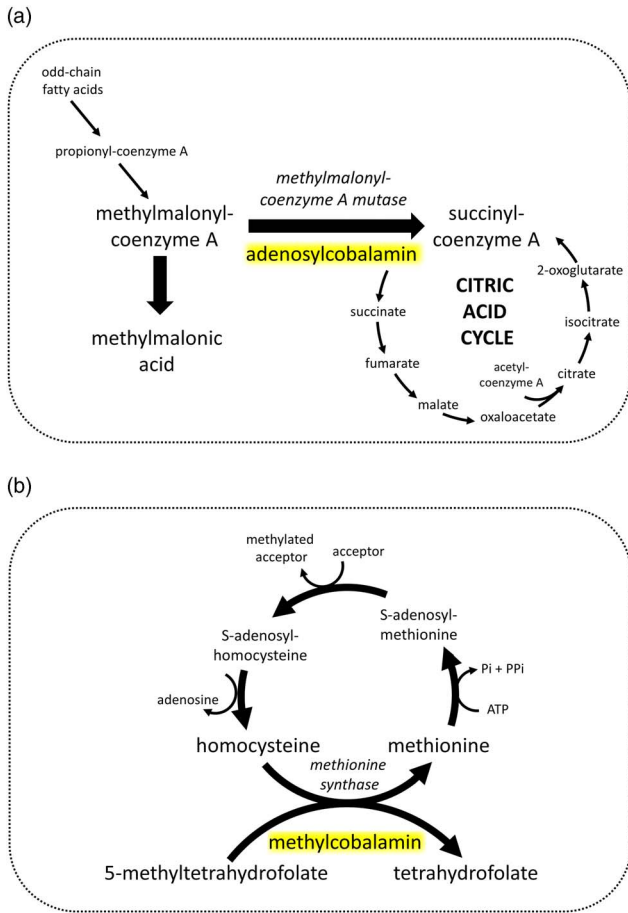


Figure: Metabolic pathways involving cobalamin as a co-factor.

and Alexander⁵ have hypothesized about an increased production of nitric oxide via activation of the pre-synaptic nitric oxide synthase enzyme. Nitric oxide, in turn, reacts with superoxide free radicals and forms peroxynitrite, a potent oxidant and neurotoxin. N₂O's ability to act as a non-competitive N-methyl-D-aspartate (NMDA) antagonist may further contribute to its psychogenic properties.¹

When individuals with a borderline vitamin B₁₂ reserve abuse N₂O acutely or chronically, cobalamin deficiency may be precipitated.³ Some people may remain completely asymptomatic, but others may present with the more well-known neurological

and/or hematological manifestations. These findings are listed in the Table, and are beyond the scope of this report. Less commonly documented are the psychiatric sequelae, with only a handful of cases described in the medical literature.^{1,3,5,6} These may occur in the absence of hematological and/or neurological abnormalities. Personality changes, mood disorders (depression, hypomania), paranoid psychosis with visual and auditory hallucinations (“megaloblastic madness”), and violent behavior have all been depicted.^{1,3,5,6}

Total serum vitamin B₁₂ level is one of the standard laboratory investigations ordered to assess for cobalamin deficiency. Holotranscobalamin is a more sensitive test for vitamin B₁₂ deficiency that is now commercially available. However, both tests measure whether cobalamin is present, rather than whether it is functionally active. With N₂O abuse, the vitamin B₁₂ result may return decreased or within reference limits, given that N₂O causes a functional deficiency. Therefore, surrogate functional markers – namely, MMA and HC – may be more helpful and, if both return elevated, can support the diagnosis of N₂O-associated cobalamin deficiency.

Management of N₂O-induced psychosis comprises of a two-pronged approach: abstinence from N₂O inhalation, and short-term (e.g. 1 week) supplementation with intramuscular or oral cobalamin (typically 1000 µg daily). An antipsychotic is often prescribed in the interim until psychiatric symptoms resolve. The prognosis is generally favorable, with complete resolution of most, if not all, psychiatric abnormalities. Mild neurological sequelae, if present, may persist.

CONCLUSION

Nitrous oxide is a readily available and commonly abused inhalant which is often overlooked on clinical history. Acute and chronic users may present with neuropsychiatric and/or hematological manifestations, and are especially at risk when their vitamin B₁₂ reserve is marginal. Ordering serum total cobalamin, MMA and HC levels can assist in the diagnosis. Given the safety and simplicity of therapy, clinicians should have a high index of suspicion and readily recognize the diverse symptoms and signs of N₂O abuse, thereby allowing prompt initiation of cobalamin supplementation and removal from further N₂O exposure.

REFERENCES

1. Celine C, Gunter H, Kurt A. Laughing gas abuse is no joke. An overview of the implications for psychiatric practice. Clin Neurol Neurosurg. 2013;115(7):859-62.

Table: Clinical presentations and findings associated with nitrous oxide (N₂O) use and intoxication

Neurological	<ul style="list-style-type: none"> • Reduced intellectual function, global dementia, amnesia • Subacute combined degeneration of the spinal cord, paresthesias, decreased proprioception and vibration sensitivity, hyperreflexia or areflexia, spasticity, clonus, gait disturbance, paralysis, motor-sensory polyneuropathy, Lhermitte’s sign, autonomic dysfunction
Hematological	<ul style="list-style-type: none"> • Macrocytic/megaloblastic anemia • Bone marrow suppression
Psychiatric	<ul style="list-style-type: none"> • Depression, hypomania, paranoid psychosis with visual and auditory hallucinations (“megaloblastic madness”)
Others	<ul style="list-style-type: none"> • Facial frostbite injury, pneumothorax, fatal asphyxia

2. Ng J, O'Grady G, Pettit T, Frith R. Nitrous oxide use in first-year students at Auckland University. *Lancet*. 2003;361(9366):1349-1350.
3. Sethi NK, Mullin P, Torgovnick J, Capasso G. Nitrous oxide "whippit" abuse presenting with cobalamin responsive psychosis. *J Med Toxicol*. 2006;2(2):71-4.
4. Pema PJ, Horak HA, Wyatt RH. Myelopathy caused by nitrous oxide toxicity. *AJNR Am J Neuroradiol*. 1998;19(5):894-6.
5. Tym MK, Alexander J. Nitrous oxide induced manic relapse. *Aust N Z J Psychiatry*. 2011;45(11):1002.
6. Brodsky L, Zuniga J. Nitrous oxide: a psychotogenic agent. *Compr Psychiatry*. 1975;16(2):185-8.