

SUPPLEMENTARY MOTOR AREA (SMA) DURING MOTOR ACTIVATION OF CATATONIC PATIENTS IN FUNCTIONAL MRT

G. Northoff¹, D. Khoram-Sefat², M. Herrig², J. Eckert¹, H. Hacker², B. Pflug³, K. Maurer¹. ¹ Department of Psychiatry I, ; ² Department of Neuroradiology, ; ³ Department of Psychiatry II, University of Frankfurt/M, Germany

Introduction: Catatonic patients often show akinesia with an associated deficit of the internal initiation of movements. Internal initiation of movements is closely related with function of supplementary motor area (SMA). Thus we investigated postacute catatonic patients during motor activation with sequential finger opposition (SFO) in Functional MRT.

Methods: We investigated 10 catatonic patients diagnosed according to criteria by Lohr (1987) and Rosebush (1990) in a postacute state and compared them with 10 healthy controls. Motor activation was examined with SFO in both hands. Functional imaging was performed with SFO in both hands. Functional imaging was performed using a gradient echo-EPI pulse sequence with TR 1, 8 ms, TE 66 ms, Flip angle = 99 degree, FOV 23 cm, matrix 64 × 64 (interpolated to 128), voxel size 3.13 × 3.16 × 4 mm. Series of 60 sequential multislice images parallel to AC-PC line were obtained compromising for all slices. The first two images were not used for calculation to account for latencies of oxy/desoxyhemoglobine contrast changes. For visualisation Z-score maps were superimposed to corresponding anatomic images of identical resolution. Signal time courses of the different brain sites were generated. Pertinent clinical information as well as quantity and quality of SFO were registered.

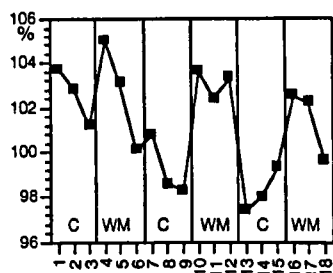
Results: Healthy subjects showed a consistent activation pattern of contralateral M1, S1 and SMA as well as less frequent ipsilateral M1 and S1. In contrast, no activation of SMA was revealed in 7 of 10 catatonic patients whereas the other 3 showed less activation of SMA than healthy controls. Moreover catatonic patients did not show a similar consistent pattern of activation as healthy subjects.

Conclusion: Our results give preliminary evidence that SMA may be functionally altered in catatonia.

FUNCTIONAL MAGNETIC RESONANCE IMAGING OF FRONTAL CORTICAL ACTIVATION IN A WORKING MEMORY TASK

M. Spitzer, T. Kammer, M.E. Bellemann, F. Gückel, G. Brix. *Experimental Psychopathology Section, Department of Psychiatry, University of Heidelberg, Voss-Str. 2, D-69115 Heidelberg, Germany; German Cancer Research Institute (dkfz), Heidelberg, Germany*

Functional magnetic resonance imaging was used in conjunction with a letter detection task for the study of frontal lobe functioning during working memory in 16 normal subjects. In the activation task, subjects responded by pressing a button whenever any presented



letter was the same as the second last in the sequence. In the control condition, the subjects had to respond to a fixed letter. Hence, the activation condition and the control condition differed only subjectively, i.e., regarding the task demand, whereas the stimuli and the type and frequency of response were identical. The activation condition produced significant activation in the dorsolateral prefrontal cortex.

To conclude, the present paradigm led to the activation of prefrontal areas known to be involved in working memory functions. In contrast to experimental tasks previously used rather extensively to study the prefrontal cortex, the paradigm is characterized by its simplicity, interpretability, and its ties to known neurophysiology of the frontal cortex.

LEARNING STUDIES WITH FUNCTIONAL MRI

R. Turner. *Wellcome Department of Cognitive Neurology, Institute of Neurology, Queen Square, London, WC1N 3BG, England*

The new technique of functional magnetic resonance imaging was used to study the effects of learning on cortical organization in humans. Because this method is entirely noninvasive it can be repeated with individual subjects as often as desired, and large populations of volunteer subjects with specific characteristics can be studied without requirement for personal medical benefit. The hypothesis addressed was that learning experiences produce long-term changes in brain areas activated during performance of the learned tasks.

Blood oxygenation level dependent (BOLD) contrast imaging of human brain function using Echo-Planar MRI (EPI) gives good freedom from motion artifact, high SNR/unit time, and adequate spatial resolution. Cortical areas show a signal change related to task-dependent activity, in images with a spatial resolution of 2.5 mm × 2.5 mm × 5 mm, obtained in 40 ms per image. Theoretical considerations suggest an ultimate spatial localization of cortical electrical activity to within about 2 mm by such techniques.

A study of signal changes in motor cortex M1 during the learning of a complex finger-tapping task showed an increase in activated area, compared with an untrained task, over a period of 3–5 weeks of training, well correlated with the learning curve for this task. This suggests that the trained task comes to be represented by a more extensive neural network in M1 than the untrained task, an instance of medium-term neural plasticity. The increase in area for the trained task was observable even eight weeks after cessation of training.

Longer term plasticity was studied using language reading tasks in a population of young healthy congenitally deaf subjects, compared with normally hearing subjects. Subjects read English sentences, controlled with nonsense strings of consonants, and viewed American Sign Language sentences presented using a video of a competent signer, controlled by means of nonsense signs. Significant differences and some striking similarities were found between the two groups, which have profoundly different language experiences.

The two studies suggest remarkable research potential for fMRI in longitudinal psychiatric studies.

RIGHT FRONTAL HYPOPERFUSION IN SCHIZOPHRENICS WHILE PERFORMING THE WISCONSIN CARD SORTING TEST — A FUNCTIONAL MRI STUDY

H.-P. Volz, C. Gaser, F. Häger, W.A. Kaiser¹, H. Sauer. *Psychiatric Department, Jena, Germany; Institute of Diagnostic and Interventional Radiology of the University of Jena, Jena, Germany*

Since the pioneering work of Ingvar and Franzen the concept of hypofrontality in schizophrenia has gained considerable attention. Especially when using cognitive challenges, this phenomenon could