



# Understanding American tegumentary leishmaniasis in urban Montes Claros, Brazil: insights from clinical, immunological and therapeutic investigations

## Research Article

**Cite this article:** Lopes DMS *et al.* (2024). Understanding American tegumentary leishmaniasis in urban Montes Claros, Brazil: insights from clinical, immunological and therapeutic investigations. *Parasitology* 1–9. <https://doi.org/10.1017/S0031182024001057>

Received: 19 April 2024  
Revised: 8 July 2024  
Accepted: 9 July 2024

### Keywords:

alpha-gal; American tegumentary leishmaniasis; *Leishmania braziliensis*; *Leishmania infantum*

### Corresponding author:

Alexandre F. Marques;  
Email: [alexandre.marques@usm.edu](mailto:alexandre.marques@usm.edu)

Dayse M. S. Lopes<sup>1</sup> , Jackeline M. S. Lima<sup>1</sup>, Karine S. M. Ribeiro<sup>1</sup>, Clarissa F. Gomes<sup>1</sup>, Rebeca M. Rocha<sup>1</sup>, Thainara S. Gonçalves<sup>1</sup>, Thallyta M. Vieira<sup>1</sup>, Sílvio F. de Carvalho<sup>1</sup>, M. G. Finn<sup>2</sup>, Ana Paula Venuto<sup>1</sup> and Alexandre F. Marques<sup>3</sup>

<sup>1</sup>Universidade Estadual de Montes Claros – Unimontes, Montes Claros, MG, Brazil; <sup>2</sup>School of Chemistry and Biochemistry, Georgia Institute of Technology, Atlanta, GA, USA and <sup>3</sup>Center for Molecular and Cellular Biosciences, School of Biological, Environmental, and Earth Sciences, University of Southern Mississippi, Hattiesburg, MS, USA

### Abstract

The challenge of American tegumentary leishmaniasis (ATL) continues in Brazil, presenting a persistent public health issue despite initiatives aimed at public outreach, vector control and health education. To gain a deeper understanding of this disease, a study was conducted in an endemic region located in the northern region of the state of Minas Gerais, Brazil. The study monitored 30 resident patients diagnosed with ATL, using serum samples from 6 healthy individuals as controls. The localized cutaneous form of the disease was found to be predominant, with lesions appearing on various parts of the body and the majority of the affected individuals being male. The study found significantly higher levels of IgG anti- $\alpha$ -Gal antibodies in ATL-infected patients compared to healthy individuals. Treatment of 19 patients with meglumine antimoniate resulted in limited improvement in symptoms for most. Nonetheless, the study found that 12 patients who completed treatment with epithelialization of the lesions showed a significant decrease in IgG anti- $\alpha$ -Gal antibodies, indicating potential applications of this antibody in the diagnosis and monitoring of the disease. The study also identified *Leishmania* species in 7 analysed patients, revealing 6 cases infected by *Leishmania braziliensis* and 1 by *L. infantum*, with a significant difference in the anti- $\alpha$ -Gal responses. The findings of the study emphasize the urgent need for the development of human vaccines and innovative treatment strategies adapted to the diversity of *Leishmania* species causing cutaneous leishmaniasis and individual patient responses to improve the clinical management of ATL in Brazil and similar endemic regions.

### Introduction

Leishmaniasis is an infectious disease that affects humans and other mammals and is caused by infection with the intracellular protozoa of the genus *Leishmania* (Ross, 1903). These parasites are transmitted during the blood meal of female phlebotomine insects of the genera *Lutzomyia* for New World Latin America and *Phlebotomus* for the Old-World Mediterranean Basin, Asia, and parts of Africa (Yamey and Torreele, 2002; Chappuis *et al.*, 2007). Leishmaniasis has numerous clinical manifestations and different therapeutic responses (Machado *et al.*, 2019). Individual clinical presentations are affected by factors such as age, nutritional status, *Leishmania* species and the individual's immune capacity (Kevric *et al.*, 2015). Two primary clinical forms of the disease have been identified: visceral leishmaniasis (VL), also known as kala-azar (the most severe form), and cutaneous or tegumentary leishmaniasis (TL), which is the most common form (Soong *et al.*, 2012; Pasha *et al.*, 2022).

According to the World Health Organization (WHO) (WHO, 2024), it is estimated that between 0.7 and 1 million new cases of TL occur annually worldwide, with the Americas being the continent responsible for more than 95% of the cases (Sheikh *et al.*, 2024). It is known in the Americas as American tegumentary leishmaniasis (ATL), a non-contagious parasitic dermatological condition (Akhoundi *et al.*, 2016) is mainly associated with poverty in developing countries (Burza *et al.*, 2018), ATL is regarded as a neglected tropical disease. Although rarely fatal, ATL can severely harm the patient's daily life by causing destructive, disfiguring and disabling ulcerative lesions on the skin and mucous membranes. The severity of manifestation can vary from localized cutaneous leishmaniasis, showing single or multiple lesions in the same location that may heal spontaneously, to ulcerative forms that are much more severe. Even in its mildest form, disease healing can take several months and leave disfiguring scars (Pearson and Sousa, 1996). Approximately 40 million people worldwide suffer

© The Author(s), 2024. Published by Cambridge University Press. This is an Open Access article, distributed under the terms of the Creative Commons Attribution licence (<http://creativecommons.org/licenses/by/4.0/>), which permits unrestricted re-use, distribution and reproduction, provided the original article is properly cited.

from stigmatizing effects caused by inactive scars of the disease (Bailey *et al.*, 2017; 2019; Bennis *et al.*, 2017).

The immunological status plays a significant role in the presentation and development of leishmaniasis. The disseminated form is characterized by numerous papular and acneiform lesions (acne-like) involving various body parts owing to haematogenous or lymphatic distribution (Machado *et al.*, 2019). Diffuse cutaneous leishmaniasis occurs in patients without known immunodeficiency causes, lacks a specific cellular response to *Leishmania* antigens, and is characterized by the formation of diffuse non-ulcerated lesions throughout the skin. In mucosal/mucocutaneous leishmaniasis, the immune response is exacerbated and ineffective, affecting nasopharyngeal regions by destroying infected tissues (Silveira *et al.*, 2004; Volpedo *et al.*, 2021).

For leishmaniasis treatment, meglumine antimoniate, a pentavalent antimony derivative available in the Americas, has been advocated as the first choice drug in Brazil. It can be administered *via* intramuscular (IM), intravenous (IV) or intraslesional (IL) injection. This medication has severe and well-known adverse effects, including cardiac, hepatic, pancreatic, renal and musculoskeletal system toxicities, making its use contraindicated in patients with relevant comorbidities (Sampaio *et al.*, 2019). Another option in Brazil is miltefosine, administered orally with few side effects, most commonly discrete changes in kidney and liver function, nausea and vomiting (Machado *et al.*, 2010).

Once considered a rural disease, leishmaniasis is now expanding to urban areas and involves several variables. In Brazil, these include a large population of canine reservoirs, the presence and adaptation of vectors, climate changes and human migration (Harhay *et al.*, 2011; Rocklov and Dubrow, 2020; Mojahed *et al.*, 2022). However, this new urban and peri-urban leishmaniasis migration has been observed not only in Brazil (Jeronimo *et al.*, 2004) but also in countries such as Italy (Tarallo *et al.*, 2010), Iran (Oshaghi *et al.*, 2010), Mexico (Sanchez-Garcia *et al.*, 2010) and Morocco (Boussaa *et al.*, 2005). This epidemiological change in disease ecology and the migration of infected people to cities creates new opportunities for outbreaks in traditionally non-endemic regions of Europe and North America and spread to new sites in already endemic countries. Climate change also has the potential to progressively create ideal settings in Europe and North America for sandfly vectors (Boussaa *et al.*, 2005; Ready, 2008; Gonzalez *et al.*, 2010).

The infective promastigote form of *Leishmania* has a glycoconjugate on its surface, composed mostly of molecules fixed by a glycosylphosphatidylinositol (GPI) anchor. Among these surface glycoconjugates are lipophosphoglycans, proteophosphoglycans and glycoinositolphospholipids (McConville *et al.*, 1990; Assis *et al.*, 2012). These have been shown to contribute to parasite virulence, infectivity, survival and pathogenicity (Gupta *et al.*, 2022) by modulating essential functions related to the parasite/host interaction, including the invasion of cells that promote the host's innate immune response (Descoteaux and Turco, 1999; Assis *et al.*, 2012; Carneiro and Peters, 2021). At the structural level, the  $\alpha$ -Gal trisaccharide epitope (Gala1-3Galb1-4GlcNAc-) has been identified as a key carbohydrate present at varying levels on the surfaces of *Leishmania major*, *Leishmania infantum* and *Leishmania amazonensis* (Al-Salem *et al.*, 2014; Moura *et al.*, 2017). In this study, we investigated the production of anti- $\alpha$ -Gal antibodies by 30 patients diagnosed with ATL in the urban setting of Montes Claros-MG, Brazil, correlating this molecular marker with sociodemographic factors, clinical characteristics and treatment. Our findings provide valuable insights into ATL's demographic and clinical aspects and the potential significance of anti- $\alpha$ -Gal IgG antibodies in diagnosis and monitoring. This study underscores the complexity of ATL and the importance of pursuing new treatment strategies, especially considering the diversity of *Leishmania* species and individual patient

responses. Further research is needed to improve the management of ATL in endemic regions.

## Materials and methods

### Ethical aspects

This study was approved (opinion number 5.086.431/2021) by the Research Ethics Committee of the Universidade Estadual de Montes Claros (CEP/Unimontes) and accredited by (Comitê Nacional de Ética em Pesquisa (CONEP).

### Study population area

This was a retrospective clinical study that used a quantitative approach. Thirty patients with a clinical and laboratory diagnosis of TL were followed up between March and December 2022, encompassing a period before and during treatment recommended by the Ministry of Health. This study was conducted in Montes Claros, located in the Upper Middle São Francisco Basin in southeastern Brazil, north of Minas Gerais. The municipality has an estimated population of 417 478 inhabitants and is located at a latitude of 16° 43' 41", longitude of 43° 51' 54" and an altitude of 638 m. The ATL-infected study group consisted of 30 patients residing in areas endemic for ATL and treated at the Reference Center for Infectious Diseases (CERDI) of Policlínica Alto São João de Montes Claros, Minas Gerais, with 1 or more persistent *Leishmania* lesions. All patients considered cases of ATL were confirmed by clinical and laboratory diagnosis (direct or molecular examination) according to the recommendations of the Ministry of Health. The inclusion criteria were patient access during the study period, patients of both sexes, aged 18 years and over, of any ethnicity, diagnosed with ATL and signed the informed consent form. Pregnant women, children and impaired individuals were excluded. Uninfected individuals: samples from 6 healthy volunteers (not infected by ATL and Chagas disease) living in an area endemic for ATL.

### Epidemiological analysis and clinical data

After the appointment, the study information was explained to the patients, and if they agreed, the signature in the TCLE was obtained, and the questionnaire was administered. Additional information was obtained from medical records and anamnesis sheets. The following epidemiological variables were analysed: sex, age, origin, education, occupation, exposure to rural areas, comorbidities, clinical form of ATL and number, location and duration of lesions. The patient was then forwarded to a biological material collection room upon medical request.

### Biological samples

Whole blood (4 mL) was collected from patients diagnosed with cutaneous Leishmaniasis at the Reference Center for Infectious Diseases (CERDI) at the Policlínica Alto São João de Montes Claros, Minas Gerais. Among the 30 patients positive for ATL, blood was collected from 12 individuals after being diagnosed with ATL and after treatment. Eighteen patients did not complete the treatment at the end of the study period. We were also unable to follow the patients past the study period; therefore, it was impossible to verify the presence of healing of the lesions over time. Blood was collected by a qualified professional using the venipuncture technique. Sterile needles, syringes, adult phlebotomy tourniquet with lock, collection tubes (4 mL clot activator tube, FirstLaB), dressings and cotton were used. The samples were centrifuged at 4000 RPM to separate the serum. Serum ( $\pm$  2 mL) was collected using a single-channel micropipette, the

clot was discarded correctly, and the samples were stored at  $-20^{\circ}\text{C}$  in a freezer for later use in the detection of anti- $\alpha$ -Gal IgG by ELISA, following the protocol adapted from Brito *et al.* (2016).

### ELISA

To determine the levels of anti- $\alpha$ -Gal IgG antibodies in human sera, 96-well polystyrene ELISA plates (Sarstedt<sup>®</sup>) were coated with a sample of Qb virus-like particles (VLPs) bearing an average of 540 covalently attached  $\alpha$ -Gal molecules, which we previously used as a highly specific and effective probe of the  $\alpha$ -Gal humoral immune response (Brito *et al.*, 2016). These polyvalent particles, denoted VLP-Q $\beta$ ( $\alpha$ -Gal)<sub>540</sub>, were used at a concentration of 50 ng mL<sup>-1</sup> in phosphate saline buffer pH 7.6 (PBS), incubated overnight at 4°C. The treated wells were then blocked with 1% fetal bovine serum (BSA) (Sigma-Aldrich) in PBS for 50 min at 37°C and washed. The resulting antigen-coated plates were sequentially incubated with 50  $\mu$ L of sera (in duplicate) at a 1:100 dilution in PBS containing 1% BSA at 37°C for 90 min, washed and incubated with secondary anti-human IgG antibody conjugated with horseradish peroxidase (HRP) (1:1000 dilution) in PBS for 30 min at 37°C. Plates were washed 5 times after each incubation step with PBS/0.05% Tween solution and then dried by inversion on an absorbent paper. The HRP reaction was developed using 100  $\mu$ L of peroxidase substrate SigmaFast<sup>®</sup> OPD (*o*-phenylenediamine) (Sigma-Aldrich), incubated at 37°C for 30 min at room temperature, and protected from light. Addition of 4N sulphuric acid stopped the reaction. Absorbance was measured using a Multiskan GO spectrophotometer (Thermo Scientific) at a wavelength of 490 nm (MOURA *et al.*, 2017).

### Statistics

Statistical analyses were performed using the GraphPad Prism software version 9.5.1 (733) (© 2023 GraphPad Software, Irvine, CA, USA). The serum ELISA results were normalized as previously described, using a 1-to-10 scale between the minimum and maximum values. (Brito *et al.*, 2016) After demonstrating data normality using the Kolmogorov–Smirnov test, analysis of variance (one-way ANOVA) was performed, followed by the Bonferroni post-test to determine specific differences between groups. The normal distribution of data was verified using the Shapiro–Wilk test, and the non-parametric Kruskal–Wallis test was used for comparative analysis. Differences between groups were evaluated using the Duun–Bonferroni post-hoc method and were considered significant at  $P < 0.05$ .

## Results

### Study subjects

As males are generally more susceptible to leishmaniasis than females (Dahal *et al.*, 2021), we randomly recruited 18 males and 12 females diagnosed with ATL (*L. braziliensis* and *L. infantum*) for this study, ranging in age from 22 to 88 years (mean age, 53 years). Fourteen patients (47%) declared themselves brown (Table 1). A predominantly urban occurrence profile (70%) was observed for housing in both urban and rural areas (Fig. 1A, B). However, among these patients, 17 (57%) declared having visited the rural environment at some point before noticing the initial symptoms or wounds (Table 1).

### Clinical manifestations of Leishmania

The variety of clinical symptoms associated with cutaneous leishmaniasis is similar to those of leprosy or tuberculosis; the type

**Table 1.** Sociodemographic profiles of patients with ATL in this study

Sociodemographic variables	Sex		Total
	Male 12 (40%)	Female 18 (60%)	
Age			
22–57	8	10	18 (60%)
60–88	4	8	12 (40%)
Self-declared colour or race			
Asian	2	0	2 (6.66%)
Black	3	8	11 (36.66%)
White	7	10	17 (56.66%)
Native	0	0	
Residence			
Urban	8	13	21 (70%)
Rural	4	5	9 (30%)
Education			
Illiterate	2	2	4 (13.33%)
Elementary school	4	6	10 (33.33%)
High school	4	9	13 (43.33%)
College	2	1	3 (10%)
Occupation			14 (13.33%)
Domestic activities <sup>a</sup>	9	5	
Administrative or commercial activities	1	7	8 (26.66%)
Agricultural/rural worker	1	5	6 (20%)
Other <sup>b</sup>	1	1	2 (6.66%)

<sup>a</sup>Domestic activities: housewife, home secretary, cleaning lady, retirees, pensioners and unemployed.

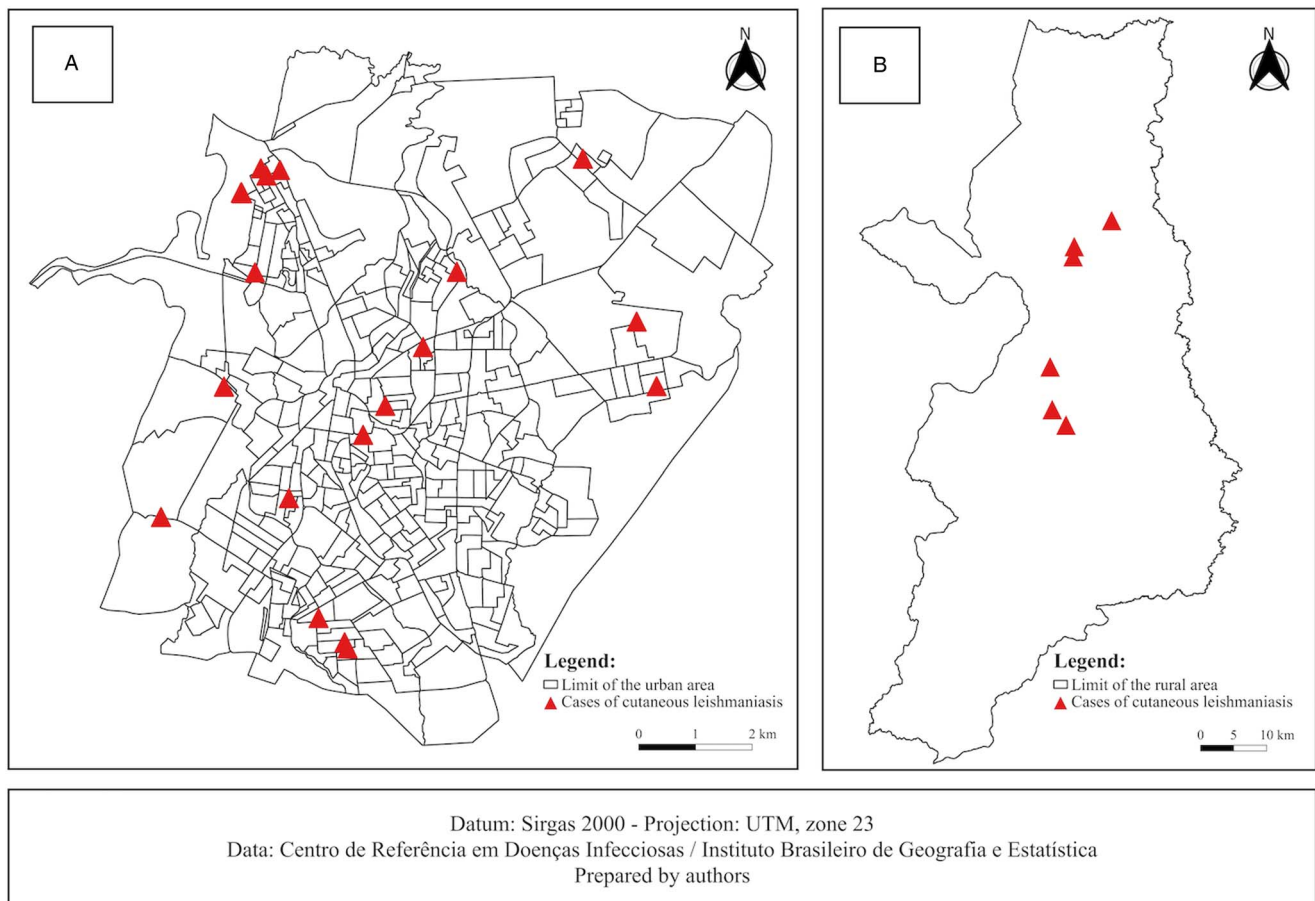
<sup>b</sup>Others: psychologist, event promoter.

Source: Prepared by the author from information obtained from the Reference Center for Infectious Diseases (Also São João Polyclinic) in Montes Claros, Minas Gerais.

and strength of the host's immune response is a useful comparator. The immunological reaction to cutaneous leishmaniasis depends on a variety of host immune factors, as well as on the distinctions between infected *Leishmania* species. Knowledge about the parasite and protective measures against the disease also play a large role, as inadequate education on this subject often results in a late search for medical assistance. Among the patients, lesions existed from 1 to 24 months before the first medical appointment (Table 2), with the disseminated form having the longest duration. Among these patients, lesions appeared localized (66.6%), disseminated (30%) and mucocutaneous (3.33%) (Table 3). Thirteen patients (43.3%) had a single wound and the remaining 17 (56.7%) had multiple wounds. In general, ulcers are painless; however, 30% of patients experience pain. Eighty percent of the patients had lesions smaller than or equal to 3 cm in diameter, most frequently in the lower limbs.

### Identification and treatment of Leishmania spp.

Seven of the 30 patients participated in a companion study to identify the infecting species of *Leishmania* using PCR/RFLP and genomic sequencing; the results are shown in Table 4. *Leishmania braziliensis* was found in all but 1 patient, of which 3 had the localized form, 2 disseminated and 1 cutaneous/mucosal form



**Figure 1.** Spatial distribution of ATL cases in household units in (A) urban areas and (B) rural areas in the municipality of Montes Claros, Minas Gerais, Brazil.

(Fig. 1A–F). *Leishmania infantum* was identified in 1 patient who had 4 ulcerated granulomatous lesions (Fig. 1G). The patient was initially treated with miltefosine with no improvement in the lesions; intralesional meglumine antimoniate was administered as a second treatment (Fig. 2).

#### Evaluation of anti- $\alpha$ -Gal IgG antibody production in leishmaniasis patients

The level of anti- $\alpha$ -Gal IgG antibodies was found to be significantly higher in ATL-positive patients than in healthy patients (Fig. 3A). IgG levels were also measured in 12 patients after treatment, and the anti- $\alpha$ -Gal response was significantly diminished

**Table 2.** Time interval between symptom onset and the patient's first appointment

Lesion time (months)	Sex		Total
	Female 12 (40%)	Male 18 (60%)	
1	0	1	1 (3.3%)
2	5	4	9 (30%)
3	3	4	7 (23.3%)
4	1	2	3 (10%)
5	1	2	3 (10%)
6	1	3	4 (13.3%)
9	0	1	1 (3.3%)
12	1	0	1 (3.3%)

**Table 3.** Appearances of lesions in patients with ATL

Features	Sex		Total
	Female	Male	
Clinical form	12 (40%)	18 (60%)	30 (100%)
Localized	9	11	20 (66.6%)
Disseminated	3	6	9 (30%)
Mucocutaneous	0	1	1 (3.33%)
Lesion			
Single	4	9	13 (43.3%)
Multiple	8	9	17 (56.6%)
Size			
$\leq 3$ cm	11	13	24 (80%)
$\geq 3$ cm	1	5	6 (20%)
Pain			
Yes	2	7	9 (30%)
No	10	11	21 (70%)
Site			
Face	0	2	2 (6.6%)
Upper limbs	3	6	9 (30%)
Lower limbs	8	6	14 (46.6%)
Upper limbs and face	0	1	1 (3.3%)
Upper and lower limbs	1	3	4 (13.3%)



**Table 4.** *Leishmania* spp. and patient treatment

Patient	Sex	Age	Clinical form <sup>a</sup>	Species <sup>b</sup>	Size and number of lesions	Time <sup>c</sup>	Treatment <sup>d</sup>
1	F	62	L	<i>inf.</i>	Back, arm, and forearm (4)	12	Miltefosine + MA intralesional
2	M	71	L	<i>braz.</i>	Leg (1)	3	MA intralesional
3	F	58	L	<i>braz.</i>	Leg (1)	3	Miltefosine
4	F	52	D	<i>braz.</i>	Whole body (8)	2	MA intravenous
5	M	49	D	<i>braz.</i>	Arm (10)	24	Miltefosine
6	M	77	M	<i>braz.</i>	Face and nasal mucosa (1)	9	Amphotericin B
7	M	48	L	<i>braz.</i>	Arm (1)	6	MA intralesional

by treatment (Fig. 3B,  $P = 0.0019$ ). We did not have sufficient data points to make meaningful distinctions between the 4 types of treatments currently recommended by the Ministry of Health. No significant differences were observed in the levels of anti- $\alpha$ -Gal IgG antibodies among the ATL-infected patients with different clinical forms (Fig. 3C). The lone patient with an identified *L. infantum* infection displayed a lower anti- $\alpha$ -Gal response (Fig. 3D) than in those infected with *L. braziliensis*, although statistical significance could not be assigned.

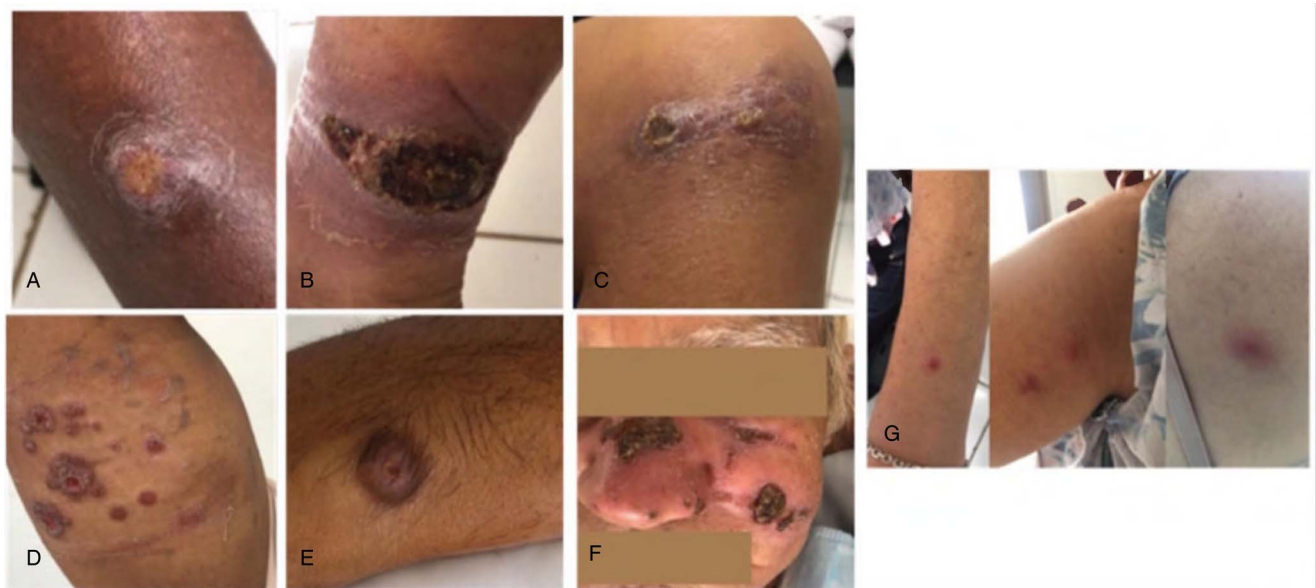## Discussion

ATL is a serious public health problem and is considered by the WHO as one of the central parasitic diseases (Torres-Guerrero *et al.*, 2017; de Vries and Schallig, 2022). Patients in this study were treated in the customer service specialized (CSE) care service at the Alto Policlínica São João de Montes Claros-MG outpatient clinic, which provides exclusive care to patients with tegumentary leishmaniasis. Established by the National Humanization Policy (NHP) of Brazil, this health service is the first provided to patients with leishmaniasis by health professionals, followed by clinical evaluation. Here, most ATL was observed in male patients of working age, self-declared brown, a profile observed in previous studies (Dahal *et al.*, 2021; Ursine *et al.*, 2023). It is believed that greater exposure, mainly due to occupational factors and hesitation in

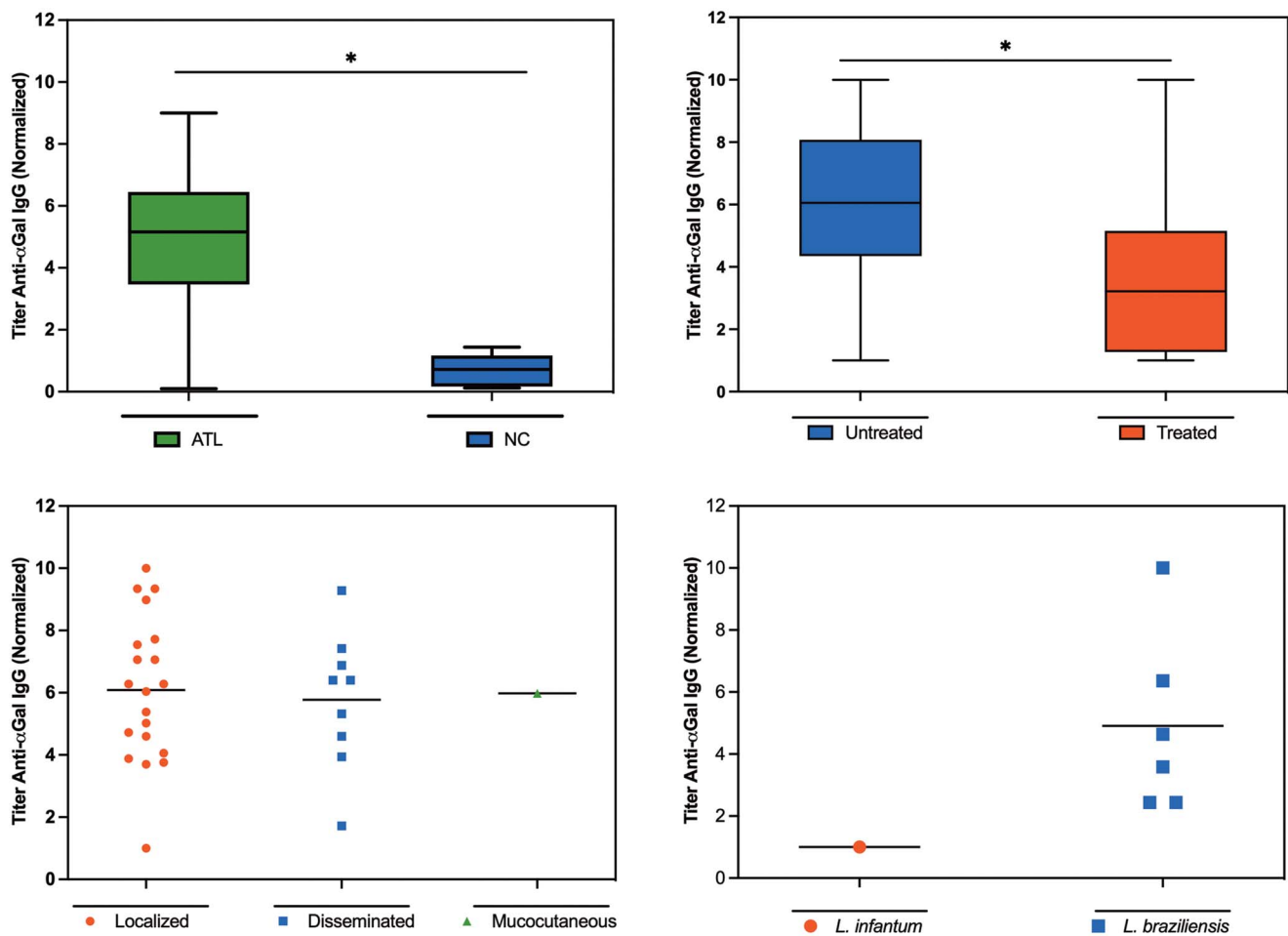
seeking health services, contributes to greater vulnerability in this cohort (Armijos *et al.*, 1997; Pinto *et al.*, 2020). Furthermore, due to biological (hormonal) factors, there is strong evidence of a greater predisposition of men to develop the disease (Lockard *et al.*, 2019). Differences in parasitic load and clinical manifestation have been described according to gender under experimental conditions (Travi *et al.*, 2002; Rodriguez *et al.*, 2018).

The ATL presented a predominantly urban occurrence profile, different from the one observed in most Brazilian regions where the occurrence profile is rural (Marchi *et al.*, 2019). In this study, it was noted that most residents of the urban environment frequented the rural environment. However, due to uncontrolled urbanization, deforestation and increasing human contact with wild environments, urbanization of the disease has been observed in studies previously carried out in the same municipality (Cardoso *et al.*, 2019; Ursine *et al.*, 2021). Due to the peculiar epidemiological characteristics of ATL, strategies for control must be flexible and distinct, suited to each region or particular focus and considering environmental, animal and human health, as well as the interaction between professionals from different areas of knowledge for health promotion (Semenza and Zeller, 2014). As in other studies, patients affected by ATL in this study were delayed in seeking health services and, consequently, starting treatment.

The time of evolution of ATL symptoms determines the severity of the disease. Delays in diagnosis and treatment initiation may



**Figure 2.** Leishmaniasis lesions. (A) *L. braziliensis*, localized form on the leg. (B) *L. braziliensis*, localized form on the posterior part of the leg. (C) *L. braziliensis*, disseminated form throughout the body. (D) *L. braziliensis*, disseminated on the arm and forearm. (E) *L. braziliensis*, localized on the arm. (F) *L. braziliensis*, mucocutaneous form on the face and nasal mucosa. (G) *L. infantum* lesions.



**Figure 3.** Anti- $\alpha$ -Gal IgG immune response. (A) Patients diagnosed with ATL ( $n=30$  vs healthy subjects ( $n=6$ , all negative for ATL, visceral leishmaniasis and Chagas disease). (B) Anti- $\alpha$ -Gal IgG levels in the 12 patients before and after treatment. (C) Anti- $\alpha$ -Gal IgG levels in 30 infected patients separated by the clinical form. (D) Anti- $\alpha$ -Gal IgG levels in 7 patients for whom *Leishmania* species were identified. Sera were collected after the confirmatory diagnosis of ATL and diluted 1/100. Results were normalized. (Brito et al., 2016) Statistically significant differences are indicated by \* ( $P < 0.05$ ).

lead to complications and irreversible sequelae in patients. We observed patients with severe, persistent lesions who did not respond well to treatment, which may be associated with several factors, including the time since disease onset. Even though infection of the mucosa is less frequent than that of the skin, involvement of the oral and nasal mucosa is usually more severe. Furthermore, the advanced and mutilating forms of the disease can lead to psychological, social and behavioural harm (Diniz et al., 2011). Regarding the clinical form, the localized cutaneous form was predominant, as observed in other studies, and this form is responsible for more than 90% of cases in Brazil (Gosch et al., 2017; Grangeiro Junior et al., 2018). The areas most affected by sandfly bites are the most exposed areas of the body, predominantly the lower limbs, followed by the upper limbs. Localized lesions in the upper limbs, head, and trunk tend to evolve and heal more quickly than those located in the lower limbs (Pinart et al., 2020). However, this profile was not a general rule in the evaluated patients, as 1 patient from the study remained with an arm injury for 24 months, and another with arm injuries and a forearm did not respond well to the first therapeutic regimen, requiring a second treatment.

Immunosuppression caused by human immunodeficiency virus (HIV), associated with infections caused by the protozoan *Leishmania*, can lead to disease progression. It is recommended to perform serology for HIV in all patients with ATL (Lindoso et al., 2016). In this study, all patients were tested for HIV; none had *Leishmania*/HIV co-infection. As it is also an endemic

area for Chagas disease, we verified that no patient was affected by *Trypanosoma cruzi*. However, some comorbidities were observed, and systemic arterial hypertension (SAH) was prevalent among the studied patients (40%). SAH is one of Brazil's most important non-transmissible chronic diseases (NTCD) and influences the choice of therapy for ATL.

Intralesional application of meglumine antimoniate (Glucantime) is the most prevalent treatment for ATL and was shown to be effective in 87% of cases in a 2018 study by Ramalho et al. (2018). This route of administration was adopted by the Ministry of Health in 2017 through the tegumentary leishmaniasis manual, noting that the treatment modality should be dictated by the clinical form, with the support of laboratory diagnosis and complying with the criteria established for each situation. Our results also highlighted the importance of identifying the species involved since we observed therapeutic failure in a patient infected with *Leishmania infantum*. Similar findings have been described for the treatment of the Old World species *L. major* and *L. tropica* (Chakravarty and Sundar, 2010).

In 2014, a group of researchers reported that patients infected with *Leishmania* spp. in the Old World (*L. major* and *L. tropica*, different species than those found in Brazil) had significantly higher levels (up to 9-fold) of anti- $\alpha$ -Gal IgG compared to healthy control subjects (Al-Salem et al., 2014). The same study presented the intriguing observation that cured individuals showed higher levels of anti- $\alpha$ -Gal IgG antibodies than healthy individuals, suggesting that after chemotherapy, more  $\alpha$ -Gal epitopes in

intracellular amastigotes may be exposed to the host's immune system, leading to a greater B-cell response and a considerable increase in anti- $\alpha$ -Gal titre (Ramirez and Guevara, 1997; Al-Salem *et al.*, 2014). We note, however, that low parasitaemia can occur in scars of patients cured of ATL. The results described here show a similar increase in anti- $\alpha$ -Gal levels in infected vs healthy patients but a decrease in anti- $\alpha$ -Gal IgG antibodies after treatment. The difference with the Old-World study may be due to several factors, including the fact that Brazilian patients were not completely cured and that the treatment mechanism did not involve a direct immunological component. In these cases, we suggest that treatment induces a drop in parasitaemia and, therefore, in the  $\alpha$ -Gal epitope stimulus. Indeed, we observed considerable decreases in anti- $\alpha$ -Gal antibody levels in patients treated for Chagas disease in both published (Andrade *et al.*, 2004; Brito *et al.*, 2016) and recent unpublished studies by our group.

Moura *et al.* (2017) demonstrated that vaccination with  $\alpha$ -Gal in a model of  $\alpha$ -galactosyltransferase knockout mice (which mimic the anti- $\alpha$ -Gal immune response observed in humans) protected them against *L. amazonensis* and *L. infantum*, preventing parasitic infection in liver and spleen (Moura *et al.*, 2017). These results support the possible efficacy of  $\alpha$ -Gal immune response against leishmaniasis in humans. It was also noted that the expression of the  $\alpha$ -Gal epitope is significantly lower in *L. infantum* than in the thermotropic species *L. amazonensis*, which is consistent with the finding of lower anti- $\alpha$ -Gal titre in the patient in this study infected with *Leishmania infantum*. Indeed, there is a lack of reports of the presence of the  $\alpha$ -Gal epitope in other species of *Leishmania* spp. present in Brazil: our findings here of elevated anti- $\alpha$ -Gal IgG antibodies in 30 patients in an urban Brazilian setting strongly suggest that this is true concerning *L. braziliensis*.

We also noted that a correlation exists between the ABO blood type and susceptibility to certain infectious diseases, including malaria (Rispen *et al.*, 2013; Cabezas-Cruz *et al.*, 2017); blood group A and B antigens resemble  $\alpha$ -Gal. As most of the patients in our study were in group O, we had no opportunity to incorporate this factor into our analysis.

It has been reported that  $\alpha$ -Gal antigens on the pathogen surface can play an important role during infection (Yilmaz *et al.*, 2014; Cabezas-Cruz and de la Fuente, 2017; Cabezas-Cruz *et al.*, 2017; Pacheco *et al.*, 2020), and a complementary relationship appears to emerge for the anti- $\alpha$ -Gal immune response. Yilmaz *et al.* (2014) showed that the production of anti- $\alpha$ -Gal antibodies is associated with protection against malaria transmission. They suggested that immunization with adjuvants that favour the production of anti- $\alpha$ -Gal IgM antibodies might protect against malaria (Yilmaz *et al.*, 2014). In an investigation of anti- $\alpha$ -Gal IgG antibody levels in COVID-19, the development of interventions with probiotics based on commensal bacteria with  $\alpha$ -Gal epitopes was proposed to modify the microbiota and increase  $\alpha$ -Gal-induced protective immune response (Urta *et al.*, 2021). Finally, patients infected with *T. cruzi* showed high levels of anti- $\alpha$ -Gal in the acute and chronic phases of Chagas disease (Avila *et al.*, 1988; Travassos *et al.*, 1988; Gazzinelli *et al.*, 1991). Anti- $\alpha$ -Gal antibodies are known to bind  $\alpha$ -Gal present on the *T. cruzi* surface and induce complement-mediated lysis of the parasite, suggesting that anti- $\alpha$ -Gal contributes to host protection (Towbin *et al.*, 1987; Gazzinelli *et al.*, 1991).

In this study, we conclude that by monitoring 30 ATL-infected patients, our investigation reaffirmed the significance of serum IgG antibody levels against the  $\alpha$ -Gal trisaccharide motif as a potential marker of *Leishmania* susceptibility. The significantly elevated anti- $\alpha$ -Gal antibody levels observed in ATL-infected individuals compared with healthy subjects highlight the promising utility of this biomarker in diagnostic and monitoring

applications. Furthermore, the predominant use of meglumine antimoniate in treatment, when administered to most patients, yielded limited symptom improvement, suggesting potential challenges in current therapeutic approaches. Nevertheless, post-treatment analysis revealed a significant decrease in IgG anti- $\alpha$ -Gal antibodies in a subset of patients, indicating a potential correlation between the treatment response and antibody levels.

Notably, the identification of *Leishmania* species revealed a predominance of *Leishmania braziliensis* infections exhibiting heightened anti- $\alpha$ -Gal responses in contrast to a single case of *Leishmania infantum* infection. This underscores the importance of considering *Leishmania* species diversity in developing tailored treatment strategies and emphasizes the urgent need for future research focusing on human vaccines and innovative therapeutic interventions.

**Data availability statement.** N/A.

**Acknowledgements.** The graphic art here was created using BioRender.com.

**Author contributions.** Conceptualization, A.F.M., A.P.V. and M.G.F.; methodology, D.M.S.L., A.F.M., A.P.V., T.S.G., R.M.R. and M.G.F.; formal analysis, D.M.S.L., A.P.V. and A.F.M.; investigation, A.F.M., A.P.V., D.M.S.L., M.G.F., R.M.R., J.M.S.L.; resources, A.F.M., A.P.V. and C.F.G.; data curation, D.M.S.L.; writing – original draft preparation, D.M.S.L., A.F.M. and A.P.V.; writing – review and editing, A.F.M. and M.G.F.; visualization, K.S.M.R., T.M.V., S.F.G.C. and C.F.G.

**Financial support.** This research was funded by Fundação de Amparo à Pesquisa do Estado de Minas Gerais – FAPEMIG. # APQ 03176-18 No 251.

**Competing interests.** The authors declare no conflicts of interest.

**Ethical standards.** This research was approved (opinion number 5.086.431/2021) by the Research Ethics Committee of the Universidade Estadual de Montes Claros (CEP/Unimontes) and accredited by CONEP (Comitê Nacional de Ética em Pesquisa).

## References

- Akhoundi M, Kuhls K, Cannet A, Votycka J, Marty P, Delaunay P and Sereno D (2016) A historical overview of the classification, evolution, and dispersion of *Leishmania* parasites and sandflies. *PLoS Neglected Tropical Diseases* **10**, e0004349.
- Al-Salem WS, Ferreira DM, Dyer NA, Alyamani EJ, Balghonaim SM, Al-Mehna AY, Al-Zubiany S, Ibrahim el K, Al Shahrani AM, Alkhuailid H, Aldahan MA, Al Jarallah AM, Abdelhady SS, Al-Zahrani MH, Almeida IC and Acosta-Serrano A (2014) Detection of high levels of anti-alpha-galactosyl antibodies in sera of patients with Old World cutaneous leishmaniasis: a possible tool for diagnosis and biomarker for cure in an elimination setting. *Parasitology* **141**, 1898–1903.
- Andrade AL, Martelli CM, Oliveira RM, Silva SA, Aires AI, Soussumi LM, Covas DT, Silva LS, Andrade JG, Travassos LR and Almeida IC (2004) Short report: benzimidazole efficacy among *Trypanosoma cruzi*-infected adolescents after a six-year follow-up. *American Journal of Tropical Medicine and Hygiene* **71**, 594–597.
- Armijos RX, Weigel MM, Izurieta R, Racines J, Zurita C, Herrera W and Vega M (1997) The epidemiology of cutaneous leishmaniasis in subtropical Ecuador. *Tropical Medicine & International Health* **2**, 140–152.
- Assis RR, Ibraim IC, Noronha FS, Turco SJ and Soares RP (2012) Glycoinositolphospholipids from *Leishmania braziliensis* and *L. infantum*: modulation of innate immune system and variations in carbohydrate structure. *PLoS Neglected Tropical Diseases* **6**, e1543.
- Avila JL, Rojas M and Garcia L (1988) Persistence of elevated levels of galactosyl-alpha(1-3)galactose antibodies in sera from patients cured of visceral leishmaniasis. *Journal of Clinical Microbiology* **26**, 1842–1847.
- Bailey F, Mondragon-Shem K, Hotez P, Ruiz-Postigo JA, Al-Salem W, Acosta-Serrano A and Molyneux DH (2017) A new perspective on cutaneous leishmaniasis-implications for global prevalence and burden of disease estimates. *PLoS Neglected Tropical Diseases* **11**, e0005739.
- Bailey F, Mondragon-Shem K, Haines LR, Olabi A, Alorfi A, Ruiz-Postigo JA, Alvar J, Hotez P, Adams ER, Velez ID, Al-Salem W, Eaton J,



- Acosta-Serrano A and Molyneux DH (2019) Cutaneous leishmaniasis and co-morbid major depressive disorder: a systematic review with burden estimates. *PLoS Neglected Tropical Diseases* **13**, e0007092.
- Bennis I, Thys S, Filali H, De Brouwere V, Sahibi H and Boelaert M (2017) Psychosocial impact of scars due to cutaneous leishmaniasis on high school students in Errachidia province, Morocco. *Infectious Diseases of Poverty* **6**, 46.
- Boussaa S, Guernaoui S, Pesson B and Boumezzough A (2005) Seasonal fluctuations of phlebotomine sand fly populations (Diptera: Psychodidae) in the urban area of Marrakech, Morocco. *Acta Tropica* **95**, 86–91.
- Brito CR, McKay CS, Azevedo MA, Santos LC, Venuto AP, Nunes DF, D'Avila DA, Rodrigues da Cunha GM, Almeida IC, Gazzinelli RT, Galvao LM, Chiari E, Sanhueza CA, Finn MG and Marques AF (2016) Virus-like particle display of the alpha-gal epitope for the diagnostic assessment of Chagas disease. *ACS Infectious Diseases* **2**, 917–922.
- Burza S, Croft SL and Boelaert M (2018) Leishmaniasis. *Lancet (London, England)* **392**, 951–970.
- Cabezas-Cruz A and de la Fuente J (2017) Immunity to alpha-gal: toward a single-antigen pan-vaccine to control major infectious diseases. *ACS Central Science* **3**, 1140–1142.
- Cabezas-Cruz A, Mateos-Hernandez L, Alberdi P, Villar M, Riveau G, Hermann E, Schacht AM, Khalife J, Correia-Neves M, Gortazar C and de la Fuente J (2017) Effect of blood type on anti-alpha-Gal immunity and the incidence of infectious diseases. *Experimental and Molecular Medicine* **49**, e301.
- Cardoso DT, de Souza DC, de Castro VN, Geiger SM and Barbosa DS (2019) Identification of priority areas for surveillance of cutaneous leishmaniasis using spatial analysis approaches in Southeastern Brazil. *BMC Infectious Diseases* **19**, 318.
- Carneiro MB and Peters NC (2021) The paradox of a phagosomal lifestyle: how innate host cell-*Leishmania amazonensis* interactions lead to a progressive chronic disease. *Frontiers in Immunology* **12**, 728848.
- Chakravarty J and Sundar S (2010) Drug resistance in leishmaniasis. *Journal of Global Infectious Diseases* **2**, 167–176.
- Chappuis F, Sundar S, Hailu A, Ghalib H, Rijal S, Peeling RW, Alvar J and Boelaert M (2007) Visceral leishmaniasis: what are the needs for diagnosis, treatment and control? *Nature Reviews Microbiology* **5**, 873–882.
- Dahal P, Singh-Phulgenda S, Olliaro PL and Guerin PJ (2021) Gender disparity in cases enrolled in clinical trials of visceral leishmaniasis: a systematic review and meta-analysis. *PLoS Neglected Tropical Diseases* **15**, e0009204.
- Descoteaux A and Turco SJ (1999) Glycoconjugates in *Leishmania* infectivity. *Biochimica et Biophysica Acta* **1455**, 341–352.
- de Vries HJC and Schallig HD (2022) Cutaneous Leishmaniasis: a 2022 updated narrative review into diagnosis and management developments. *American Journal of Clinical Dermatology* **23**, 823–840.
- Diniz JL, Costa MO and Goncalves DU (2011) Mucocutaneous Leishmaniasis: clinical markers in presumptive diagnosis. *Brazilian Journal of Otorhinolaryngology* **77**, 380–384.
- Gazzinelli RT, Pereira ME, Romanha A, Gazzinelli G and Brener Z (1991) Direct lysis of *Trypanosoma cruzi*: a novel effector mechanism of protection mediated by human anti-gal antibodies. *Parasite Immunology* **13**, 345–356.
- Gonzalez C, Wang O, Strutz SE, Gonzalez-Salazar C, Sanchez-Cordero V and Sarkar S (2010) Climate change and risk of leishmaniasis in North America: predictions from ecological niche models of vector and reservoir species. *PLoS Neglected Tropical Diseases* **4**, e585.
- Gosch CS, Marques CP, Resende BS, Souza JDS, Rocha R, Lopes DSS, Gosch MS, Dias FR and Dorta ML (2017) American tegumentary leishmaniasis: epidemiological and molecular characterization of prevalent *Leishmania* species in the state of Tocantins, Brazil, 2011–2015. *Revista do Instituto de Medicina Tropical de Sao Paulo* **59**, e91.
- Grangeiro Junior CRP, Pimentel JVC, Teixeira Junior AG, Jesus AF, Galvao TCF, Souza LAA, Gadelha M, Damasceno KS, Rolim Neto ML, Lima MAP, Nascimento VBD and Silva C (2018) American cutaneous leishmaniasis in a northeast Brazilian city: clinical and epidemiological features. *Revista da Sociedade Brasileira de Medicina Tropical* **51**, 837–842.
- Gupta AK, Das S, Kamran M, Ejazi SA and Ali N (2022) The pathogenicity and virulence of *Leishmania* – interplay of virulence factors with host defenses. *Virulence* **13**, 903–935.
- Harhay MO, Olliaro PL, Costa DL and Costa CH (2011) Urban parasitology: visceral leishmaniasis in Brazil. *Trends in Parasitology* **27**, 403–409.
- Jeronimo SM, Duggal P, Braz RF, Cheng C, Monteiro GR, Nascimento ET, Martins DR, Karplus TM, Ximenes MF, Oliveira CC, Pinheiro VG, Pereira W, Peralta JM, Sousa J, Medeiros IM, Pearsoni RD, Burns TL, Pugh EW and Wilson ME (2004) An emerging peri-urban pattern of infection with *Leishmania chagasi*, the protozoan causing visceral leishmaniasis in northeast Brazil. *Scandinavian Journal of Infectious Diseases* **36**, 443–449.
- Keivric I, Cappel MA and Keeling JH (2015) New World and Old World *Leishmania* infections: a practical review. *Dermatologic Clinics* **33**, 579–593.
- Lindoso JA, Cunha MA, Queiroz IT and Moreira CH (2016) Leishmaniasis-HIV coinfection: current challenges. *HIV AIDS (Auckl)* **8**, 147–156.
- Lockard RD, Wilson ME and Rodriguez NE (2019) Sex-related differences in immune response and symptomatic manifestations to infection with *Leishmania* species. *Journal of Immunology Research* **2019**, 4103819.
- Machado PR, Ampuero J, Guimaraes LH, Villasboas L, Rocha AT, Schriefer A, Sousa RS, Talhari A, Penna G and Carvalho EM (2010) Miltefosine in the treatment of cutaneous leishmaniasis caused by *Leishmania braziliensis* in Brazil: a randomized and controlled trial. *PLoS Neglected Tropical Diseases* **4**, e912.
- Machado GU, Prates FV and Machado PRL (2019) Disseminated leishmaniasis: clinical, pathogenic, and therapeutic aspects. *Anais Brasileiros De Dermatologia* **94**, 9–16.
- Marchi MNA, Caldart ET, Martins FDC and Freire RL (2019) Spatial analysis of leishmaniasis in Brazil: a systematized review. *Revista do Instituto de Medicina Tropical de Sao Paulo* **61**, e68.
- McConville MJ, Homans SW, Thomas-Oates JE, Dell A and Bacic A (1990) Structures of the glycoinositolphospholipids from *Leishmania major*. A family of novel galactofuranose-containing glycolipids. *Journal of Biological Chemistry* **265**, 7385–7394.
- Mojahed N, Mohammadkhani MA and Mohamadkhani A (2022) Climate crises and developing vector-borne diseases: a narrative review. *Iranian Journal of Public Health* **51**, 2664–2673.
- Moura APV, Santos LCB, Brito CRN, Valencia E, Junqueira C, Filho AAP, Sant'Anna MRV, Gontijo NF, Bartholomeu DC, Fujiwara RT, Gazzinelli RT, McKay CS, Sanhueza CA, Finn MG and Marques AF (2017) Virus-like particle display of the alpha-gal carbohydrate for vaccination against *Leishmania* infection. *ACS Central Science* **3**, 1026–1031.
- Oshaghi MA, Rasolian M, Shirzadi MR, Mohtarami F and Doosti S (2010) First report on isolation of *Leishmania tropica* from sandflies of a classical urban cutaneous leishmaniasis focus in southern Iran. *Experimental Parasitology* **126**, 445–450.
- Pacheco I, Contreras M, Villar M, Rivalde MA, Alberdi P, Cabezas-Cruz A, Gortazar C and de la Fuente J (2020) Vaccination with alpha-gal protects against mycobacterial infection in the zebrafish model of tuberculosis. *Vaccines (Basel)* **8**(2), 195. <https://doi.org/10.3390/vaccines8020195>
- Pasha F, Saleem S, Nazir T, Tariq J and Qureshi K (2022) Visceral leishmaniasis (kala-azar): a triumph against a trickster disease. *Cureus* **14**, e25698.
- Pearson RD and Sousa AQ (1996) Clinical spectrum of Leishmaniasis. *Clinical Infectious Diseases* **22**, 1–13.
- Pinart M, Rueda JR, Romero GA, Pinzon-Florez CE, Osorio-Arango K, Silveira Maia-Elkhoury AN, Reveiz L, Elias VM and Tweed JA (2020) Interventions for American cutaneous and mucocutaneous leishmaniasis. *The Cochrane Database of Systematic Reviews* **8**, CD004834.
- Pinto M, de Oliveira TM, de Assis Aguiar AN, Pinto PEM, Barbosa DS, de Araujo Diniz S and Silva MX (2020) Profile of American tegumentary leishmaniasis in transmission areas in the state of Minas Gerais, Brazil, from 2007 to 2017. *BMC Infectious Diseases* **20**, 163.
- Ramalho DB, Silva RED, Senna MCR, Moreira HSA, Pedras MJ, Avelar DM, Saraiva L, Rabello A and Cota G (2018) Meglumine antimoniate intralesional infiltration for localised cutaneous leishmaniasis: a single arm, open label, phase II clinical trial. *Memorias do Instituto Oswaldo Cruz* **113**, e180200.
- Ramirez JL and Guevara P (1997) Persistent infections by *Leishmania* (*Viannia*) *braziliensis*. *Memorias do Instituto Oswaldo Cruz* **92**, 333–338.
- Ready PD (2008) Leishmaniasis emergence and climate change. *Revue Scientifique et Technique* **27**, 399–412.
- Rispens T, Derksen NI, Commins SP, Platts-Mills TA and Aalberse RC (2013) IgE production to alpha-gal is accompanied by elevated levels of specific IgG1 antibodies and low amounts of IgE to blood group B. *PLoS One* **8**, e55566.
- Rocklov J and Dubrow R (2020) Climate change: an enduring challenge for vector-borne disease prevention and control. *Nature Immunology* **21**, 479–483.
- Rodriguez NE, Lima ID, Gaur Dixit U, Turcotte EA, Lockard RD, Batra-Sharma H, Nascimento EL, Jeronimo SMB and Wilson ME



- (2018) Epidemiological and experimental evidence for sex-dependent differences in the outcome of *Leishmania infantum* infection. *American Journal of Tropical Medicine and Hygiene* **98**, 142–145.
- Ross R** (1903) Note on the bodies recently described by Leishman and Donovan. *British Medical Journal* **2**, 1261–1262.
- Sampaio RNR, Silva J, Paula CDR, Porto C, Motta J, Pereira LIA, Martins SS, Barroso DH, Freire GSM and Gomes CM** (2019) A randomized, open-label clinical trial comparing the long-term effects of miltefosine and meglumine antimoniate for mucosal leishmaniasis. *Revista da Sociedade Brasileira de Medicina Tropical* **52**, e20180292.
- Sanchez-García L, Berzunza-Cruz M, Becker-Fausser I and Rebollar-Tellez EA** (2010) Sand flies naturally infected by *Leishmania* (*L.*) *mexicana* in the peri-urban area of Chetumal city, Quintana Roo, Mexico. *Transactions of the Royal Society of Tropical Medicine and Hygiene* **104**, 406–411.
- Semenza JC and Zeller H** (2014) Integrated surveillance for prevention and control of emerging vector-borne diseases in Europe. *Euro Surveillance* **19**(13), 20757. <https://doi.org/10.2807/1560-7917.es2014.19.13.20757>
- Sheikh SY, Hassan F, Shukla D, Bala S, Faruqui T, Akhter Y, Khan AR and Nasibullah M** (2024) A review on potential therapeutic targets for the treatment of leishmaniasis. *Parasitology International* **100**, 102863.
- Silveira FT, Lainson R and Corbett CE** (2004) Clinical and immunopathological spectrum of American cutaneous leishmaniasis with special reference to the disease in Amazonian Brazil: a review. *Memorias do Instituto Oswaldo Cruz* **99**, 239–251.
- Soong L, Henard CA and Melby PC** (2012) Immunopathogenesis of non-healing American cutaneous leishmaniasis and progressive visceral leishmaniasis. *Seminars in Immunopathology* **34**, 735–751.
- Tarallo VD, Dantas-Torres F, Lia RP and Otranto D** (2010) Phlebotomine sand fly population dynamics in a leishmaniasis endemic peri-urban area in southern Italy. *Acta Tropica* **116**, 227–234.
- Torres-Guerrero E, Quintanilla-Cedillo MR, Ruiz-Esmenjaud J and Arenas R** (2017) Leishmaniasis: a review. *F1000Research* **6**, 750.
- Towbin H, Rosenfelder G, Wieslander J, Avila JL, Rojas M, Szarfman A, Esser K, Nowack H and Timpl R** (1987) Circulating antibodies to mouse laminin in Chagas disease, American cutaneous leishmaniasis, and normal individuals recognize terminal galactosyl(alpha 1–3)-galactose epitopes. *Journal of Experimental Medicine* **166**, 419–432.
- Travassos LR, Milani SR, Oliveira TG, Takaoka D and Gorin PA** (1988) Immunobiological responses to short carbohydrate epitopes in *Trypanosoma cruzi*. *Memorias do Instituto Oswaldo Cruz* **83**(suppl. 1), 427–430.
- Travi BL, Osorio Y, Melby PC, Chandrasekar B, Arteaga L and Saravia NG** (2002) Gender is a major determinant of the clinical evolution and immune response in hamsters infected with *Leishmania* spp. *Infection and Immunity* **70**, 2288–2296.
- Urta JM, Ferreras-Colino E, Contreras M, Cabrera CM, Fernandez de Mera IG, Villar M, Cabezas-Cruz A, Gortazar C and de la Fuente J** (2021) The antibody response to the glycan alpha-Gal correlates with COVID-19 disease symptoms. *Journal of Medical Virology* **93**, 2065–2075.
- Ursine RL, Rocha MF, Sousa JF, Santos RCD, Soares MD, Gusmao MSF, Leite ME and Vieira TM** (2021) American tegumentary Leishmaniasis in an endemic municipality in the North of Minas Gerais State: spatial analysis and socio-environmental factors. *Revista do Instituto de Medicina Tropical de Sao Paulo* **63**, e2.
- Ursine RL, Rocha MF, Neto FC, Leite ME, Dolabela Falcao L, Gorla DE, de Carvalho SFG and Vieira TM** (2023) Influence of anthropic changes and environmental characteristics on the occurrence of tegumentary leishmaniasis in Montes Claros, Minas Gerais, Brazil, between 2012 and 2019. *Acta Tropica* **238**, 106787.
- Volpedo G, Pacheco-Fernandez T, Holcomb EA, Cipriano N, Cox B and Satoskar AR** (2021) Mechanisms of immunopathogenesis in cutaneous leishmaniasis and post kala-azar dermal leishmaniasis (PKDL). *Frontiers in Cellular and Infection Microbiology* **11**, 685296.
- WHO** (2024) Leishmaniasis. In.
- Yamey G and Torrelee E** (2002) The world's most neglected diseases. *BMJ* **325**, 176–177.
- Yilmaz B, Portugal S, Tran TM, Gozzelino R, Ramos S, Gomes J, Regalado A, Cowan PJ, d'Apice AJ, Chong AS, Doumbo OK, Traore B, Crompton PD, Silveira H and Soares MP** (2014) Gut microbiota elicits a protective immune response against malaria transmission. *Cell* **159**, 1277–1289.