

Central diabetes insipidus misdiagnosed as acute gastroenteritis in a pediatric patient

Laleh Gharahbaghian, MD; Shahram Lotfipour, MD, MPH; Christopher E. McCoy, MD; Wirachin Hoonpongsimanont, MD; Mark Langdorf, MD, MHPE

ABSTRACT

This case report describes an unusual presentation of nausea, vomiting and diarrhea, which was misdiagnosed as acute gastroenteritis in a 6-year-old girl. The patient later returned to the emergency department (ED) with severe dehydration from idiopathic central diabetes insipidus (DI). At her first visit, this previously healthy patient presented with mild dehydration, signs of acute gastroenteritis and normal urine output. Her brother had experienced similar symptoms a few days earlier. She tolerated an oral fluid challenge and was discharged from the ED with stable vital signs. Two days later, the patient returned with severe dehydration, resolving diarrhea and persistent vomiting. She was admitted to the pediatric intensive care unit. Magnetic resonance imaging illustrated an absent posterior pituitary enhancing signal, which demonstrated a loss of function in that region. There were no other abnormalities. The patient subsequently received desmopressin with improving clinical status and was discharged on the eighth hospital day. DI is a rare disease, but can be fatal if left undiagnosed. It should, therefore, be considered in the differential diagnosis of a dehydrated patient with an unexpectedly low urine specific gravity.

Keywords: diabetes insipidus, dehydration, pediatric, gastroenteritis

RÉSUMÉ

Nous présentons le cas inhabituel d'une fillette de 6 ans présentant des nausées, des vomissements et des diarrhées, pour lequel un mauvais diagnostic de gastro-entérite aiguë est posé. La patiente est retournée à l'urgence, souffrant de déshydratation sévère, associée à un diabète insipide (DI) central idiopathique. Lors de sa première visite, la patiente, qui était en bonne santé précédemment, présentait des signes de légère déshydratation et de gastro-entérite aiguë. Son débit urinaire était normal. Son frère avait eu des symptômes similaires quelques jours plus tôt. Elle a toléré une solution par voie orale et a obtenu son congé de l'urgence, ses signes vitaux étant stables. Deux jours plus tard, la patiente se présente de nouveau à l'urgence, se plaignant de déshydratation sévère et de vomissements persistants. La diarrhée avait par contre disparu. Elle est admise à l'unité des soins intensifs pédiatriques. Un examen par imagerie à résonance magnétique a révélé l'absence d'hypersignal du lobe postérieur de l'hypophyse, ce qui témoigne d'une perte de fonction post-hypophysaire. Aucune autre anomalie n'a été relevée. La patiente a été traitée à la desmopressine, ce qui a amélioré son état clinique. Elle a reçu son congé au huitième jour d'hospitalisation.

Introduction

Central diabetes insipidus (DI) is more common than nephrogenic DI in the pediatric population. It is usually caused by a deficiency in the antidiuretic hormone (ADH),

resulting in the loss of the ability to concentrate urine. Patients will quickly become severely dehydrated as the result of polyuria. Large dilute urinary volumes, with a urine specific gravity of less than 1.005, may cause hypernatremia and eventual death.¹ Early diagnosis can avoid such

From the Department of Emergency Medicine, University of California, Irvine School of Medicine, Orange, Calif.

Submitted Mar. 22, 2007; Revised Feb. 5, 2008; Accepted Feb. 22, 2008

This article has been peer reviewed.

CJEM 2008;10(5):488-92

dire consequences. Since 30% of central DI is idiopathic, the clinical presentation may be that of a secondary illness. It should be considered, therefore, in the differential diagnosis of any dehydrated patient with an unexpectedly low urine specific gravity. We describe a pediatric patient with idiopathic central DI who presented with vomiting and diarrhea, normal urine output and serum sodium and low urine specific gravity despite severe dehydration.

Case report

Initial visit

A 6-year-old girl was brought to the emergency department (ED) by her mother. The patient complained of nausea, vomiting and diarrhea over the previous 2 days. Her mother described the vomiting as nonbloody and nonbilious. The patient had 7 episodes of vomiting over this 2-day period and was unable to tolerate liquids. There were 2 episodes of nonbloody diarrhea that began on the day of the ED visit. Her mother also reported that her daughter had had a runny nose over the past 5 days, for which she had taken her to see their family physician. There was no medication prescribed and the symptoms were presumably attributed to a viral etiology. Her mother stated that the patient's 18-month-old brother also had nausea and vomiting, without diarrhea. The children did not eat the same meals but were in close contact with each other. There was no associated abdominal pain, fever, chills, rash, cough, change in urine output, recent travel, trauma or antibiotic use, nor were there any previous episodes of these symptoms. The patient's past medical and surgical history was unremarkable, and the patient was not taking medication. The patient was born at term by spontaneous vaginal delivery without complication, and her immunizations were up to date. The family history was unremarkable, and no alcohol or drugs were reported to be used in the home.

The physical exam showed an oral temperature of 36.4°C, a heart rate of 131 beats/minute and a respiratory rate of 20 breaths/minute. The patient's blood pressure was 115/79 mm Hg and her oxygen saturation on room air was 100%. Her measured weight was 22 kg, and she appeared to be her stated age. She was alert, nontoxic, quiet and in no distress. No specific signs of dehydration were documented. Her head was normocephalic and atraumatic. Her oropharynx and tympanic membranes were clear, and her pupils were equal and reactive to light. There was no evidence of lymphadenopathy. Her lungs were clear to auscultation. Her heart had a regular rhythm, but was tachycardic. Her abdomen was soft, and she complained of mild tenderness to deep palpation in the epigastric area without rebound or

guarding. There was no cyanosis or edema of the extremities and no rash. The patient was alert, oriented and followed commands without focal neurologic abnormalities.

Her glucose at bedside was 6.4 mmol/L. A catheterized urinalysis showed a specific gravity of 1.003, a pH of 7.0, ketone of 15 mg/dL, 5 white blood cells per high power field and no protein, glucose, bilirubin, hemoglobin, leukocyte esterase, nitrite, red blood cells, epithelial cells or crystals; however, there was a rare amount of bacteria. A chest radiograph, performed to evaluate for an occult pneumonia, was unremarkable. No blood tests were performed.

The patient received 440 mL of an intravenous (IV) normal saline bolus and tolerated oral liquids. There was no documented urine output during the ED visit. The patient's rechecked vital signs were normal, and she was discharged with a diagnosis of acute gastroenteritis. Discharge instructions included keeping well hydrated, following up with her family physician and returning to the ED in case of fever, chills, worsening symptoms, continued vomiting or any other concerns.

Return visit

Two days later, the patient returned complaining of nonbloody vomiting that was occurring 7 times daily with no bowel movement since the last ED visit. Her mother reported that she had been less active, was begging for water, breathing fast and having increasing abdominal pain, which was intermittent in nature and mild in severity. The patient denied fever, chills, diarrhea and dysuria, and her urine output was unchanged.

Her physical exam showed an oral temperature of 36.9°C, a heart rate of 107 beats/minute and a respiratory rate of 24 breaths/minute. Her blood pressure was 112/85 mm Hg and her oxygen saturation was 100% on room air. The patient's measured weight was 16 kg (a loss of 6 kg from the previous visit). The patient was sleepy but arousable, and did not flinch to IV catheter placement. Her eyes were sunken with dry mucous membranes and dry lips. Her lungs were clear with tachypnea, her heart rate was regular but tachycardic, and there was a 3-second capillary refill rate. She had dry skin with diminished turgor. Her abdomen was soft with mild tenderness in the epigastric area without distension, rebound or guarding. The patient was able to follow commands and there were no focal neurologic findings.

Her bedside glucose was normal. A complete metabolic panel showed a sodium of 145 mmol/L (reference range [RR] 136–142 mmol/L), potassium 3.1 mmol/L (RR 3.5–5.0 mmol/L), chloride 107 mmol/L (RR 96–106 mmol/L), bicarbonate 22 mmol/L (RR 21–28 mmol/L),

blood urea nitrogen 1.1 mmol/L (RR 2.9–8.2 mmol/L), creatinine 38.1 $\mu\text{mol/L}$ (RR 8–31 $\mu\text{mol/L}$), glucose 6.2 mmol/L (RR 3.9–6.1 mmol/L), anion gap 16 mmol/L, and normal lipase and liver function tests. Her white blood cell count was $11.9 \times 10^9/\text{L}$ (RR 4.5–11 $\times 10^9/\text{L}$), hemoglobin 14.3 g/L (RR 11.5–15.5 g/L), hematocrit 0.43 (RR 34–45) and platelets $540 \times 10^9/\text{L}$ (RR 150–400 $\times 10^9/\text{L}$). A catheterized urinalysis showed a specific gravity of 1.000, no ketones, with all other values within normal limits. A venous blood gas showed respiratory alkalosis with a pH of 7.57 (RR 7.36–7.4), a Pco_2 25 mm Hg (RR 42–48 mm Hg), bicarbonate 22.5 mmol/L (RR 21–27 mmol/L) and the base excess was 2 mEq/L. An acute abdominal radiograph series was unremarkable.

The patient received supplemental oxygen and a 640-mL normal saline IV bolus. She was placed on a cardiac monitor, which showed sinus tachycardia. Her urine and blood were cultured, and she was started on IV antibiotics and received IV potassium. The patient was admitted to the pediatric intensive care unit.

While in the pediatric intensive care unit, the urine specific gravity remained below 1.005. Because of our clinical suspicion of central DI, we ordered magnetic resonance imaging (MRI) with and without contrast, which demonstrated an absent enhancing signal from the posterior pituitary thus indicating loss of function. No other abnormalities were noted. An endocrinology consultation recommended desmopressin, which was started on the second hospital day. The patient's ADH level was 0.7 pmol/L (0.9–4.4). Her anterior pituitary hormone levels, including thyroid stimulating hormone, prolactin and corticotropin, were within normal limits. The urine and blood cultures were negative and antibiotics were stopped on the second day. Her serum sodium peaked at 152 mmol/L. The patient improved clinically and was discharged on the eighth hospital day with diagnoses of idiopathic central DI and severe dehydration. Discharge medications included desmopressin and follow-up was scheduled with endocrinology.

Discussion

Nausea, vomiting and diarrhea are common complaints in the ED, especially in the pediatric population, and are commonly diagnosed as acute gastroenteritis. However, they are also uncommon signs of DI. Central DI is, itself, uncommon, with a prevalence of 1 case per 25 000 population.^{1,2} However, it is important to detect DI early, as severe dehydration and death occur most commonly in patients with restricted access to water, especially in children and the elderly.^{1,3} In this case, it is difficult to know whether the

patient had acute gastroenteritis that unmasked her idiopathic central DI or if her symptoms were a result of it.

Pathophysiology

ADH is a napeptide hormone mostly secreted from the posterior pituitary. ADH secretion is under very precise control and is directly related to changes in plasma osmolarity. It acts on the renal collecting tubule to activate the insertion of water channels, or aquaporins, into the cell membrane. This in turn allows water to pass through the cell and into circulation, thus regulating free water excretion and stimulating free water reabsorption.⁴

Central DI is caused by a complete or partial deficiency in the synthesis or release of ADH resulting in polyuria, polydipsia, dilute urine, hypernatremia, dehydration and eventual death if untreated.^{1,3} Figure 1⁵ illustrates the integration of signals that trigger ADH release. In this case, the hallmark of very dilute urine was observed in a clinical setting that was most consistent with acute gastroenteritis and dehydration. The ADH level was normal because of a presumed partial deficiency of the posterior pituitary.

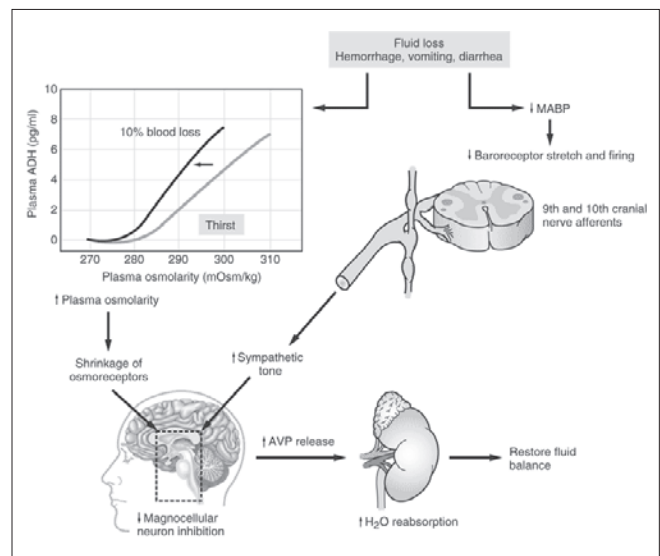


Fig. 1. Release of arginine vasopressin (AVP), also known as antidiuretic hormone (ADH), is stimulated by an increase in plasma osmolarity and by a decrease in blood volume. Small changes in plasma osmolarity above a threshold of 280 mOsm/kg produce an increase in ADH release before the stimulation of thirst. A decrease in blood volume and a decrease in mean arterial blood pressure (MABP) greater than 10% signal the hypothalamus to increase the release of ADH by using the 9th and 10th cranial nerves. These signals increase sympathetic tone, therefore decreasing magnocellular neuron inhibition and stimulating ADH release. Reprinted with permission from Molina, P. *Endocrine physiology*, 2nd ed.⁵

Etiology

The most common causes of central DI account for 70% of cases and include central nervous system tumours, trauma, infections or complications of cranial surgery.^{3,6,7} The defective sites of the pituitary typically affect areas that are involved in ADH secretion.^{1,8} Lesions of the posterior pituitary rarely cause permanent DI because the ADH is produced in the hypothalamus and can still be secreted into the circulation, thus explaining why our patient had dilute urine without polyuria.¹ Given that the MRI showed an absent posterior pituitary signal without other abnormalities, our patient likely had idiopathic central DI, which accounts for 30% of cases. These cases are thought to be a result of the destruction of hypothalamic cells, possibly from an autoimmune process. Other rare causes include familial DI, cancer (i.e., lung, lymphoma or leukemia), hypoxic encephalopathy, infiltrative disorders, anorexia and intracranial vascular lesions.^{2,8,9}

Signs and symptoms

Patients with central DI typically present with signs of dehydration. Paradoxically, they also present with polyuria, polydipsia and nocturnal enuresis. The 2 most common signs of DI are excessive thirst and increased urination.⁴ Our patient exhibited excessive thirst but no noted increase in urination. In contrast to our patient, those who develop central DI from an intracranial process typically have a more acute presentation. They present with polyuria, then a transient increased urine osmolarity because of stored ADH release that is followed by polydipsia and nocturia. The urine output can total as much as 3–18 L per day. In children, enuresis, fatigue and anorexia typically predominate.³ Like our patient, those who have a nontraumatic cause typically have a more indolent course. They have subtle symptoms because of free access to water and maintain normal serum sodium levels.¹ With increasing serum sodium and osmolarity, the patient will become more irritable, restless, ataxic and tremulous, with tonic spasms and eventual death if the serum osmolarity reaches 420 mmol/kg H₂O.¹ The overall mortality from hypernatremia is 10%.^{1,6}

Diagnosis

The diagnosis of DI is usually made clinically and is based on polyuria in the face of dehydration. ED laboratory studies, including low urine specific gravity and high serum sodium levels, are supportive.³ The hallmarks of DI are a urine specific gravity of less than 1.005 and a urine osmo-

larity of less than 200 mmol/kg H₂O.¹⁰ Additional tests include serum osmolarity, ADH level, urine sodium and the water deprivation test, which is a semiquantitative test to ensure adequate dehydration and maximal stimulation of ADH for diagnosis. It is performed in uncertain clinical cases while the patient is hospitalized.¹ The decreased ability to concentrate urine may also occur with hypokalemia (e.g., hyperaldosteronism), hypercalcemia, renal tubular abnormalities and primary polydipsia.⁵ The diagnostic imaging modality of choice for central DI is a brain MRI, or more specifically, a pituitary MRI. *T*₁-weighted images of the healthy posterior pituitary yield a hyperintense signal. In patients with central DI, this signal is absent, as it was in our patient.^{8,9,11}

Management

Treatment of central DI involves the restoration of tissue perfusion through the replacement of previous and ongoing fluid losses with IV normal saline boluses, followed by 5% dextrose in 0.45% normal saline maintenance. Target urine output is 0.5 mL/kg/h.^{1,3} Repeat sodium levels should be obtained to avoid reducing serum sodium by more than 10–15 mmol/L per day. More rapid reductions may result in seizures and cerebral edema. In children who have a serum sodium greater than 180 mmol/L, peritoneal dialysis can be considered.¹

The chronic treatment of DI is aimed at reducing the urine output, usually by increasing the concentration or activity of ADH. The drug of choice is desmopressin, a synthetic analogue of the native hormone, arginine vasopressin.¹ Two minor structural alterations to the molecule have created a drug that has prolonged antidiuretic action and minimal pressor activity, offering an ideal pharmacodynamic profile.¹² Patients with mild dehydration and an adequate thirst response can be discharged home with specific instructions on hydration and close follow-up. Patients with moderate-to-severe dehydration or who have poor follow-up should be admitted for evaluation by an endocrinologist.¹ Our patient was started on desmopressin and showed signs of clinical improvement before she was discharged.

Conclusion

Nausea, vomiting and diarrhea are common complaints of pediatric patients in the ED and point to the common diagnosis of acute gastroenteritis. DI is a rare disease but can be fatal if left undiagnosed. To discriminate between the common and benign and the rare and dangerous, the emer-

gency physician must assure that the urine specific gravity matches the clinical picture before deciding on disposition.

Competing interests: None declared.

References

1. Ahrens W. Fluid and electrolyte therapy. In: Tintinalli JE, Kelen GD, Stapczynski JS, et al. *Emergency medicine: a comprehensive study guide*. 6th ed. New York (NY): McGraw-Hill; 2004. p. 158-159.
2. Charmandari E, Brook CG. 20 years of experience in idiopathic central diabetes insipidus. *Lancet* 1999;353:2212-3.
3. Makaryus AN, McFarlane SI. Diabetes insipidus: diagnosis and treatment of a complex disease. *Cleve Clin J Med* 2006;73:65-71.
4. Baylis PH, Cheetham T. Diabetes insipidus. *Arch Dis Child* 1998;79:84-9.
5. Molina PE. Anterior pituitary gland. In: *Endocrine physiology*, 2nd ed. New York (NY): McGraw-Hill; 2006.
6. Rose BD, Post TW. Hyperosmolal states — hypernatremia. In: *Clinical physiology of acid-base and electrolyte disorders*, 5th ed. New York (NY): McGraw-Hill; 2001. p. 751-4.
7. Kimmel DW, O'Neil BP. Systemic cancer presenting as diabetes insipidus: Clinical and radiographic features of 11 patients with a review of metastatic-induced diabetes insipidus. *Cancer* 1983;52:2355.
8. Ikema T, Takasu N. Serial T1-weighted magnetic resonance imaging changes in a patient with central diabetes insipidus, possibly due to lymphocytic infundibuloneurohypophysitis. *Eur J Endocrinol* 2005;153:989-90.
9. Pivonello R, De Bellis A, Faggiano A, et al. Central diabetes insipidus and autoimmunity: relationship between the occurrence of antibodies to arginine vasopressin-secreting cells and clinical, immunological, and radiological features in a large cohort of patients with central diabetes insipidus of known and unknown etiology. *J Clin Endocrinol Metab* 2003;88:1629-36.
10. Cooperman M. Diabetes insipidus. Available: <http://imedicine.com/DisplayTopic.asp?bookid=6&topic=543> (accessed 2007 Jan 14).
11. Ozata M, Tayfun C, Ketaran K, et al. Magnetic resonance imaging of posterior pituitary for evaluation of the neurohypophyseal function in idiopathic and autosomal dominant neurohypophyseal diabetes insipidus. *Eur Radiol* 1997;7:1098-102.
12. Kim RJ, Malattia C, Allen M, et al. Vasopressin and desmopressin in central diabetes insipidus: adverse effects and clinical considerations. *Pediatr Endocrinol Rev* 2004;1:115-23.

Correspondence to: Dr. Shahram Lotfipour, Associate Clinical Professor, Department of Emergency Medicine, 101 The City Dr., Rte. 128-01, Orange CA 92868; shl@uci.edu