



# Right ventricular outflow tract stenting in children with tetralogy of Fallot beyond one year of age: indications and immediate outcomes

## Original Article

**Cite this article:** Abqari S, Kidwai MM, Kamran MM, Haseen MA, and Rabbani S (2025) Right ventricular outflow tract stenting in children with tetralogy of Fallot beyond one year of age: indications and immediate outcomes. *Cardiology in the Young* **35**: 393–398. doi: [10.1017/S1047951124036527](https://doi.org/10.1017/S1047951124036527)



Received: 18 May 2024  
Revised: 3 November 2024  
Accepted: 21 November 2024  
First published online: 26 December 2024

### Keywords:

right ventricular outflow tract stenting; tetralogy of Fallot; pulmonary artery; risk factors

### Corresponding author:

Shaad Abqari;  
Email: [drshaadabqari@gmail.com](mailto:drshaadabqari@gmail.com)

Shaad Abqari<sup>1</sup>, Mohammad Moaz Kidwai<sup>2</sup> , Mirza Mohammad Kamran<sup>3</sup> ,  
Mohammad Azam Haseen<sup>4</sup> and Shamayal Rabbani<sup>4</sup>

<sup>1</sup>Department of Pediatrics, JNMCH, Aligarh Muslim University, Aligarh, Uttar Pradesh, India; <sup>2</sup>Department of Cardiology, JNMCH, Aligarh Muslim University, Aligarh, Uttar Pradesh, India; <sup>3</sup>Interdisciplinary Pediatric cardiac centre, JNMCH, Aligarh Muslim University, Aligarh, Uttar Pradesh, India and <sup>4</sup>Department of CVTS, JNMCH, Aligarh Muslim University, Aligarh, Uttar Pradesh, India

### Abstract

**Introduction:** Right ventricular outflow tract stenting has emerged as a key palliative intervention for infants with tetralogy of Fallot who are not suitable candidates for complete repair. Although the Blalock-Taussig shunt remains the standard palliative approach for tetralogy of Fallot patients over one year of age, the potential of right ventricular outflow tract stenting in this older age group has not been widely explored. In this study, we present our experience with right ventricular outflow tract stenting in children beyond one year of age. **Methods and Results:** In this study, a total of 52 patients of tetralogy of Fallot who underwent palliative stenting of the right ventricular outflow tract from 2018 to 2022 were enrolled. Out of the 52 patients, 38 children were more than 1 year of age with a mean age of  $4.82 \pm 3.5$  (1.5–13 years) and mean weight of  $13.10 \pm 7.0$  (5.6–34) kgs. Most common indication was presence of unfavourable anatomy in 27 (71%) followed by presence of refractory spells in 14 (36.8%) patients. Stent embolisation was seen in one patient, while two patients developed features of pulmonary oedema and needed prolonged ventilatory support. There was no mortality seen in this study group. **Conclusion:** Our study has shown that right ventricular outflow tract stenting in children even beyond one year of age is technically feasible, with good immediate outcomes, especially in those who present with any complication, thus reducing the perioperative morbidity and mortality.

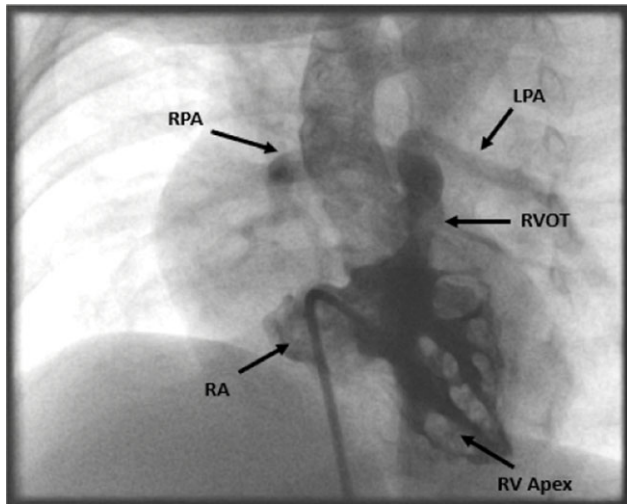
## Introduction

The ideal management of patients with tetralogy of Fallot is surgical complete repair, which includes patch closure of the ventricular septal defect and relief of the pulmonary outflow tract obstruction. However, there is a subset of patients who are not suitable for complete repair. These include patients with small-branch pulmonary arteries, refractory cyanotic spells, and severe systemic illness. Traditionally these patients are subjected to staged repair that includes palliative Blalock-Taussig shunt surgery. Post-operative management of Blalock-Taussig shunt is difficult, especially in infants, and it can lead to distortion of pulmonary arteries which can impact complete repair at a later date.<sup>1,2</sup> Transcatheter right ventricular outflow tract stenting is one such palliative procedure, which has gained acceptance in the recent past in infants. The reason is relatively easy post-procedure management as compared to Blalock-Taussig shunt and potential for a more physiological growth of pulmonary arteries.<sup>3,4</sup>

Majority of the literature has described right ventricular outflow tract stenting in neonatal period<sup>3,4,5</sup> or early infancy; however, the procedure can be an effective method of palliation even in children beyond 1 year of age. The present study is done to describe the feasibility, indications, technical considerations, and immediate outcome in children above one year of age undergoing right ventricular outflow tract stenting.

## Materials and methods

The present study was undertaken in a newly established Pediatric Cardiac Unit in a tertiary referral centre. Relevant data were obtained retrospectively from the case files and the catheterisation records and data of those children who were above one year of age and underwent right ventricular outflow tract stenting procedure was analysed. The patients were admitted at least 1 day prior to the procedure; however, in case of emergency intervention, the child was first stabilised in paediatric ICU and then shifted to Cath lab.



**Figure 1.** Figure showing right ventricular (RV) angiogram. RV angiogram done using NIH catheter in LAO30/cranial30 view showing severe infundibular and valvular pulmonary stenosis with confluent and hypoplastic branch pulmonary arteries.

### Inclusion criteria

A combined decision along with the surgical team was taken in each patient of tetralogy of Fallot admitted to our unit. All those children above one year of age diagnosed with tetralogy of Fallot physiology who were not fit for complete repair were subjected to palliative repair. The decision for right ventricular outflow tract stenting was made taking into consideration the clinical condition, associated comorbidities and anatomy.

### Exclusion criteria

All the children with tetralogy of Fallot and adequate anatomy for complete repair, and those less than one year of age.

### Right ventricular outflow tract stenting procedure

**Pre-procedure management:** Those patients who presented to us with cyanotic spells received standard treatment, which included intravenous beta blocker, ketamine infusion, bicarbonate, and fluid bolus. Patients who were stable were kept on oral propranolol.

The procedure was performed under conscious sedation or general anaesthesia depending on the clinical condition of the patient. Right femoral vein access was taken for all cases and right femoral artery cannula was inserted for continuous blood pressure monitoring and for blood gas analysis. Pre-procedure Oxygen saturation (Spo<sub>2</sub>) was recorded.

### Right ventricular angiogram

Right ventricular angiogram was performed through an Cordis NIH catheter or any other angiographic catheter placed within the apex of the right ventricle. A LAO 30 with cranial 30 tilt (Figure 1) and straight lateral projections was used to delineate the length and diameter of right ventricular outflow tract, diameter of pulmonary valve annulus and main pulmonary artery, sizes of branch pulmonary arteries, and their arborisation in the lung fields.

### The selection of stent

The type of stent used for right ventricular outflow tract stenting was a bare metal balloon-mounted stent and included either a

coronary stent, biliary stent, or peripheral vascular stent. The diameter and length of the stent were guided by the measurements done on echocardiography and angiography and influenced by the size of the patient, the dimensions of the outflow tract, and the anticipated length of palliation. It is always better to spare the pulmonary arteries annulus and to deploy the stent in the infundibular area. The reason being avoidance of transannular patch during complete repair. In these cases, the diameter of the stent was taken as 2 mm larger than the infundibular diameter. But in those patients who have hypoplastic main pulmonary arteries and/or pulmonary arteries annulus ( $z$  score  $< -3$ ), the stent had to be deployed in such a fashion so as to cover both the infundibular area as well as the annulus. The diameter of the stent in such cases was taken as at least 2 mm larger than the pulmonary arteries annulus. In smaller children, coronary stent was used; however, in older children or in those who required medium to longer-term palliation, a bare metal peripheral vascular stent was utilised.

### Crossing the right ventricular outflow tract

When a coronary stent was planned, a 0.014" coronary wire was advanced across the right ventricular outflow tract via an end-hole catheter and a stable position was achieved by placing the wire in distal branch pulmonary arteries. In non-coronary stents, which need a stiff wire, after crossing the right ventricular outflow tract with a 0.014 wire, a softer catheter such as Glide catheter was passed into the distal branch pulmonary arteries and coronary wire was replaced by a 0.032 Terumo wire and a diagnostic catheter like (Judkins Right) JR or multipurpose catheter was passed. Further, the Terumo wire was replaced with the stiff wires like Amplatz superstiff wire. The whole exercise was done due to the hypertrophied infundibular area which did not allow the diagnostic catheter to pass over the coronary wire in older children.

### Stent deployment

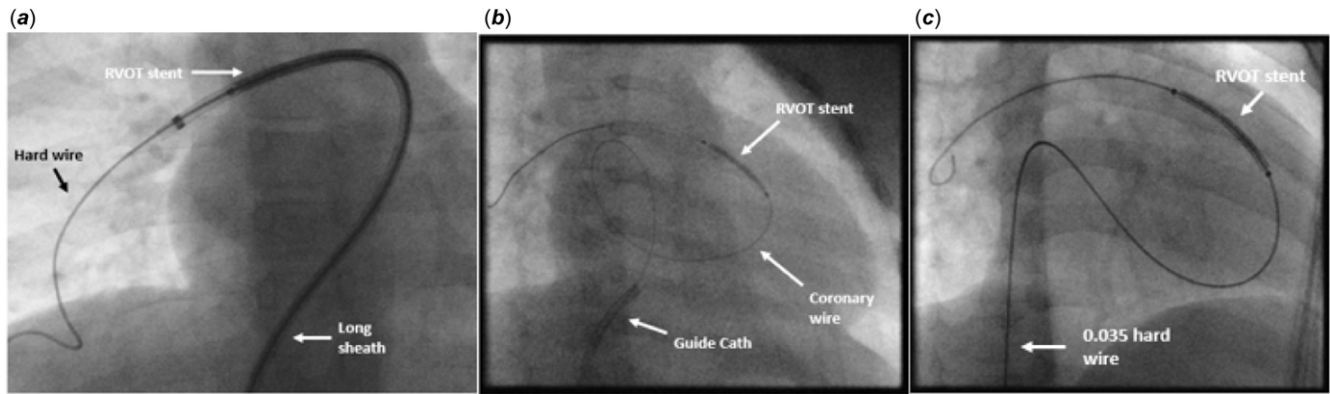
An appropriately sized long sheath (Figure 2a) or guide catheter (Figure 2b) was chosen to ensure optimal support during stent deployment. If manoeuvring the long sheath or guide catheter was challenging, the stent was deployed directly over the wire (Figure 2c). For cases requiring coronary stents, a guide catheter was used, while for non-coronary bare metal stents, a long sheath was preferred.

When a long sheath or guide catheter was employed, it was positioned across the right ventricular outflow tract to facilitate safe stent delivery and allow for check angiograms during deployment. In cases with a small annulus, the stent was deployed across the pulmonary valve, achieving secure two-point fixation at the infundibular level and the valve annulus.

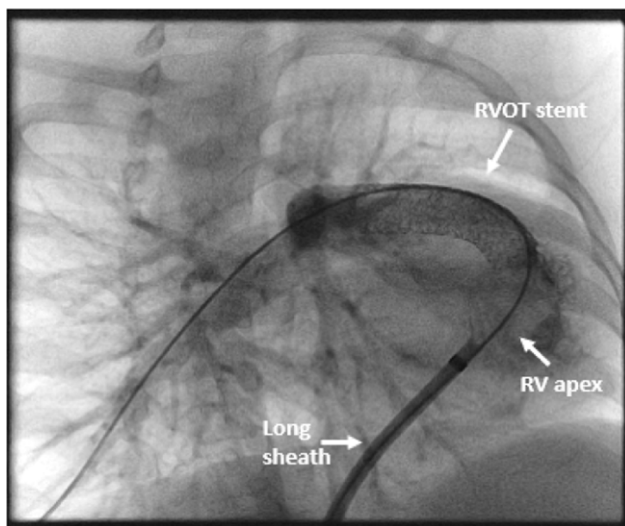
When the position of the stent appeared satisfactory, (confirming it on echocardiography), the balloon was inflated. The position of the stent was confirmed on check angiogram via the side arm of the sheath as shown in Figure 3. The position of the stent, opacification of the branch pulmonary arteries, and pulmonary valve movements were recorded on the final angiogram. The Spo<sub>2</sub> level was noted after stent deployment. Immediate post-procedure significant increase in the Spo<sub>2</sub> levels was anticipated from baseline. If not, then re-assessment of the stent position was made.

### Post procedure echocardiography

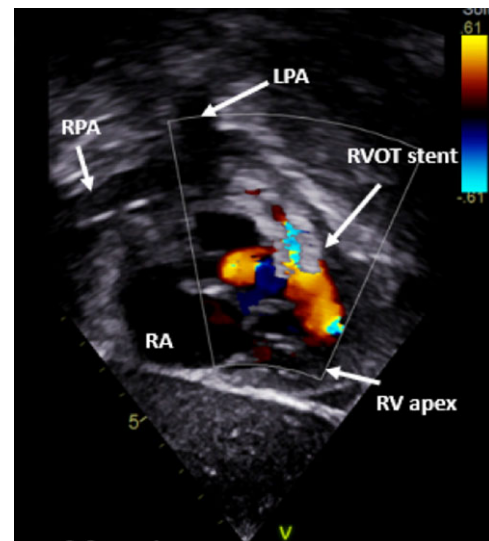
It was done to confirm the position of the stent (Figure 4), gradient across the stent, ventricular function, any interference



**Figure 2.** Figure showing stent being deployed with the support of long sheath (2a), guide catheter (2b) and without any support (2c). Figure 2a showing a long sheath being used to deploy the stent. Figure 2b showing guide catheter being used to deploy the stent. Figure 2c showing stent being deployed without the support of any sheath/catheter.



**Figure 3.** Figure showing check angiogram done via long sheath. Angiogram done via the long sheath in RAO30/cranial30 view, which was done post deployment, shows right ventricular outflow tract stent in proper position with relief of infundibular and valvular pulmonary stenosis.



**Figure 4.** Figure showing echo image after stent deployment. Colour doppler echo image in sub costal coronal view, showing right ventricular outflow tract stent in proper position covering the infundibular and valvular area.

with tricuspid valve function, and evidence for effusion. A repeat blood gas analysis was obtained to document the improvement in SaO<sub>2</sub>.

#### Post-procedure management

The patient was transferred to the paediatric ICU, and a chest X ray was performed for any evidence of pulmonary overflow. Those patients who were mechanically ventilated pre-procedure were extubated the next day. Heparin infusion was continued and replaced with Aspirin (3–5 mg/kg) once the child started to take orally and the aspirin was continued till the complete repair.

Outcome analysis and complications: The following outcomes and complications were analysed:

- The primary outcome was percentage increase in Spo<sub>2</sub>
- Gradient across the right ventricular outflow tract stent
- Length of ICU and hospital stay
- Stent embolisation
- Local vascular complications
- Mortality

#### Statistical analysis

Descriptive statistics for categorical variables were reported as frequency and percentage, whereas continuous variables were reported as mean and standard deviations. Paired *t*-test was used to compare the Spo<sub>2</sub> before and after the right ventricular outflow tract stenting procedure. A *p* value of <0.05 was taken as significant.

#### Results

In this study, a total of 38 tetralogy of Fallot patients underwent palliative stenting of the right ventricular outflow tract from 2018 to 2022 and were above one year of age. Table 1 shows patient demographics.

#### Indications for right ventricular outflow tract stenting

Table 2 describes the various indications for which right ventricular outflow tract stenting was done. Most common indication for palliative right ventricular outflow tract stenting was presence of unfavourable anatomy as seen in 27 (71%)

**Table 1.** Table showing patient demographics

	Number (%)
Total number of patients	38 (100 %)
Male	26 (68.4 %)
Female	12 (31.5 %)
Age (mean $\pm$ SD)	4.82 $\pm$ 3.5 (1.5–13)
Weight (mean $\pm$ SD) Kg	13.10 $\pm$ 7.0 (5.6–34)
Height (mean $\pm$ SD) cm	96.40 $\pm$ 23.2 (67–150)
BSA (mean $\pm$ SD) m <sup>2</sup>	0.57 $\pm$ 0.20 (0.34 –1.14)

**Table 2.** Indication for right ventricular outflow tract stenting

Indication	Number (%)
<b>Cyanotic spells</b>	14 (36.8)
<b>Unfavourable anatomy</b>	
Mc Goon score <1.5	27 (71)
Nakata Index <150 mm/m <sup>2</sup>	24 (63.1)
Branch PA z score < -2	24 (63.1)
PA annulus z score < -2	26 (68.4)
<b>Extra cardiac causes</b>	
Kyphoscoliosis	1(2)
Brain Abscess	2(5)
Haemoptysis	2(5)

**Table 3.** Table showing pulmonary arteries (PA) anatomy

Parameter	Number (%)
RPA z score	-0.40 $\pm$ 1.30 (-3.4- +2.8)
LPA z score	-0.31 $\pm$ 1.37 (-3.2- +3.4)
PA annulus z score	-2.70 $\pm$ 0.95 (-4.7- -0.3)
Mc Goon ratio	1.40 $\pm$ 0.29 (0.80–2.1)
Nakata Index (mm/m <sup>2</sup> )	143.18 $\pm$ 57.11 (63–284)

patients. The second most common indication was the presence of refractory spells seen in 14 (36.8%) patients. One patient underwent re-stenting of the right ventricular outflow tract and one needed additional stenting of the left pulmonary artery. Analysis of pulmonary artery anatomy revealed that z score of pulmonary arteries annulus was lesser as shown in Table 3.

### Right ventricular outflow tract stenting procedure

#### Outcome analysis and complications

The primary outcome measured was an increase in saturation post-procedure, which was 36.97  $\pm$  19.75%. There was a statistically significant increase in the mean SpO<sub>2</sub> levels from baseline with a *p* value of <0.01. Table 5 shows the various outcomes analysed and complications seen in this study. Stent embolisation was seen in one patient which was removed surgically. Two

**Table 4.** Shows the procedure-related hardware, techniques, and fluoroscopy time

	Number (%)
<b>Type of sheath used</b>	
Long sheath	23 (60.5)
Guiding catheter	6 (15.8)
None	9 (23.6)
<b>Wire used</b>	
0.014	24 (63.1)
0.035	14 (36.8)
<b>Angiographic view used for stent deployment</b>	
RAO30	16 (42.1)
LAO30/cranial30	22 (57.8)
<b>Transthoracic Echo assistance</b>	38 (100)
<b>Annulus sparing stent</b>	9 (23.6%)
<b>Fluoroscopy time (mean <math>\pm</math> SD) minutes</b>	35.96 $\pm$ 23.9 (8.4–88.9)

**Table 5.** Table showing outcome and complications

Parameter	Mean $\pm$ SD (range/%)
Pre procedure SpO <sub>2</sub> (%)	53.90 $\pm$ 18.56 (19–79)
Post procedure SpO <sub>2</sub> (%)	94.89 $\pm$ 4.83 (79–100)
Percentage increase in SpO <sub>2</sub>	36.97 $\pm$ 19.75 (6–75)
RVOT gradient (mean $\pm$ SD) mmHg	49.76 $\pm$ 11.2 (30–72)
Length of ICU stay (hours)	26.18 $\pm$ 23.7 (16–132)
Length of hospital stay (hours)	51.45 $\pm$ 42.9 (48–240)
Need of mechanical ventilation	2 (5.2%)
Stent embolisation	1 (2.6%)
Overflow	2 (5.2%)
Local vascular complications	7 (18.4%)
Mortality	0

patients developed features of pulmonary oedema and needed prolonged ventilatory support. Local vascular complications in the form of loss of femoral arterial pulse were seen in nine (25.7%) patients, which was managed by heparin infusion. There was no mortality seen in this study group.

### Discussion

Transcatheter management of CHD has achieved great success in the last decade. Right ventricular outflow tract stenting is one such achievement done as a palliation in children with tetralogy of Fallot not suitable for complete repair. The decision regarding the type of palliation also depends on the experience of the team with regards to right ventricular outflow tract stenting and the outcomes of palliative shunt procedure, especially in infants.

In this study, 38 patients of tetralogy of Fallot above the age of one year underwent right ventricular outflow tract stenting procedure. This amounts to 72% of our total right ventricular outflow tract stenting cohort (out of the total 52 patients). This



high percentage is expected, as in a low- and middle-income country patients with tetralogy of Fallot commonly sometimes present for the first time during childhood, adolescence, or even late adulthood.<sup>6</sup> These patients usually come to attention due to some complication like cyanotic spell, brain abscess, thrombotic stroke, or haemoptysis. In this study, we summarise our experience of right ventricular outflow tract stenting in patients with tetralogy of Fallot beyond one year of age.

The most common indication for right ventricular outflow tract stenting was unfavourable pulmonary anatomy, and the next most common indication was refractory spells. In a meta-analysis, cyanotic spells and low birth weight were the most common indications for right ventricular outflow tract stenting,<sup>7</sup> but the focus of study was children less than one year of age.

Two patients with brain abscesses underwent urgent right ventricular outflow tract stenting as they were having worsening cyanosis (spell), and waiting for the patients to be sterile before sending for complete repair could prove to be detrimental. We encountered one patient with severe kyphoscoliosis and very low baseline saturation. Corrective surgery for kyphoscoliosis was not possible at such low saturation levels so we decided to do right ventricular outflow tract stenting.

The right ventricular outflow tract stenting procedure has evolved over the last decade and has been well described by Stumper et al.<sup>5</sup> In our experience, it is always safer to perform the right ventricular outflow tract stenting procedure under general anaesthesia, especially in children who have spells. This is beneficial, especially when crossing the right ventricular outflow tract with the hard wire or long sheath can obstruct the right ventricular outflow tract and lead to desaturation. Also, one must ensure that the necessary hardware is available, including various ranges of bare metal stents, exchange length hard wires, and even Glide catheters (when Judkins right catheter doesn't cross the right ventricular outflow tract). We have observed that passing the hard wire across the right ventricular outflow tract, especially in younger children, can obstruct the right ventricular outflow tract and lead to desaturation and bradycardia. In such a scenario, it is advisable to use a coronary stent, which requires a lower profile 0.014 wire for deployment. In all cases, it is better to cross the right ventricular outflow tract with a 0.014 coronary wire. Then depending on the type of stent used, it can be exchanged with a hard wire using a diagnostic or Glide catheter. In some cases, where catheter cannot be crossed across the right ventricular outflow tract, pre-balloon dilatation of the right ventricular outflow tract can facilitate smooth delivery of the catheter. The key to the success of right ventricular outflow tract stenting is appropriate imaging of the right ventricular outflow tract, so as to decide about the size of the stent and where to deploy it. Echocardiographic measurement and guidance for deployment appear to be more accurate.

Use of a long sheath or guide catheter (depending on the type of stent used, as described above) is preferred so that check angiograms can be done before and after deploying the stent. Long sheaths are also beneficial as they protect the hard wire, allow smooth stent delivery, and make balloon retrieval easier.<sup>5</sup> Once an exchange length hard wire has been crossed across the right ventricular outflow tract, then passing the long sheath becomes easy and it is parked in the right ventricular inflow. A guide catheter functions similarly to a long sheath when a coronary stent is used. We have observed that the major issue with using long sheaths/guide catheters is that they can lead to loss of wire position. In such cases, deploying with just the wire can be tried. This

method was also described by Linnane et al,<sup>8</sup> where they avoided the long sheath, and used angled Glide catheter to facilitate placement of the guidewire in the branch pulmonary arteries. In our study, nine (23.6%) patients underwent right ventricular outflow tract stenting without any support. In this method, extra support to the wire can be provided by making a loop in the right atrium as shown in Figure 2b).

The type of stent used is also an important factor in the success of this procedure. Due to the narrow infundibular area, manoeuvring the stent is not easy, leading to loss of wire position in certain cases. Use of low-profile stents, like the coronary stent, makes our life easier and can reduce the procedure time. In our experience, one drawback of using coronary stents in children beyond one year of age is that it provides a very short-term palliation.

One must always try to spare the pulmonary annulus so as to avoid transannular patches during complete repair. But in patients with a hypoplastic Main Pulmonary Artery (MPA) and pulmonary arteries annulus, deploying the stent across the pulmonary arteries annulus becomes a necessary evil. In this study, 39 (75%) patients had a hypoplastic pulmonary arteries annulus and had stent deployed across the pulmonary arteries annulus.

Re-stenting of the right ventricular outflow tract was done in one patient in our study. In previous studies, it was shown that the most common location for in-stent stenosis after right ventricular outflow tract stenting was the proximal end near the infundibular area.<sup>3,9</sup> In a study by Quant D et al., the incidence of re-intervention was 37.5%. It is seen that due to constant pressure of the infundibular muscle, there is loss of stent integrity, especially in coronary stents.<sup>10</sup> Thus, post right ventricular outflow tract stenting, these patients need a regular follow up and early complete repair.

In this study, immediate outcomes were also analysed. The primary outcome analysed was percentage increase in *Sop2* levels. We saw a statistically significant increase in the saturation levels post-deployment ( $p < 0.001$ ). The increase in *Spo2* levels indicates successful right ventricular outflow tract stenting, and if the increase in saturation is not satisfactory, we need to reassess the position of the stent and patients' ventilation. In our series, we had one patient who underwent right ventricular outflow tract stenting in view of hypoplastic Left Pulmonary Artery (LPA). Increase in *Spo2* after right ventricular outflow tract stenting was not satisfactory, so it was decided to stent the LPA, after which, the *Spo2* increased to 90%.

Right ventricular outflow tract stenting like any other interventional procedure is not free from complications. This can be in the form of stent embolisation, pulmonary oedema (as seen in Blalock-Taussig shunt), balloon rupture, dissection, arrhythmias, bradycardia and hypotension, tricuspid valve regurgitation, and local vascular complications.<sup>11</sup> Local vascular complication in the form of temporary loss of lower limb arterial pulse was seen in seven patients (18.4%), which was managed with heparin infusion. None of the patients needed embolectomy. Stent embolisation was seen in one (2.6%) of patients, which embolised into the right ventricular body, and was removed surgically. This complication can be prevented by proper imaging (preferably echocardiography) just before deploying the stent. Pulmonary oedema was seen in two patients (5.2%) who needed prolonged ventilatory support. We have observed that a peak gradient of at least 40 mm Hg across right ventricular outflow tract post-stenting protects against pulmonary oedema. Even then, we must have a

high index of suspicion, especially in infants and watch for features of pulmonary oedema (high airway pressures, cardiomegaly and pulmonary venous congestion on chest X ray, pulmonary bleed, etc.). There was no mortality in our series and all of the patients were discharged in satisfactory condition on oral aspirin.

### Limitations

This study was a retrospective observational analysis. The outcomes were not compared with patients who underwent Blalock-Taussig shunt surgery.

### Conclusion

Our series has shown that right ventricular outflow tract stenting in children beyond one year of age is technically feasible, with good immediate outcome, especially in those who present with any complication, thus reducing the perioperative morbidity and mortality. Appropriate pre-procedure planning, presence of necessary hardware, and echocardiographic imaging during the procedure are the key to its success. The following are our recommendations for a successful right ventricular outflow tract stenting:

- Crossing the right ventricular outflow tract initially with a coronary wire.
- Pre-balloon dilatation if the catheter for exchanging with the hard wire cannot cross the right ventricular outflow tract or using a buddy wire.
- The hard wire can be looped in the right atrium to provide support for stent deployment without sheath/catheter support.
- Echocardiographic guidance for stent deployment.
- Use of stents which have a low profile and are supported by 0.014 wire, like the coronary stents or biliary stents.
- Post-procedure monitoring for pulmonary over circulation.

### References

1. Gladman G, McCrindle BW, Williams WG, Freedom RM, Benson LN. The modified Blalock-Taussig shunt: clinical impact and morbidity in Fallot's tetralogy in the current era. *J Thorac Cardiovasc Surg* 1997; 114: 25–30.
2. Petrucci O, O'Brien SM, Jacobs ML, Jacobs JP, Manning PB, Eghtesady P. Risk factors for mortality and morbidity after the neonatal Blalock-Taussig shunt procedure. *Ann Thorac Surg* 2011; 92: 642–651.
3. Sandoval JP, Chaturvedi RR, Benson L et al. Right ventricular outflow tract stenting in tetralogy of Fallot infants with risk factors for early primary repair. *Circ Cardiovasc Interv* 2016; 9: e003979. DOI: [10.1161/CIRCINTERVENTIONS.116.003979](https://doi.org/10.1161/CIRCINTERVENTIONS.116.003979).
4. Dohlen G, Chaturvedi RR, Benson LN et al. Stenting of the right ventricular outflow tract in the symptomatic infant with tetralogy of Fallot. *Heart* 2009; 95: 142–147. DOI: [10.1136/hrt.2007.135723](https://doi.org/10.1136/hrt.2007.135723).
5. Quandt D, Penford G, Ramchandani B, Bhole V, Mehta C, Stumper O. Stenting of the right ventricular outflow tract as primary palliation for Fallot-type lesions. *J Congenit Cardiol* 2017; 1: 3.
6. Iyer PU, Moreno GE, Caneo LF, Faiz T, Shekerdemian LS, Iyer KS. Management of late presentation congenital heart disease. *Cardiol Young* 2017; 27: S31–9.
7. Laurentius A, Wiyono L, Subali AD, Siagian SN. Evaluation of right ventricular outflow tract stenting as palliative treatment in severely cyanotic Tetralogy of Fallot: a systematic review and meta-analysis of observational studies. *J Tehran Univ Heart Center* 2021; 16: 135–146.
8. Linnane N, Nasef MA, McMahon CJ et al. Right ventricular outflow tract stenting in symptomatic infants without the use of a long delivery sheath. *Catheter Cardiovasc Interv* 2021; 98: E275–E281.
9. Prabhu S, Mehra S, Kanaparthi S, Maiya SS, Rao S. Right ventricular outflow tract histology post-stenting and in-stent stenosis. *Ann Pediatr Cardiol* 2022; 15: 206–208.
10. McElhinney DB, Cheatham JP, Jones TK et al. Stent fracture, valve dysfunction, and right ventricular outflow tract reintervention after transcatheter pulmonary valve implantation: patient-related and procedural risk factors in the US melody valve trial. *Circ Cardiovasc Interv* 2011; 4: 602–614.
11. Abqari S. Right Ventricular Outflow Tract Stenting. *Congenital Heart Defects: Recent Advances*, 2022, 187.