

# Neuroimaging Highlight

Editors: William Hu, Mark Hudon

## Accidental Hydrogen Peroxide Ingestion

Submitted by: S. Furtado, S. Jodoin, W. Hu, R. Sevick

Can. J. Neurol. Sci. 2001; 29: 276-277

A 78-year-old gentleman was found by his son approximately one hour after accidental ingestion of 30-50 ml of 35% hydrogen peroxide; this was taken in error instead of intended gastrograffin in preparation for abdominal CT. The patient was confused, vomiting and was rushed to hospital.

Examination by ICU staff at the time of admission disclosed a fluctuating level of consciousness. Initial examination by the consulting neurologist the day following ingestion showed stupor, a left sixth nerve palsy, absence of left sided movement and bilateral Babinskis. MRI at this point showed multiple foci of restricted diffusion and abnormal T2 signal throughout the anterior and posterior circulations including the right occipital lobe as well as multiple foci in the parietal lobes, right greater than left (Figures 1,2,3). After discussion with the family, level 3 care was instituted (no code, comfort measures only).

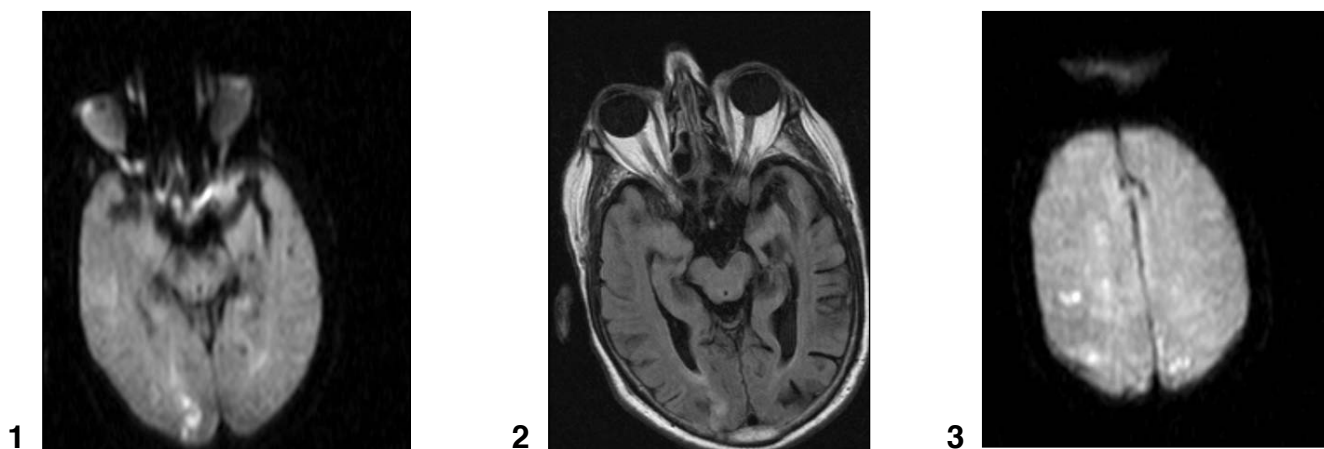
However, by the next day, the patient demonstrated dramatic improvement and re-examination by the neurology service five days after ingestion demonstrated a normal neurologic exam, including the patient's recall of solution ingestion. Investigations at this point showed normal carotid Doppler flow studies, normal cardiac ventricular function, moderate aortic regurgitation and

no evidence of an intracardiac shunt, although the echocardiographic study was described as limited. Repeat MRI 2 weeks later showed resolution of most of the previously described ischemic areas, including the right occipital focus (Figure 4).

The patient was discharged home from hospital.

Ingestion of hydrogen peroxide resulting in cerebral infarction has been described in the literature.<sup>1,2</sup> Typically, this ingestion is in error, but it is sometimes intentional for perceived health benefits.<sup>1</sup> The pediatric population is particularly vulnerable to accidental ingestion.<sup>3</sup> Multiple mechanisms of action have been proposed to account for cerebral infarction. These include hypoxemia as a result of bronchospasm or pulmonary aspiration produced by direct ingestion; undissociated hydrogen peroxide may undergo dissociation in the venous system and right heart with resultant embolization across an existing right to left shunt; the hydrogen peroxide may undergo catalysis only in the arterial supply, then producing embolization. This is similar to iatrogenic air embolism during invasive procedures (ie, arch angiography).<sup>4</sup>

Recovery in case descriptions reported is variable, ranging

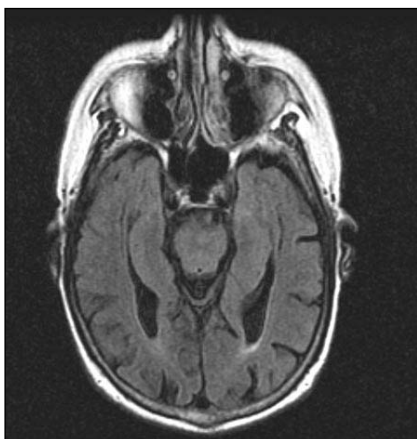


**Figures 1,2,3:** MR imaging in the day following ingestion shows restricted diffusion (DWI, figure 1) and associated T2-weight hyperintensity (FLAIR, figure 2) in the right occipital lobe as well as accompanying ischemic foci in the parietal lobes (DWI, figure 3)

From the Department of Clinical Neurosciences, University of Calgary, Calgary, AB Canada.

RECEIVED JUNE 12, 2002. ACCEPTED IN FINAL FORM JUNE 17, 2002.

Reprint requests to: S. Furtado, Area 3, 3350 Hospital Drive, NW, Calgary, Alberta T2N 4N1 Canada



**Figure 4:** Repeat FLAIR imaging after clinical recovery shows resolution of the right occipital lobe ischemic focus.

from death to residual deficits, with improved outcome following hyperbaric oxygen therapy.<sup>5</sup> Given outcome in described case reports, our patient has shown an excellent course.

#### REFERENCES

1. Sherman SJ, Boyer V, Sibley WA. Cerebral infarction immediately after ingestion of hydrogen peroxide solution. *Stroke* 1994; 25: 1065-1067.
2. Ijichi T, Itoh T, Sakai R, et al. Multiple brain gas embolism after ingestion of concentrated hydrogen peroxide. *Neurology* 1997; 48: 277-279.
3. Dickson KF, Caravati EM. Hydrogen peroxide exposure— 325 exposures reported to a regional poison control center. *J Toxicol Clin Toxicol* 1984; 32: 705-714.
4. Catron PW, Dutka AJ, Biondi DM, et al. Cerebral air embolism treated by pressure and hyperbaric oxygen. *Neurology* 1991; 41: 314-315.
5. Mullins ME, Beltran JT. Acute cerebral gas embolism from hydrogen peroxide ingestion successfully treated with hyperbaric oxygen. *J Toxicol Clin Toxicol* 1998; 36: 253-256.