

Main Article

Dr H Samuel takes responsibility for the integrity of the content of the paper

Cite this article: Samuel H, Lepcha A, Philip A, John M, Augustine A. A cadaveric temporal bone study of the anatomical landmarks for middle turn cochleostomy. *J Laryngol Otol* 2023;**137**:769–774. <https://doi.org/10.1017/S0022215123000026>

Accepted: 6 December 2022
First published online: 23 January 2023

Key words:

Cochlear Implant; Scala Tympani; Labyrinthitis

Author for correspondence:

Dr H Samuel, ENT-4 Office, Rm 304, Op block, CMC Hospital, Ida Scudder Road, Vellore, Tamilnadu 632004, India
E-mail: habiethomas@hotmail.com

Abstract

Objective. This study aimed to determine anatomical landmarks for accurate and safe middle turn cochleostomy on cadaveric temporal bones.

Methods. In 17 cadaveric wet adult temporal bones, cortical mastoidectomy was performed, followed by extended posterior tympanotomy through which a middle turn opening was created anterior to the stapes footplate. Micro-measurements of various lengths were taken from the cochleostomy to normal middle-ear anatomical landmarks using a digital microscope.

Results. The mean length from the middle turn cochleostomy to the processus cochleariformis was 1.8 ± 0.3 mm and to the tympanic segment of the facial nerve was 2.2 ± 0.3 mm. The mean shortest length from the oval window to the osseous spiral lamina was 2.4 ± 0.3 mm and to the internal carotid artery was 5.0 ± 0.6 mm. The mean shortest length from the round window to the internal carotid artery was 4.3 ± 0.6 mm.

Conclusion. A middle turn cochleostomy can be safely drilled by using the measured lengths in difficult cases.

Introduction

Labyrinthitis ossificans is a pathological condition wherein ossification of the cochlear lumen occurs as a result of varying aetiology. This makes cochlear implant electrode insertion difficult for the operating surgeon if the round window or the basal turn is obstructed with bone. The first option would be to drill further into the proximal basal turn from the round window until a definite lumen is visualised. If this is not successful, an alternative technique is anterograde or retrograde double array insertion, first described independently by Lenarz *et al.* and Bredberg *et al.* in 1997, which takes advantage of a second opening or cochleostomy created into the middle turn of the cochlea.^{1,2} This may be the only option when resistance is encountered to passage of the electrode beyond 7–8 mm of the round window. The current existing guideline for middle turn cochleostomy is to drill a few millimetres anterior to the oval window. Cochlear drilling using a single landmark may result in complications like osseous spiral lamina trauma, scala vestibuli insertion or internal carotid artery injury. To date, there has been no accurate description of surgical landmarks for middle turn cochleostomy in the medical literature. This study aims to describe the anatomical landmarks and guidelines for a middle turn cochleostomy so as to ensure electrode insertion into the scala tympani of the middle turn of the cochlea.

Materials and methods

A descriptive cadaveric study was conducted in the temporal bone dissection laboratory of the ENT department of a tertiary medical college hospital. Seventeen wet cadaveric normal adult temporal bones were acquired from the department of anatomy, and the study was started after approval by the institutional review board and ethics committee (approval number: 11109).

The study was conducted over one year from July 2018 to July 2019. In each of the formalin-preserved temporal bones, cortical mastoidectomy followed by posterior tympanotomy was carried out using a surgical microscope. Once adequate exposure of the round window and stapedial tendon was achieved through the facial recess, the incus buttress was drilled off for an extended facial recess approach as shown in [Figure 1](#).

The malleus, incus and stapes suprastructure were then dislocated and removed for better exposure of the promontory. The stapes footplate was left intact in most of the bones after cutting the stapedial tendon and removing the firm, cadaveric stapes suprastructure with micro-scissors. A middle turn fenestra was then drilled with a 1-mm diamond burr, commencing at a point 2 mm anterior to the oval window. This measurement was taken using a calibrated piece of paper scale as shown in [Figure 2](#).

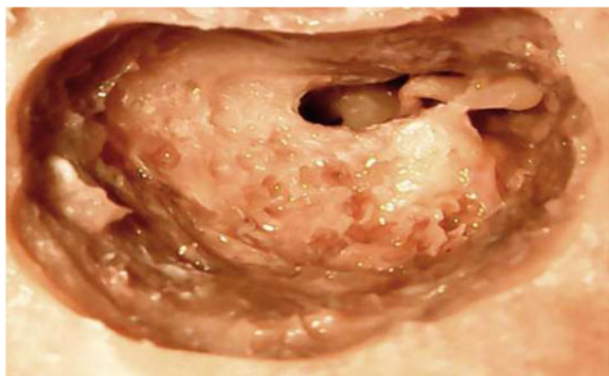


Fig. 1. Extended posterior tympanotomy (left side).

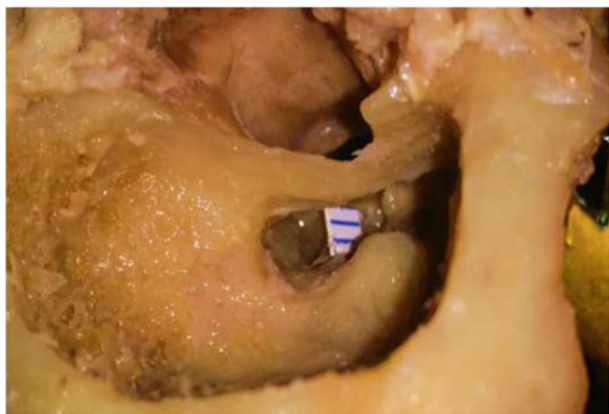


Fig. 2. Middle turn cochleostomy performed 2 mm anterior to stapes footplate (left side).

An electrode gauge (Cochlear, Sydney, Australia) was then passed into the cochleostomy opening to confirm the lumen patency (Figure 3a and b). Cochlear turns were next outlined by drilling out the cochlear lateral walls for a complete drillout (Figure 4 and 5). Then, the electrode placement within the compartments of the middle turn was checked. Once it was confirmed to be within the scala tympani of the middle turn, measurements were taken from various fixed middle-ear landmarks to the middle turn cochleostomy with the help of the handheld camera of a digital microscope, which had previously been used for temporal bone micro-distance measurements.³ The various parameters measured included the length from the processus cochleariformis to the middle turn cochleostomy, the length from the proximal portion of the tympanic segment of the facial nerve canal to the middle turn cochleostomy, the shortest length from the anterior edge of the oval window to the osseous spiral lamina of the middle turn, and the shortest lengths from the anterior edge of the oval and round windows to the petrous internal carotid artery.

Statistical analysis

Quantitative variables were summarised using mean and standard deviation. Categorical variables were summarised using counts and percentages. Mean lengths were presented with 95 per cent confidence intervals. The intraclass correlation co-efficient was calculated for various measured parameters, and inter-observer variability was checked between the values of two authors (HS and AP). Reliability was

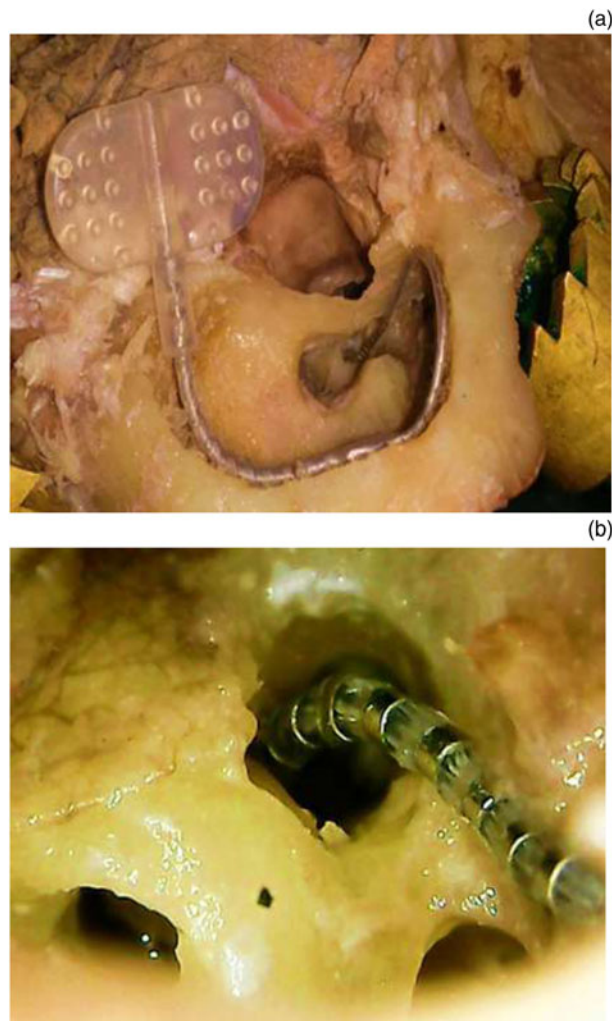


Fig. 3. (a) Electrode gauge inserted through the middle turn cochleostomy. (b) Close up view of the electrode gauge inserted through the middle turn cochleostomy.

interpreted as follows: intraclass correlation co-efficient less than 0.5, poor; between 0.5 and less than 0.75, moderate; between 0.75 and 0.9, good; and more than 0.9, excellent.⁴

Results

Out of the 17 temporal bones, 11 were on the left side and 6 were on the right side. The inter-observer reproducibility of the measured parameters was acceptable, as shown in Table 1. The distance between the processus cochleariformis and middle turn cochleostomy ranged from 1.3 to 2.4 mm, with a mean length of 1.8 ± 0.3 mm (Figure 6). Drilling inferiorly beyond 1.8 mm caused wrong opening into the scala vestibuli of the basal turn of cochlea in 12 bones (71 per cent). The mean oblique length from the most proximal part of the tympanic segment of facial nerve to the middle turn cochleostomy was 2.2 ± 0.4 mm (Figure 6).

The mean length from the anterior edge of the oval window to the osseous spiral lamina of the middle turn was 2.4 ± 0.2 mm (Figure 7), and the shortest length from the oval window to the osseous spiral lamina was just 1.8 mm. The shortest length from the oval window to the petrous internal carotid artery was 5.0 ± 0.6 mm, and the shortest length from the round window to the internal carotid artery was 4.3 ± 0.6 mm (Figure 8). The ideal direction of drilling of the middle turn cochleostomy was from posterior to anterior along a

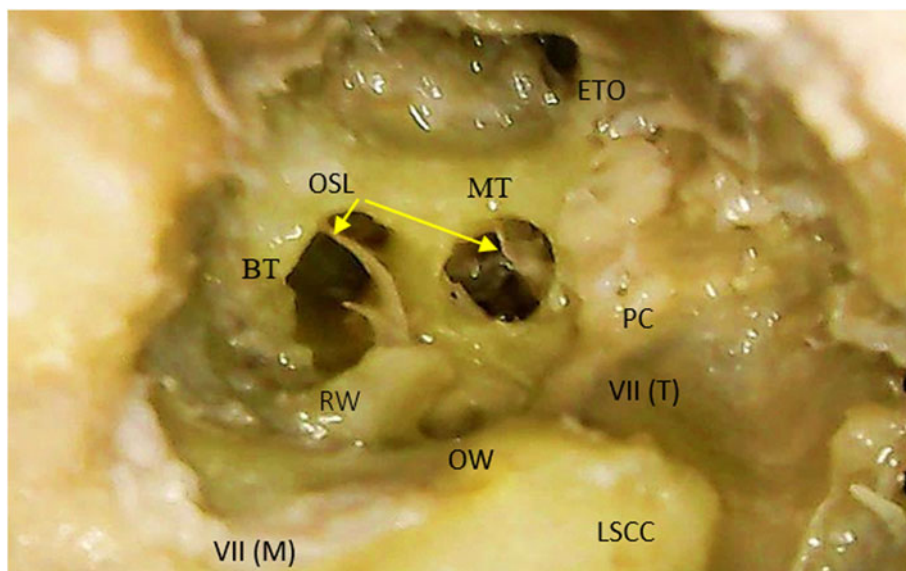


Fig. 4. Cochlear drillout exposing basal and middle turns of left cochlea. ETO = Eustachian tube opening; OSL = osseous spiral lamina; MT = middle turn; BT = basal turn; PC = processus cochleariformis; RW = round window niche partially drilled; VII (T) = tympanic segment of facial nerve; OW = oval window; VII (M) = mastoid segment of facial nerve; LSCC = lateral semi-circular canal

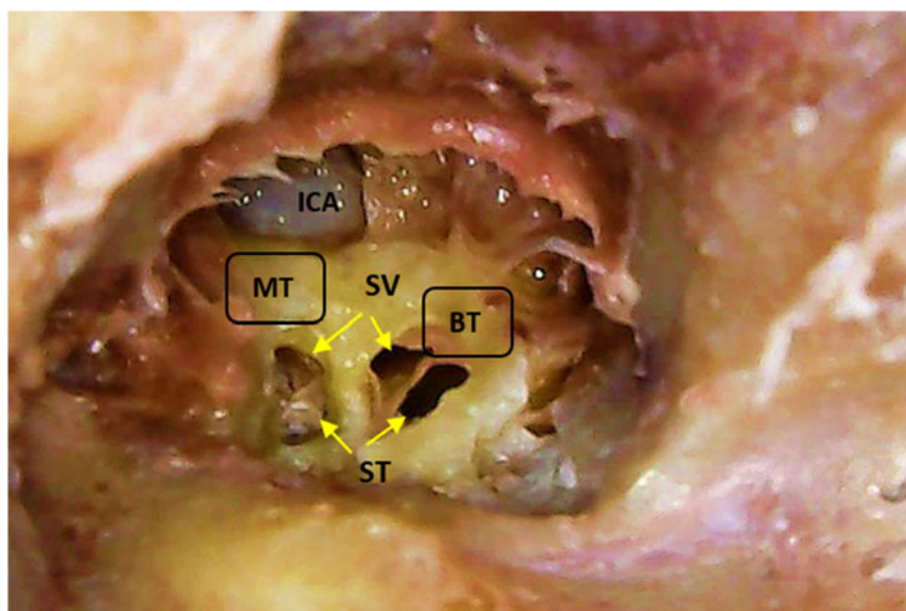


Fig. 5. Cochlear dissection of right cochlea showing the compartments (scala vestibuli (SV), scala tympani (ST)) within the basal and middle turns (BT and MT) of cochlea along with exposed internal carotid artery (ICA).

Table 1. Intraclass correlation between two raters or observers

Parameter	Intraclass correlation
PC-MTC	0.95 (0.62, 0.99)
VII-MTC	0.97 (0.92, 0.99)
OW-OSL	0.87 (0.65, 0.95)
OW-ICA	0.98 (0.97, 0.99)
RW-ICA	0.99 (0.98, 0.99)

PC = processus cochleariformis; MTC = middle turn cochleostomy; VII = tympanic segment of the facial nerve; OW = oval window; OSL = osseous spiral lamina; ICA = internal carotid artery; RW = round window

linear line between the oval window and the Eustachian tube orifice, parallel to the tensor tympani.

In most of the temporal bones (10 of 17), safe entry into the scala tympani of the middle turn of the cochlea could be achieved via the postero-inferior quadrant of the point of intersection between these two arbitrary lines (Figure 9): a line from the oval window to the Eustachian tube orifice and

a line from the processus cochleariformis towards the hypotympanum at the 6 o'clock position.

Discussion

Cochlear implantation in ossified labyrinths poses a challenge even in the best surgical hands. In most cases of labyrinthitis ossificans, ossification of the basal turn occurs because the disease originates from around the round window, probably because the opening of the cochlear aqueduct into the basal turn is close to the round window.⁵ In advanced stages of such ossification, it is difficult both to find a cochlear lumen within the basal turn upon drilling along the round window niche and to achieve adequate electrode insertion even if a lumen is found. The basis for a middle turn cochleostomy in the case of labyrinthitis ossificans is that the spiral ganglion population in the middle turn and apical turn is likely to be functionally better than in the most affected basal turn. This technique has been proven to show improved results with regard to post-operative auditory outcomes as well.⁶ Bredberg *et al.*¹ described drilling of a middle turn

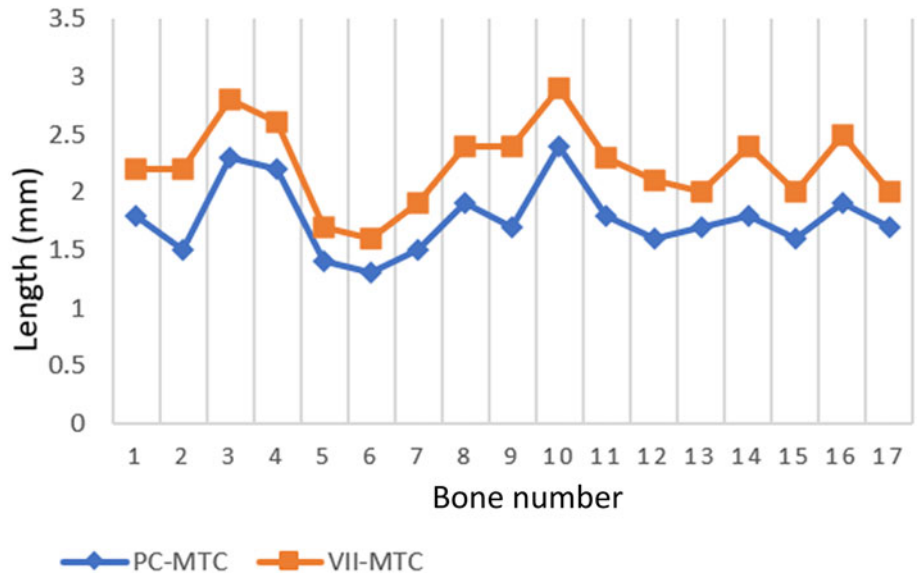


Fig. 6. Mean length between the middle turn cochleostomy to the processus cochleariformis and tympanic segment of facial nerve. PC=processus cochleariformis; MTC = middle turn cochleostomy; VII = tympanic segment of the facial nerve

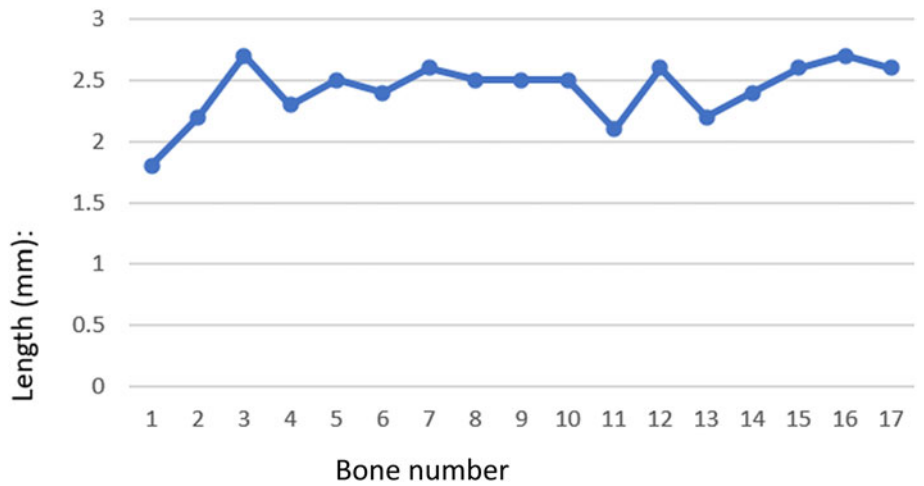


Fig. 7. Mean length from the middle turn cochleostomy to the osseous spiral lamina of the middle turn.

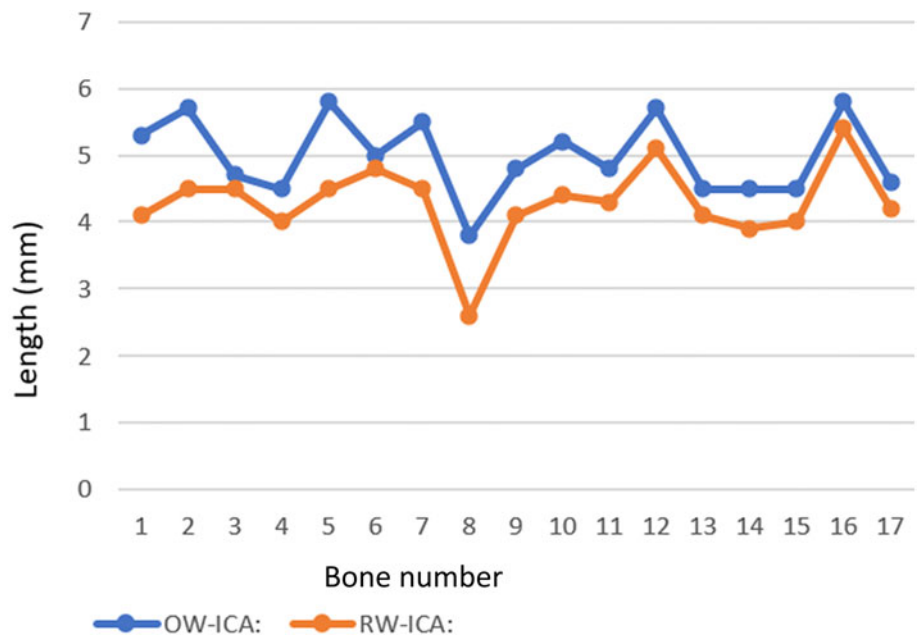


Fig. 8. Mean length from the oval window (OW) and round window (RW) to the internal carotid artery (ICA).

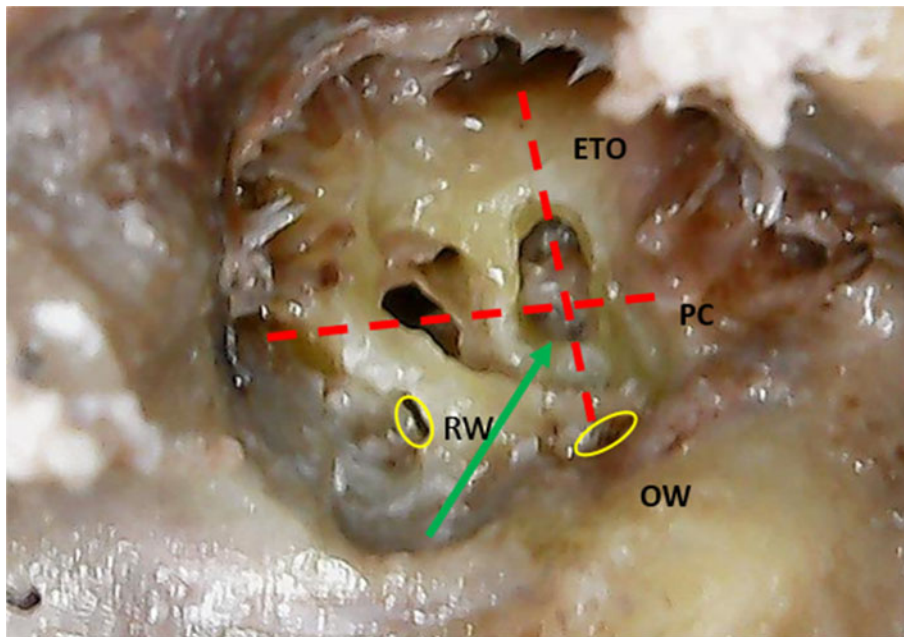


Fig. 9. Safe entry point into the middle turn of left cochlea marked by the green arrow. ETO = Eustachian tube opening; PC = processus cochleariformis; RW = round window; OW = oval window

cochleostomy superior to the oval window in a direction parallel to the tympanic facial nerve, whereas Lenarz *et al.*² advocated drilling 2–3 mm anterior to the oval window below the tensor tympani canal. Drilling parallel to the tympanic segment of the facial nerve would mean entering the middle turn almost perpendicularly onto the osseous spiral lamina, whereas drilling in a direction between the oval window and the Eustachian tube orifice, as in this study, ensures that the drill bit is parallel to the osseous spiral lamina within the middle turn, hence minimising the risk of injury.

Moreover, drilling postero-superior to the actual middle turn just at the anterior border of the oval window might risk injury to the labyrinthine segment of the facial nerve because it runs in a lateral to medial direction towards the fundus of the internal auditory canal. The nerve lies within the triangle bounded by the geniculate ganglion antero-superiorly, the middle turn antero-inferiorly and the apex formed by the spherical recess of the vestibule.⁷ Drilling the middle turn cochleostomy less than 2 mm from the oval window might cause an entry into the pars descendens of the basal turn itself. If the opening is created inferiorly, wrong entry into the scala vestibuli of the basal turn is also possible. We achieved an entry into the middle turn in all bones at a length of 2 mm anterior to the oval window. In the study by Isaacson *et al.* as well, entry into the middle turn was achieved in 8 out of 10 bones at a mean length of 2 mm from the stapes footplate.⁸ On drilling beyond a mean length of 2.4 mm anteriorly from the oval window, it was observed that damage to the osseous spiral lamina attachment to the lateral wall of the middle turn was inevitable. Keeping this length as a safety margin in mind and drilling parallel to the direction of the spiral lamina would actually be crucial for hearing preservation in these difficult cases. The ideal electrode insertion site has been demonstrated to be into the scala tympani, as it is more robust and closer to the nerve cells, and such an insertion ensures minimal intra-cochlear structural damage, good hearing outcomes and less post-operative vertigo.^{9,10,11} The safe point for entry into the middle turn, as shown in Figure 9, can guide electrode insertion into the scala tympani compartment of the middle turn.

In a study on 20 cadaveric temporal bones, it was inferred that the tunnel for the middle turn should be created at an

angle of about 134 degrees in relation to the tympanic segment of the facial nerve.¹² We believe that intra-operatively, in view of the magnified working surgical field, it is easier and more accurate to find landmarks to a point with linear measurements rather than angles. The mean length from the inferior surface of the cochlear basal turn to the junction between the petrous carotid artery and the jugular bulb was 8 mm in the study by Liu *et al.*¹³ In this study, we measured the shortest mean distance between the round window and the internal carotid artery to be 4.3 mm, which was comparable to another cadaveric study in which this length ranged from 2.79 to 5.34 mm.¹⁴ This would be the shortest length for drilling from the basal turn, especially in cases of ossified cochlea, beyond which injury to the horizontal part of the internal carotid artery can be encountered. Similarly, the shortest mean length from the oval window to the internal carotid artery was found to be roughly 5 mm as measured in this study, which should be kept in mind as the anterior length limit while drilling the middle turn cochleostomy. As middle turn cochleostomies are performed in ossified cochlea, it is possible for the surgeon to overlook this length while attempting to find a lumen in difficult cases.

- Finding cochlear lumen for electrode insertion is a surgical challenge during cochlear implantation in labyrinthitis ossificans
- Middle turn cochleostomy involves entry into the middle turn of cochlea when the basal turn is completely ossified by disease
- Accurate middle turn cochleostomy and electrode placement is necessary for minimising intra-cochlear trauma and better cochlear implantation outcomes for ossified labyrinths

Conclusion

Knowledge of the surgical anatomy and landmarks for drilling a middle turn cochleostomy is essential for any neurotologist performing cochlear implantations in challenging cases. The mean length for safe entry into the scala tympani of the middle turn of the cochlea is between 2 mm and 2.4 mm from the anterior edge of the oval window and 1.8 mm from the processus cochleariformis. The angulation to drill should be in an antero-inferior direction along a line parallel to the

line drawn between the oval window and the Eustachian tube. The postero-inferior quadrant of the intersection of a line between the oval window and the Eustachian tube orifice with a line from the processus cochleariformis towards the hypotympanum at the 6 o'clock position is the safest entry to the scala tympani in middle turn cochleostomy.

Acknowledgements. The authors would like to acknowledge the department of anatomy for providing the cadaveric temporal bones necessary for the study and the institutional research and ethics board at Christian Medical College, Vellore, India for funding this study.

Competing interests. None declared

References

- Bredberg G, Lindström B, Löppönen H, Skarzynski H, Hyodo M, Sato H. Electrodes for ossified cochleas. *Am J Otol* 1997;**18**:42–3
- Lenarz T, Lesinski-Schiedat A, Weber BP, Issing PR, Frohne C, Büchner A *et al.* The nucleus double array cochlear implant: a new concept for the obliterated cochlea. *Otol Neurotol* 2001;**22**:24–32
- Samuel H T, Lepcha A, Philip A, John M, Augustine AM. Dimensions of the posterior tympanotomy and round window visibility through the facial recess: cadaveric temporal bone study using a novel digital microscope. *Indian J Otolaryngol Head Neck Surg* 2022;**74**:714–18
- Koo TK, Li MY. A Guideline of selecting and reporting intraclass correlation coefficients for reliability research. *J Chiropr Med* 2016;**15**:155–63
- Green JD, Marion MS, Hinojosa R. Labyrinthitis ossificans: histopathologic consideration for cochlear implantation. *Otolaryngol Head Neck Surg* 1991;**104**:320–6
- Lenarz T, Büchner A, Tasche C, Cristofoli T, Lesinski-Schiedat A, Wallenberg EV *et al.* The results in patients implanted with the nucleus double array cochlear implant: pitch discrimination and auditory performance. *Ear Hear* 2002;**23**:90–101
- Presutti L, Nogueira JF, Alicandri-Ciufelli M, Marchioni D. Beyond the middle ear: endoscopic surgical anatomy and approaches to inner ear and lateral skull base. *Otolaryngol Clin North Am* 2013;**46**:189–200
- Isaacson B, Roland PS, Wright CG. Anatomy of the middle-turn cochleostomy. *The Laryngoscope* 2008;**118**:2200–4
- Finley CC, Holden TA, Holden LK, Whiting BR, Chole RA, Neely GJ *et al.* Role of electrode placement as a contributor to variability in cochlear implant outcomes. *Otol Neurotol* 2008;**29**:920–8
- Aschendorff A, Kromeier J, Klenzner T, Laszig R. Quality control after insertion of the nucleus contour and contour advance electrode in adults. *Ear Hear* 2007;**28**:75–9
- Todt I, Basta D, Ernst A. Does the surgical approach in cochlear implantation influence the occurrence of postoperative vertigo? *Otolaryngol Head Neck Surg* 2008;**138**:8–12
- Leal M de C, Caldas Neto S da S. The anatomical orientation of the middle turn of the cochlea: importance during surgical implantation of the ossified cochlea. *Otol Neurotol* 2015;**36**:406–8
- Liu W, Lu Y, Laurell G, Cousins V. A morphometric study of the structures bordering the infra-cochlear corridor relevant for endoscopic/microscopic ear surgery. *J Otol* 2018;**13**:81–84
- Jain S, Gaurkar S, Deshmukh PT, Khatri M, Kalambe S, Lakhota P *et al.* Applied anatomy of round window and adjacent structures of tympanum related in cochlear implantation. *Braz J Otorhinolaryngol* 2019;**85**:435–46