

Short report

A symptom-based approach to treatment of psychosis in autism spectrum disorder*

Victoria Bell[†], Henry Dunne[†], Tharun Zacharia, Katrina Brooker and Sukhi Shergill

Summary

The optimal management of autism with psychosis remains unclear. This report describes a 22-year-old man with autism and psychosis who was referred to a tertiary-level specialist psychosis service, following a 6-year history of deterioration in mental health starting around the time of sitting GCSE examinations and an episode of bullying at school. We describe the individualised symptom-based approach that was effective in his treatment.

Declaration of interest

The authors declare no conflict of interest.

Copyright and usage

© The Royal College of Psychiatrists 2018. This is an Open Access article, distributed under the terms of the Creative Commons Attribution-NonCommercial-NoDerivatives licence (<http://creativecommons.org/licenses/by-nc-nd/4.0/>), which permits non-commercial re-use, distribution, and reproduction in any medium, provided the original work is unaltered and is properly cited. The written permission of Cambridge University Press must be obtained for commercial re-use or in order to create a derivative work.

Knowledge of both autism spectrum disorder (ASD) and psychosis has developed within spectrum constructs. Despite the long history of association between these disorders, there is often little clinician awareness of how to assess and treat psychosis when it coexists with ASD. This is partly due to the degree of overlap in clinical symptoms, and the fact that the disorders share many physical and genetic predisposing factors,¹ as well as a lack of standardised clinical tools specifically developed for use in comorbid cases.

ASD and psychosis have been conceptualised as neurodevelopmental disorders.² A recent review of cross-sectional and longitudinal studies highlighted the similarities between ASD and psychosis in terms of genetic, environmental and brain imaging research.³ Individuals demonstrate dysfunctional social interactions to various degrees in both disorders; similarities are evident in the lack of emotional reciprocity in ASD and blunted affect in psychosis, and the delay or lack of speech development in ASD parallels alogia in psychosis. The defining features of ASD, including impairments in attention, information processing, theory of mind (ToM), and executive functioning, are typically ancillary to psychosis.¹ Overall, negative symptoms of psychosis appear to share many features with ASD, while there is a paucity of research that explores positive symptoms in ASD. A key difficulty is that less than 2% of ASD research has been conducted with adults,⁴ and this has mostly focused on pre-adolescent children in whom it is less likely that psychotic phenomena are experienced. In one of the only identified full adult studies, albeit with a limitation of sampling, Raja and Azzoni conducted a retrospective review of all patients with ASD over a 15-year period and reported that 80% experienced delusions and 73% had hallucinations.⁵ It is plausible that social impairment and rigid thinking may leave individuals with ASD prone to a deficit in reality testing, while ToM difficulties could exacerbate paranoid thinking. There is some evidence that positive psychotic symptoms occur at an elevated rate in adolescent ASD samples.^{6,7} Anxiety and depression are also common in ASD, and are endorsed as significant factors in paranoid thinking, and with the emergence and persistence of psychosis.⁸

Given that ASD and psychosis are hypothesised to exist on a continuum, it is important to look beyond the diagnostic level

and investigate the co-occurrence of symptoms.⁹ The focus on clarifying the diagnosis may be based on clinician preference or a way of managing complexity, yet this may prove to be an obstacle in the advancement of the formulation and treatment of the difficult experiences for which patients require help. In this report, we add to the limited existing evidence of successfully treating psychosis with comorbid ASD by focusing on symptoms.

Case report

HP is a 22-year-old Caucasian male from the UK, who first presented to services at the age of 16 years. His parents first noticed there were problems in school when HP started to complain of vomiting and the sensation of a lump in his throat (globus pharyngis). Around this time, he was sitting his GCSE examinations. There was a lowering of mood and poor sleep, and weight loss was noted as he struggled to eat without vomiting immediately afterwards, which led to a 1-week admission to a general hospital for treatment of acute renal failure. Before the commencement of sixth form at school, HP disclosed to his parents that he had been bullied at school (a group of boys had made videos of him, including him being flash mobbed, which had been placed on YouTube; they had also made a persecutory Facebook page). His peers had made a banner saying he was a 'schizophrenic', and his parents reported that he then researched schizophrenia and told them this was what was wrong with him. Within the first month of restarting school he appeared sad, crying, inappropriately laughing at short intervals, and was noted to have both poor sleep and reduced appetite. His verbal communication reduced and he displayed abnormal posturing. In March 2012, after initial psychiatric assessment, he had a second 1-week admission to a general hospital because of dehydration with renal impairment secondary to food and fluid restriction. He subsequently had an in-patient admission to a Child and Adolescent Mental Health Services ward, for over a year, until June 2013. He was diagnosed with Asperger's syndrome, dissociative disorder, and a severe depressive episode with psychotic features. HP was discharged home for a year but became increasingly non-communicative and episodically aggressive toward his parents. He was transferred to our service in August 2014; his difficulties were noted to be unpredictable episodic physical aggression to staff/patients, tearfulness, staring blankly, incontinence of urine, regular episodes of vomiting, strikingly

* The original version of this article was published with the incorrect title. A notice detailing this has been published and the error rectified in the online PDF and HTML version.

[†] Authors should be acknowledged as joint first authors.

bizarre postural movements and elective mutism. At admission to our service he was taking venlafaxine 150 mg OD, quetiapine 100 mg mane and 150 mg nocte, and lorazepam 0.5–1 mg p.r.n.. Between 2011 and 2014 the clinical notes documented that HP had treatment trials of several antipsychotics (risperidone, aripiprazole, olanzapine, quetiapine) and several antidepressants (venlafaxine, fluoxetine, sertraline). Benzodiazepines (diazepam, lorazepam) had also been tried to manage anxiety and bizarre postural movements, with minimal improvement reported in case notes.

A developmental history was gained from his parents. There is no family history of physical or mental health problems. HP was born at full term with no complications during pregnancy or delivery. HP reportedly spoke single words by 24 months of age and simple phrases by 33 months. There was a delay in his development of expressive language; he found it difficult to form complex sentences with past, present and future tenses and complex grammatical constructions. Conversations lacked reciprocal communication and were reported as intellectual, pedantic and educational. He first walked unaided at 14 months and there were no delays in toilet training. In nursery he preferred to play on his own quietly, without imaginative play, rather than join in play. He did not appear to understand non-verbal behaviour and he did not show emotionally expressive gestures. He had one friend at primary school, and did not get invited to other children's houses at secondary school. He would not greet his parents after an absence, and he would generally ignore visitors. As a young child, he spent 'hours at a time' lining up objects such as Lego and stones in a particular order and intensely disliked tidying them away or change. He had strong interests in maps and numerical calculations. HP attended mainstream primary school from 5 to 11 years of age, followed by grammar school, achieving A/A*s at GCSEs. There is no reported history of illicit drugs or alcohol consumption and no forensic history. HP was not taking any medications for physical health.

Formulation

Given that HP was diagnosed with ASD in the context of stressful events at school, physical health problems and his first presentation of psychotic symptoms, we sought a second opinion from the National Autism Service (South London and Maudsley National Health Service Foundation Trust), where a diagnosis of 'high functioning' ASD was confirmed. Their assessment included the Autism Diagnostic Interview-Revised: 'Communication' score of 18, above the cut-off score of 8; 'Reciprocal Social Interaction' score of 21, above the cut-off score of 10; 'Repetitive Behaviours and Stereotyped Patterns of Interest' score of 4, above the cut-off score of 3.¹⁰

As a multi-professional team we discussed what might account for HP's significant and ongoing deterioration. First, organic disorder was considered, such as a rapid neuro-deteriorative state or low-grade encephalitis. However, magnetic resonance imaging (MRI) scans, electroencephalograms (EEGs), anti-NMDA antibodies, as well as B12, folate and thyroid function tests were repeatedly normal. Second, we considered the worsening of ASD symptoms; while undoubtedly individuals with ASD are more sensitive to the effects of psychosocial stressors, the severity of this case, the prolonged mutism, elements of catatonic behaviour, the lack of response on rescue from school environment yet progressive worsening did not provide a sole explanation. Thus a comorbid disorder was more likely, rather than just a very severe case of ASD. Third, it was suggested that HP was experiencing post-traumatic stress disorder following the bullying, and may have experienced dissociation, flashbacks and a strong physiological response when he encountered reminders of these events (internal or external). It is possible that HP was showing avoidance of any traumatic memories by trying not to think or talk about them. Episodes of

violence, concentration difficulties, and freezing may be related to hyper-arousal symptoms. Finally, we conceptualised this as a psychotic disorder superimposed on a baseline of ASD. In previous services, a mood disorder with psychotic features was treated. Our observations did not indicate dominant mood features but rather a dominant picture of withdrawn and disorganised behaviour (e.g. mutism, restricted responsiveness, catatonic posturing, incontinence and unexplained violence). The evidence of hearing voices was limited to a clinical note from a previous admission and observed episodes of incongruous laughter. Reduced verbal communication could be an effort to reduce the risk of being a target of ridicule, as he previously stated that he felt people were laughing at what he said when at school. Negative symptoms (e.g. lack of drive and flattened affect) appeared more evident. HP's age, gender, onset and progression are compatible with established norms for psychotic illness. Although there is a clinical dilemma with respect to differentiating between psychotic catatonia and autism-related catatonia, the National Autism Service advised that this is especially common in late adolescence and labelled this as part of ASD. Two independent specialists assessed psychosis and this was adopted as our working diagnosis for treatment.

Treatments

Medications

Antipsychotics were monitored against key problematic behaviours (see Fig. 1). This involved nursing staff completing ABC charts (i.e., antecedent, behaviour, consequence) to document all daily incidents of repetitive behaviours, aggression and incontinence. Days when he spent time off the in-patient unit were monitored from the sign in/out book used to record patient leave. At admission, lorazepam was increased to 8 mg/day to treat catatonia and violence but, as there was no improvement in symptoms and he appeared increasingly sedated, this was discontinued. Quetiapine was changed to olanzapine 20 mg daily and there was some improvement to his mental state noted from behavioural observations, including more days spent off the ward doing occupational therapy activities and a reduction in aggression and incontinence. Olanzapine was chosen (rather than aripiprazole or risperidone, which have larger evidence bases in ASD) because there were concerns about HP's agitation and poor food intake; it has sedative effects, stimulates appetite and has a larger evidence base for use in psychosis and low mood.^{11,12} As there was no clear benefit from antidepressant medication (venlafaxine), this was tapered and discontinued in October 2014. In January 2015, it was considered that he warranted a trial of clozapine, which is the only antipsychotic to repeatedly demonstrate efficacy for patients who fail to respond to other antipsychotic medication, but has a broad range of adverse effects.¹³ Clozapine initiation followed satisfactory baseline creatine kinase and troponin measures, echocardiography and normal physical observations. Clozapine was titrated according to Maudsley prescribing guidelines.¹⁴ His full blood count displayed no signs of eosinophilia, neutropenia or agranulocytosis (neutrophils $5.64 \times 10^9/L$, white blood cells $9.17 \times 10^9/L$, and eosinophils $0.40 \times 10^9/L$). Clozapine treatment resulted in a further reduction in aggression and incontinence. Significant sedation was observed initially that appeared to have an impact on the number of activities he engaged in during the day. Although the number of days off the ward increased 3–4 months after initiation of Clozapine, much encouragement and behavioural plans were needed for him to engage in any activities, and when outside he showed excessive vigilance and vomiting increased. Medical reasons for vomiting were investigated and no organic cause was found. There was also an increase in obsessive checking behaviours that were newly observed

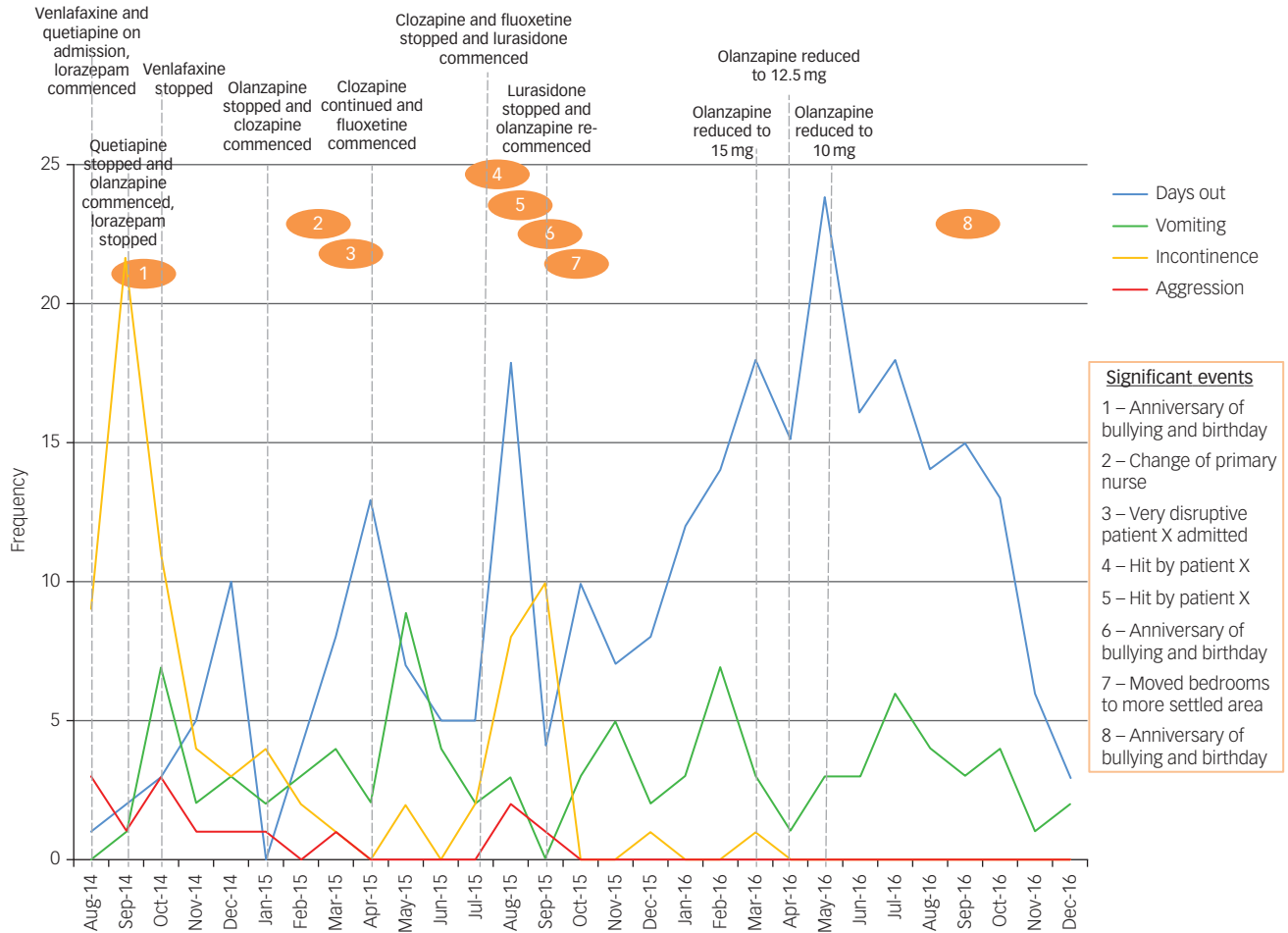


Fig. 1 The frequencies of key behaviours, significant events and medication changes during admission.

and were assessed on a monthly basis with the Yale–Brown Obsessive Compulsive Scale (Y-BOCS; adapted to be clinician rated).¹⁵ An attempt to treat these obsessive symptoms with high-dose fluoxetine was ineffective, for example, it took him approximately 1 h to walk from the ward to outside owing to constant retracing and counting of his steps (this previously took him 2–3 min). The reduction in quality of life and potential long-term effects on physical health were considered to outweigh the potential benefits of continuing with this treatment; clozapine was therefore tapered and discontinued in July 2015 and cross titrated with lurasidone. Following cessation of clozapine, the above symptoms resolved spontaneously and the impression of the medical team was that this was a clozapine-induced obsessive–compulsive disorder.¹⁶ Lurasidone was considered because of its safer metabolic profile and positive anxiolytic and antidepressant effects.¹⁷ Lurasidone was titrated up to 111 mg daily, and we observed a reduction in vomiting and more interactions with others (e.g. playing board games, verbal responses to questions, wanting to go outside). However, severe sleep disturbance, increased nocturnal urinary incontinence and increased episodic aggression were also observed. This medication change coincided with two physical assaults by another patient, and it is therefore difficult to ascertain whether the observed changes were due to medication, environmental stressors or both. Benzodiazepines were ineffective in reducing these behaviours, and therefore lurasidone was switched to olanzapine in September 2015, increased to 20 mg daily. There was a gradual improvement in his sleep and behaviour, although vomiting remained problematic. In March 2016, after 6 months of treatment

with olanzapine 20 mg, this was reduced in increments of 2.5 mg to a stable daily dose of 10 mg to reduce sedation, while monitoring for the re-emergence of key problematic behaviours and psychotic symptoms.

Psychological input

To help manage ASD-related needs, positive behaviour interventions such as social stories, which were appropriate for his academic and developmental level, were used (e.g. morning/evening routines, moving bedroom). We monitored HP's reactions to these interventions in terms of a simple mood visual analogue scale; staff consistency was key in their implementation. Information gathered from the completed ABC charts was used to develop behavioural interventions, and these were regularly reviewed during multi-professional meetings. Family interventions were offered monthly to his parents and focused on understanding and managing ASD and psychosis; particularly how to respond to distress. HP remained selectively mute throughout his admission, and therefore it was not possible to deliver cognitive–behavioural therapy for psychosis. He met with the clinical psychologist weekly for individual sessions that focused on understanding anxiety, anger and dissociation; he appeared to enjoy hearing new information and would say aloud what he had learned. Given his distress and previous incidents of violence to others, he was encouraged to practice grounding techniques and controlled breathing exercises (and these were used by staff when outside with HP) to help maintain his attention in the present moment and reduce distress.

Outcomes

There was a notable shift in HP's engagement with people and activities. There were no aggressive events since August 2015, and no catatonic behaviour or unusual posturing; however, episodic incontinence and vomiting remained. He began speaking in short sentences and would sing along to music videos independently. He answered factual questions on a few restrictive areas (e.g. world capitals and even the first 100 digits of pi) with enjoyment. HP engaged in voluntary work at the local community shop for a few hours a week, went swimming, played snooker, etc. He was more independent in washing, dressing and at mealtimes.

Discussion

This report describes the successful improvement in symptoms and quality of life in a young man with psychosis and ASD, who had previously tried numerous medical interventions. With an appreciation of the apparent fluid boundaries between ASD and psychosis, we adopted a symptom-based approach. Rigorous monitoring of symptoms and adaption of standardised measures enabled us to safely identify an optimal therapeutic strategy, as well as identifying complications associated with specific medications. We were also able to reduce polypharmacy.

It has been observed in the literature that psychosis can be misdiagnosed in people with ASD if the experience occurs at the time of high stress and disrupted routine. In this case, resolution did not occur until the prescription of antipsychotic medication and introduction of behavioural management strategies. It is plausible that HP experienced an acute and transient psychotic episode as part of a stress reaction to bullying; Fig. 1 illustrates increases in vomiting, incontinence and aggression around the anniversary and following environmental stressors. Given the query regarding trauma and that HP reported feeling 'frightened', we might have expected a selective serotonin reuptake inhibitor (SSRI) to have had a more beneficial effect on his mental state by lowering anxiety, but this was not observed. The level of violence upon admission concerned our team and his parents – ToM deficits inherent in ASD may indeed make it more likely that he acted on persecutory ideas. Therefore, if psychotic symptoms were ignored, violence may have continued and led to long-term placements in a more secure environment.

It is important to comprehensively assess and treat psychosis in adults with ASD to reduce morbidity associated with these disorders. We consider close monitoring of signs and symptoms key to developing awareness of the individual characteristics, and allowing treatment changes to be made accurately and quickly.

Victoria Bell, BSc, PhD, DClInPsy, Clinical Psychologist, National Psychosis Unit, South London and Maudsley National Health Service (NHS) Foundation Trust, London, UK. Department of Psychosis Studies, Institute of Psychiatry, Psychology and Neuroscience (IoPPN), King's College London, London, UK; **Henry Dunne**, BA, Medical Student, King's College London, London, UK; **Tharun Zacharia**, MRCPsych, Specialist Registrar in General Adult and Older Adults Psychiatry, South London and Maudsley NHS Foundation Trust, London, UK; **Katrina Brooker**, BSc, Practice Development Nurse, National Psychosis Unit, South London and Maudsley NHS Foundation Trust, London, UK; **Sukhi Shergill**, BSc, MBBS, SFHEA, PhD, FRCPsych, Professor of Psychiatry and Systems Neuroscience, Department of Psychosis Studies, Institute of Psychiatry, Psychology and Neuroscience (IoPPN), King's College London, London, UK; Consultant Psychiatrist, National Psychosis Unit, South London and Maudsley NHS Foundation Trust, London, UK

Correspondence: Dr Victoria Bell, Department of Psychosis Studies, Institute of Psychiatry, Psychology and Neuroscience (IoPPN), King's College London, London SE5 8AF, UK. Email: victoria.1.bell@kcl.ac.uk

First received 2 Aug 2017, final revision 3 Nov 2017, accepted 6 Nov 2017

Funding

S.S. was funded by a European Research Council Grant (grant number 311686), and by the National Institute for Health Research (NIHR) Mental Health Biomedical Research Centre at South London and Maudsley NHS Foundation Trust and King's College London, and a joint infrastructure grant from Guy's and St Thomas' Charity and the Maudsley Charity.

References

- Nylander L, Lugnegard T, Hallerback MU. Autism spectrum disorders and schizophrenia spectrum disorders in adults: is there a connection? A literature review and some suggestions for future clinical research. *Clin Neuropsychiatry J Treat Eval* 2008; **5**: 43–54.
- Owen MJ, O'Donovan MC, Thapar A, Craddock N. Neurodevelopmental hypothesis of schizophrenia. *Br J Psychiatry* 2011; **198**: 173–5.
- Chisholm K, Lin A, Abu-Akel A, Wood SJ. The association between autism and schizophrenia spectrum disorders: a review of eight alternate models of occurrence. *Neurosci Biobehav Rev* 2015; **55**: 173–83.
- van Dooren K, McPherson L, Lennox N. Mapping the needs of adults with autism and co-morbid intellectual disability. *Curr Dev Disord Rep* 2016; **3**: 82–9.
- Raja M, Azzoni A. Autistic spectrum disorders and schizophrenia in the adult psychiatric setting: diagnosis and comorbidity. *Psychiatr Danub* 2010; **22**: 514–21.
- Barneveld PS, Pieterse J, de Sonnevill L, van Rijn S, Lahuis B, van Engeland H, et al. Overlap of autistic and schizotypal traits in adolescents with autism spectrum disorders. *Schizophr Res* 2011; **126**: 231–6.
- Bevan JR, Thapar A, Lewis G, Zammit S. The association between early autistic traits and psychotic experiences in adolescence. *Schizophr Res* 2012; **135**: 164–9.
- North AS, Russell AJ, Gudjonsson GH. High functioning autism spectrum disorders: an investigation of psychological vulnerabilities during interrogative interview. *J Forens Psychiatry Psychol* 2008; **19**: 323–34.
- van Os J, Hanssen M, Bijl RV, Ravelli A. Strauss (1969) revisited: a psychosis continuum in the general population? *Schizophr Res* 2000; **45**: 11–20.
- Lord C, Rutter M, Le Couteur A. Autism Diagnostic Interview-Revised: a revised version of a diagnostic interview for caregivers of individuals with possible pervasive developmental disorders. *J Autism Dev Disord* 1994; **24**: 659–85.
- Fleischhacker WW, McQuade RD, Marcus RN, Archibald D, Swainink R, Carson WH. A double-blind, randomized comparative study of aripiprazole and olanzapine in patients with schizophrenia. *Biol Psychiatry* 2009; **65**: 510–17.
- Mauri MC, Moliterno D, Rossattini M, Colasanti A. Depression in schizophrenia: comparison of first- and second-generation antipsychotic drugs. *Schizophr Res* 2008; **99**: 7–12.
- La Grenade L, Graham D, Trontell A. Myocarditis and cardiomyopathy associated with clozapine use in the United States. *N Engl J Med* 2001; **345**: 224–5.
- Taylor D, Paton C, Kapur S. *Maudsley Prescribing Guidelines* (11th edn). Informa Healthcare, 2012.
- Goodman WK, Price LH, Rasmussen SA, Mazure C, Fleischmann RL, Hill CL, et al. The Yale–Brown Obsessive–Compulsive Scale: development, use, and reliability. *Arch Gen Psychiatry* 1989; **46**: 1006–11.
- Schirmbeck F, Zink M. Clozapine-induced obsessive-compulsive symptoms in schizophrenia: a critical review. *Curr Neuropharmacol* 2012; **10**: 88–95.
- Samalin L, Garnier M, Llorca PM. Clinical potential of lurasidone in the management of schizophrenia. *Ther Clin Risk Manag* 2011; **7**: 239.

