

## Genetical studies on the skeleton of the mouse

### XXVI. PINTAIL\*

By R. J. BERRY

*Medical Research Council Experimental Genetics Research Unit,  
University College London*

(Received 7 April 1960)

#### INTRODUCTION

The gene for Pintail (symbol *Pt*; linkage group VIII) in the mouse was first described by Hollander & Strong (1951). The original mutant occurred in an experiment in which mice of the 'pBr' strain were treated with the alleged mutagen methylcholanthrene. The animals used in the work described in this paper were descended from four Pintail animals received from the Roscoe B. Jackson Memorial Laboratory, Maine, U.S.A. in August 1956. These animals were initially outcrossed to the CBA/Gr inbred strain, and the present line is descended from these crosses.

#### GENETICS

According to Hollander & Strong (1951) the mutant showed no dominance. Matings between Pintail heterozygotes produce offspring which can be classified at birth into three phenotypic classes: normal, 'moderate' Pintail and 'extreme' Pintail, the distinction between the two Pintail phenotypes being made on the basis of tail length. 'Extreme' Pintail animals are almost always *Pt/Pt*: in back-cross ('extreme' Pintail  $\times$  'moderate' Pintail) and in intercross matings they are produced in the proportions of a half and a quarter respectively.

There may be a certain amount of mis-classification between Pintail homozygotes and heterozygotes, but all test-matings have confirmed the original classification. The breeding data collected in this laboratory are set out in Table 1. Animals classified as 'moderate' Pintails have been assumed to be genotypically *Pt/+*, and those classified as 'extreme' Pintail to be *Pt/Pt*.

Table 1. *Segregation of Pintail*

Type of mating	Normal	<i>Pt/+</i>	<i>Pt/Pt</i>	Total
1. <i>Pt/+</i> $\delta$ $\times$ <i>+/+</i> $\text{♀}$	151	125	0	276
2. <i>+/+</i> $\delta$ $\times$ <i>Pt/+</i> $\text{♀}$	97	94	0	191
3. <i>Pt/+</i> $\times$ <i>Pt/+</i>	157	337	148	642
4. <i>Pt/Pt</i> $\times$ <i>+/+</i>	0	46	0	46
5. <i>Pt/Pt</i> $\times$ <i>Pt/+</i>	0	42	39	81
6. <i>Pt/Pt</i> $\times$ <i>Pt/Pt</i>	0	0	117	117

\* Work carried out in partial fulfilment of requirements for degree of Ph.D. (London).

*Interaction of Pintail and other genes*

The effect of Pintail in combination with Brachyury (*T*), Danforth's short-tail (*Sd*) and vestigial-tail (*vt*) was studied. Reciprocal crosses were made between Pintail and these genes. Litters were killed at birth and stained with methylene blue for cartilage. No differences were found between reciprocal matings of the same type.

1.  $Pt/+ \times vt/vt$ 

The offspring were classified as;

22 normals; 15 with *Pt*-type tail.

Hence it was concluded that Pintail and vestigial-tail heterozygotes do not interact.

2.  $Pt/+ \times Sd/+$ 

Animals carrying the *Sd*-gene have an abnormal axis-atlas articulation and hence can be recognized in clearance preparations (Theiler, 1951, Grüneberg, 1953*b*).

The observed segregation was;

24 normals, 21 with *Pt*-type tail, 29 *Sd* animals with a short tail, 14 *Sd* animals with a filamentous tail.

If the last class is genotypically  $Sd/+ ; Pt/+$  the segregation is reasonably close to the 1 : 1 : 1 : 1 expected segregation.

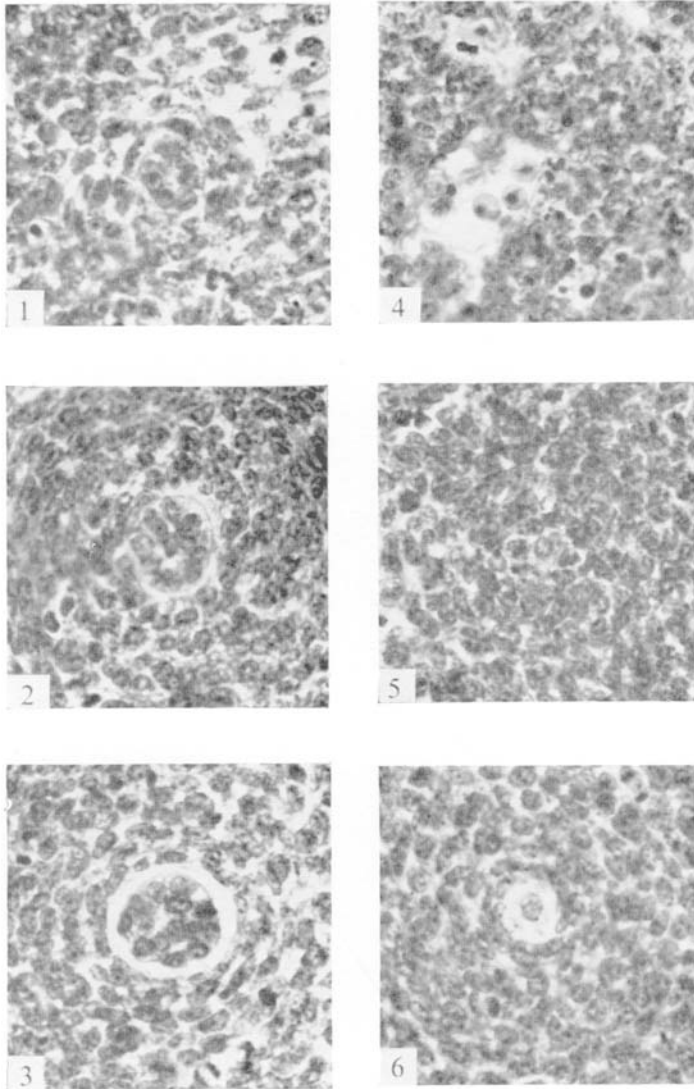
However the *Sd* gene has a relatively strong expression on the genetic background of the *Pt* stock. In a cross between an *Sd* male and a  $+/+$  female from the *Pt* stock, the progeny were classified as follows;

16 normal, 22  $Sd/+$  animals.

The *Sd* animals all had very short tails, and five of them had only filamentous tails. Hence it would be incorrect to assume that the fourteen animals with filamentous tails from the  $Pt/+ \times Sd/+$  cross are necessarily of  $Sd/+ ; Pt/+$  genotype. It is likely that most of them are, since there is no deficiency of *Sd* animals, but the only conclusion that can be made is that there may be some mis-classification of  $Sd/+$  and  $Sd/+ ; Pt/+$  animals. All the animals with filamentous tails which were not killed at birth died before weaning and thus could not be tested genetically.

3.  $Pt/+ \times T/+$ 

The  $Pt/+$  gene on the genetic background of the *T*-stock shows a reduced manifestation. As the effects of the *T* and *Pt* genes on the tail are rather different, it was possible to classify  $Pt/+$  animals among the offspring with a reasonable expectation of accuracy. Distinguishing between the other two abnormal genotypes was more difficult. Grüneberg (1958*a*) found that, although early *T* embryos possess a notochord from head to tail-tip, in a single 10½-day-old embryo (which was the



1-6: 7.5  $\mu$  transverse sections of the tail of embryos from litter 2 (nominal age  $13\frac{1}{3}$  days).  
1-3: Respectively 50th, 200th and 400th sections from the tail tip in a normal embryo. (C.R.L. 9.9mm.).  
4-6: Comparable sections in a *Pt/+* embryo (C.R.L. 10.1mm.). At the tail tip there is considerable pycnosis and disorganization and no signs of a notochord. The notochord is very small when it eventually becomes visible (6). A trace of the notochord can be seen in 5.

R. J. BERRY

(Facing p. 440)

oldest that he examined), 'the notochord was lost track of for a stretch in the cloacal region. . . . It may be that in this embryo the notochord may have actually disintegrated for a distance.' It was found that the nuclei pulposi were reduced in the thoracic and lumbar regions in clearance preparations of some newborn  $T/+$  mice. Hence it would appear that there was a secondary breakdown of the notochord in these embryos.

Now the  $Pt$  gene also reduces the size of the nuclei pulposi (see below) and among the abnormal animals resulting from the  $Pt/+ \times T/+$  cross were a number with a filamentous tail, and these animals had the most abnormal discs. If these animals are taken to be double heterozygotes, the offspring of the cross can be classified as follows

$$32 +/+ , 24 Pt/+ , 28 T/+ , 11 Pt/+ ; T/+$$

As there is no deficiency of  $T/+$  animals, and as no filamentous-tailed animals were found among the offspring of the cross between  $T/+$  and a normal from the  $Pt$  stock, this classification is probably substantially correct. Hence the conclusion that  $Pt$  and  $T$  reinforce each other.

#### ANATOMY

The morphology of Pintail mice from birth onwards was described by Hollander & Strong (1951). Generally the tail of Pintail heterozygotes is about two-thirds normal length with a peculiar thin and distorted tip (hence the name) with one or more distal kinks. Alizarin red clearance preparations showed that the kinks are formed by the displacement from correct alignment of normal tail vertebrae. No ankyloses were found. Only the actual vertebrae involved in a 'kink' are abnormal: more distal vertebrae become normal again except at the extreme end of the tail, where the last few vertebrae are small and somewhat irregular. The number of tail vertebrae is usually reduced by about a third, but there were some Pintail animals with the normal number of tail vertebrae. Measurements of the overall length of tail vertebrae revealed no difference between normal and Pintail animals.

Pintail homozygotes differed from heterozygotes only in having a much shorter and more kinked tail, the number of tail vertebrae being always less than ten.

'The Pintail trait is almost as easy to recognize in newborn young as in adults. The tail of the normal newborn mouse has a smooth contour and blunt tip; that of Pintail is more irregular in contour, usually with one or more constrictions, and has a pronounced filiform tip. In the more pronounced cases even half or more of the tail may be thin, and may be bent down and reflexed somewhat like a bent pin' (Hollander & Strong). The classification of all segregating litters was made at birth or soon afterwards, and from the close agreement between the expected and observed segregation ratios, is presumably substantially correct. However, on several occasions it was found that animals classified as Pintail at birth seemed to have a normal tail later in life. Methylene blue clearance preparations (see below) showed that in fact the birth classification was correct and animals which are

clearly Pintail at birth may later become phenotypically normal. In alizarin preparations of up to and including 12-day-old animals no abnormal tails were found. The 15-day-old animals showed the usual pattern of tail deformity. The shortening of the tail with the production of a terminal filament, and the kinking of the tail found in adult mice are almost certainly different manifestations of the gene. The filament falls off the tail as the mouse grows up, and the tail tip may thereafter appear reasonably normal. The tail kinks are probably the incidental result of instability in the axial skeleton so that deforming stress, even that normally incident on a mouse tail in a small cage, might easily result in the displacement of vertebrae. Such instability would be expected because Pintail mice have abnormal intervertebral discs (see below). This explanation accords well with the apparently random distribution of tail-kinks in the distal part of the tail, and the occurrence of normal vertebrae distal to a kink. Hence tail kinks would not be expected to be an inevitable accompaniment of the Pintail trait; the most constant feature would seem to be the form of the tail tip.

Thirty-one *Pt/+* and twenty-five normal skeletons enzymatically macerated with papain were studied for the occurrence of minor variants (Grüneberg, 1955; Deol and Truslove, 1957). Only two small effects of the Pintail gene (or a gene closely linked to it; see Grüneberg, 1955) were revealed: an increase in the occurrence of the interfrontal bone of the skull ( $\chi^2 = 5.3$ ,  $P = 0.02$ ) and a decrease in the incidence of sacralization of L.VI ( $\chi^2 = 3.6$ ,  $P = 0.06$ ).

Pintail heterozygotes are not known to have any abnormality other than that of the skeleton. Hollander (1951) described urinogenital abnormalities in one branch of his Pintail stock.

In this line homozygous Pintail animals frequently had a persistent cloaca or an imperforate anus, the latter resulting in early death. Pintail homozygotes of the present stock frequently die during the first fortnight of life. Such animals are invariably retarded in growth and possess a distended belly. On dissection the stomach and intestines are found to be packed with food right down to the anus. One animal which was found dead on the second day after birth was found to have an imperforate anus. However, most of the *Pt/Pt* animals that die, do so about the end of the first week and certainly have some anal opening. A possible explanation for the cause of death of these animals seems to be that the size of the anus is insufficient to cope with the faeces, and hence they suffer from a chronic anal blockage.

#### THE INTERVERTEBRAL DISCS

Some time ago Grüneberg made an incidental observation that the nucleus pulposus of the intervertebral disc was very clearly demonstrated in young mice stained with methylene blue for cartilage and cleared in methyl salicylate (Noback, 1916, see also Grüneberg, 1953*a*). It was found that animals aged about three weeks were the best for this purpose. The animals were killed and the vertebral column removed. The spine was then stretched, tied to a flat glass plate and fixed in formalin. The method of staining and clearing was the same as for whole younger animals.

It was found that the nuclei pulposi were very much reduced throughout the vertebral column in Pintail animals. Drawings of preparations of a normal and a Pintail animal are shown in Fig. 1. It is evident that there are differences in both the size and the shape of the nuclei pulposi between the two animals. The abnormal seems to have more compact and densely staining discs, particularly in



Fig. 1. Drawings of methylene blue stained preparations of mice aged 25 days to show the variation in size and shape of the nuclei pulposi in normal and *Pt/+* animals. The convention of shading is the same throughout, so that although the nuclei pulposi in the tail of the Pintail animal appear larger than in the thoracic region, they in fact contain less notochordal material.

- A. Trunk region: sixth cervical vertebrae (at the top) to thirteenth thoracic.  
B. Tails of the same mice.

the thoracic region. However, this may be a direct effect of the dorsoventral depth of the discs: the normal animal has densely stained discs in the thoracic region, and flatter and thinner ones in the lumbar region. The only irregularity found in the nuclei pulposi was in the last one or two lumbar discs of Pintail mice in which the nucleus pulposus sometimes seemed to be split in the middle taking the form of two partly overlapping plates. The shape of the nuclei pulposi changes in a

characteristic fashion from head to tail, but the variation seems to be about the same in both Pintails and normals. The ratio of the two major diameters (anterio-posterior and lateral) of the nucleus pulposus is approximately the same in all three genotypes in most regions except the tail, with the exceptions noted above.

It was impossible to see if the nuclei pulposi at a tail kink differed from neighbouring ones, because there seems to be virtually no nucleus pulposus in the region of the tail where kinks occur.

#### *Histological studies on the intervertebral disc*

Serial sections were cut of selected intervertebral discs from fixed normal and *Pt/+* mice. The findings confirmed the results obtained from the study of methylene blue clearance preparations. Discs from *Pt/+* animals possessed a very much smaller nucleus pulposus than normal, containing fewer cells and already undergoing signs of degeneration at the age of 100 days. The age changes of the discs in Pintail mice will be the subject of a separate communication.

#### EMBRYOLOGY

Hollander & Strong (1951) state that recognition of the Pintail trait is 'possible in late foetal stages', but attempted no further embryological analysis. In the present study embryos were collected from both backcross (Pintail  $\times$  normal) and intercross (Pintail  $\times$  Pintail) matings. The chronological age of the embryos was known to within one night, and this time was checked by measuring the crown-rump length of the embryos, and comparing it with the standard series given by Grüneberg (1943). Twenty-one litters containing 130 embryos ranging in size (average C.R.L.) from 11.6 mm. (14½ days old) to 2.4 mm. (9 days old) were serially sectioned. A camera-lucida drawing was made of every embryo before it was sectioned. The material was fixed in Bouin's fluid and embedded by Peterfi's collodion impregnation method (Peterfi, 1921). Sections were cut at 7.5  $\mu$  or 8  $\mu$  except in the case of the large embryos of litter 3 and the trunk region of litter 1 which were sectioned at 10.0  $\mu$ . The sections were stained with Ehrlich's haematoxylin and eosin. Great care was taken to obtain, as nearly as possible, transverse sections through the tail, the tail bud or the posterior end of the body, as interpretation of these regions is difficult or even impossible in oblique sections (Grüneberg, 1956). In the larger embryos (litters 1-2, 11-12) the tail was cut from the trunk and sectioned separately. The trunk region was then available for sectioning in a more favourable plane. Projection drawings at magnification  $\times 250$  were made of every tenth section of the tail region of each embryo.

The serially sectioned embryos are listed in Table 2. About half a dozen embryos are omitted from the classified litters because of mechanical damage during preparation which made classification impossible. Normals and abnormal could be recognized by external inspection in litters 1-2, 11-12; as classified from the sectioned material, litters 3-7 contained 12  $+/+$  and 15 *Pt/+* embryos, and litters 11-17 8  $+/+$ , 16 *Pt/+* and 12 *Pt/Pt* embryos. There was no detectable effect

Table 2. *Serially sectioned embryos*

Litters	<i>Pt/+ × +/+ matings</i>				<i>Pt/+ × Pt/+ matings</i>					
	Nominal age (days)	Mean C.R.L. (mm.)	No of embryos		Litters	Nominal age (days)	Mean C.R.L. (mm.)	No. of embryos		
			+/+	<i>Pt/+</i>				+/+	<i>Pt/+</i>	<i>Pt/Pt</i>
1	14½	11.5	5	3	11	14½	11.6	1	2	2
2	13½	10.0	1	6	12	12½	8.0	1	2	2
3	12	7.7	3	2	13	11	5.4	1	1	2
4	11½	6.3	2	2	14	10½	4.5	1	2	2
5	11½	6.1	3	4	15	10½	4.3	3	1	1
6	10½	4.5	2	4	16	10	3.7	1	4	2
7	10	3.7	2	3	17	10	3.7	0	4	1
9	9½	2.8	6*							
10	9	2.4	5*							

\* Not classified.

of the genotype upon size (crown rump length), and therefore only the mean size of litters are given in the table.

*The Development of Pt/+ and Pt/Pt Embryos*

*14½-day-old embryos.* At the age of 14½ days, the tail tip of Pintail embryos appears constricted and tapering. It was not found possible to distinguish between *Pt/+* and *Pt/Pt* embryos by external inspection at this age. Sections of the tail of *Pt/+* animals of litter 1 showed some pycnotic cells in the tail tip and considerable terminal disorganization. The notochord was very much reduced and terminated some way before the actual end of the tail. There was no proper notochord terminally although in places the remains of the sheath with one or two cells, often pycnotic, could be seen. The notochord proper begins about half-way along the tail and is clear and continuous for the rest of its course anteriorly. The cells, which are arranged concentrically around the notochord in the normal, do not show the same degree of orientation in the abnormal, as if some organizing influence which normally emanates from the notochord is absent or reduced. In litter 11 (which is of the same age) there was one normal embryo, two embryos similar to the abnormal in litter 1 and presumed Pintail heterozygotes, and two more severely affected animals. These are presumably Pintail homozygotes. In these two animals there was no trace of the notochord in the tail at all, and pycnosis was much more advanced than in the *Pt/+* embryos. Distally pycnotic cells were found in all parts of the sections of the tail; more anteriorly pycnosis seemed to be confined more to the central region as if it were radiating from the place where the notochord normally would be.

*13½-day-old embryos.* The embryos in litter 2, one day younger, were similar in appearance and tail structure to those of litter 1. The appearance of the notochord in sections of two embryos of this age are shown in Plate I. The trunks of two embryos from this litter, one normal, one *Pt/+*, were serially sectioned so that the notochord was cut transversely over as great a region as possible. Counts were



made of the number of cells in the notochord (Fig. 2). Abercrombie (1946) has drawn attention to the possible inaccuracies involved in the making of cell counts from microtome sections. No attempt has been made to apply this correction as all counts were made for comparison with a similar series. The number of cells in the *Pt/+* embryo is reduced by about a third.

The only difference between the two animals seems to be in the reduced number of cells in the *Pt/+* animal in the regions of cell aggregation. These are the cells which persist until birth and eventually become the nucleus pulposus of the intervertebral disc.

*12½-day-old embryos.* Litters 3 and 12 differed from the older ones only in showing less pycnosis. At this stage Pintail embryos cannot be recognized with certainty from their external appearance, and hence the classification had to be made entirely from sections. Although the notochordal sheath had been formed in the

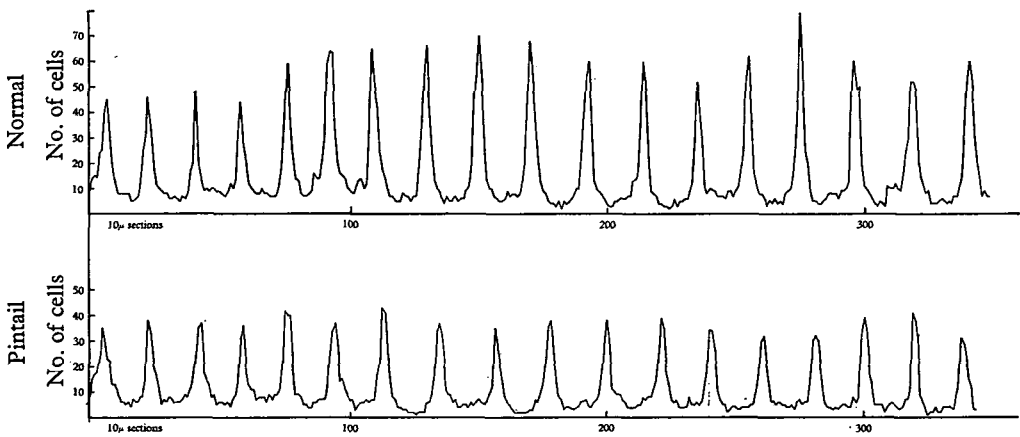


Fig. 2. Number of cells in the notochord of the trunk region of a normal and a *Pt/+* embryo of litter 2 (nominal age  $13\frac{1}{2}$  days, C.R.L. 9.9 mm. and 10.1 mm. respectively), showing the progressive reduction in number of the cells in the aggregations in the Pintail embryo along the axis of the embryo.

trunk region, it had not extended into the tail of these embryos. This made the interpretation of the tail sections more difficult and although in many places it was impossible to recognize a notochord, it was possible that a small one was present.

*11–11½-day-old embryos.* At this stage condensation of mesenchyme round the notochord of the tail has barely begun, and hence the notochord is clear in section. There seems to be no marked pycnosis in the sectioned embryos examined (litters 4, 5 and 13). It was possible, at least in litters 4 and 5, to recognize the abnormal animals by a rather smaller tail notochord, but the difference in size was not striking. Although measurements of the cross-sectional area and counts of the number of notochordal cells tended to confirm the classification made by eye, convincing differences between the three genotypes were, at this stage, only revealed by mitotic counts (see below).

*9–11-day-old embryos.* It was not found possible to recognize Pintail embryos at ages younger than 11 days from a cursory inspection of sectioned material. All

embryos have an apparently normal tail both in overall size and in the size of the notochord. Now Pintail embryos of 11 days and older have a reduced notochord which leads to a breakdown of the tail tip. The reduction of the notochord is not yet obvious in 10-day embryos. It may have been brought about by:

- i. the death of cells
- ii. the failure of cells to increase in number
- iii. the loss of notochordal cells by migration and incorporation in other tissues.

To test these alternatives the number of cells, pycnoses and mitoses in the notochord were counted in a region immediately in front of the tail tip (sections 30–50 from the tip) in a total of 55 embryos (data summarized in Table 3: the mitotic rate counts fall into distinct groups which have been pooled). In the two youngest litters 9 and 10 it was found impracticable to count the cells in the notochord in

Table 3. *Mitotic rates (mitosis/cell) in the notochord of normal and abnormal embryos (sections 30–50 from the tail tip). The upper section of the table from Pt/+ × +/+ matings, the middle section from Pt/+ × Pt/+ matings. In the lower section, comparable figures are given from some +/+ embryos from Grüneberg's (1958 b) Sd experiments, prepared by the present author. Individual counts, in all but five cases, are based on 200–500 cells. Numbers of embryos in parentheses.*

Litters	Mean C.R.L. (mm.)	Mitotic rate			
		+ / +	Pt / +	Pt / Pt	
{ 5	6.1	0.118 (3)	0.065 (4)	—	
	6	0.194 (2)	0.098 (4)	—	
	7	0.194 (2)	0.119 (3)	—	
{ 13	5.4	0.129 (1)	0.096 (1)	0.054 (2)	
	14	0.202 (1)	0.105 (2)	0.070 (2)	
	15	4.3	0.200 (3)	0.114 (1)	0.086 (1)
	16	3.7	0.257 (1)	0.138 (4)	0.079 (2)
	17	3.7	—	0.129 (4)	0.076 (1)
{	5.1	0.177 (2)			
	4.4	0.199 (5)			
	3.7	0.275 (3)			

In addition to the litters tabulated above, two younger litters from Pt/+ × +/+ matings have been examined in which normal and abnormal embryos could not be distinguished. One, of six embryos (litter 9, mean C.R.L. 2.8mm.) had a mean mitotic rate of 0.483 mitoses/cell; the other, of five embryos (litter 10, mean C.R.L. 2.4mm.) had a mean mitotic rate of 0.401.

section 30 because at this age the notochord has not yet become differentiated from its neighbours in this region and in these two litters the counts were made on sections 35–50 inclusive in front of the tail tip. The mitotic and pycnotic rates are not affected by the plane of sectioning (unlike cell number) and hence provide a reasonably accurate estimate of the rate of increase or decrease in cell number. A cell was scored as being in mitosis if its chromosomes were clearly visible.

No embryos had more than a few pycnotic cells in the notochord, but there were

marked differences in mitotic rates between different embryos. Fig. 3 includes counts from both backcross (indicated by  $\circ$ ) and intercross (indicated by  $\bullet$ ) matings. Also included (indicated by  $\times$ ) are data from normal embryos of another stock (see Table 3).

Embryos from intercross matings (litters 13–17, Table 2) are distributed in

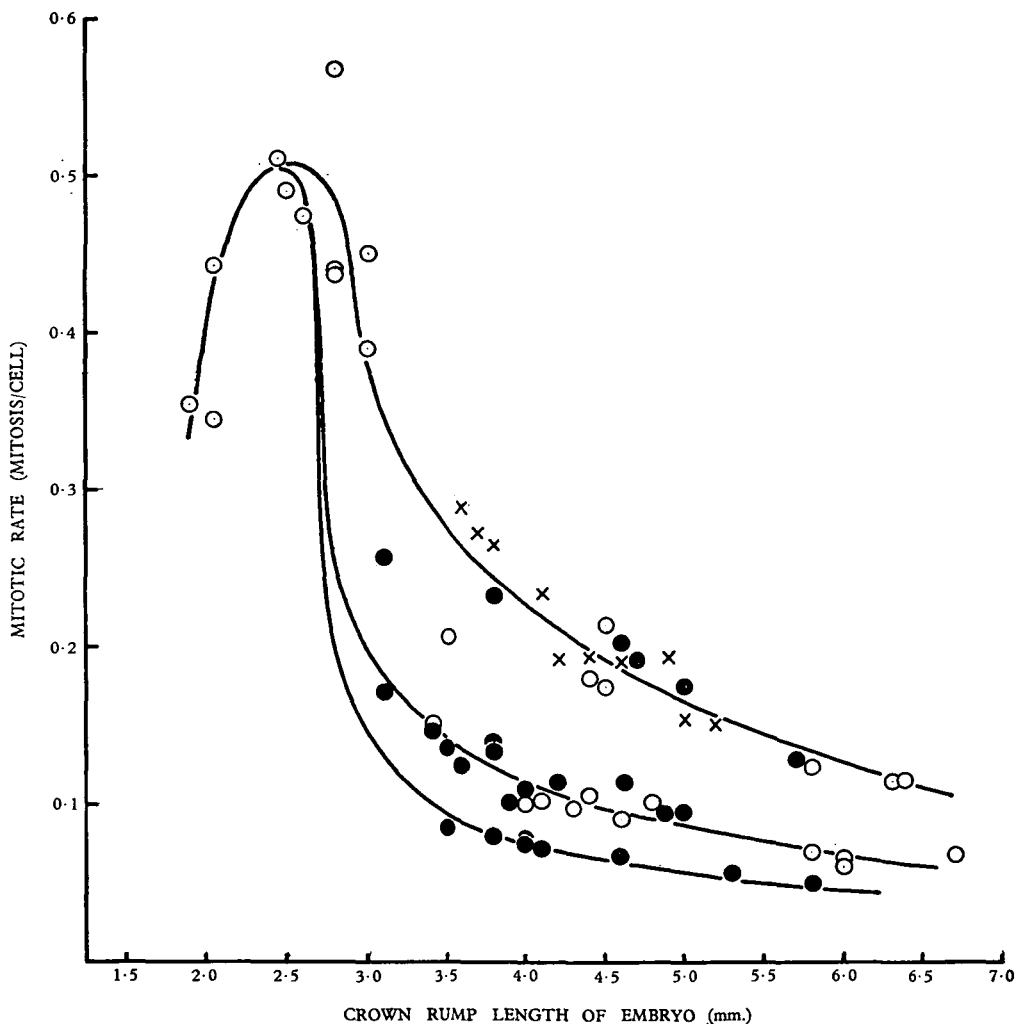


Fig. 3. Mitotic rate in the embryonic tail notochord showing the different rates of cell division in  $+/+$ ,  $Pt/+$  and  $Pt/Pt$  embryos. The rate in embryos from backcross matings is indicated by  $\circ$ , from intercross matings by  $\bullet$ . The top line represents the mitotic rate in normal embryos, the bottom line in putative  $Pt/Pt$  embryos. Normal embryos from Grüneberg (1958b) are indicated by  $\times$ .

three distinct groups in the figure in the proportions 6 : 12 : 8. Embryos from litters 5–7 (from backcross matings) fall into the two upper groups in Fig. 3, in the proportion of 7 : 11. Hence it seems reasonable to conclude that the mitotic rate in the notochord of normal mice is shown by the top line of Fig. 3, that the second line includes the  $Pt/+$  embryos, and the bottom line the  $Pt/Pt$  embryos.

Moreover litter 5 can be classified directly from the appearance of the notochord in sections. This classification is the same as the one made on the basis of mitotic counts.

Fig. 3 shows that in normal embryos of 3.5 mm. C.R.L. or over the mitotic rate of the cells of the notochord decreases steadily. This process is accelerated mildly in *Pt/+* and strongly in *Pt/Pt* embryos. The reason for this difference is not clear. It is possible that the separation of the notochord from tail gut and neural tube happens in a rather different way in Pintail embryos, but the available data are not adequate to establish this point and will not be discussed.

Litters 9 and 10 contain 11 embryos. The probability of any embryo being genotypically *Pt/+* is 0.5. Hence the probability of there being no Pintail animal in this group is  $(\frac{1}{2})^{11}$ , which can clearly be neglected. However it is clear from Fig. 3 that Pintail embryos cannot be identified before the age of 10 days on the basis of the mitotic rate in the notochord.

The average mitotic rates in the notochord of the tail tip of embryos collected by Grüneberg (1958*b*) are also given in Table 3. It is clear that the mitotic rates in the notochord of these embryos and those in the Pintail stock inferred to be normal are very similar. The mitotic rate in the known normal embryos is slightly higher than in the embryos from the Pintail stock. This may just be experimental error, but it may represent a true difference in growth rate between the notochords of the two series of embryos. The known normal series of embryos is from the *Sd*-stock, and this is known to have different modifying genes to those present in the *Pt*-stock (see above).

It may be mentioned here that the tail gut and the ventral ectodermal ridge of the tail (Grüneberg, 1956) are of approximately normal size.

#### CONCLUSIONS ABOUT THE EFFECT OF THE *Pt* GENE ON DEVELOPMENT

From the data presented in the previous sections it is possible to arrive at a fairly complete understanding of the causal relationships in the effect of the *Pt* gene on development. The findings can be most conveniently summarized in a 'pedigree of causes' of the gene effects (Fig. 4). The accelerated age changes of the nuclei pulposi of the intervertebral discs will be discussed in a separate communication (Berry, 1960).

#### SUMMARY

1. The gene for Pintail (symbol *Pt*) shows no dominance. Heterozygotes are viable and fertile; many homozygotes die early in life, but the survivors appear to breed normally. *Pt* reinforces the effects of *Sd* and *T* on the tail; there is no evidence for interaction between *Pt* and *+vt*.

2. The gene produces a shortening of the tail, but the most marked effect on the adult is in the great reduction of the nucleus pulposus of the intervertebral discs, which may lead to tail kinks in some animals.

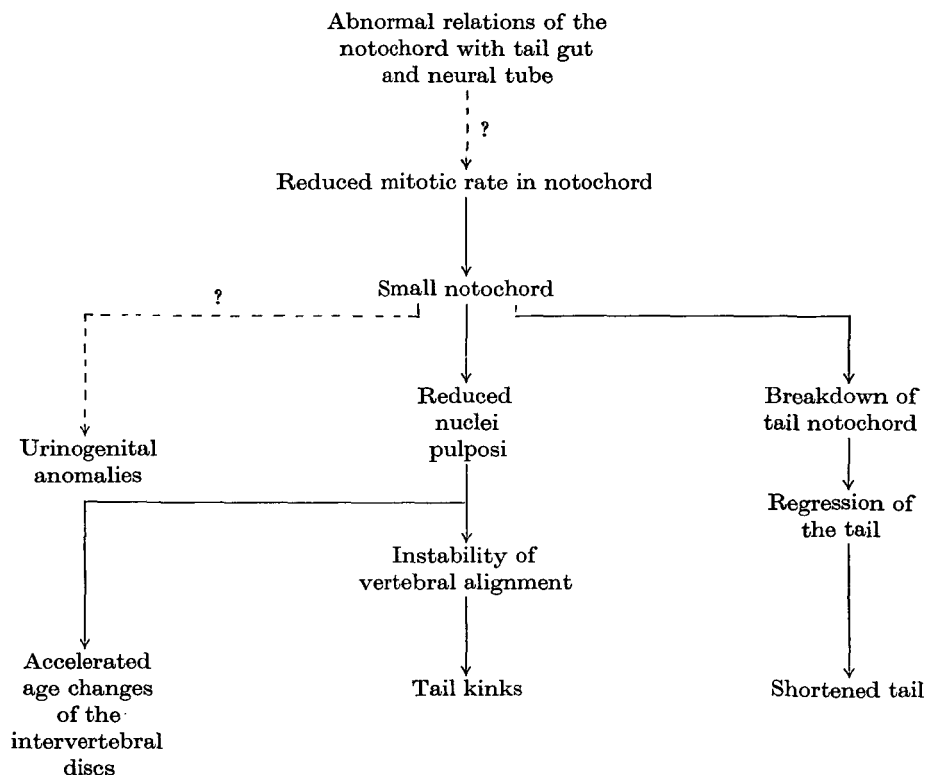


Fig. 4. Pedigree of causes of the *Pt* gene effects.

3. Pintail embryos can be recognized from the eleventh day stage of development onwards by the possession of a much smaller notochord than normal. This reduced notochord is the result of a reduced rate of cell division which first manifests itself in 10-day embryos. Perhaps this reduced rate is the result of altered relations of the notochord with tail-gut and neural tube in 10-day embryos.

The author would like to express his gratitude to Professor Grüneberg, F.R.S., for his interest and guidance in this work. The Roscoe B. Jackson Memorial Laboratory, Maine, U.S.A. is thanked for the gift of original Pintail animals. Mr A. J. Lee drew the original of Figs. 1, 2 and 3. Miss June Denny assisted with the photography. The work was carried out during the tenure of a Medical Research Council Scholarship, which is gratefully acknowledged.

#### REFERENCES

- ABERCROMBIE, M. (1946). Estimation of nuclear proportions from microtome sections. *Anat. Rec.* **94**, 239–247.
- BERRY, R. J. (1960). A genetically controlled degeneration of the nucleus pulposus in the mouse. (In preparation.)
- DEOL, M. S. & TRUSLOVE, G. M. (1957). Genetical studies on the skeleton of the mouse. XX. Maternal physiology and variation in the skeleton of C57BL mice. *J. Genet.* **55**, 288–312.
- GRÜNEBERG, H. (1943). The development of some external features in mouse embryos. *J. Hered.* **30**, 88–92.

- GRÜNEBERG, H. (1953*a*). Genetical studies on the skeleton of the mouse. VII. Congenital hydrocephalus. *J. Genet.* **51**, 327–358.
- GRÜNEBERG, H. (1953*b*). Genetical studies on the skeleton of the mouse. VI. Danforth's short-tail. *J. Genet.* **51**, 317–326.
- GRÜNEBERG, H. (1955). Genetical studies on the skeleton of the mouse. XV. Relations between major and minor variants. *J. Genet.* **53**, 515–535.
- GRÜNEBERG, H. (1956). A ventral ectodermal ridge of the tail in mouse embryos. *Nature, Lond.*, **177**, 787–788.
- GRÜNEBERG, H. (1958*a*). Genetical studies on the skeleton of the mouse. XXIII. The development of Brachyury and Anury. *J. Embryol. exp. Morph.* **6**, 424–443.
- GRÜNEBERG, H. (1958*b*). Genetical studies on the skeleton of the mouse. XXII. The development of Danforth's short-tail. *J. Embryol. exp. Morph.* **6**, 124–148.
- HOLLANDER, W. F. (1951). Inherited persistent cloaca in adult mice. *Anat. Rec.* **111**, 477 (Abstr.)
- HOLLANDER, W. F. & STRONG, L. C. (1951). Pintail, a dominant mutation linked with brown in the house mouse. *J. Hered.* **42**, 179–182.
- NOBACK, G. J. (1916). The use of the Van Wijhe method for the staining of the cartilaginous skeleton. *Anat. Rec.* **11**, 292–294.
- PETERFI, T. (1921). Eine beschleunigte Celloidin-Paraffineinbettung mit Nelkenöl- oder Methylbenzozatcelloidin. *Z. wiss. Mikr.* **38**, 342–345.
- THEILER, K. (1951). Die Entwicklung der Zwischenwirbelscheiben bei der Short-Danforth-Maus. *Rev. suisse Zool.* **58**, 484–488.