

NASCET Percent Stenosis Semi-Automated Versus Manual Measurement on CTA

Kevin Lian, Jeremy H. White, Eric S. Bartlett, Aditya Bharatha, Richard I. Aviv, Allan J. Fox, Sean P. Symons

ABSTRACT: Purpose: To compare North American Symptomatic Carotid Endarterectomy Trial (NASCET) stenosis values and NASCET grade categorization (mild, moderate, severe) of semi-automated vessel analysis software versus manual measurements on computed tomography angiography (CTA). **Methods:** There were four observers. Two independently analyzed 81 carotid artery CTAs using semi-automated vessel analysis software according to a blinded protocol. The software measured the narrowest stenosis in millimeters (mm), distal internal carotid artery (ICA) in mm, and calculated percent stenosis based on NASCET criteria. One of these two observers performed this task twice on each carotid, the second analysis was delayed two months in order to mitigate recall bias. Two other observers manually measured the narrowest stenosis in mm, distal ICA in mm, and calculated NASCET percent stenosis in a blinded fashion. The calculated NASCET stenoses were categorized into mild, moderate, or severe. Chi square and analysis of variance (ANOVA) were used to test for statistical differences. **Results:** ANOVA did not find a statistically significant difference in the mean percent stenosis when comparing the two manual measurements, the two semi-automated measurements, and the repeat semi-automated. Chi square demonstrated that the distribution of grades of stenosis were statistically different ($p < 0.05$) between the manual and semi-automated grades. Semi-automated vessel analysis tended to underestimate the degree of stenosis compared to manual measurement. **Conclusion:** The mean percentage stenosis determined by semi-automated vessel analysis is not significantly different from manual measurement. However, when the data is categorized into mild, moderate and severe stenosis, there is a significant difference between semi-automated and manual measurements. The semi-automated software tends to underestimate the stenosis grade compared to manual measurement.

RÉSUMÉ: Mesure semi-automatisée versus manuelle du pourcentage de sténose selon les critères NASCET à l'angiographie par tomodensitométrie. Objectif: Le but de l'étude était de comparer les mesures de sténose à l'angiographie par tomodensitométrie (ACT) selon NASCET et le classement par catégories (léger, modéré, sévère) faites au moyen d'un logiciel d'analyse semi-automatisé des vaisseaux ou manuellement. **Méthode:** Quatre observateurs ont participé à l'étude. Deux observateurs ont analysé à l'insu 81 ACT carotidiennes au moyen d'un logiciel d'analyse semi-automatisée de vaisseaux. Le logiciel mesurait la sténose la plus serrée en millimètres (mm), la carotide interne distale en mm et calculait le pourcentage de sténose selon les critères NASCET. L'un de ces deux observateurs effectuait ces mesures à deux reprises au niveau de chaque carotide à deux mois d'intervalle pour minimiser le biais de rappel. Deux autres observateurs mesuraient manuellement la sténose la plus serrée en mm, la carotide interne distale en mm et calculaient le pourcentage de sténose à l'aveugle. Chaque sténose calculée selon les critères NASCET était ensuite classée comme étant légère, modérée ou sévère. Le chi-carré et l'analyse de variance (ANOVA) ont été utilisés pour déterminer s'il y avait des différences statistiques entre les deux méthodes de mesure utilisées. **Résultats:** L'ANOVA n'a pas révélé de différence significative au point de vue statistique entre les deux mesures manuelles, les deux mesures semi-automatisées et la reprise de la mesure semi-automatisée. Le chi-carré a montré que le classement des sténoses était différent au point de vue statistique ($p < 0,05$) selon que la mesure était faite par la méthode manuelle ou semi-automatisée. La méthode de mesure semi-automatisée avait tendance à sous-estimer le degré de sténose par rapport à la mesure manuelle. **Conclusion:** Le pourcentage moyen de sténose déterminé par l'analyse de vaisseaux semi-automatisée ne diffère pas de façon importante de la mesure manuelle. Cependant, quand les sténoses sont classées en légères, modérées ou sévères, il existe une différence significative au point de vue statistique entre les mesures semi-automatisées et manuelles. Le logiciel de mesure semi-automatisée tend à sous-estimer le grade de la sténose par rapport à la mesure manuelle.

Can J Neurol Sci. 2012; 39: 343-346

The quantification of extracranial internal carotid artery (ICA) stenosis is an established method of determining which patients may benefit from carotid revascularization, thus reducing the risk of ipsilateral stroke¹⁻³. It has been demonstrated that symptomatic patients with severe carotid artery stenosis (70-99%) benefit most from revascularization, while some risk reduction of ipsilateral stroke has been conferred to symptomatic patients with moderate grade lesions (50-69%)¹⁻³.

Carotid artery stenosis can be quantified using computed tomography angiography (CTA)⁴⁻⁷. The measurement of carotid

artery stenosis has traditionally been performed using North American Symptomatic Carotid Endarterectomy Trial

From the Division of Neuroradiology, Department of Medical Imaging, University of Toronto, Toronto, Ontario, Canada.

RECEIVED APRIL 20, 2011. FINAL REVISIONS SUBMITTED NOVEMBER 22, 2011.

Correspondence to: Sean P Symons, Division of Neuroradiology, Department of Medical Imaging, Sunnybrook Health Sciences Centre, University of Toronto, 2075 Bayview Avenue, AG31D, Toronto, Ontario, Canada, M4N 3M5.
Email: sean.symons@sunnybrook.ca

(NASCET) ratios^{4,8}. There are pitfalls with this method when measuring carotid stenosis on CTA. The luminal boundary is not precise on CTA, often appearing more as a halo rather than a fine boundary line. Different radiologists may measure the width of the lumen by placing calipers at different points within the halo, resulting in different absolute millimeter measurements and different calculated NASCET percent stenosis.

The evolution of semi-automated vessel analysis software allows quantification of carotid artery stenosis without manual measurements or calculations but with some limitations^{9,10}. The reproducibility of semi-automated vessel analysis has been demonstrated by previous studies to be excellent¹¹. However, its accuracy in comparison to manual measurements are unclear. The purpose of this paper is to examine the accuracy of semi-automated vessel analysis in the determining NASCET percent stenosis and in grading the severity of carotid stenosis in comparison to the manual technique.

METHODS

Inclusion criteria

Institutional research board approval was obtained. Examinations were retrospectively collected from a single institution over a six month period. All consecutive patients examined by CTA during this time period for suspected carotid artery disease were entered into the study. Examinations for trauma, dissection, or vascular anomalies were not included. One hundred and eight carotids were evaluated. Examinations where severe motion artifact prohibited accurate manual or semi-automated measurements were excluded. One case (two carotids) was excluded for this reason. Five carotid complete occlusions were excluded. Suspected ICA near-occlusions (small or collapsed distal ICAs) were identified by comparing the distal ICA axial lumen measurement to the axial lumen measurements of the contralateral distal ICA and the ipsilateral distal external carotid artery (ECA). Distal ICAs with a diameter less than or equal to 80% of the contralateral distal ICA were excluded. If the contralateral ICA was also narrowed or occluded, an ICA was excluded if both reviewers' measurement averages met the following "near-occlusion" criteria: notable bulb stenosis, distal ICA diameter of 3 mm or less, and distal ICA/distal ECA ratio of 1.25 or less. These criteria were adapted from criteria for subtle near-occlusions recognized on standard conventional angiography¹²⁻¹⁵. Twenty cases of near occlusion were excluded. A total of 81 carotid arteries were included in the final analysis.

Materials / Image Acquisition

All CTA examinations were performed using a GE Medical Systems (Waukesha, Wisconsin, USA) Lightspeed Plus 4-slice helical computed tomogram (CT) with a 6.3 MHU Performix tube. Images were obtained from C6 to vertex using the helical HS mode with 7.5 mm/rotation and 1.25 x 1.25 mm collimation (120 kVp, 350 mA). Intravenous access was via an antecubital vein using an 18 or 20 gauge angiocatheter. A total of 100 to 125 ml iohexol 300 mg/ml (Omnipaque 300, GE Healthcare, Princeton, New Jersey, USA) was injected at a rate of 4.0 to 4.5 ml/second, with a 17 second delay or the use of Smart Prep at the pulmonary artery. Computed tomography technologists performed multiplanar reformats (MPRs) at the CT operator's

console. Coronal and sagittal thick and thin MPR images were created; the thick MPRs were 10 mm thick with a 3 mm overlap. Bilateral rotational MPRs were created at the carotid bifurcations with a thickness of 7 mm and spacing by 3 mm. Three dimensional volume rendered images were created on a GE Medical Systems Advantage workstation, Version 4.2 (Waukesha, Wisconsin, USA).

Semi-automated carotid artery stenosis evaluation

Two observers (JHW and SPS) independently analyzed the carotid arteries using semi-automated vessel analysis software (GE Advantage Workstation, Advanced Vessel Analysis, Version 4.2) with a blinded protocol. One of these two observers (SPS) repeated the semi-automated carotid artery analysis at a separate sitting. The first and second measurement sessions were separated by two months in order to prevent any recall bias. For each ICA, the software determined the narrowest luminal diameter in mm, the distal ICA luminal diameter in mm, and calculated the percent stenosis based on NASCET criteria. The calculated percent stenosis for each carotid was then classified into mild (<50%), moderate (50-69%), or severe (≥70%).

For each carotid artery, the software users selected multiple points in the lumen of the distal common and internal carotid artery using the axial source images. The selected vessel lumen was subsequently mapped by the software and displayed to the user as MPRs and curved reformats. In the event of poor tracking of the vessel by the software program, reference points were reset and more reference points were selected. Reference points were also made on the MPRs in cases of poor vessel tracking. Improper vessel tracking most commonly occurred at the bulb stenosis. With densely calcified plaques, more reference points were selected through the region of the plaque. A reference point in the distal ICA was selected beyond the tapering of the carotid bulb. The software then determined the narrowest luminal diameter in mm, luminal diameter of the reference point in the distal ICA in mm, and calculated percent carotid artery stenosis. Stenosis measurement tables and the post-processed images were saved on PACS (AGFA Impax, Version 4.5, Mortsel, Belgium).

Manual carotid stenosis evaluation

Two other observers (ESB and AJF) independently measured the same carotid arteries in a blinded fashion¹. Millimeter measurements were obtained by using the submillimeter measurement and magnification tools on the PACS workstation. As in the semi-automated group, special attention was directed to some of the more densely calcified plaques to ensure accurate measurement. Windowing was used to best visualize the contrast filled lumen. Measurement of carotid stenosis was performed at the narrowest portion of the carotid bulb on the axial source data. MPRs were used to ensure true cross-sectional measurements. ICAs identified as passing oblique to the axial plane were measured perpendicular to their own oblique carotid axis as seen on MPRs. These measurements were verified with measurements from the reformats to ensure accuracy in obtaining the narrowest diameter in a true cross-sectional plane. The distal ICA was measured beyond the bulb where the walls of the vessel are parallel and no longer tapering from the carotid bulb as per NASCET. The calculated percent stenosis for each

Table: Distribution of stenoses detected by repeats of manual and semi-automated measurements

	Mild	Moderate	Severe
Manual One	42 (52%)	32 (39%)	7 (9%)
Manual Two	47 (58%)	25 (31%)	9 (11%)
Semi-automated One	64 (79%)	17 (21%)	0 (0%)
Semi-automated Two	57 (70%)	22 (27%)	2 (3%)
Semi-automated Two Repeat	56 (69%)	21 (26%)	4 (5%)

Mild: <50% stenosis. Moderate: 50-69% stenosis. Severe: >70% stenosis.

carotid was then classified into mild (<50%), moderate (50-69%), or severe (\geq 70%).

Statistical analysis

Each carotid artery was considered unique for statistical purposes. A total of five stenosis determinations were made on each carotid: Manual One, Manual Two, Semi-automated One, Semi-automated Two, and Semi-automated Two Repeat. One-way analysis of variance was used to compare the mean stenosis in these five groups. Chi-square was used to compare the stenosis categorization (mild, moderate, severe) in these five groups.

RESULTS

A total of 81 carotid arteries from 58 patients were included in the analysis. There were 41 males and 17 females. Mean age was 71 years.

The mean percentage stenosis in each group was as follows: Manual One 42 ± 31 , Manual Two 42 ± 24 , Semi-automated One 34 ± 18 , Semi-automated Two 37 ± 18 , and Semi-automated Two Repeat 38 ± 19 . There was no significant difference in the mean stenosis ($p > 0.05$), although the semi-automated tended to underestimate stenosis in comparison to the manual technique.

The distribution of stenosis grades for Manual One, Manual Two, Semi-automated One, Semi-automated Two, and Semi-automated Two Repeat are shown in the Table. Chi square found a significant difference between the five groups ($p = 0.003$). Pairwise comparisons determined significant differences between Manual One and Semi-automated One ($p < 0.001$), Manual One and Semi-automated Two ($p < 0.001$), Manual One and Semi-automated Two Repeat ($p = 0.003$), Manual Two and Semi-automated One ($p = 0.001$), Manual Two and Semi-automated Two ($p < 0.001$), and Manual Two and Semi-automated Two Repeat ($p = 0.015$). There was no significant difference when comparing Manual One to Manual Two, Semi-automated One to Semi-automated Two, Semi-automated One to Semi-automated Two Repeat, and Semi-automated Two to Semi-automated Two Repeat ($p > 0.05$).

The semi-automated method appeared to consistently underestimate the grade of stenosis compared to the manual method (Figure). Manual measurement (Manual One and Two)

had a mean of eight patients as having severe stenosis, while semi-automated measurement (Semi-automated One, Two, and Two Repeat) had a mean of two patients with severe stenosis. In the moderate category, semi-automated measurement observed a mean of 20 cases, in contrast to a mean of 29 cases identified by manual measurement. Consequently, the semi-automated measurement classified a mean of 59 patients as having mild stenosis, while the manual measurement identified a mean of 45 patients in the mild grade.

DISCUSSION

Computed tomography angiography is an accurate and reliable method of assessing carotid stenosis and is now an attractive alternative to conventional angiography⁴. Semi-automated vessel analysis software has the potential to further enhance the reliability, accuracy, and the speed of quantifying carotid stenosis. Previous studies have demonstrated that semi-automated vessel analysis has excellent intraobserver and interobserver reproducibility¹¹. Our current study has also show that the mean stenosis determined by semi-automated vessel analysis software is not significantly different from manual measurement. However, it is important to determine whether semi-automated vessel analysis software yields similar grade categorizations as manual measurement since clinical management is highly dependent on stenosis grade. In this study, the semi-automated method tended to underestimate the grade of stenosis compared to manual measurement. Although, since we did not have the gold standard control of DSA, one could argue that the manual measurement overestimated the degree of stenosis compared to semi-automated.

Bucek et al¹⁶ compared the accuracy of semi-automated CTA measurements with the results obtained from DSA as the gold standard. Although good correlation was observed, semi-automated vessel analysis had a low sensitivity (54.2%) in recognizing severe cases of stenosis. In another study, Silvennoinen et al¹⁰ suggested that semi-automated vessel

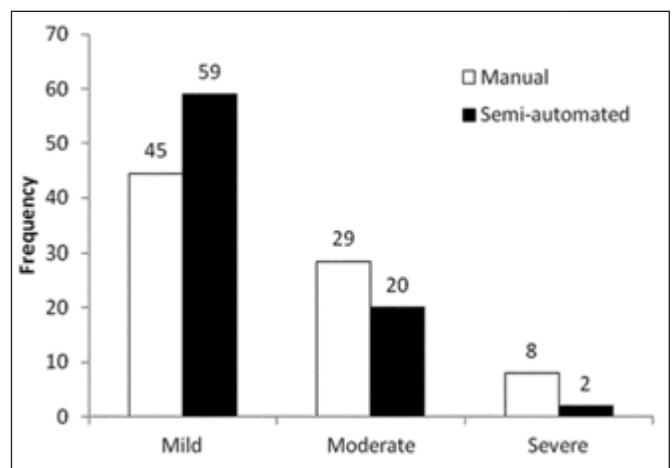


Figure: Histogram of average number of cases detected within different categories of stenosis by method of assessment.

analysis may underestimate the number of cases of both severe and moderate stenosis with respect to both manually interpreted CTA and DSA.

Our findings are congruent with these previous studies as semi-automated vessel analysis was shown to underestimate the number of cases of moderate and severe stenosis. The underestimation was especially notable for severe stenosis as only a mean of 25% of the cases were detected with the semi-automated technique. In comparison to previous studies, our study offers more robust statistical evidence of the discrepancies between manual and semi-automated measurements. Such discrepancies have important clinical implications since the indication of severe stenosis is the prime determining factor for whether patients should receive surgical or medical intervention.

The exact nature of how semi-automated vessel analysis causes underestimation is unclear. However, we noted a few possible factors that may interfere with the accuracy of the software in vessel tracking. If the software improperly tracks the vessel, the calculations can be inaccurate and unreliable. The severity of vessel stenosis and plaque burden appeared to increase the rate of poor tracking. This was thought to be secondary to a smaller density difference for the software to track the true lumen. Other interfering factors included calcification, bifurcating vessels and tortuous vessels. These problems were compensated for by placing more region of interest points along the vessel at the region of poor tracking. In our opinion, adding extra reference points on the reformats, in addition to the axial images, further increased the accuracy of vessel mapping. At regions of high-grade stenosis, magnification of the axial images before placing regions of interest was beneficial. Such potential pitfalls in semi-automated carotid analysis require that the workstation operator have a detailed knowledge of carotid anatomy.

There are potential limitations of our study. Firstly, semi-automated vessel analysis of CTA was compared solely to manual measurements of CTA and not to the gold standard DSA. This affected our ability to comment on the true accuracy of the semi-automated measurements. However, previous studies have shown a good correlation between DSA and CTA measurements of carotid stenosis^{7,10}. A second potential limitation is that vessel analysis software is provided by various vendors. Product variability may exist, although all vendors use a similar technique of vessel tracking. However, the potential product variability may impair the ability to generalize our findings. Lastly, our CTA data came from 4-slice CT scanners. Compared to 64-slice scanners, our 4-slice scanners have the same axial resolution (xy-axis resolution). The z-axis resolution is however slightly less on the 4-slice scanners. Since most carotid stenosis measurements are made in the axial plane, this difference is not likely significant.

CONCLUSION

Our results indicate that statistically significant differences exist between manual measurement grading of carotid stenosis on CTA compared to semi-automated vessel analysis. The semi-automated method tends to underestimate the grade of stenosis in comparison to manual measurement. Semi-automated vessel analysis software should be used cautiously when assessing carotid stenosis on CTA.

REFERENCES

1. North American Symptomatic Carotid Endarterectomy Trial Collaborators. Beneficial effect of carotid endarterectomy in symptomatic patients with high-grade carotid stenosis. *N Engl J Med.* 1991;325:445-53.
2. Rothwell PM, Eliasziw M, Gutnikov SA, et al. Analysis of pooled data from the randomized controlled trials of endarterectomy for symptomatic carotid stenosis. *Lancet.* 2003;361(9352):107-16.
3. Levinson MM, Rodriguez DI. Endarterectomy for preventing stroke in symptomatic and asymptomatic carotid stenosis: review of clinical trials and recommendations for surgical therapy. *Heart Surg Forum.* 1999;2(2):147-68.
4. Bartlett ES, Walters TD, Symons SP, et al. Quantification of carotid stenosis on CT angiography. *Am J Neuroradiol.* 2006;27(1):13-19.
5. Anderson GB, Ashforth R, Steinke DE, et al. CT angiography for the detection and characterization of carotid artery bifurcation disease. *Stroke.* 2000;31(9):2168-74.
6. Randoux B, Marro B, Koskas F, et al. Carotid artery stenosis: prospective comparison of CT, three-dimensional gadolinium-enhanced MR, and conventional angiography. *Radiology.* 2001;220(1):179-85.
7. Leclerc X, Godefroy O, Pruvo JP, et al. Computed tomographic angiography for the evaluation of carotid artery stenosis. *Stroke.* 1995;26(9):1577-81.
8. Zhang Z, Berg M, Ikonen A, et al. Carotid stenosis degree in CT angiography: assessment based on luminal area versus luminal diameter measurements. *Eur Radiol.* 2005;15(11):2359-65.
9. Zhang Z, Berg MH, Ikonen AE, et al. Carotid artery stenosis: reproducibility of automated 3D CT angiography analysis method. *Eur Radiol.* 2004;14(4):665-72.
10. Silvennoinen HM, Ikonen S, Soinnie L, et al. CT angiographic analysis of carotid artery stenosis: comparison of manual assessment, semiautomatic vessel analysis, and digital subtraction angiography. *Am J Neuroradiol.* 2007;28(1):97-103.
11. White JR, Bartlett ES, Bharatha A, et al. Reproducibility of semi-automated measurement of carotid stenosis on CTA. *Can J Neuro Sci.* 2010;37(4):498-503.
12. Fox AJ, Eliasziw M, Rothwell PM, et al. Identification, prognosis, and management of patients with carotid artery near occlusion. *Am J Neuroradiol.* 2005;26(8):2086-94.
13. Fox AJ. How to measure carotid stenosis. *Radiology.* 1993;186(2):316-18.
14. Dix JE, McNulty BJ, Kalimes DF. Frequency and significance of a small distal ICA in carotid stenosis. *Am J Neuroradiol.* 1998;19(7):1215-18.
15. Bartlett ES, Walters TD, Symons SP, et al. Diagnosing carotid stenosis near-occlusion by using CT angiography. *Am J Neuroradiol.* 2006;27(3):632-7.
16. Bucek RA, Puchner S, Kanitsar A, et al. Automated CTA quantification of internal carotid artery stenosis: a pilot trial. *J Endovasc Ther.* 2007;14:70-6.