

## Immunoglobulins anti-*Anisakis simplex* in patients with gastrointestinal diseases

R. Gutiérrez and C. Cuéllar\*

Departamento de Parasitología, Facultad de Farmacia, Universidad Complutense, 28040 Madrid, Spain

### Abstract

The nematode *Anisakis simplex* causes anisakidiasis, a disease that often mimics other gastrointestinal diseases. Patients with digestive haemorrhaging, Crohn's disease, digestive cancer and appendicitis were analysed for antibodies to *A. simplex*. Antibody detection was carried out by enzyme-linked immunosorbent assay (ELISA) and immunoblotting using crude extract (CE) antigen and excretory-secretory (ES) products. Total immunoglobulin (Igs), IgG, IgM, IgA and IgE were studied. The highest percentage was obtained when Igs were tested against CE antigen. A higher percentage of positivity was observed with the appendicitis group. The Crohn's disease group showed the highest levels of IgG against the ES antigen. Using immunoblotting, 24% and 48% of sera from patients with symptoms of Crohn's disease and digestive haemorrhaging, respectively, showed a positive immunorecognition pattern of CE antigen. The prevalence of detectable antibodies against *A. simplex* is higher in patients with digestive disorders than in the healthy population. A linear correlation was observed between prothrombin activity and Igs-CE, IgA-CE and IgA-ES but not between IgE-CE and the other immunoglobulin levels. Specific IgA is associated with a higher activity index of Crohn's disease. Specific antibodies were observed against *A. simplex* in patients with appendicitis and gastrointestinal cancer, indicating a higher rate of positivity for IgA.

### Introduction

Anisakidiasis is a human disease caused by accidental ingestion of larval nematodes belonging to the family Anisakidae, especially *Anisakis simplex*. Infection is acquired by ingesting raw or undercooked fish and squid (Sakanari & McKerrow, 1989). Ishikura *et al.* (1993) divided anisakidiasis into gastric, intestinal and heterologous anisakidiasis (ectopic anisakidiasis), based on the location of lesions. The disease is often misdiagnosed as appendicitis, acute abdomen, gastric tumour or cancer, ileitis, cholecystitis, diverticulitis, tuberculous peritonitis, pancreatic cancer or Crohn's disease (Sakanari & McKerrow, 1989). The aetiology of Crohn's disease is unknown. Thayer (1987) and Kornbluth *et al.* (1993)

suggested that toxic microbial products, dietary, viral and/or infectious factors produce clinical symptoms, confirmed by endoscopy, similar to that of Crohn's disease. Parasitic diseases, such as schistosomiasis, amoebiasis and balantidiasis have also been incriminated (Dodd, 1991; Kornbluth *et al.*, 1993). Hayasaka *et al.* (1971), reported that of 1531 cases initially diagnosed as acute regional ileitis, 140 were due to helminth infections, especially *Anisakis*, while 622 cases demonstrated a phlegmonous reaction with eosinophilia possibly caused by *Anisakis*. This apparently self-perpetuating granulomatous lesion has been identified by Richman & Lewicki (1973) as a cause of right ileocolitis secondary to anisakidiasis.

In patients with stomach anisakidiasis, occult blood is often present in the gastric juice or faeces (Bier *et al.*, 1987). Oshima (1972) and Van Thiel (1976) suggested that occult blood may also be present in intestinal anisakidiasis. Larval ES products have been shown to have inhibitory or

\*Author for correspondence  
Fax: 00 34 91 3941815  
E-mail: cuellarh@farm.ucm.es

anticoagulant properties by prolonging coagulation times suggesting an alteration of one of the coagulation proteins namely factors Xa, IIa or Va (Perteguer *et al.*, 1996).

As Spain is a country with an elevated rate of fish ingestion (78.2 g per person per day) (ENNA, 1995), the true incidence and prevalence of anisakidiasis in Spain is likely to be greater than previously described by Arenal *et al.* (1991), López-Vélez *et al.* (1992), Valero *et al.* (1992) and Clavel *et al.* (1993). García-Palacios *et al.* (1996) in their study of seroprevalence using ELISA and immunoblotting with crude larval extracts of *A. simplex* against human sera from Spanish people showing no clinical suspicion of anisakidiasis obtained 6% with detectable antibody values. More recently, reports of other cases human anisakidiasis have been published in Spain (Cruchaga *et al.*, 1995; Martín *et al.*, 1996; Canut *et al.*, 1996; Acebes *et al.*, 1996; Rodríguez *et al.*, 1996; Romeo *et al.*, 1997; Daschner *et al.*, 1997, 1999; Olveira *et al.*, 1999; Domínguez *et al.*, 2000; Esteve *et al.*, 2000; C. López *et al.*, 2000; D. López *et al.*, 2000).

In the present paper we investigate the levels of specific antibodies against larval antigens of *A. simplex* in sera from patients previously diagnosed with a variety of digestive diseases to determine the relationship between specific antibody levels and activity, location and/or status.

## Materials and methods

### *Patients and serum samples*

Nineteen patients, under the care of the gastroenterology service of the Hospital La Paz, Madrid, with digestive haemorrhaging were selected for this study between 1996 and 1997. Thirty patients with Crohn's disease, together with four and five sera from patients with digestive cancer or appendicitis, were also selected for this study from January to July 1997. All Crohn's disease patients, were diagnosed using clinical, radiological, endoscopic and histopathological criteria, according to Lennard-Jones (1989). Disease activity was measured using the Harvey-Bradshaw Index (Harvey & Bradshaw, 1996). For each patient, the history of the disease, location and treatment with or without immunosuppressive therapy, were recorded.

For all patients, the following laboratory factors were analysed: leukocytes, eosinophils, haemoglobin, partial thromboplastin time (PTT), prothrombin time (PT), fibrinogen, platelets and erythrocyte sedimentation rate.

Human serum E17 (anisakidiasis reference serum) was supplied by the Contrôle National de Qualité en Parasitologie (Département de Biologie Médicale 'E. Brumpt', Centre Hospitalier, 95500 Gonesse, France). The serum of reference E17 was obtained two months post-infection and tested by Western-blot, immunoelectrophoresis and the Ouchterlony test (Petithory *et al.*, 1992).

### *Anisakis simplex antigen preparation*

Third stage larvae (L3) of *A. simplex* were extracted from the blue whiting, *Micromesistius poutassou*. For the preparation of the crude extract (CE), L3 were placed in a

phosphate buffer saline (PBS) comprising 0.01 M sodium phosphate and 0.15 M NaCl and was homogenized following sonication (Virsonic 5, Virtis). The homogenate was extracted in PBS at 4°C overnight, delipidized with n-hexane, centrifuged (Biofuge 17RS, Heraeus Sepatech) and the supernatant dialysed (García-Palacios *et al.*, 1996). To obtain excretory-secretory (ES) products, viable L3 were placed in Minimum Essential Eagle Medium with Earle's salts (ICN Biomedicals, Inc. Costa Mesa, California) supplemented with sodium bicarbonate (2.2 g l<sup>-1</sup>), glutamine (0.292 g l<sup>-1</sup>) and gentamicin (4 g l<sup>-1</sup>) and maintained at 28°C. Supernatants were collected weekly and dialysed (Perteguer *et al.*, 1996).

## ELISA

Each of 96-well microtitre plates (Nunc-Immuno Plate PoliSorp™) was sensitized by the addition of 0.1 µg per well of larval CE or ES antigens. Wells were blocked by the addition of 0.1% bovine serum albumin (BSA) in PBS. Affinity isolated, peroxidase conjugated, goat anti-human immunoglobulins (Igs) (gamma, alpha, mu and light chains), IgG (gamma), IgM (mu) and IgA (alpha) (CALTAG Laboratories) at the appropriate dilution in PBS-Tween, 0.1% BSA, were incubated. After washing, substrate (o-phenylene-diamine; SIGMA) was added at 0.04% in phosphate-citrate buffer (pH 5.0) with 0.04% hydrogen peroxide. The reaction was stopped with 3 N sulphuric acid and the plates read at 492 nm. Simultaneously, an ELISA without antigen was used as a control (García *et al.*, 1996). For evaluation of the results we used the Diagnostic Index (DI) as the ratio between the optical density (O.D.) of the test serum and the O.D. of the negative control once its corresponding non-specific reaction with BSA used in the postcoating was subtracted (García-Palacios *et al.*, 1996). For Igs, IgG, IgM and IgA DI lower than 1.49 was considered negative and equal or higher than 1.5 positive.

### *ELISA for IgE determination*

Plates were coated with 1 µg CE antigen per well. Test serum, at the dilution 1/2 was added in duplicate. A murine monoclonal antibody against an epsilon human IgE chain (IgG1κ, E21A11; INGENASA, Madrid, Spain) was added and incubated, followed by a goat anti-mouse IgG1 (gamma) horseradish peroxidase conjugate (CALTAG Laboratories, Burlingame, California). The following steps were performed as described in the previous ELISA method. Diagnostic indices equal or higher than 2.5 were estimated as positive (Gutiérrez *et al.*, 2000).

### *Immunoblotting analysis*

Sodium dodecylsulphate-polyacrylamide gel electrophoresis (SDS-PAGE) was carried out using a Mini Protean® II cell (Bio Rad). Gels consisted of a 4% stacking gel and a 5–20% linear gradient separating gel. Larval CE antigen was dissolved in a sample buffer (50 mM Tris-HCl buffer, pH 8.6, containing 2% SDS, 20% glycerol and 0.02% bromophenol blue) diluted 1:1 in electrode buffer (25 mM Tris, 192 mM glycine, pH 8.3), containing 1% SDS.

Electrophoresis was performed and protein bands were transferred onto a 0.22  $\mu\text{m}$  pore size nitrocellulose membrane (Pharmacia) in a Multiphor II Nova Blot semi-dry transfer cell (Pharmacia) with 48 mM Tris, 39 mM glycine, 0.037% SDS and 20% methanol, pH 9.2. The membrane was cut into strips and each strip was blocked with PBS containing 5% non-fat dry milk, prior to immunorecognition by incubation with sera diluted at 1/50 in PBS-Tween containing 1% non-fat dry milk. Each strip was then incubated with affinity isolated, peroxidase conjugated, goat anti-human immunoglobulins (gamma, alpha, mu and light chains), IgG (gamma), IgM (mu) and IgA (alpha). To visualize bands, strips were reacted with the substrate (PBS, containing 0.006%  $\text{H}_2\text{O}_2$ :methanol, containing 0.03% 4-chloro-1-naphthol) (García-Palacios *et al.*, 1996).

### Statistical analysis

Data were analysed with SPSS/PC software using an one-way ANOVA test. Multiple statistical comparisons post-hoc were realized with the Scheffé method. Correlation coefficients were also determined by the Pearson test. *P* values <0.05 were considered to be statistically significant.

### Results

A total of 57 patients, with Crohn's disease (30), digestive haemorrhaging (19), digestive cancer (4) and appendicitis (5), were examined. There was no previous diagnosis or no evidence of a current *Anisakis* infection. All sera were previously selected using ELISA against the CE antigen of *A. simplex*. The 57 sera showed DIs greater than 1.4 for total immunoglobulin responses. The mean patient age was  $42.38 \pm 17.60$ , including those with Crohn's disease ( $37.22 \pm 11.48$ ), digestive haemorrhaging ( $54.27 \pm 15.85$ ), cancer ( $71.33 \pm 5.68$ ) and appendicitis ( $24.80 \pm 4.65$ ). Mean values of DI or O.D. in each immunoglobulin group are shown in table 1, and prevalence values in table 2. The highest percentage was obtained when Igs were tested against CE antigen. Higher percentages of positivity were observed with the

Table 2. Prevalence (%) of detectable antibodies against *Anisakis simplex* in 57 patients with gastrointestinal disorders.

Immunoglobulin	N	%
Igs-CE	51	89.4
IgG-CE	43	75.4
IgM-CE	15	26.3
IgA-CE	36	63.1
IgE-CE	8	14.0
Igs-ES	28	49.1
IgG-ES	33	57.8
IgM-ES	13	22.8
IgA-ES	33	57.8

Diagnostic Index  $\geq 1.5$  for Igs, IgG, IgM and IgA; DI  $\geq 2.5$  for IgE-CE. N, number of patients with detectable antibodies; CE, crude extract; ES, excretory-secretory.

appendicitis group (figs 1 and 2), though these were not statistically significant. However, by testing IgG against the ES antigen significant differences ( $P < 0.05$ ) were observed when the appendicitis group was compared with the digestive haemorrhaging and Crohn's disease groups. The latter group showed the highest levels of this specific isotype (fig. 2).

When selected sera were tested using immunoblot analysis against the CE larval antigen, 24% and 48% of sera from patients with Crohn's disease and haemorrhage, respectively, showed an immunorecognition pattern markedly similar to the human anisakidiasis reference serum. Likewise, 20% of sera from patients with Crohn's disease and 24% with digestive haemorrhaging reacted with antigenic proteins of a high molecular weight approximately between 50 and 250 kDa, with a band of about 70 kDa being observed in all cases. Finally, 28% of sera from patients with Crohn's disease and 8% with digestive haemorrhaging only showed a reaction with antigenic proteins of a high molecular weight.

Leukocytes, eosinophils, haemoglobin, PT, fibrinogen, platelets and erythrocyte sedimentation rates were analysed for each group depending upon the diagnosis. Haemoglobin was less significant in patients with digestive haemorrhaging than in those with appendicitis. Leukocytes were significantly higher in patients with

Table 1. Mean Diagnostic Index values ( $\pm$ SD) of patient sera tested with indirect ELISA against *Anisakis simplex* antigens.

DI	Groups					Total
	1	2	3	4		
Igs-CE	$1.9 \pm 0.4$	$1.9 \pm 0.4$	$1.8 \pm 0.2$	$1.9 \pm 0.4$	$1.8 \pm 0.4$	
IgG-CE	$1.9 \pm 0.4$	$1.4 \pm 0.5$	$2.2 \pm 0$	$1.4 \pm 0.5$	$1.7 \pm 0.6$	
IgM-CE	$1.2 \pm 0.4$	$1.0 \pm 0.8$	$1.0 \pm 0.6$	$1.6 \pm 1.2$	$1.1 \pm 0.6$	
IgA-CE	$1.7 \pm 0.45$	$1.6 \pm 0.7$	$1.5 \pm 0.8$	$1.0 \pm 0.7$	$1.7 \pm 0.8$	
IgE-CE	$0.9 \pm 0.4$	$1.9 \pm 2.6$	$0.8 \pm 0.6$	$1.5 \pm 1.2$	$1.2 \pm 1.6$	
Igs-ES	$1.2 \pm 0.3$	$1.2 \pm 0.4$	$0.7 \pm 0.1$	$1.8 \pm 0.8$	$1.2 \pm 0.5$	
IgG-ES	$1.6 \pm 0.6$	$1.6 \pm 0.5$	$1.4 \pm 0.3$	$3.6 \pm 3.4$	$1.8 \pm 1.2$	
IgM-ES	$1.5 \pm 0.5$	$0.8 \pm 0.5$	$1.0 \pm 0.1$	$1.3 \pm 0.3$	$1.0 \pm 0.6$	
IgA-ES	$1.8 \pm 0.7$	$2.2 \pm 1.1$	$1.2 \pm 0.4$	$2.4 \pm 2.1$	$1.8 \pm 1.3$	

DI, Diagnostic Index; 1, Crohn's disease; 2, digestive haemorrhaging; 3, cancer; 4, appendicitis; CE, crude extract; ES, excretory-secretory antigen.

Crohn's disease and appendicitis when compared with patients with digestive haemorrhaging. In the latter group, prothrombin activity was also significantly less than in the other patient groups. Finally, platelets were significantly higher in patients with Crohn's disease compared with patients with digestive haemorrhaging.

When the 57 patients were analysed using the Pearson's correlation coefficient, no linear correlation between Igs-CE and IgG-CE and the other immunoglobulin levels tested was observed. After studying the clinical variables in these patients, a linear correlation was observed between Igs-CE levels and patient age and eosinophilia. Using Pearson's correlation coefficient on the Crohn's disease group, no linear correlation was observed between IgE-CE and the other immunoglobulin levels. In this group we observed correlations between patient age and IgA-CE; disease history and IgA-CE levels; location of the disease and Igs-CE, IgG-CE and IgE-CE levels; disease activity index and IgA-ES levels; eosinophils and Igs-CE levels; fibrinogen and Igs-ES, IgG-ES and IgM-ES levels and prothrombin activity and IgA-ES levels. In the digestive haemorrhaging group, no linear correlation between IgG-CE levels and other immunoglobulins studied was observed. With reference to immunoglobulin levels and clinical variables, linear correlations were observed between fibrinogen and IgM-CE; haemoglobin and IgG-ES; prothrombin activity and Igs-CE, IgA-CE and IgA-ES, and erythrocyte sedimentation rates and Igs-CE levels. In the case of the cancer and appendicitis groups, linear correlations between patient age and Igs-CE levels, and leukocytes and IgE-CE and Igs-ES levels were observed.

## Discussion

Intestinal anisakidiasis and Crohn's disease are similar in many respects, due to their granulomatous inflammatory characteristics and their preference to locate at the ileocolon. In the present study, 30 patients diagnosed with Crohn's disease were studied and a number of questions arise to explain the high prevalence of specific detectable antibodies in these patients. None of the Crohn's disease patients were under specific dietetic advice, except for the stenotic ileal forms where fibre intake was restricted, nor were patients under any anti-inflammatory treatment. We believe the most probable explanation rests with intestinal permeability and a mucosal barrier. The higher prevalence of specific antibodies against *Anisakis* could be considered a phenomenon of increased permeability. In fact, circulatory antibodies to a range of commensal bacteria have been reported in inflammatory bowel disease (Dalton & Jewell, 1992). On the other hand, lesions caused by a number of parasites can mimic Crohn's disease (Wayne & Hunt, 1982; Meybehm *et al.*, 1989; Liacouras *et al.*, 1993). Right ileocolitis secondary to anisakiasis has been demonstrated by Richman & Lewicki (1973) who considered *A. simplex* larvae in the aetiology of Crohn's disease. Correlations were observed between IgA levels and Crohn's disease activity index. Akao *et al.* (1990) demonstrated that IgA antibodies responses were more specific than IgG antibodies in anisakiasis. In Crohn's disease patients, *Anisakis* antigens could lead to

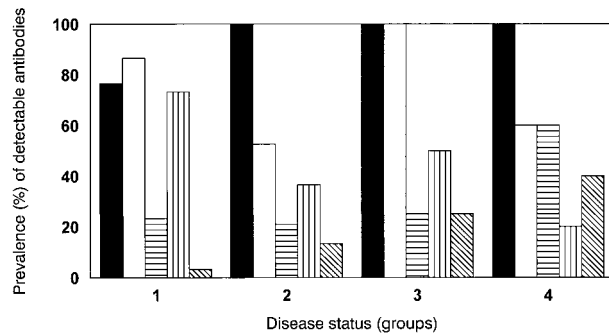


Fig. 1. The prevalence (%) of detectable antibodies against CE *Anisakis simplex* antigen in groups of patients with Crohn's disease (1), digestive haemorrhaging (2), cancer (3) and appendicitis (4). ■, Igs; □, IgG; ▨, IgM; ▩, IgA; ▭, IgE.

the local secretion of specific antibodies which cross-react with intestinal epithelial cell antigens leading to the development of local cell-mediated responses and further cell damage. Furthermore, cytokines produced by activated macrophages, such as interleukin (IL)-1, IL-6 and tumour necrosis factor, are significantly elevated in Crohn's disease, and Th1 cytokines IL-2 and interferon may be abnormally elevated or decreased according to the history of the disease (Strober *et al.*, 1997). It is important to consider whether an aetiological disease agent, such as *A. simplex*, may modulate the T helper (Th)1-Th2 dichotomy for its own benefit. Cuéllar *et al.* (1998) observed that *A. simplex* products inhibited nitric oxide production in bacterial lipopolysaccharide-treated J774 macrophages. The antigen-specific immune response of the immunocompetent host can generate the requisite cytokines in response to specific *A. simplex* antigens and could induce nitric oxide in proximity to the parasite. Although these implications in the pathology of human anisakidiasis are limited, they suggest an immune evasion mechanism by which *A. simplex* can evade the toxic effect of nitric oxide, indicating that parasite proteins may interfere with the ability of macrophages to respond to activating signals decreasing pro-inflammatory cytokines. However, larval antigens could control mucosal inflammation in an attempt to avoid larval expulsion, which is a parasitic failure as humans are

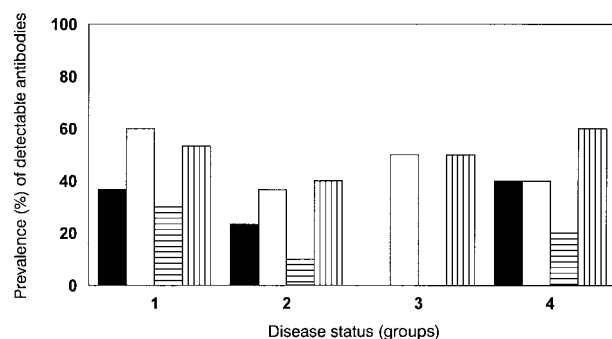


Fig. 2. The prevalence (%) of detectable antibodies against ES *Anisakis simplex* antigen in groups of patients with Crohn's disease (1), digestive haemorrhaging (2), cancer (3) and appendicitis (4). ■, Igs; □, IgG; ▨, IgM; ▩, IgA; ▭, IgE.

abnormal hosts. However, at present, we are unable to ascertain whether *A. simplex* contributes to the development of pathogenesis in Crohn's disease.

In the present paper we have also investigated the relationship between gastrointestinal tract bleeding episodes and specific detectable antibodies anti-*A. simplex*. A high prevalence of specific detectable antibodies in patients with digestive haemorrhaging can be explained because the lesions caused by parasites can mimic ulceration and other gastrointestinal diseases. In Spain, *Pseudoterranova decipiens* larval infections have been reported to mimic a chronic peptic ulcer (López *et al.*, 1992). Likewise, according to Domingues *et al.* (1993), there is a correlation between the degree of liver fibrosis and varices, and the risk of haemorrhaging is correlated with the degree of liver fibrosis and the presence of *Schistosoma mansoni* in patients. Rolachon *et al.* (1996) reported *S. mansoni* colonic infection in a patient presenting exclusively with recurrent episodes of serious gastrointestinal haemorrhaging without hepatic lesions. Overstreet & Meyer (1981) observed haemorrhagic lesions in the stomach and proximal duodenum of monkeys following infection with the nematode *Hysterothylacium* type MB. As *A. simplex* products contain an inhibitory or anticoagulant property (Perteguer *et al.*, 1996), it is interesting to note that linear correlations were found between levels of fibrinogen, haemoglobin and prothrombin activity and specific antibody levels. In addition, some of the positive sera from haemorrhaging patients, when tested using immunoblot analysis, showed an immunorecognition pattern markedly similar to the human anisakidiasis reference serum. Whether an abnormal response to parasite antigens or the parasite itself initiated this process requires further investigation.

Finally, a small group of nine patients with either cancer or appendicitis was studied, in which linear correlations between leukocytes and IgE levels were observed. It is interesting to note that one gangrenous appendicitis patient showed the following results: Igs-CE (1.6), IgG-CE (1.7), IgM-CE (0.6), IgA-CE (2.3), IgE-CE (3.0), Igs-ES (3.0), IgG-ES (8.1), IgM-ES (1.8) and IgA-ES (6.0). The first case of human anisakidiasis published in Spain was reported by Arenal *et al.* (1991). It was a case of acute abdomen due to appendicular lumen occlusion by *Anisakis* larvae. Likewise, Valero *et al.* (1992) identified larvae of *A. simplex* following surgical intervention of a patient with a clinical suspicion of peritonitis. Finally, a case of anisakidiasis was reported by Clavel *et al.* (1993) in which a living *Anisakis physeteris* larva was found in the abdominal cavity of a woman. Cancrini *et al.* (1997) described the case of a patient with severe pain in the ileocecal region, and a diagnosis of acute appendicitis led to an appendectomy. Since Spain is a country with an elevated rate of fish ingestion (78.2 g per person per day) (ENNA, 1995) and the symptoms of anisakidiasis frequently imitate an attack of acute appendicitis, *Anisakis* larvae should be considered in the diagnosis of appendicitis and other intestinal diseases.

### Acknowledgements

We wish to thank Dr J.C. Petithory for the E17 reference

serum from a patient infected with *Anisakis*. This research was supported by PR295/95-6074 (Universidad Complutense) and SAF98-0072 (Comisión Interministerial de Ciencia y Tecnología).

### References

- Acebes, J.M., Fernández, P., Díaz, G., Velicia, R., González, J.M. & Citores, R. (1996) Dos casos de anisakiasis en Hospital del Río Hortega (Valladolid). *Revista Española de Enfermedades Digestivas* **88**, 59–60.
- Akao, N., Ohyama, T.A. & Kondo, K. (1990) Immunoblot analysis of serum IgG, IgA and IgE responses against larval excretory-secretory antigens of *Anisakis simplex* in patients with gastric anisakiasis. *Journal of Helminthology* **64**, 310–318.
- Arenal, J., Marcos, I., Borrego, M., Bowman, W., Castro, J. & Blanco, J. (1991) Anisakiasis como causa de apendicitis aguda y cuadro reumatológico: primer caso en la literatura médica. *Revista Española de Enfermedades Digestivas* **79**, 355–358.
- Bier, J.W., Deardorff, T.L., Jackson, G.J. & Raybourne, R.B. (1987) Human anisakiasis. *Bailliere's Clinical Tropical Medicine and Communicable Diseases* **2**, 723–733.
- Cancrini, G., Magro, G. & Giannone, G. (1997) First case of extra-gastrointestinal anisakiasis in a human diagnosed in Italy. *Parassitologia* **39**, 13–17.
- Canut, A., Lobora, A., López, J. & Romero, J.A. (1996) Anisakiosis gástrica aguda por cocción insuficiente en horno microondas. *Medicina Clínica* **106**, 8.
- Clavel, A., Delgado, B., Sánchez, C., Carbonell, E., Castillo, J., Ramírez, J., Quílez, J., Gómez, R. & Kagei, N. (1993) A live *Anisakis physeteris* larva found in the abdominal cavity of a woman in Zaragoza, Spain. *Japanese Journal of Parasitology* **5**, 445–448.
- Cruchaga, S., Pascual, J., Muñoz, F., Guerra, A. & Ladrón de Guevara, C. (1995) Hallazgo endoscópico de una larva de gusano en el fondo de úlcera gástrica. *Enfermedades Infecciosas y Microbiología Clínica* **13**, 631–632.
- Cuellar, C., Perteguer, M.J. & de las Heras, B. (1998) Effects of *Anisakis simplex* on nitric oxide production in J774 macrophages. *Scandinavian Journal of Infectious Diseases* **30**, 603–606.
- Dalton, H.R. & Jewell, D.P. (1992) The immunology of inflammatory bowel disease. pp. 127–147 in Jannerot, G., Lennard-Jones, J. & Truelove, S. (Eds) *Inflammatory bowel disease*. Malmö, Corona.
- Daschner, A., Alonso, A., Mora, C., Moreno, A., Villanueva, R. & López, C. (1997) Anisakiasis gastroalérgica con parasitación masiva. *Revista Española de Alergología e Inmunología Clínica* **12**, 370–372.
- Daschner, A., Alonso, A., Caballer, T., de Parga, J.M. & López, C. (1999) Usefulness of early serial measurement of specific and total immunoglobulin E in the diagnosis of gastro-allergic anisakiasis. *Clinical and Experimental Allergy* **29**, 1260–1264.
- Dodd, L.G. (1991) *Balantidium coli* infestation as a cause of acute appendicitis. *Journal of Infectious Diseases* **163**, 1392.
- Domingues, A., Lima, A., Dias, H. & Laso, G. (1993) An ultrasonographic study of liver fibrosis in patients

- infected with *Schistosoma mansoni* in north-east Brazil. *Transactions of the Royal Society of Tropical Medicine and Hygiene* **87**, 556–568.
- Domínguez, J., Cimarra, M., Sevilla, M., Alonso, A., Moreno, T. & Martínez, C. (2000) *Anisakis simplex*: a case of intestinal pseudo-obstruction. *Revista Española de Enfermedades Digestivas* **92**, 132–139.
- ENNA (1995) Encuesta de Presupuestos Familiares 1990–91. Estudio Nacional de Nutrición y Alimentación 1991. Madrid, INI.
- Esteve, C., Resano, A., Díaz, P. & Fernández, M. (2000) Eosinophilic gastritis due to *Anisakis*: a case report. *Allergologie et Immunopathologie (Madrid)* **28**, 21–23.
- García-Palacios, L., González, M.L., Esteban, M.I., Mirabent, E., Perteguer, M.J. & Cuéllar, C. (1996) Enzyme-linked immunosorbent assay, immunoblot analysis and RAST fluoroimmunoassay analysis of serum responses against crude larval antigens of *Anisakis simplex* in a Spanish random population. *Journal of Helminthology* **70**, 281–289.
- Gutiérrez, R., Guillén, R., Madero, R. & Cuéllar, C. (2000) Digestive haemorrhage in patients with anti-*Anisakis* antibodies. *European Journal of Gastroenterology and Hepatology* **12**, 337–343.
- Harvey, R.F. & Bradshaw, J.M. (1996) A simple index of Crohn's disease activity. *Lancet* **347**, 214–219.
- Hayasaka, H., Ishikura, H. & Takayama, J. (1971) Acute regional ileitis due to *Anisakis* larvae. *International Surgery* **55**, 8–14.
- Ishikura, H., Kikuchi, K., Nagasawa, K., Ooiwa, T., Takamiya, H., Sato, N. & Sugane, K. (1993) Anisakidae and anisakidosis. pp. 43–102 in Sun, T. (Ed.) *Progress in clinical parasitology*. Vol. III. New York, Springer-Verlag.
- Kornbluth, A., Salomon, P. & Sachar, D.B. (1993) Crohn's disease. pp. 1270–1304 in Sleisenger, M.H. & Fordtran, J.S. (Eds) *Gastrointestinal disease*. Philadelphia, Saunders.
- Lennard-Jones, J.E. (1989) Classification of inflammatory bowel disease. *Scandinavian Journal of Gastroenterology* **24**, 2–6.
- Liacouras, C.A., Bell, L.M., Aljabi, M.C. & Piccoli, D.A. (1993) *Angiostrongylus costaricensis* enterocolitis mimics Crohn's disease. *Journal of Pediatric Gastroenterology and Nutrition* **16**, 203–207.
- López, D., Ramírez, L.M., del Rosal, R., López, F., Fernández, R. & Mino, G. (2000) Study of 13 cases of anisakiasis in the province of Cordoba. *Medicina Clínica (Barcelona)* **114**, 177–180.
- López, C., Gómez, A., Daschner, A., Moreno, A., de Parga, J.M., Caballero, T., Barranco, P. & Cabanas, R. (2000) Gastroallergic anisakiasis: findings in 22 patients. *Journal of Gastroenterology and Hepatology* **15**, 503–506.
- López-Vélez, R., García, A., Barros, C., Manzabettia, F. & Oñate, J.M. (1992) Anisakidosis en España. Descripción de tres casos. *Enfermedades Infecciosas y Microbiología Clínica* **10**, 158–161.
- Martín, J.C., Cuesta, C., Vaquero, C., Díez, L.M. & Said, M.A. (1996) Obstrucción intestinal por anisakiosis. Aportación de dos nuevos casos. *Cirugía Española* **59**, 174–176.
- Meybehm, M., Dworak, O. & Gugler, R. (1989) Granulomatous colitis with pseudopolyp in schistosomiasis. *Deutsche Medizinische Wochenschrift* **114**, 19–22.
- Olveira, A., Sánchez, S., Conde, P., Moreno, A., Martínez, A. & Comas, C. (1999) Gastrointestinal anisakiasis. Seven cases in three months. *Revista Española de Enfermedades Digestivas* **91**, 70–72.
- Oshima, T. (1972) *Anisakis* and anisakiasis in Japan and adjacent areas. pp. 301–393 in Morishita, K., Komiya, Y., Matsubayashi, H. (Eds) *Progress in medical parasitology in Japan*. Tokyo, Meguro Parasitological Museum.
- Overstreet, R. & Meyer, G. (1981) Hemorrhagic lesions in stomach of rhesus monkey caused by a piscine ascarid nematode. *Journal of Parasitology* **87**, 226–235.
- Perteguer, M.J., Raposo, R. & Cuéllar, C. (1996) *In vitro* study on the effect of larval excretory-secretory products and crude extracts from *Anisakis simplex* on blood coagulation. *International Journal for Parasitology* **26**, 105–108.
- Petithory, J.C., Verrier, F. & Guyet-Rousset, P. (1992) Biological study of a case of colonic anisakiasis. Review of the literature. *Pathology and Biology* **40**, 47–51.
- Richman, R.H. & Lewicki, A.M. (1973) Right ileocolitis secondary to anisakiasis. *American Journal of Roentgenology, Radium Therapy and Nuclear Medicine* **119**, 329–331.
- Rodríguez, J.M., Muñoz, E., Roset, F., Tresserres, F., Sala, A., Veloso, E. & Marco, C. (1996) Anisakiasis, una causa infrecuente de abdomen agudo. *Cirugía Española* **60**, 74–76.
- Rolachon, A., Malaval, T., Martin, J., Granger, P., Palloux, H., Fourmet, J. & Hostein, J. (1996) Hémorragie digestive grave et récidivante: une forme exceptionnelle de bilharziose colique. *Gastroenterologie et Clinique Biologie* **20**, 693–695.
- Romeo, J.A., Martínez, A.E., Olivares, U., Sancha, A., López, J., Barros, J. & Echavarri, J. (1997) Gastric anisakiasis diagnosed by endoscopy. *Gastroenterology and Hepatology* **20**, 306–308.
- Sakanari, J.A. & McKerrow, J.H. (1989) Anisakiasis. *Clinical Microbiological Reviews* **2**, 278–284.
- Strober, W., Kelsall, B., Fuss, I., Marth, T., Ludviksson, B., Ehrhardt, R. & Neurath, M. (1997) Reciprocal IFN-g and TGF-b responses regulate the occurrence of mucosal inflammation. *Immunology Today* **18**, 61–64.
- Thayer, W.R. (1987) Infectious agents in inflammatory bowel disease. pp. 101–108 in Jannerot, E.D. (Ed.) *Inflammatory bowel disease*. New York, Raven Press.
- Valero, A., Mira, J., Pérez, R., Sanz, J., Geraldía, M., García, J., García, P. & Adroher, E. (1992) Descripción de un caso de anisakiosis humana. IX Reunión Científica de la Asociación de Parasitólogos Españoles.
- Van Thiel, P.H. (1976) The present state of anisakiasis and its causative worms. *Tropical and Geographical Medicine* **28**, 75–85.
- Wayne, J.D. & Hunt, R.H. (1982) Colonoscopic diagnosis of inflammatory bowel disease. *Surgery North America* **62**, 905–913.

(Accepted 19 September 2001)

© CAB International, 2002