

and environmental screening was performed in several units. Processes of catheter care in the hemodialysis unit were reviewed. Water samples from the hemodialysis unit, and samples of solutions used in patient care were sent for culture. Isolates from patients and from environmental samples were sent for 16S rRNA gene sequencing to determine genetic relatedness. **Results:** In total, 16 patients, 8 of whom were male, developed *B. cenocepacia* bacteremia during the investigated period. The median age was 68 years (range, 19–83), and 15 of 16 had at least 1 comorbidity. All patients used a central venous catheter (CVC) for hemodialysis, and 11 (70%) of these 16 were temporary. Chlorhexidine gluconate solution was routinely used as part of CVC care and 1 bottle was shared among 4 hemodialysis stations. On suspicion of contamination, all identified chlorhexidine bottles were recalled on February 26, 2021, and random samples from 15 opened and 19 unopened bottles were sent for culture from the following units: hemodialysis (n = 2), ICU (n = 14), wards (n = 6), and 4 each from transplant surgery, and delivery suites. Of 34 sampled bottles, 17 grew *B. cenocepacia*: 8 opened and 9 unopened bottles. The Bayesian inference tree (Fig. 1) supports the hypothesis that patient samples and the samples from the chlorhexidine solutions were most probably related to each other based on the 16S rRNA sequences. However, the individual identities of the specific sample sequences could not be determined using the analyzed region of the gene, possibly due to low quality of the sequences received. No new cases of *B. cenocepacia* were identified after recall of the chlorhexidine

solution, and the outbreak was deemed resolved on March 24, 2021. **Conclusions:** Medical solutions routinely used in patient care can cause outbreaks and should be suspected as a potential source of infection by infection control teams.

Disclosures: None

Antimicrobial Stewardship & Healthcare Epidemiology 2023;3(Suppl. S2):s92–s93
doi:10.1017/ash.2023.358

Presentation Type:

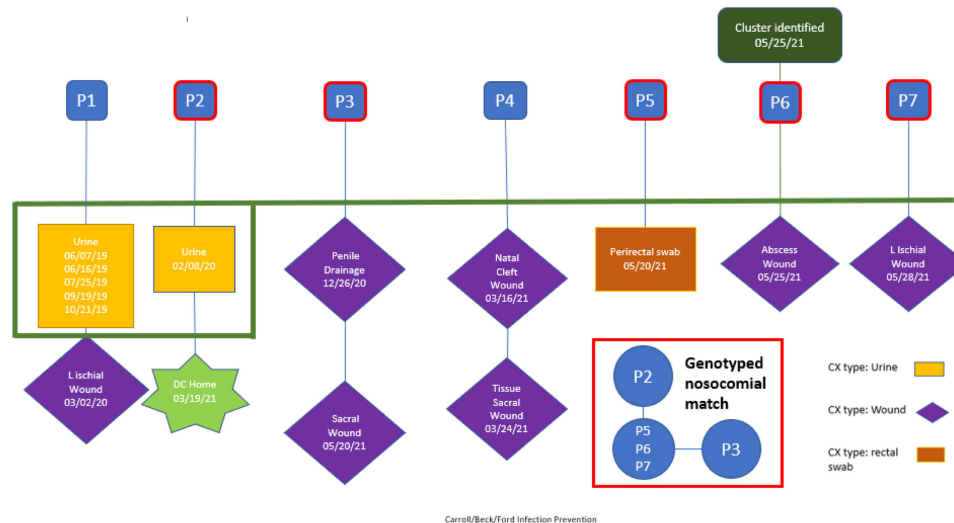
Poster Presentation - Poster Presentation

Subject Category: Outbreaks

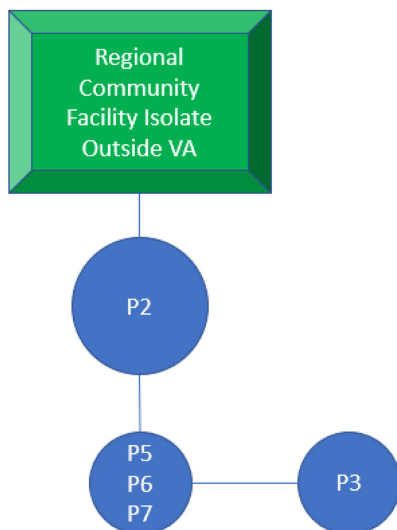
Multidrug-resistant *Acinetobacter* outbreak in spinal cord unit identified and stemmed through infection prevention epidemiologic efforts

Sean O’Neil; Delvina Ford; Erica Beck and Theresa Carroll

Background: Drug-resistant pathogens are a significant source of increased cost and patient complications in long-term and/or congregate care settings. Once introduced, depending on the environmental niche in which they establish and the mechanisms they employ for survival, they can be difficult to eradicate. We report the details of an epidemiologic investigation of a multidrug-resistant *Acinetobacter baumannii* (MDR-A) outbreak in a spinal cord intervention (SCI) unit within a Veterans Affairs facility in San Antonio, Texas, that was identified after back tracing



Carroll/Beck/Ford Infection Prevention



Five *A. baumannii* isolates belonged to sequence type (ST) ST-2 and a single isolate belonged to ST-1

Patient	Culture Results
P2	Urine 02/08/20
P3	Wound 12/26/20 Wound 05/20/21
P5	Perirectal Swab 05/20/21
P6	Wound 05/25/21
P7	Wound 05/28/21

a positive wound culture from a long-term resident. **Methods:** All MDR-A isolates were matched to the patients harboring them. Their clinical, epidemiologic, and geographic histories within our facility were traced. All potentially shared characteristics between cases were evaluated closely. **Results:** In total, 5 cases were determined to be likely connected over a period of ~18 months starting December 2020. The extant isolates underwent molecular evaluation and were genetically related. Patient activity was traced by the infection prevention team to identify potential sources of transmission. Environmental sampling after standard cleaning found a common strain on a shower trolley shared by these patients. Following focused cleaning of this and other shared locations, no new related isolates have been identified from patient or environmental samples. **Conclusions:** In this case, investigation by the infection prevention team of a single multidrug-resistant organism led to identification and eradication of a potential pathogen. Despite standard cleaning processes, a likely shared fomite was identified and decontaminated, thereby preventing future infections. This case exemplifies the value of thorough epidemiologic study paired with modern molecular methods of identification.

Disclosures: None

Antimicrobial Stewardship & Healthcare Epidemiology 2023;3(Suppl. S2):s93–s94

doi:10.1017/ash.2023.359

Presentation Type:

Poster Presentation - Poster Presentation

Subject Category: Outbreaks

Impact of respiratory syncytial virus in an open bay neonatal intensive care unit

Minisha Morris; Annette Vasandani; Yvonne Estrada; Malik Merchant; Annie Garcia; John Duran; Melissa Gallant and Adonica Benesh

Background: Respiratory syncytial virus, RSV, is a respiratory virus that causes cold-like symptoms in adults. In infants and young children, RSV can cause severe illnesses such as bronchiolitis or pneumonia. We describe a successful response to a laboratory-confirmed RSV outbreak in a 21-bed open-pod neonatal intensive care unit (NICU) at a level 2 trauma hospital. **Methods:** After 2 of the 3 initial neonates were diagnosed with hospital-onset RSV, an outbreak investigation began on November 16, 2022. Following the results, testing was expanded to all neonates in the NICU. The clinical case was defined as a hospitalized neonate with laboratory confirmation of RSV by RSV antigen screen or polymerase chain reaction (PCR) detection on the Biofire respiratory panel. Outbreak resolution was determined by utilizing a viral test for the remaining positive neonates after the 2-week incubation period from the last identified positive neonate. **Results:** On day 1 of the investigation, 6 of 18 neonates were identified as positive for RSV. The initial 12 negative neonates received a prophylactic dose of palivizumab. Due to the increase in positive neonates, enhanced infection prevention and control measures were immediately implemented. These measures included the immediate closure of the NICU for new transfers, placing all positive neonates in a single-bay cohort

in the NICU, implementing contact and droplet precautions, minimizing shared staff, increasing environmental cleaning, and using dedicated equipment. With awareness of the increased community occurrence of RSV, additional measures were taken to monitor adherence to infection prevention and control measures by staff and visitors entering the NICU, including daily symptom screening. Visitation was restricted to block scheduling to monitor the number of individuals in the NICU. Once we obtained the complete conversion of the initial neonate cohort, the additional focus shifted to maintaining the enhanced precautions until all neonate laboratory tests were negative. The NICU was successfully reopened once the remaining 3 positive neonates received no growth on their viral culture. **Conclusions:** The quick and effective response from a multidisciplinary team allowed a successful intervention to mitigate the identified outbreak. This investigation highlights the importance of enhanced infection prevention and control practices during increased community spread. Future efforts focus on educating staff and visitors on appropriate measures to decrease transmission risks.

Disclosures: None

Antimicrobial Stewardship & Healthcare Epidemiology 2023;3(Suppl. S2):s94

doi:10.1017/ash.2023.360

Presentation Type:

Poster Presentation - Poster Presentation

Subject Category: Outbreaks

COVID-19 outbreak in an acute psychiatric unit—Unique challenges and creative solutions

Supriya Narasimhan; Sherilyn Oribello; Laura Tang; Tracey Stoll and Vidya Mony

Background: We describe the management of a major COVID-19 outbreak in January 2022 during the SARS-CoV-2 omicron-variant winter surge involving the only inpatient psychiatric facility of Santa Clara County, California, which serves a population of 1.9 million. **Methods:** On January 14, 2022, infection prevention staff were notified of a symptomatic COVID-19 case in our locked inpatient psychiatric unit who had been admitted since October 2021. The index patient had no visitors or transfers outside the unit. The patients in this unit were noncompliant with masking and mingled with each other during meals. Initial testing identified 23 positive cases among 47 patients and 12 staff cases. Mitigating actions included closing the unit to new admissions, creating alternate care areas in the emergency psychiatric unit, and separating patients into “exposed but negative” and “infected” cohorts and housing them in “red,” and “yellow” zones, respectively. A “green” zone was created by clearance of positive cases. For the cohort exposed to COVID-19, masking was enforced by supervision, dining was scheduled in batches, and daily symptom screening and antigen testing were performed in addition to standard postexposure RT-PCR testing on day 4 and day 7. Mandatory N95 respirators and eye protection were implemented for staff on unit entry. Exposed staff followed employee health protocols for postexposure testing. Enhanced environmental control measures included terminal cleaning and UV-C disinfection of common areas and patient rooms and a thorough investigation of airflow. Discharged patients were contacted if they were residing in congregate facilities. **Results:** Of 47 patients, 39 (83%) tested positive for COVID-19. However, 8 patients remained negative; all 8 had received at least their primary vaccine series (Table 1). In total, 16 HCWs were SARS-CoV-2 positive in this outbreak. The outbreak officially ended 25 days after the first case. All SARS-CoV-2–positive patients had mild illness, not requiring treatment or hospitalization. We identified vaccine immune escape, staff presenteeism, patient noncompliance with masking, and comingling as major causes of transmission. We determined through contact tracing and temporality that the outbreak likely started from a positive staff member or visitor because most patients had been long-term residents. **Conclusions:** This outbreak was challenging due to the specialized behavioral needs of the involved patients. It was imperative to reopen this unit quickly and safely to provide psychiatric care to our county’s most vulnerable patients. Ongoing PPE education, repeated reinforcement, engagement in staff wellness to combat pandemic fatigue,

