

## Main Article

Associate Professor R J Briggs takes responsibility for the integrity of the content of the paper

R J Briggs was *The Journal of Laryngology & Otology* 2017 Visiting Professor.

**Cite this article:** Shaul C, Dragovic AS, Stringer AK, O'Leary SJ, Briggs RJ. Scalar localisation of peri-modiolar electrodes and speech perception outcomes. *J Laryngol Otol* 2018;**132**:1000–1006. <https://doi.org/10.1017/S0022215118001871>

Accepted: 25 June 2018  
First published online: 29 October 2018

### Key words:

Cochlear Implantation; Scala Tympani; Scala Vestibuli; Computed Tomography, X-Ray

### Author for correspondence:

Associate Professor Robert Briggs,  
Department of Otolaryngology,  
Royal Victorian Eye and Ear Hospital,  
East Melbourne, Victoria, Australia  
E-mail: [rjbriggs@netspace.net.au](mailto:rjbriggs@netspace.net.au)  
Fax: +61 3 9650 2522

© JLO (1984) Limited, 2018. This is an Open Access article, distributed under the terms of the Creative Commons Attribution licence (<http://creativecommons.org/licenses/by/4.0/>), which permits unrestricted re-use, distribution, and reproduction in any medium, provided the original work is properly cited.

# Scalar localisation of peri-modiolar electrodes and speech perception outcomes

C Shaul<sup>1,2</sup>, A S Dragovic<sup>1</sup>, A K Stringer<sup>1</sup>, S J O'Leary<sup>1,2</sup> and R J Briggs<sup>1,2</sup>

<sup>1</sup>Department of Otolaryngology, Royal Victorian Eye and Ear Hospital, East Melbourne and <sup>2</sup>Otolaryngology, Department of Surgery, University of Melbourne, Australia

## Abstract

**Objective.** To identify the intracochlear electrode position in cochlear implant recipients and determine the correlation to speech perception for two peri-modiolar electrode arrays.

**Methods.** Post-operative cone-beam computed tomography images of 92 adult recipients of the 'CI512' electrode and 18 adult recipients of the 'CI532' electrode were analysed. Phonemes scores were recorded pre-implantation, and at 3 and 12 months post-implantation.

**Results.** All CI532 electrodes were wholly within scala tympani. Of the 79 CI512 electrodes intended to be in scala tympani, 58 (73 per cent) were in scala tympani, 14 (17 per cent) were translocated and 7 (9 per cent) were wholly in scala vestibuli. Thirteen CI512 electrodes were deliberately inserted into scala vestibuli. Speech perception scores for post-lingual recipients were higher in the scala tympani group (69.1 per cent) compared with the scala vestibuli (54.2 per cent) and translocation (50 per cent) groups ( $p < 0.05$ ). Electrode location outside of scala tympani independently resulted in a 10.5 per cent decrease in phoneme scores.

**Conclusion.** Cone-beam computed tomography was valuable for demonstrating electrode position. The rate of scala tympani insertion was higher in CI532 than in CI512 electrodes. Scala vestibuli insertion and translocation were associated with poorer speech perception outcomes.

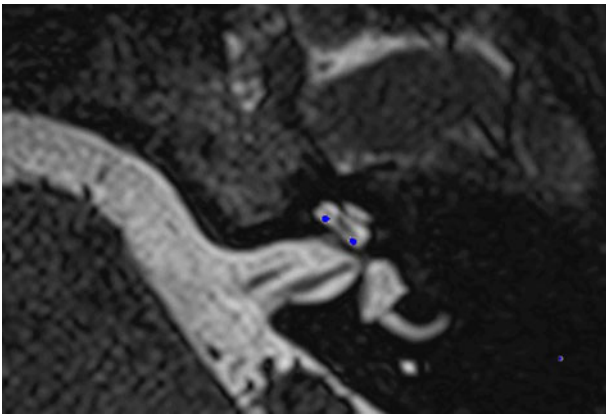
## Introduction

A variety of factors have been demonstrated to influence the audiological outcomes and speech perception performance following cochlear implantation. These include age at hearing loss onset, age at implantation, duration of severe to profound hearing loss and level of pre-operative residual hearing.


Intracochlear electrode position has emerged as another potentially significant contributor to outcome. Specifically, the insertion of the electrode array directly to scala tympani, without translocation to scala vestibuli, has been associated with better speech perception outcomes and more successful preservation of residual acoustic hearing.<sup>1–5</sup> Optimal electric stimulation requires atraumatic electrode insertion, with the electrode contacts within scala tympani for direct spiral ganglion stimulation. The mechanisms that may explain poorer outcomes with scala vestibuli insertion, or scala tympani to scala vestibuli translocation, are: damage to essential neurosensory elements (basilar membrane, organ of Corti and Reissner's membrane), and modiolar proximity variation and cross-turn stimulation, which can lead to pitch confusion.

Successful cochlear implant electrode placement in scala tympani requires that the electrode is inserted through the round window, or through an extended round window or separate cochleostomy, which opens into scala tympani. It is now recognised that an anteriorly placed cochleostomy risks entry into scala media and scala vestibuli. This applies for either straight or pre-curved (peri-modiolar) electrodes. Notably, round window and extended round window approaches have lower rates of placement outside the scala tympani in comparison to a cochleostomy approach, with up to a 70 per cent reduction in scala vestibuli insertion with round window and extended round window approaches.<sup>4,5</sup> In some cases, scala tympani obstruction with fibrosis or ossification, particularly in advanced otosclerosis or post-meningitis cases, can mandate scala vestibuli placement as the only option for electrode insertion.

Peri-modiolar electrodes such as the Contour Advance™ electrode arrays were designed to decrease electrical stimulation thresholds and provide more targeted electro-stimulation.<sup>6</sup> It has been demonstrated, however, that for Contour electrodes inserted into scala tympani, there is an incidence of scalar dislocation, with translocation from scala tympani to scala vestibuli usually occurring at the ascending basal turn. Pre-curved electrode arrays such as the Contour Advance are held straight, with an internal platinum stylet to facilitate initial insertion through the cochleostomy or extended round window opening. The pre-curved electrode is then pushed off the stylet and should follow the scala tympani lumen around the modiulus without any lateral wall contact. If, however, the electrode is initially over-inserted, or potentially if orientation is incorrect, then



**Fig. 1.** Co-registered image of pre-operative magnetic resonance imaging and post-operative cone-beam computed tomography scans showing the electrode within scala tympani.



**Fig. 2.** Co-registered image of pre-operative magnetic resonance imaging and post-operative cone-beam computed tomography scans showing the electrode within scala vestibuli.

penetration of the basilar membrane can occur, and the electrode translocates and is advanced into scala vestibuli.

Boyer *et al.* demonstrated that 23 out of 31 peri-modiolar arrays (74 per cent) were placed completely within scala tympani.<sup>2</sup> This rate was considerably lower in studies by Wanna *et al.*,<sup>4</sup> who reported a rate of 58 per cent (40 out of 69 peri-modiolar arrays were completely within scala tympani), and O'Connell *et al.*,<sup>7</sup> who reported a rate of 47 per cent (17 out of 36 peri-modiolar arrays were completely within scala tympani). In contrast, the rates for lateral wall arrays were all above 89 per cent. Although all these studies have found significant differences between types of electrodes and approaches, the overall patient numbers are relatively low.

Initial understanding of intracochlear electrode position was based on human cadaveric temporal bone studies. Post-operative clinical studies relied on cochlear view plain X-rays, which enable a good assessment of angular depth of insertion but not of scalar localisation. More recently, a variety of imaging modalities have been used to study intracochlear electrode position in cochlear implant recipients. These include rotational tomography, computed tomography (CT) and cone-beam CT. Post-operative CT images can also be co-registered with pre-operative magnetic resonance imaging (MRI) scans for clearer demonstration of scalar position.

The primary objective of this study was to examine the Melbourne Cochlear Implant Clinic experience with peri-modiolar electrodes, and identify the rates of scala tympani complete insertion, scala tympani and scala vestibuli translocation, and unplanned and planned scala vestibuli insertion. We also wanted to compare the speech perception between groups of patients with different electrode placements. As well as the Cochlear<sup>TM</sup> Nucleus<sup>®</sup> Profile Contour Advance Electrode ('CI512'), we now have experience with the Slim Modiolar Electrode ('CI532'); hence, we can compare intracochlear position and speech perception outcomes between the two different peri-modiolar arrays.

## Materials and methods

A prospective observational study was conducted of 110 peri-modiolar cochlear implantations, involving 92 of the CI512 arrays and 18 of the CI532 arrays. The study was conducted with the approval of the Royal Victorian Eye and Ear Hospital's Human Research Ethics Committee (East Melbourne, Australia). Patients aged over 18 years who underwent cochlear implantation through the Melbourne Cochlear Implant Clinic between January

2015 and March 2016, and who had undergone post-operative cone-beam CT scanning, were included.

## Surgical procedure

The surgical approach used was a standard transmastoid facial recess technique. All insertions were performed via separate cochleostomy or extended round window cochleostomy. Operative notes were reviewed particularly to identify cases where intracochlear pathology necessitated deliberate scala vestibuli insertion.

## Image analysis

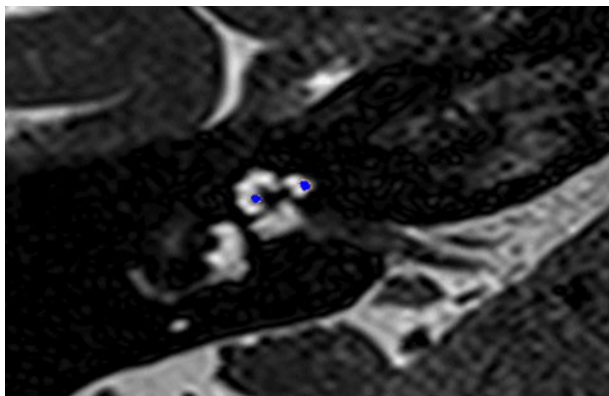
All cone-beam CT images were separately interpreted by an ENT registrar, an otology fellow and a senior otologist. Electrode localisation was categorised into three groups: (1) complete scala tympani placement; (2) complete scala vestibuli placement; and (3) translocation from scala tympani to scala vestibuli. In the majority of cases, electrode position was clear. In 19 cases, the cone-beam CT was more difficult to interpret and there was not consensus among all 3 interpreters.

In these 19 cases, co-registration of the pre-operative MRI and post-operative cone-beam CT was performed, as described elsewhere.<sup>8</sup> In short, the cone-beam CT and MRI scans were imported into the image analysis program Amira<sup>TM</sup> for semi-automatic registration. Three reference points on each image set were marked in three dimensions to allow automatic multi-point registration. The final registration was performed free-hand, to ensure that the cochlea, vestibule and semicircular canals were aligned, with researcher satisfaction determining the final endpoint. This allowed accurate assessment of electrode position for these cases (Figures 1–3).

## Audiology history and performance

Demographic data, including hearing loss aetiology, pre- or post-lingual onset, duration of severe to profound hearing loss before implantation, and pre-operative audiology evaluation findings, were recorded for all patients.

Speech perception testing was repeated 3 and 12 months post-operatively. Participants were required to listen to a list of 50 consonant–vowel–consonant words, which contained 150 phonemes, presented in quiet audition alone, via a loud-speaker, at a level of 65 dB SPL. The participants were required



**Fig. 3.** Co-registered image of pre-operative magnetic resonance imaging and post-operative cone-beam computed tomography scans showing the electrode translocated from scala tympani to scala vestibuli.

to repeat the word they heard and an audiologist scored the number of phonemes repeated correctly. The consonant–vowel–consonant words were recorded by a male Australian talker, according to the rules stipulated to ensure a balanced list of phonemes.<sup>9</sup>

### Statistical analysis

Statistical differences in subjects' demographics and audiology results were evaluated (with IBM SPSS Statistics version 24; Chicago, Illinois, USA) using a two-tailed, two-sample *t*-test, Mann–Whitney test, analysis of variance or Kruskal–Wallis test, as appropriate, followed by correction for multiple comparisons (Tukey or Bonferroni–Dunn post-hoc tests). The correlations between the individual's demographic details and scala placements and the audiology results were evaluated using a Pearson correlation test. Variables that were found to be associated with audiology performance were entered into a multiple regression model using the stepwise method. Data are presented as means and standard deviations. Statistical significance was defined as  $p < 0.05$ .

## Results

### Surgical procedure performed

All CI532 electrodes and 79 of the CI512 electrodes (86 per cent) were intended to be inserted into scala tympani, while 13 of the CI512 electrodes (14 per cent) were deliberately inserted into scala vestibuli because of anatomical changes (9 patients had far-advanced otosclerosis and 4 had post-meningitis cochlear ossification).

### Image analysis findings

Imaging demonstrated that all 18 of the CI532 electrodes were localised in scala tympani. Of the 79 cases in which the CI512 electrode was intended to be inserted into scala tympani, 58 electrodes (73 per cent) were localised in scala tympani, while 14 (17 per cent) were translocated and 7 (9 per cent) were localised in scala vestibuli. Of the 13 cases of deliberate scala vestibuli insertion, 9 electrodes (69 per cent) were wholly in scala vestibuli, and 4 (31 per cent) commenced in scala vestibuli and then translocated to scala tympani (Table 1 and Figure 4).

**Table 1.** Translocation of CI512 electrode from scala tympani to scala vestibuli

Intended scalar localisation	Total	Radiological localisation		
		Scala tympani	Scala vestibuli	Translocation
Scala tympani	79	58 (73)	7 (9)	14 (18)
Scala vestibuli	13	0 (0)	9 (69)	4 (31)
Total	92	58	16	18

Data represent numbers (and percentages) of arrays

### Audiology history and performance findings

There were no significant differences between the various array localisation groups in regard to: age at implant, duration of severe to profound hearing loss before implantation, percentage of pre-lingual patients, and pre-operative phonemes scores. However, while not significant, the proportion of pre-lingual patients in the scala tympani group ( $n = 17$ ) was higher than that in the scala vestibuli group ( $n = 1$ ) and translocation group ( $n = 4$ ) (Table 2).

Comparison of post-operative phonemes scores between the CI512 electrode localisation groups revealed better scores for scala tympani localisation, at 3 and 12 months post-implantation, but without statistical significance (Table 2 and Figure 5). When the pre-lingual patients were excluded and the post-lingual patients analysed, there were significant differences between the scala tympani group and the other two groups (scala vestibuli and translocation) ( $p = 0.013$ ). These differences were significant at 12 months post-implantation. Post-hoc analysis demonstrated significant differences between scala tympani and scala vestibuli groups (69.1 per cent vs 54.2 per cent;  $p < 0.05$ ) and between scala tympani and translocation groups (69.1 per cent vs 50 per cent;  $p < 0.005$ ) at 12 months post-implantation, but without significant differences between scala vestibuli and translocation groups (Table 3 and Figure 6).

In addition, as would be expected, age at implantation and duration of deafness were significantly correlated with 12-month post-operation phoneme scores, with Pearson correlation values of  $-0.24$  and  $-0.35$ , respectively. However, pre-implantation phoneme scores were not found to correlate with post-implantation phoneme scores. Therefore, scalar localisation, age at implantation and duration of deafness were entered into a multiple regression analysis model. Those three independent variables were retained in the model, accounting for 25 per cent of the overall variability in the 12-month post-operation phoneme scores. The scores decreased by 0.29 per cent and 0.35 per cent for every one-year increase in age and duration of deafness, respectively ( $p < 0.01$ ). Electrodes located out of scala tympani demonstrated a 10.5 per cent decrease in phonemes scores ( $p < 0.05$ ).

For those recipients with planned scala vestibuli electrode insertion because of scala tympani obstruction, the mean 12-month phoneme score was 46.1 per cent (Table 4).

### CI512 versus CI532

All patients with CI532 electrodes had post-lingual onset hearing loss. The CI532 electrode outcomes were therefore only compared to post-lingual CI512 electrode patients. Phoneme scores at 3 and 12 months post-implantation were higher in the CI532 electrode group (65 per cent) compared to the CI512 electrode group (79 per cent) (Table 5). Furthermore,

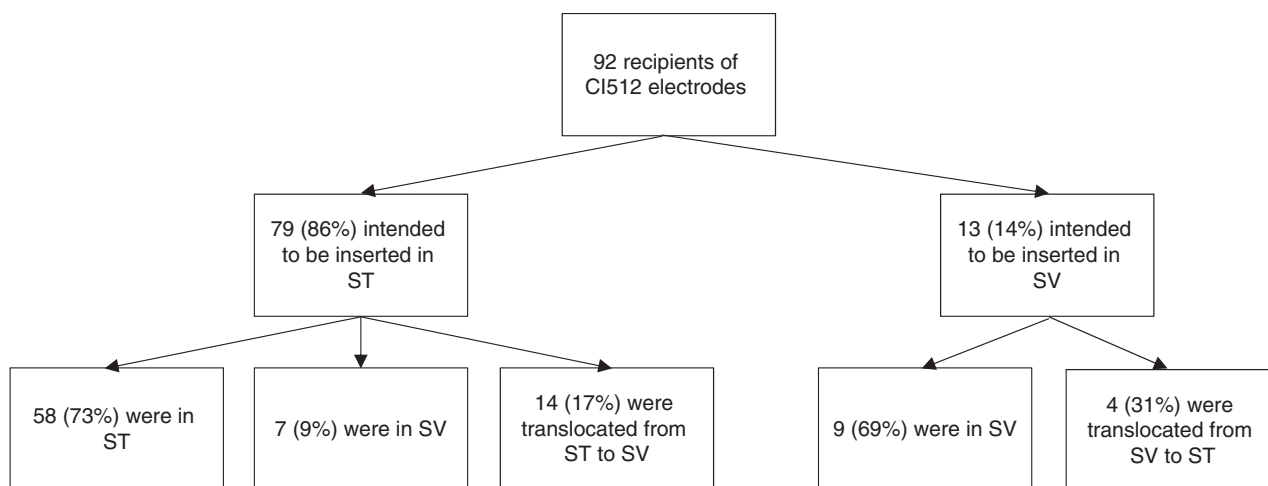


Fig. 4. Scalar localisation of CI512 electrodes based on intended insertions and imaging localisation. ST = scala tympani; SV = scala vestibuli

Table 2. Comparison between CI512 electrode localisation groups with intended scala tympani insertion

Parameter	Scala tympani	Scala vestibuli	Translocation	P-value*
Patients (n)	58	7	14	-
Age (mean (SD); years)	59.9 (17)	63 (19)	61.3 (22)	0.78
Pre-lingual patients (n (%))	17 (29)	1 (14)	4 (21)	0.18
Deafness duration (mean (SD); years)	22.2 (15)	25.4 (20)	21.5 (13)	0.21
Pre-op phoneme score (mean (SD); % correct)	12.7 (16)	9.3 (8)	11.7 (11)	0.43
3-mth post-op phoneme score (mean (SD); % correct)	52.7 (28)	45.2 (26)	45.2 (26)	0.38
12-mth post-op phoneme score (mean (SD); % correct)	57.7 (27)	52.3 (30)	46.2 (24)	0.48

\*Analyses conducted using the Kruskal-Wallis test. SD = standard deviation; pre-op = pre-operative; mth = month; post-op = post-operative

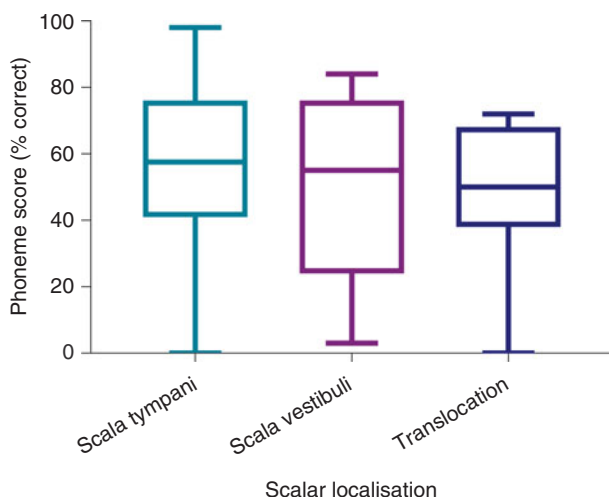


Fig. 5. Twelve-month post-implantation phonemes scores of all patients with CI512 electrodes according to scalar localisation.

when compared to the CI512 electrode patients with complete scala tympani insertion, the CI532 electrode group demonstrated better performance. However, phoneme scores were higher pre-operatively for the CI532 electrode group than for the CI512 electrode group (Table 5). Therefore, in order to match the CI512 and CI532 electrode groups, the patients in the CI512 electrode group with lower quartile pre-operative phoneme scores were removed. After matching the groups, the differences become smaller, but remained significant 12

months post-implantation (69 per cent vs 80 per cent) (Table 6 and Figure 7).

### Discussion

Atraumatic scala tympani insertion that preserves intracochlear structure is the ultimate goal of cochlear implantation. This study used cone-beam CT and, when necessary for clarification, co-registration with pre-operative MRI, to examine peri-modiolar electrode position. The results confirmed previous study findings which showed that, with the CI512 electrode, even when there is intended scala tympani insertion, there is a significant incidence of either direct scala vestibuli placement or translocation from scala tympani to scala vestibuli.

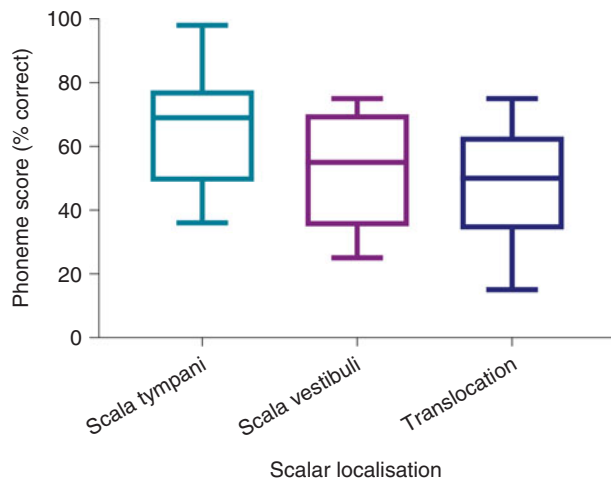
The proportion of complete scala tympani insertion among CI512 electrodes in our study was 73 per cent. This is similar to the finding of Boyer *et al.*<sup>2</sup> (74 per cent), and higher than the rates reported by Wanna *et al.*<sup>4</sup> and O’Connell *et al.*<sup>10</sup> (under 50 per cent). Boyer *et al.*<sup>2</sup> used a round window approach, while Wanna *et al.*<sup>4</sup> and O’Connell *et al.*<sup>10</sup> implanted using a round window, extended round window or cochleostomy approach. They had the lowest rate of complete scala tympani insertions for peri-modiolar implants with the latter of these approaches (25.9 per cent).

When cochlear anatomy is normal, we believe that the occurrence of scala vestibuli placement or translocation is directly related to surgical technique. A cochleostomy located too anteriorly, or made too large, may predispose the patient to

**Table 3.** Comparison between localisation of CI512 electrodes intended for scala tympani insertion in post-lingual patients

Parameter	Scala tympani	Scala vestibuli	Translocation	P-value*
Patients (n)	41	6	10	–
Age (mean (SD); years)	66.9 (14)	64.4 (20)	69.5 (10)	0.34
Deafness duration (mean (SD); years)	17.9 (13)	15.6 (12)	10.1 (14)	0.16
Pre-op phoneme score (mean (SD); % correct)	14.2 (17)	10.5 (8)	12.6 (12)	0.35
3-mth post-op phoneme score (mean (SD); % correct)	63.6 (21)	52.7 (20)	47.3 (23)	0.11
12-mth post-op phoneme score (mean (SD); % correct)	69.1 (17)	54.2 (25)	50 (21)	0.013 <sup>†</sup>

\*Analyses conducted using the Kruskal–Wallis test. <sup>†</sup> $p < 0.05$ . SD = standard deviation; pre-op = pre-operative; mth = month; post-op = post-operative

**Fig. 6.** Twelve-month post-implantation phonemes scores of post-lingual patients with CI512 electrodes according to scalar localisation.

scala vestibuli placement. Translocation occurs because of incorrect use of the Advance Off-Stylet insertion technique. In this study, eight different surgeons operated on the patients, with some having a very low rate of translocation and others a much higher rate. Those surgeons with a high rate of translocation have since been able to modify their insertion technique, ensuring correct electrode orientation and not inserting the array beyond the white mark before Advance Off-Stylet. This has dramatically improved their rates of accurate scala tympani placement.

The CI532 device was introduced during the study period. Although the numbers are small, we felt it worthwhile to include CI532 electrode recipients and to compare their results to CI512 electrode recipients. Of the CI532 electrodes, 100 per cent were shown to be completely in scala tympani. An extended round window approach was used and this clearly provides accurate scala tympani entry. The absence of any translocation with the CI532 electrode is consistent with previously reported temporal bone studies,<sup>11</sup> and is better than the findings reported by McJunkin *et al.*<sup>12</sup> Presumably, insertion without an internal stylet, and the reduced bulk and stiffness of the electrode, can reduce translocation between scala and minimise intracochlear structure damage.<sup>13,14</sup>

Post-operative imaging with accurate assessment of intracochlear electrode position is certainly useful, and allows surgeons to validate or modify their surgical technique. A number of imaging modalities have been used to assess electrode location. These include high-resolution CT,<sup>4</sup> rotational tomography,<sup>15</sup> flat panel CT<sup>16</sup> and cone-beam CT.<sup>2</sup> The clear advantage of cone-beam CT is the reduced radiation to recipients. The resolution and information that can be

**Table 4.** Comparison between CI512 electrode localisation groups with intended scala vestibuli insertion

Parameter	Scala vestibuli	Translocation	P-value*
Patients (n)	9	4	–
Age (mean (SD); years)	59.2 (5)	75 (4)	0.16
Deafness duration (mean (SD); years)	28.4 (8)	35.2 (12)	0.51
Pre-op phoneme score (mean (SD); % correct)	6.6 (4)	7.2 (6)	0.94
3-mth post-op phoneme score (mean (SD); % correct)	40 (8)	28.7 (13)	0.33
12-mth post-op phoneme score (mean (SD); % correct)	50.6 (9)	36.1 (9)	0.26

\*Analyses conducted using the t-test or Mann–Whitney U test. SD = standard deviation; pre-op = pre-operative; mth = month; post-op = post-operative

obtained from cone-beam CT has improved over recent years and is now superior to routine CT.

In this study, the same cone-beam CT system was used for all patients (i-CAT Next Generation (17–19) cone-beam CT (i-CAT, Hatfield, Pennsylvania, USA)). Most of the electrodes could be accurately localised using this system. However, in 19 cases, we used co-registration with pre-operative MRI studies in order to obtain better information. Recently, we have used a new system, the NewTom 5 G XL cone-beam CT system (Verona, Italy). This provides dramatically better resolution, with no need for co-registration with pre-operative MRI for electrode localisation. The routine in the Melbourne Cochlear Implant clinic is to perform a temporal bone cone-beam CT for every adult recipient during the early post-operative period. This has replaced the previously used cochlear view plain X-ray (modified Stenvers view). Cone-beam CT allows accurate localisation of all electrodes within the cochlea, and is useful not only for research purposes but also to identify the unusual case of tip fold-over and need for re-implantation.

In 13 cases, there was intracochlear fibrosis or ossification obstructing scala tympani in the basal turn, and so it was necessary to insert the electrodes directly into scala vestibuli. In nine of these cases, cone-beam CT confirmed that the electrodes were located in the scala vestibuli; however, in four cases, translocation was observed from scala vestibuli to scala tympani. The mean 12-month phoneme score for these planned scala vestibuli recipients was 46.1 per cent. It is reassuring to see that these recipients obtained significant benefit with their implants, despite the degree of intracochlear

**Table 5.** Comparison between post-lingual patients with CI512 electrodes (with intended scala tympani insertion) and CI532 electrodes

Parameter	CI512 electrode	CI532 electrode	P-value*
Patients (n)	57	18	-
Age (mean (SD); years)	68.2 (14)	62.2 (16)	0.17
Deafness duration (mean (SD); years)	16.2 (13)	12.7 (7)	0.32
Pre-op phoneme score (mean (SD); % correct)	13 (18)	26.1 (22)	0.002 <sup>†</sup>
3-mth post-op phoneme score (mean (SD); % correct)	59.9 (22)	73.1 (16)	0.019 <sup>†</sup>
12-mth post-op phoneme score (mean (SD); % correct)	64.8 (19)	79.5 (14)	0.002 <sup>†</sup>

\*Analyses conducted using the Mann-Whitney U test. <sup>†</sup>p < 0.05. SD = standard deviation; pre-op = pre-operative; mth = month; post-op = post-operative

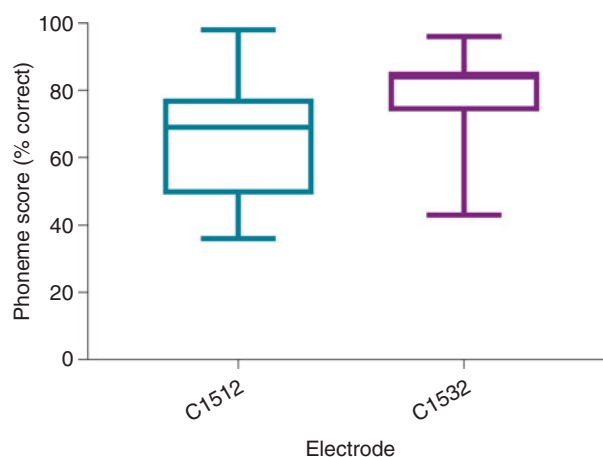
**Table 6.** Comparison between matched post-lingual patients with CI512 or CI532 electrodes (with all electrodes localised in scala tympani)

Parameter	CI512 electrode	CI532 electrode	P-value*
Patients (n)	31	18	-
Age (mean (SD); years)	66.3 (15)	62.2 (16)	0.28
Deafness duration (mean (SD); years)	16.6 (13)	12.7 (7)	0.41
Pre-op phoneme score (mean (SD); % correct)	21.2 (16)	26.1 (22)	0.11
3-mth post-op phoneme score (mean (SD); % correct)	64.9 (19)	73.1 (16)	0.08
12-mth post-op phoneme score (mean (SD); % correct)	69.4 (17)	79.5 (14)	0.017 <sup>†</sup>

The groups were matched by removing the CI512 electrode group patients with lower quartile pre-operative phoneme scores. \*Analyses conducted using the Mann-Whitney U test. <sup>†</sup>p < 0.05. SD = standard deviation; pre-op = pre-operative; mth = month; post-op = post-operative

disease. Their performance is significantly worse than the post-lingual patients with scala tympani placement. This is presumably in part a result of the degree of cochlear disease rather than the electrode position. However, the number of patients in this group with scala vestibuli to scala tympani translocation is too small to reach any statistical significance.

The degree to which scalar localisation contributes to the speech recognition outcome is the most relevant endpoint for clinicians. Our findings demonstrated that intracochlear electrode placement has a significant influence on the variability of post-implantation speech recognition results. There was a trend toward better consonant–vowel–consonant word scores for the complete scala tympani insertion group of combined pre- and post-lingual recipients, compared to the scala vestibuli and translocation groups, but this did not reach significance. Analysis of the scala tympani group revealed a much higher proportion of pre-lingual recipients, which may explain the poorer results for that group. Previous studies examining scalar localisation have reported outcomes for post-lingual recipients only.



**Fig. 7.** Twelve-month post-implantation phonemes scores of post-lingual patients with CI512 or CI532 electrodes. All electrodes were in scala tympani. The groups were matched by removing the patients with CI512 electrodes who had lower quartile pre-operative phoneme scores.

Given that poorer outcomes are expected in recipients with a pre-lingual component to their hearing loss, a further analysis that included only post-lingual recipients was performed, in order to minimise the variables. This comparison demonstrated that the scala tympani group speech performance scores were higher by 15 per cent on average, compared to the scala vestibuli group. Moreover, according to the regression analysis model, electrodes located in scala vestibuli, or translocated from scala tympani to scala vestibuli, independently reduced the 12-month post-implantation phoneme scores by 10.5 per cent, while no significant difference was found between scala vestibuli and translocation localisation.

- Cone-beam computed tomography can demonstrate post-operative scalar localisation of intracochlear peri-modiolar electrodes
- The rate of complete insertion in scala tympani was higher in ‘CI532’ (100 per cent) than in ‘CI512’ (73 per cent) electrode patients
- Electrodes not located fully in scala tympani were associated with 10 per cent lower speech perception post-implantation phoneme scores

These results are consistent with previous studies. Aschendorff *et al.* were the first to report better speech performance for recipients with scala tympani localisation, poorer performance for those with translocation and poorest results following scala vestibuli insertion.<sup>15</sup> Skinner *et al.* reported a significant negative relationship between word recognition (consonant–vowel–consonant word score) and the number of electrodes in the scala vestibuli.<sup>17</sup> Scalar position was found to be the most significant contributor ( $R^2 = 0.49$ ) in the consonant–vowel–consonant word recognition model described by Finley *et al.*<sup>3</sup> O’Connell *et al.* found that consonant–vowel–consonant word scores for complete scala tympani insertion were 51 per cent, as opposed to 39 per cent for scala vestibuli insertion.<sup>10</sup>

In this study, all CI532 electrodes were located in scala tympani, as reported by Aschendorff *et al.* in the initial clinical trial.<sup>13</sup> McJunkin *et al.* reported that only 74 per cent (17 out of 23) of CI532 electrode recipients had full scala tympani insertion, however.<sup>12</sup> This study is the first to report 12-month post-operative consonant–vowel–consonant word results for

CI532 electrode recipients. These recipients achieved significantly better consonant–vowel–consonant word results compared to CI512 electrode recipients. This difference was not only demonstrated in a comparison with the overall group of CI512 electrode recipients intended to have scala tympani insertion but also when compared to the group with confirmed scala tympani localisation. Furthermore, in order to better match the CI512 and CI532 electrode groups, those patients with CI512 electrodes who had lower quartile pre-operative consonant–vowel–consonant word scores were removed from the comparison, and the speech performance of the CI532 electrode group remained better. This study included a low number of CI532 electrode recipients, however, and so it is difficult to draw any definite conclusions regarding comparative outcomes.

## Conclusion

This study confirms the utility of cone-beam CT in demonstrating the post-operative scalar localisation of intracochlear peri-modiolar electrodes. Regression analysis confirmed the results of prior studies showing that scala vestibuli insertion, or scala tympani to scala vestibuli translocation, is associated with significantly poorer speech perception outcomes.

**Competing interests.** None declared

## References

- Aschendorff A, Kubalek R, Turowski B, Zanella F, Hochmuth A, Schumacher M *et al.* Quality control after cochlear implant surgery by means of rotational tomography. *Otol Neurotol* 2005;**26**:34–7
- Boyer E, Karkas A, Attie A, Lefournier V, Escude B, Schmerber S. Scalar localization by cone-beam computed tomography of cochlear implant carriers: a comparative study between straight and perimodiolar precurved electrode arrays. *Otol Neurotol* 2015;**36**:422–9
- Finley CC, Holden TA, Holden LK, Whiting BR, Chole RA, Neely GJ *et al.* Role of electrode placement as a contributor to variability in cochlear implant outcomes. *Otol Neurotol* 2008;**29**:920–8
- Wanna GB, Noble JH, Carlson ML, Gifford RH, Dietrich MS, Haynes DS *et al.* Impact of electrode design and surgical approach on scalar location and cochlear implant outcomes. *Laryngoscope* 2014;**124**(suppl 6):S1–7
- O'Connell BP, Hunter JB, Wanna GB. The importance of electrode location in cochlear implantation. *Laryngoscope* 2016;**1**:169–74
- Hughes ML, Abbas PJ. Electrophysiologic channel interaction, electrode pitch ranking, and behavioral threshold in straight versus perimodiolar cochlear implant electrode arrays. *J Acoust Soc Am* 2006;**119**:1538–47
- O'Connell BP, Hunter JB, Gifford RH, Rivas A, Haynes DS, Noble JH *et al.* Electrode location and audiologic performance after cochlear implantation: a comparative study between Nucleus CI422 and CI512 electrode arrays. *Otol Neurotol* 2016;**37**:1032–5
- Dragovic AS, Stringer AK, Campbell L, Shaul C, O'Leary SJ, Briggs RJ. Co-registration of cone beam CT and preoperative MRI for improved accuracy of electrode localization following cochlear implantation. *Cochlear Implants Int* 2018;**19**:147–52
- Peterson GE, Lehiste I. Revised CNC lists for auditory tests. *J Speech Lang Hear Res* 1962;**27**:62–70
- O'Connell BP, Cakir A, Hunter JB, Francis DO, Noble JH, Labadie RF *et al.* Electrode location and angular insertion depth are predictors of audiologic outcomes in cochlear implantation. *Otol Neurotol* 2016;**37**:1016–23
- Briggs RJ, Tykocinski M, Lazsig R, Aschendorff A, Lenarz T, Stover T *et al.* Development and evaluation of the modiolar research array--multi-centre collaborative study in human temporal bones. *Cochlear Implants Int* 2011;**12**:129–39
- McJunkin JL, Durakovic N, Herzog J, Buchman CA. Early outcomes with a slim, modiolar cochlear implant electrode array. *Otol Neurotol* 2018;**39**:e28–33
- Aschendorff A, Briggs R, Brademann G, Helbig S, Hornung J, Lenarz T *et al.* Clinical investigation of the Nucleus Slim Modiolar Electrode. *Audiol Neurootol* 2017;**22**:169–79
- Cuda D, Murri A. Cochlear implantation with the Nucleus Slim Modiolar Electrode (CI532): a preliminary experience. *Eur Arch Otorhinolaryngol* 2017;**274**:4141–8
- Aschendorff A, Kromeier J, Klenzner T, Laszig R. Quality control after insertion of the Nucleus Contour and Contour Advance electrode in adults. *Ear Hear* 2007;**28**(2 suppl):75–9s
- Arweiler-Harbeck D, Monninghoff C, Greve J, Hoffmann T, Goricke S, Arnolds J *et al.* Imaging of electrode position after cochlear implantation with flat panel CT. *ISRN Otolaryngol* 2012;**2012**:728205
- Skinner MW, Holden TA, Whiting BR, Voie AH, Brunnsden B, Neely JG *et al.* In vivo estimates of the position of Advanced Bionics electrode arrays in the human cochlea. *Ann Otol Rhinol Laryngol* 2007;**197**:2–24