

ROBIN'S SYNDROME IN THREE CHILDREN OF CONSANGUINEOUS PARENTS

A Pedigree Suggesting Autosomal Recessive Inheritance

GIUSEPPE RUSSO, FLORINDO MOLLICA, LORENZO PAVONE,
SALVATORE MUSUMECI

SUMMARY

A family is described in which three siblings were affected by Robin's syndrome (micrognathia and glossoptosis with cleft palate) in its severe form. Two children died very early in life, the third is surviving after surgical management and appropriate nursing care. The children were born from a consanguineous marriage (their parents were first cousins). This pedigree is highly suggestive of an autosomal recessive kind of inheritance. Malformations of the extremities (hands and/or feet) were present in the probands as well as in two relatives of the paternal line.

INTRODUCTION

A diagnosis of Robin's syndrome is made on the basis of two physical findings: micrognathia and glossoptosis. Cleft palate is usually present also.

These three symptoms are probably due to a dysontogenetic process (first arch syndrome, McKenzie 1958). Other symptoms described include: (1) anomalies of the heart (patent ductus arteriosus and foramen ovale, auricular septal defect and cor triloculare with coarctation of the aorta); (2) eyes (esotropia, glaucoma, etc.); (3) brain (mental retardation, hydrocephaly and microcephaly); (4) limbs (syndactyly, talipes equinovarus, hypoplasia of carpal and metacarpal bones, finger anomalies); and (5) ears (deafness, low-set ears) (Smith and Stowe 1961).

In the past forty-three years since the disease was first described, at least four hundred cases have been reported. Subjects of all races are affected.

The purpose of this paper is to present a family in which Robin's syndrome occurred in three siblings of consanguineous parents.

THE PEDIGREE

The family (Fig. 1) is Sicilian. The parents (III/12 and III/13) of our probands are first cousins. A paternal aunt (III/5) died when she was 13-days-old, of unknown causes; she showed bilateral talipes equinovarus but no other anomalies. One (IV/2) of two children of a paternal uncle has a malformation of the limbs, referred to as a "lack of heel". There are no congenital malformations in the maternal line.

A brother (IV/5) of our probands is 4-years-old and healthy.

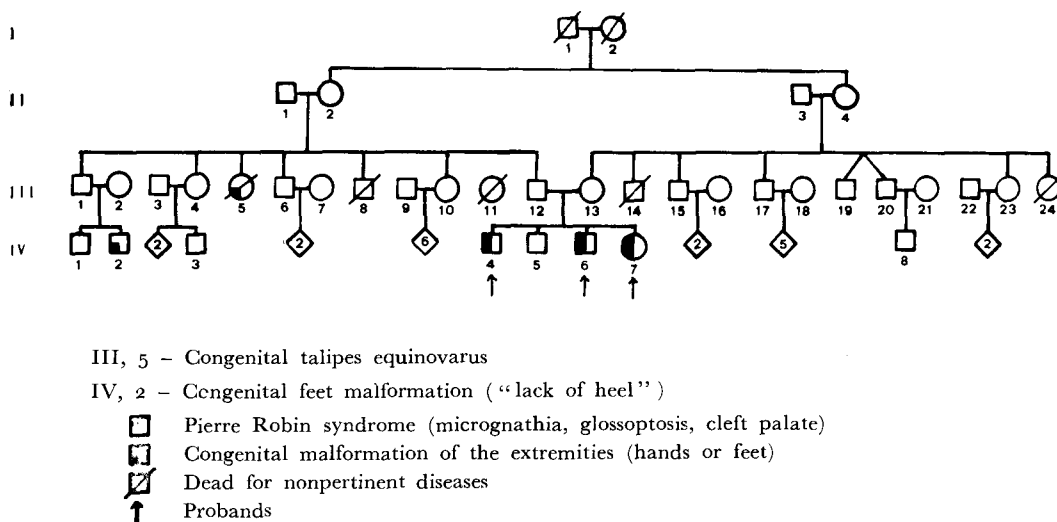


FIG. 1. Pedigree of P. family

The first proband (IV/4), a male infant, was admitted to the Pediatric Clinic of Catania at the age of 18 days. He suffered from choking spells during feeding and showed unusual facial characteristics. Physical examination revealed micrognathia, glossoptosis of slight degree, and bilateral talipes equinovarus. There were a right parietal cephalhematoma. He was emaciated and his weight was 2,600 g. There were fine rales in both lungs, dyspnea, and cyanosis. There were no cardiac murmurs. The liver was felt 4 cm below the costal margin. Routine blood and urine examinations were normal. X-ray of the chest showed slight enlargement of the heart with decreased pulmonary vasculature. An ECG was normal. The infant became increasingly cyanotic and dyspneic. He succumbed to his respiratory distress 4 days after his admission. There was no autopsy.

The second proband (IV/6) a male, came to this Clinic in very poor condition with choking spells at the age of 6 days. He was the product of a full-term spontaneous delivery without gestational complications. His birth weight was 2,600 g. Shortly after birth he was noted to have severe respiratory distress. Physical examination revealed marked cyanosis, dyspnea with intercostal retractions, and fine crepitation at the bases of both lungs. Hypoplasia of mandibula, glossoptosis and cleft palate were also present. There were no cardiac murmurs. The liver was felt 3 cm below the right costal margin. It was not possible to perform any laboratory tests because the child died after about 1 hour. There was no autopsy.

The third proband (IV/7) was a female infant 7-days-old on admission. She was the product of a full-term spontaneous delivery. Her birth weight was 3,100 g. She was admitted to the Clinic because she showed slight jaundice and chokings spells during feeding, and had facial features similar to those of her two dead brothers. She was 49 cm in length and weighed 2,900 g. She had evident micrognathia and cleft palate (Fig. 2). Her tongue fell backwards and downwards with frequent episodes of choking. Other anomalies were: camptodactyly of the fifth fingers, thumbs overlying the hypothenar area, flat-bridged nose, pectus carenatum, and low-set ears. Moro's reflex was poor. The remainder of the

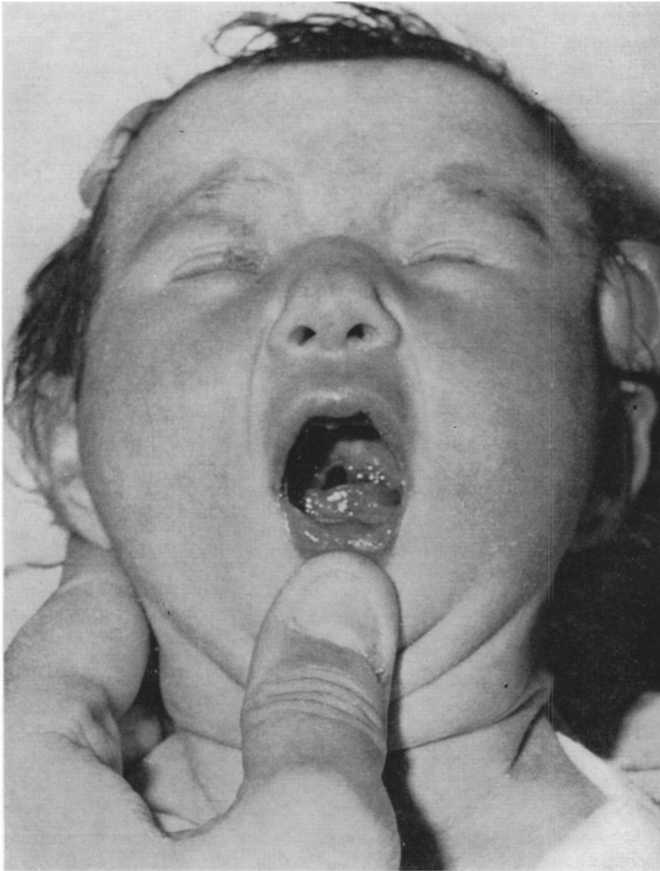


FIG. 2. *Cleft palate in IV/7*

physical examination was unremarkable. On admission slight anemia was present (Hb 10.44 g/100 ml; RBC 4.24×10^6 /cu.mm). Urinalysis, serum electrolyte and protein levels were normal. At 12 days of age the infant had a Douglas procedure (1956) in which a suture is placed between the anterior tongue and lower lip. Now 8-months-old, the infant, who is carefully controlled with appropriate nursing care, is in good conditions. In prone position she can eat spontaneously. Her growth is normal. A skeletal survey, except for the mandibular and digital anomalies, is normal. On Jan. 1972, when the infant was 45-days-old, plasma and urine aminoacid analysis performed on resin column (Moore et al. 1958) gave normal results; chromosomal complement was normal as well.

DISCUSSION

Some observations have shown that this syndrome can have a hereditary basis. Robin's syndrome in siblings has been previously reported (Smith and Stowe 1961, Sachtleben 1964, Sacrez et al. 1967, De Coninck 1969, Shah et al. 1970, Singh et al.

1970). The family histories of other cases (La Page 1937, Zunin 1955) give additional examples of the presence of the syndrome in siblings. Moreover, families have been reported in which some relatives show partial manifestations of the syndrome, namely cleft palate or cleft lip and palate (Teza and Biscatti 1964, Centa and Rasore-Quartino 1967, Bhogaonker et al. 1967, Peterson and Schimke 1968).

Two modes of inheritance have been reported: a presuntive autosomal dominant (Smith and Stowe 1961, Peterson and Schimke 1968) and an autosomal recessive which is the most common. Recently, Gorlin et al. (1970) reported a family with a subvariety of Robin's syndrome showing an X-linked mode of transmission.

The role of heredity is more likely in this family than in other families reported. The presence of the complete syndrome in three siblings (two males and one female) and the consanguinity of the parents strongly suggest an inheritance of autosomal recessive type. In all three of our patients the classical triad (micrognathia, glossoptosis and cleft palate) was associated with anomalies of the extremities.

In conclusion our family is an example of Robin's syndrome in which a hereditary transmission of the autosomal recessive type is quite likely. The frequent sporadic cases of the syndrome are probably phenocopies, i.e., nongenetic effects of environmental factors which mimic the action of the anomalous gene. The apparently sporadic cases are much more frequent than those which suggest a hereditary etiology.

REFERENCES

- Bhogaonker A., Sagar K.B., Bhakoo O.N. 1967. Pierre Robin syndrome. *Indian J. Pediatr.*, 34: 332.
- Centa A., Rasore-Quartino A. 1967. La sindrome di Pierre Robin. Studio di sette casi. *Minerva Pediatr.*, 19: 2042.
- De Coninck A. 1969. Le syndrome de Pierre Robin, urgence chirurgicale. *Acta Paediatr. Belg.*, 23: 5.
- Douglas B. 1956. The treatment of micrognathia with obstruction by a plastic operation. *Lyon Chir.*, 52: 420.
- Gorlin R.J., Cervenka J., Anderson R.C., Sauk J.J., Bevis W.D. 1970. Robin's syndrome. A probably X-linked recessive subvariety exhibiting persistence of left superior vena cava and atrial septal defect. *Am. J. Dis. Child.*, 119: 176.
- La Page C.P. 1937. Micrognathia in the newborn. *Lancet*, 1: 323.
- McKenzie J. 1958. The first arch syndrome. *Arch. Dis. Child.*, 33: 477.
- Moore S.D., Spackman H., Stein W.H. 1958. Chromatography of amino acids on sulfonate polystyrene resins: an improved system. *Anal. Chem.*, 30: 1185.
- Peterson D.M., Schimke R.N. 1968. Hereditary cup-shaped ears and the Pierre Robin syndrome. *J. Med. Genet.*, 5: 52.
- Sachtleben P. 1964. Zur Pathogenese und Therapie des Pierre-Robin Syndroms. *Arch. Kinderheilkd.*, 171: 55.
- Sacrez R., Francfort J.J., Gigonnet J.M., Beauvais P., Boll G. 1967. À propos de la débilite intellectuelle et d'anomalies associées à la triade symptomatique du syndrome de Pierre-Robin. *Ann. Pediatr. (Paris)*, 43: 29.
- Shah C.V., Pruzansky S., Harris W.S. 1970. Cardiac malformations with facial clefts (with observation on the Pierre Robin syndrome). *Am. J. Dis. Child.*, 119: 238.
- Singh R.P., Jaco N.T., Vigna V. 1970. Pierre Robin syndrome in siblings. *Am. J. Dis. Child.*, 120: 560.
- Smith J.L., Stowe F.R. 1961. The Pierre Robin syndrome (glossoptosis, micrognathia, cleft palate): a review of 39 cases with emphasis on associated ocular lesions. *Pediatrics*, 27: 128.
- Teza F., Biscatti G. 1964. Sindrome di Pierre Robin. Considerazioni su tre casi. *Clin. Pediatr. (Bologna)*, 46 (suppl. 1): 21.
- Zunin C. 1955. La sindrome "micrognazia, palatoschisi e glossoptosi" (sindrome di Pierre Robin). Dallo studio clinico e anatomopatologico di due casi. *Pediatria (Napoli)*, 63: 59.

RIASSUNTO

Viene descritta una famiglia con tre fratelli affetti da sindrome di Robin (micrognazia e glossoptosi con palatoschisi) nella forma grave. Due bambini sono morti nei primi giorni di vita, mentre il terzo è sopravvissuto dopo trattamento chirurgico e cure adatte. I genitori di questi bambini sono cugini primi. La genealogia è fortemente indicativa di un'eredità autosomica recessiva. Malformazioni delle estremità (mani e/o piedi) erano presenti sia nei probandi che in due parenti della linea paterna.

RÉSUMÉ

Une famille est décrite avec trois frères atteints de syndrome de Robin (micrognathie et glossoptose avec palatoschise) dans la forme grave. Deux enfants sont morts dans les premiers jours de vie, tandis que le troisième est survécu après traitement chirurgical et des soins appropriés. Les parents sont cousins de premier degré. Cette généalogie suggère une hérédité autosomique récessive. Des malformations des extrémités (mains et/ou pieds) étaient présentes chez les enfants atteints ainsi que chez deux parents de la ligne paternelle.

ZUSAMMENFASSUNG

In einer Familie kamen drei Geschwister mit schwerem Robin-Syndrom (Micrognathie u. Glossoptosis mit Palatoschisis) zur Welt. Zwei starben in den ersten Tagen, das dritte Kind konnte durch chirurgischen Eingriff und entsprechende Behandlung weiter leben. Die Eltern sind Vetter ersten Grades. Diese Familiengeschichte lässt auf rezessiv autosomen Erbgang schliessen. Sowohl die Kinder als zwei väterliche Verwandte wiesen Missbildungen an den Extremitäten (Hände und/oder Füße) auf.

Prof. Giuseppe Russo, Clinica Pediatrica dell'Università, Viale A. Doria, Catania, Italy.
