



Critical left main coronary artery stenosis presenting as cardiac arrest in coarctation of the aorta patient

Brief Report

Cite this article: Nitsche LJ, Callahan R, Grasty MA, Devlin PJ, Favilla E, and Mavroudis CD (2024). Critical left main coronary artery stenosis presenting as cardiac arrest in coarctation of the aorta patient. *Cardiology in the Young*, page 1 of 3. doi: [10.1017/S1047951124025289](https://doi.org/10.1017/S1047951124025289)

Received: 3 April 2024

Revised: 7 May 2024




Accepted: 7 May 2024

Keywords:

Aortic coarctation; cardiac arrest; coronary stenosis

Corresponding author:

C. D. Mavroudis; Email: mavroudisc@chop.edu

Lindsay J. Nitsche¹ , Ryan Callahan², Madison A. Grasty¹ , Paul J. Devlin¹, Emmanuelle Favilla² and Constantine D. Mavroudis¹ 

¹Division of Cardiothoracic Surgery, Children's Hospital of Philadelphia, Philadelphia, PA, USA and ²Division of Cardiology, Children's Hospital of Philadelphia, Philadelphia, PA, USA

Abstract

Congenital coronary artery stenosis coexisting with aortic coarctation in nonsyndromic patients has not previously been reported. This report describes a nonsyndromic aortic coarctation patient who experienced intraoperative cardiac arrest due to a previously undiagnosed critical left main coronary artery stenosis. The patient was successfully resuscitated, underwent patch coronary ostioplasty, and was discharged home. He remains well for four months following repair.

Coarctation of the aorta typically presents in isolation but has been associated with patent ductus arteriosus, ventricular septal defect, bicuspid aortic valve, and atrial septal defect.¹ Coronary artery anomalies in the setting of aortic coarctation can be found in patients with certain syndromes such as Noonan, Shone, Turners, or Williams syndromes.¹⁻³ In nonsyndromic patients, there have been no reported cases of concomitant congenital coronary artery stenosis with coarctation.^{1,4} The association is likewise not mentioned in comprehensive reviews on the topic of aortic coarctation.^{2,3} In contrast, congenital coronary artery anomalies are present in up to 9% of Williams syndrome patients, and this number increases to 45% if the child has supravalvular aortic stenosis.⁵ The combination of coarctation of the aorta and congenital coronary artery stenosis in this population can precipitate a coronary ischaemic event that can be fatal.^{5,6} Due to the prevalence of coronary anomalies in Williams syndrome, screening for such anomalies with cardiac catheterisation is common.⁵ Nonsyndromic patients with isolated coarctation of the aorta, however, are not typically screened for coronary artery anomalies because such an association has not hitherto been described in the extant literature.² Herein, we describe a nonsyndromic patient who was found to have left main coronary artery stenosis following intraoperative cardiac arrest after coarctation repair.

Clinical summary

A three-month-old full-term male (9.12 kg) without any history of genetic syndromes presented for elective coarctation repair via left thoracotomy for a discrete, juxtaductal coarctation of the aorta. Preoperative imaging demonstrated a common brachiocephalic trunk but ample room for clamping and repair. The coronary arteries were not completely visualised, and no further interrogation was performed. The patient underwent left thoracotomy, coarctectomy, and extended end-to-end repair. The clamp time was 21 minutes, and there was no residual gradient post repair. Ten minutes after clamp removal, the patient experienced an unprovoked episode of ventricular fibrillation. Cardiopulmonary resuscitation was begun, and the patient was successfully defibrillated with 10J using internal defibrillation paddles. The remainder of the early postoperative course was unremarkable. The patient underwent extensive evaluation for potential aetiologies of their cardiac arrest including a CT angiography that demonstrated a widely patent reconstructed aortic arch and did not identify coronary pathology. Due to a high index of suspicion, the patient underwent coronary angiography which identified an abnormally high takeoff of the left coronary artery above the sinotubular junction (Fig. 1a). Coronary angiography also showed severe stenosis of the left main coronary artery measuring 0.7 mm with normalisation to approximately 2 mm at the bifurcation of the left anterior descending and left circumflex (Fig. 1b).

The patient was brought back to the operating room on post-operative day 11. At that time, he underwent patch coronary ostioplasty which was extended just proximal to the coronary bifurcation using pulmonary artery homograft. Aortic tissue was sent for pathologic analysis, but this was non-contributory. Additionally, genetic testing including genomic DNA analysis and rapid targeted analysis of genome testing of the patient and parents was negative for

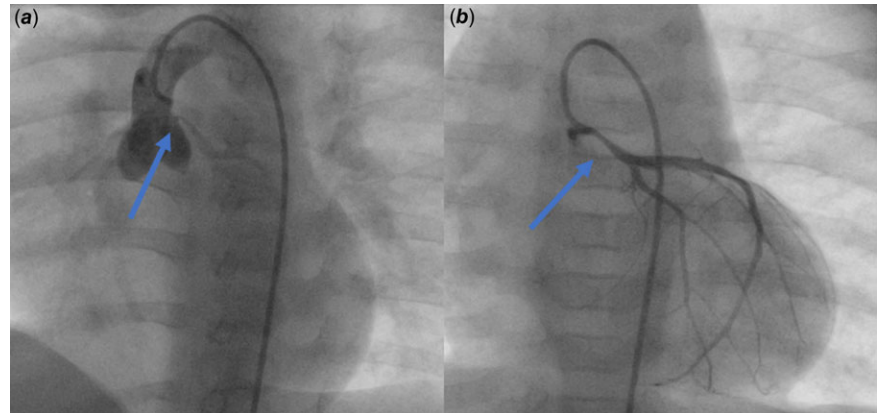


Figure 1. (a) Aortic root angiography without catheter engaged in the coronary artery. Here, you can visualise the high takeoff of the left coronary artery. (b) Preoperative left coronary artery angiography demonstrating severe left main coronary artery stenosis.

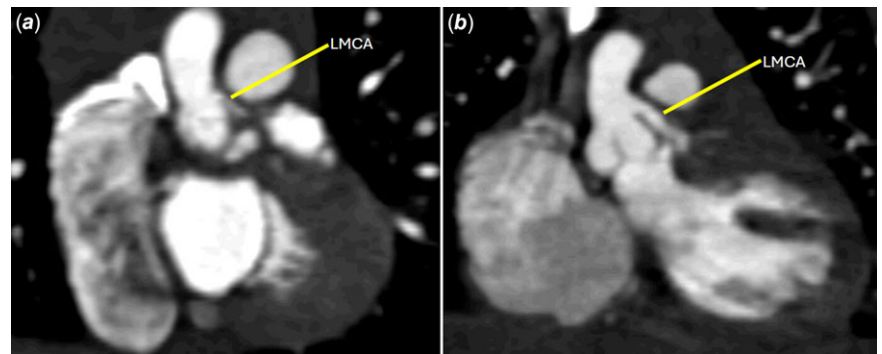


Figure 2. Computed tomography angiography coronal images demonstrating the anatomy of the left main coronary artery (LMCA) both post-left thoracotomy coarctation repair (a) and post-coronary ostioplasty (b).

Williams syndrome. The patient recovered well and had an uncomplicated hospitalisation following coronary ostioplasty. Repeat CT angiography eight days after coronary ostioplasty demonstrated a widely patent left main coronary artery (Fig. 2). The patient was discharged 11 days after undergoing the ostioplasty on 40.5 mg of aspirin daily to be taken indefinitely. He continues to do well as an outpatient four months later.

Discussion

Comprehensive reviews of aortic coarctation discussing synchronous lesions, imaging, and outcomes do not mention congenital coronary lesions in nonsyndromic patients.^{2,3} A single centre experience detailing the outcomes of 819 aortic coarctation patients reported no cases of concomitant congenital coronary pathology.⁴ Another study of 920 aortic coarctation patients derived from the CONCOR database, likewise, had no cases of congenital coronary pathology.¹ Of note, the CONCOR analysis specifically discussed the causes of cardiovascular mortality and morbidity for aortic coarctation patients, and there was no mention of congenital coronary artery abnormalities or complications thereof.¹ Further, a study specifically describing acquired coronary artery disease in 756 aortic coarctation patients fails to mention a single case of congenital coronary artery disease.⁷ Therefore, the largest studies, including those focused on cardiovascular complications, have not reported coronary artery stenosis leading to sudden death or fatal arrhythmia in patients without a genetic syndrome. There are additionally no case reports in the extant literature describing congenital coronary anomalies in nonsyndromic patients with coarctation of the aorta.

In contrast, Williams syndrome patients have been reported to possess both pathologies manifesting in symptoms such as cardiac arrest.⁵ In a report of 10 sudden death events in patients with Williams syndrome, most occurred in close temporal proximity to aortic coarctation repair.⁶ Autopsy data was available for seven cases and confirmed the presence of coronary artery stenosis in five, supporting myocardial ischaemia and fatal arrhythmia as the cause of mortality. Additionally, when historic patients were included in an additional report, there were 12 cases of coronary artery stenosis in a total of 19 patients.⁶ These events in Williams syndrome patients have been pervasive in the literature and have led to the development of recommendations for anaesthetic providers.⁵ Our patient also experienced a peri-operative cardiac arrest, but their case is novel due to the lack of genetic, or any other, predisposition to congenital coronary anomalies.

Coronary artery stenosis associated with aortic coarctation in a patient without a syndromic condition has not been reported. Therefore, this patient did not undergo coronary artery imaging due to negative family history and an absence of any syndromic sequelae. Despite their intraoperative arrest, they are clinically well, and the results of their coarctation repair and coronary ostioplasty are excellent.

Conclusion

This case represents a silent coronary anomaly presenting as cardiac arrest in a coarctation patient without Williams syndrome. This rare, potentially fatal coincidental lesion should be considered in patients with coarctation of the aorta. Due to the rarity of the condition and potential burden of invasive testing in an otherwise low-risk aortic coarctation patient, we do not suggest routine

coronary imaging in these patients. Instead, we advocate for mindfulness and preparedness on the part of the operating surgeon should a coronary issue arise.

Acknowledgements. None.

Financial support. None.

Competing interests. None.

References

1. Meijs TA, Minderhoud SCS, Muller SA, et al. Cardiovascular morbidity and mortality in adult patients with repaired aortic coarctation. *J Am Heart Assoc* 2021; 10: e023199. DOI: [10.1161/jaha.121.023199](https://doi.org/10.1161/jaha.121.023199).
2. Raza S, Aggarwal S, Jenkins P, et al. Coarctation of the aorta: diagnosis and management. *Diagnostics (Basel)* 2023; 13: 2189. DOI: [10.3390/diagnostics13132189](https://doi.org/10.3390/diagnostics13132189).
3. Kim YY, Andrade L, Cook SC. Aortic coarctation. *Cardiol Clin* 2020; 38: 337–351. DOI: [10.1016/j.ccl.2020.04.003](https://doi.org/10.1016/j.ccl.2020.04.003).
4. Brown ML, Burkhart HM, Connolly HM, et al. Coarctation of the aorta: lifelong surveillance is mandatory following surgical repair. *J Am Coll Cardiol* 2013; 62: 1020–1025.
5. Staudt GE, Eagle SS. Anesthetic considerations for patients with Williams syndrome. *J Cardiothorac Vasc Anesth* 2021; 35: 176–186. DOI: [10.1053/j.jvca.2020.01.022](https://doi.org/10.1053/j.jvca.2020.01.022).
6. Bird LM, Billman GF, Lacro RV, et al. Sudden death in Williams syndrome: report of ten cases. *J Pediatr* 1996; 129: 926–931. DOI: [10.1016/s0022-3476\(96\)70042-2](https://doi.org/10.1016/s0022-3476(96)70042-2).
7. Roifman I, Therrien J, Ionescu-Ittu R, et al. Coarctation of the aorta and coronary artery disease: fact or fiction? *Circulation* 2012; 126: 16–21. DOI: [10.1161/circulationaha.111.088294](https://doi.org/10.1161/circulationaha.111.088294).