

LETTERS TO THE EDITOR**TO THE EDITOR****Chronic Inflammatory Demyelinating Polyneuropathy and Metastatic Melanoma**

Paraneoplastic neurological syndrome (PNS) denotes the remote effects of malignancy on the nervous system not directly attributable to its primary or metastatic sites. An immune mechanism is likely, given the detection of onconeural antibodies in many instances. Both the central and peripheral nervous systems may be involved, and clinical variation is extensive. Chronic inflammatory demyelinating polyneuropathy (CIDP) may in some instances represent an example of PNS. This acquired autoimmune condition of unknown etiology has occurred in the context of viral infections, other autoimmune diseases, plasma cell dyscrasias and solid tumours, although insufficient evidence exists to distinguish these associations from idiopathic. Here, we present a case of CIDP occurring in the context of metastatic melanoma as well as review those few cases previously reported in the literature.

CASE REPORT

A 67-year-old right-handed retired salesman presented with a two-month history of symmetrical ascending paresthesias which

began in the distal lower extremities and progressed proximally into the thighs and forearms. This was associated with progressive weakness in the legs greater than the arms resulting in the eventual loss of independent ambulation. There was no history of back pain or symptoms suggestive of autonomic dysfunction. Of note, one month prior to the onset of his sensorimotor symptoms, he had noticed a large hyperpigmented skin lesion over his chest. He was subsequently diagnosed with metastatic melanoma after biopsies of the skin lesion, right axillary lymph node and spleen. Additional relevant past medical history included non-Hodgkin lymphoma diagnosed three years prior and treated with a one year course of chemotherapy with no apparent complications and in remission. His medications on presentation included candesartan, hydrochlorothiazide, omeprazole and gabapentin. There was no significant history of smoking or alcohol abuse.

On examination, there were frank fasciculations involving the pectoralis, first dorsal interosseous, abductor pollicis brevis, quadriceps and gastrocnemius muscles. There was generalized muscle atrophy although it was not clearly distinguishable from cachexia. He demonstrated generalised limb weakness, with less than antigravity power in the proximal lower extremities and associated generalized areflexia and flexor plantar responses. There was decreased pinprick and vibration sense in a glove and

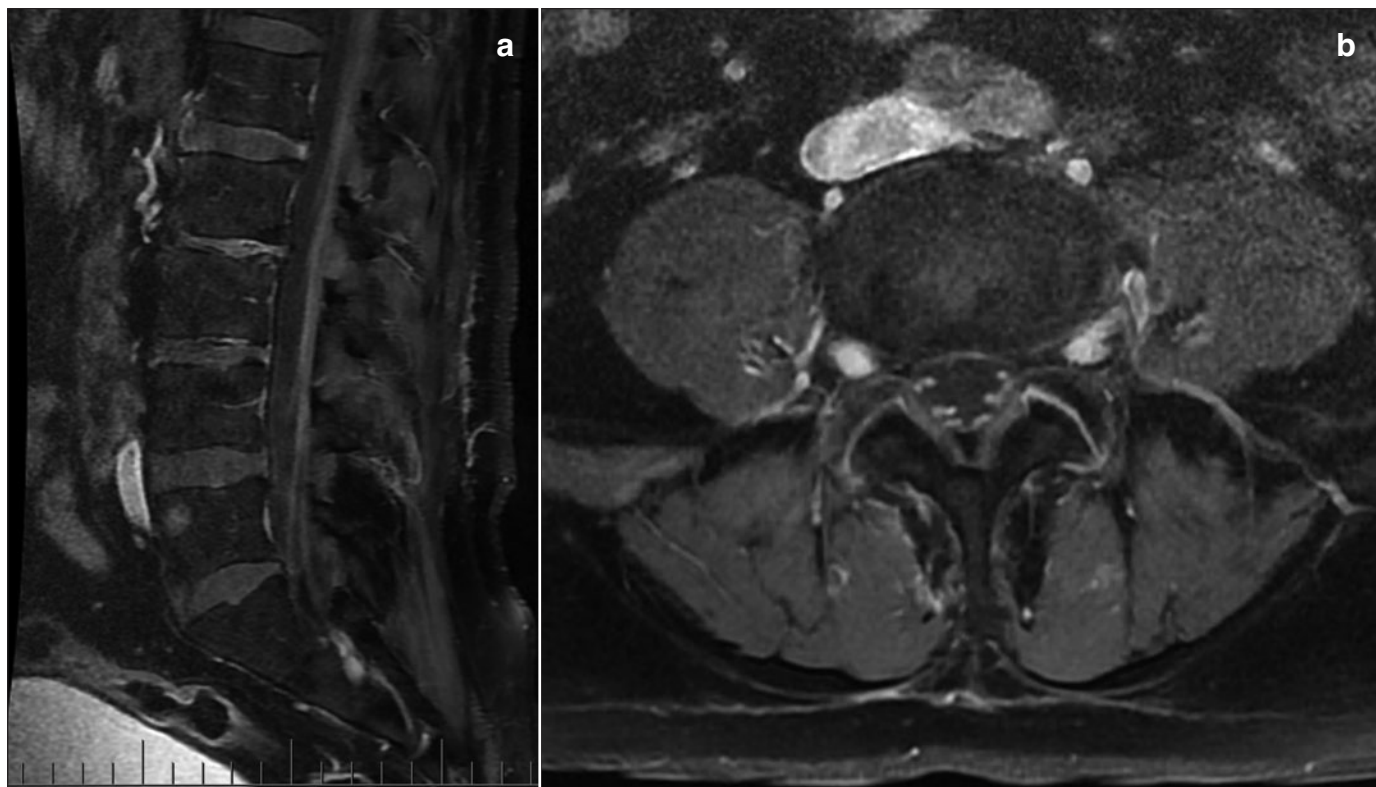


Figure 1: (a) Sagittal and (b) axial T1-weighted MRI with gadolinium demonstrating pathological nerve root enhancement as well as vertebral metastases.

stocking distribution. Cranial nerves and orthostatic vitals were normal.

Viral serology (Hepatitis B, Hepatitis C, CMV, EBV, VZV, HSV, HIV), rheumatoid factor, anti-nuclear antibodies, VDRL and vitamin B₁₂ were all negative or normal. IgM and IgG antibodies to GM1 were positive. Myelin-associated glycoprotein (MAG) antibodies were negative. Cerebral spinal fluid (CSF) evaluation showed markedly elevated protein (2.69 g/L), lymphocytosis (30 cells/mm³), normal glucose, and no dysplastic cells on cytological examination. Nerve conduction studies revealed a picture consistent with a demyelinating sensorimotor polyneuropathy with dramatically increased combined motor action potential distal latencies, decreased conduction velocities as well as evidence of conduction block and temporal dispersion but with only mildly decreased amplitude (Figure 1). Magnetic resonance imaging (MRI) of the head and spine revealed pathological enhancement of the cauda equina on T1-weighted imaging post-gadolinium (Figure 2).

Our patient was treated with a five-day course of intravenous methylprednisolone and intravenous immunoglobulin (IVIG) followed by weekly maintenance infusions. He demonstrated rapid and dramatic improvement of his motor and sensory symptoms, ambulating with the help of a walker within two weeks and near-normal motor and sensory exams within four weeks. Repeat MRI spine four weeks after the initial study did not reveal any frank progression of the enhancement.

Unfortunately, two weeks following discharge to rehabilitation and commencement of chemotherapy, he returned with confusion, fever, pancytopenia and a left lower lobe pneumonia. The motor and sensory exams were unchanged since his last hospitalization. Computed tomogram (CT) brain demonstrated marked hydrocephalus, the cause of which remained unconfirmed but suspected to be due to either leptomeningeal carcinomatosis or dramatically elevated cerebral spinal fluid (CSF) protein due to his CIDP. Given his rapid deterioration and underlying metastatic malignancy, no further investigations were performed and a palliative approach was adopted. The patient passed away shortly thereafter. An autopsy was declined by the family.

DISCUSSION

Chronic inflammatory demyelinating polyneuropathy is an acquired demyelinating disorder affecting the peripheral nerves and nerve roots. The clinical picture is usually of an ascending symmetrical sensorimotor polyradiculoneuropathy with greater motor than sensory involvement, loss of deep tendon reflexes and occasionally back pain. Weakness is both of proximal and distal muscle groups, whilst sensory disturbances are typically in a glove-and-stockings distribution affecting large myelinated fibres, although painful dysesthesias may also occur. Autonomic and cranial nerve involvement is less common.

Typical CIDP CSF samples reveal increased protein but without pleocytosis (<10cells/mm³). Our patient's pleocytosis was moderate and unusual, but in the clinical context did not discount the diagnosis of CIDP. It was felt that CIDP was the correct diagnosis in light of the classical clinical picture, unequivocal multifocal demyelinating pattern on nerve conduction studies and positive response to immunotherapy.

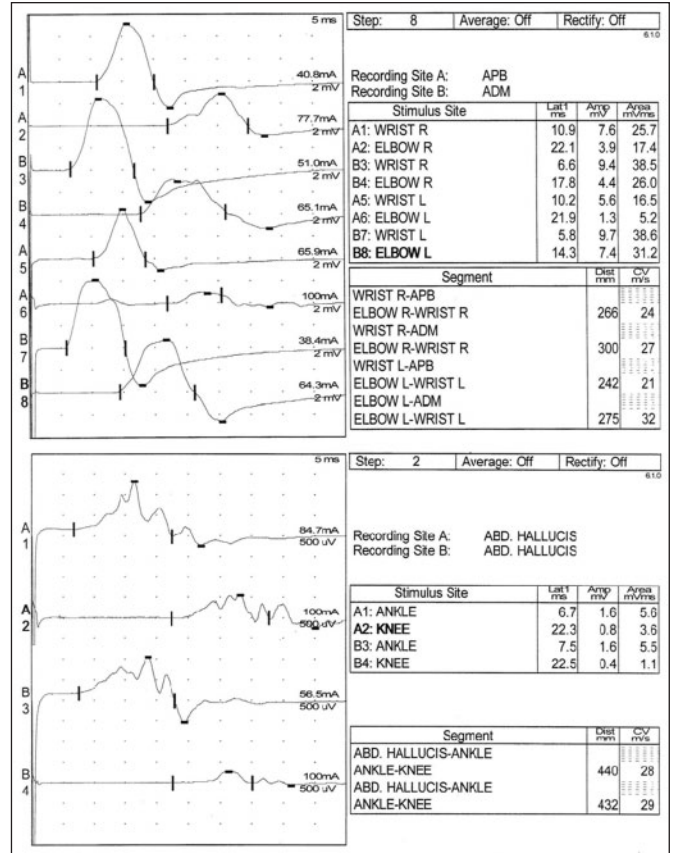


Figure 2: Nerve conduction studies and electromyography of the abductor pollicis brevis (APB), adductor digiti minimi (ADM) and abductor hallucis (ABD hallucis) muscles showing increased distal latencies and decreased conduction velocity of bilateral ulnar, median and tibial nerves whilst the combined motor action potential amplitudes were relatively spared. In addition, there was evidence of conduction block and temporal dispersion.

Also, pathological enhancement of the cauda equina has been frequently described in the context of CIDP.

The circumstantial evidence supporting a paraneoplastic relationship between CIDP and high grade melanoma is intriguing, with this being the eighth reported case of the association (Table).¹⁻⁵ Melanocytes and Schwann cells are both derived from neural crest cells and hence share many antigenic components. Melanocytes undergoing malignant transformation are known to shift and upregulate expression of an antigenic glycolipid component of their cell membrane called gangliosides. Whilst gangliosides are found in all cells, they are particularly concentrated in those of neural crest origin. An autoimmune response to gangliosides has already been established in Guillain-Barré syndrome (GBS), CIDP and multifocal motor neuropathy with conduction block (MMNCB), whilst immunotherapy directed against these antigens in melanoma patients has induced demyelinating polyneuropathies. According to the Paraneoplastic Neurological Syndrome

Table: Summary of eight cases reported in the literature describing an association between metastatic melanoma and CIDP

Ref	Age/ Sex	Melanoma primary	Estimated TNM stage	Melanoma therapy	Onset of CIDP in relation to melanoma diagnosis	Glycolipid + Glycoprotein antibodies tested		CIDP therapy	Associated conditions	Follow-up
						Positive	Negative			
Bird	62/M	unknown	III	surgery	4 months prior	-	GM1, MAG	prednisone, plasmapheresis	vitaligo (1 year)	2 years; no tumor recurrence, strength improved
Bird	43/M	unknown	III	unclear	6 months prior	-	-	prednisone	vitaligo (6 months)	4 years; strength improved
Bird	49/M	sternal	insufficient information	radiotherapy	1 year after	-	-	none	-	-
Weiss	73/F	not reported	insufficient information	surgery, IL-2, interferon- α , melanoma vaccine	12 years after	GM2, SGPG, SGLPG, sulfatide, unidentified glycolipid – all IgM, negative IgG	GM3, GM1, GD3, GD1a, GD2, GD1b, GT1b, GQ1b, MAG	not reported	-	-
Anthony	55/F	left upper arm	IV	surgery, interferon- α	11 years after	GM3 (IgM)	Other anti- glycolipids unstated, HU, YO	IVIG, prednisone	-	some neurological improvement
Rousseau	32/M	unknown	III	surgery	metastasis found during CIDP workup	-	MAG	IVIG	-	3 years; no melanomatous or neurological disease
Palma	66/M	unknown	IV	surgery, interferon- α	1 year after	-	GM1	IVIG	-	2 months; strength improved
Present	67/M	sternal	IV	chemotherapy	1 month after	GM1 (IgM + IgG)	MAG	prednisone, IVIG	NHL (3 years prior, in remission)	4 weeks CIDP resolved; 3 months deceased

Estimated staging is based on the clinical information provided in the articles, using the tumor, node, metastasis (TNM) staging system. Type of immunoglobulin (IgM vs IgG) indicated where data available. GM: monosialoganglioside, GD: disialoganglioside, GT: trisialoganglioside, GQ: tetrasialoganglioside, IVIG: intravenous immunoglobulin, SGPG: sulfoglucuronyl paragloboside, SGLPG: sulfoglucuronyl lactosaminyl paragloboside, MAG: myelin-associated glycoprotein, NHL: non-Hodgkins lymphoma.

Euronetwork, our case would be classified as a possible paraneoplastic syndrome (“a non-classical syndrome, no onconeural antibodies, and cancer present within two years of diagnosis”). Whilst paraneoplastic syndromes are defined as pathogenic rather than coincidental, the rarity and variation of clinical syndromes and current lack of definitive tests will, in many cases such as ours, prohibit such a clear distinction.

Anthony M.T. Chau
University of Sydney, Sydney, Australia
Email: amtchau@gmail.com

Amy Yu, Mark R. Keezer
McGill University, Montréal, Quebec, Canada

REFERENCES

1. Anthony DA, Bone I, Evans TR. Inflammatory demyelinating polyneuropathy: a complication of immunotherapy in malignant melanoma. *Ann Oncol.* 2000;11(9):1197-200.
2. Bird SJ, Brown MJ, Shy ME, Scherer SS. Chronic inflammatory demyelinating polyneuropathy associated with malignant melanoma. *Neurology.* 1996;46(3):822-4.
3. Palma J-A, Martin-Algarra S. Chronic inflammatory demyelinating polyneuropathy associated with metastatic malignant melanoma of unknown primary origin. *J Neurooncol.* 2009;94(2):279-81.
4. Rousseau A, Salachas F, Baccard M, Delattre JY, Sanson M. Chronic inflammatory polyneuropathy revealing malignant melanoma. *J Neurooncol.* 2005;71(3):335-6.
5. Weiss MD, Luciano CA, Semino-Mora C, Dalakas MC, Quarles RH. Molecular mimicry in chronic inflammatory demyelinating polyneuropathy and melanoma. *Neurology.* 1998;51(6):1738-41.