

Characterization of Monocarboxylate Transporters' expression in prostate carcinoma

Nelma Gomes^{*}, José Ramón Vizcaíno^{**}, Céline Pinheiro^{*} and Fátima Baltazar^{*}

^{*} Life and Health Sciences Research Institute (ICVS), School of Health Sciences, University of Minho, Campus of Gualtar, 4710-057 Braga, Portugal;

^{**} Pathology Department, Centro Hospitalar do Porto – Unidade Hospital Geral Stº António, Porto, Portugal.

nelmagom@hotmail.com

Highly proliferative cancer cells maintain high rates of glycolysis, producing large amounts of acids, mainly lactic acid. Despite this fact, only the interstitial pH of tumours is low, while the intracellular pH of tumours is either normal or higher than that of normal tissues [1, 2]. Monocarboxylate transporters (MCTs) are transmembrane proteins that, by promoting the efflux of the accumulating acids, constitute one of the most important mechanisms in the maintenance of tumour intracellular pH. MCTs play a central role in cellular metabolism and are essential for the transport of metabolically important monocarboxylates, such as lactate, across the plasma membrane [3]. As a result, MCTs constitute attractive targets for cancer therapy, which have not been explored yet [4]. There are evidences for the upregulation of MCTs in solid tumours, such as Ehrlich ascites tumours, high grade glial neoplasms, colorectal carcinoma[5], cervix carcinoma[6] and alveolar sarcoma of soft tissues, however, there are no data on prostate cancer. This study aims to characterize for the first time the immunoexpression of MCT1, 2, 4 and CD147, a protein required for proper membrane expression and activity of MCT1 and MCT4 [7], in a well characterized series of 114 cases of prostate carcinoma organized into Tissue microarrays (TMAs). The clinico-pathological value of protein immunoexpressions was also assessed. This pioneer study revealed that, for the 3 MCTs isoforms studied, statistically significant differences were observed between carcinoma samples and adjacent normal epithelium (Fig.1). Immunoexpression of MCT1 in the adjacent normal epithelium was significantly increased, when compared to tumour cells, while MCT2 and MCT4 were more frequently expressed in tumour cells than in the adjacent normal epithelium. There were no statistically significant differences in CD147 expression between the adjacent normal epithelium and tumour cells. MCT1 staining was more frequent in the basal and lateral cell borders, with an absence of staining in the apical membrane. Staining for MCT4 and MCT2 was mainly observed in the cytoplasm of tumour cells, what suggests that they could have important functions in the membrane of some cellular organelles. Assessment of correlation between MCT4 expression and the clinico-pathological data revealed a positive association between MCT4 positivity and low PSA levels, affected surgical margin and presence of biochemical recurrence. There were no significant correlations between both CD147, MCT1 and MCT2 expressions and the clinico-pathological data. The specificity and sensitivity of MCT2 tumour staining led us to hypothesize that this MCT

isoform may be explored as a new tumour marker in prostate carcinoma. These results support a metabolic pathway different from glycolysis in prostate cancer, where the participation of MCTs is poorly understood.

References

- [1] C.Dang, G. Semenza, Trends Biochem Sci, 24(2) (1999) 68.
- [2] G.Helmlinger, A. Sckell, Clin Cancer Res, 8 (2002) 1284.
- [3] A.Halestrap, D.Meredith, Pflugers Arch, 447 (2004) 619.
- [4] H.Izumi, K.Kohno, Cancer Treat. Rev, 29, (2003) 541.
- [5] C.Pinheiro, F.Baltazar, Virchows Arch, 452 (33) (2008)139.
- [6] C.Pinheiro, F.Baltazar, Int J Gynecol Pathol; 27 (4) (2008) 568.
- [7] P.Kirk, M.Wilson, Embo J; 19 (2000) 3896.

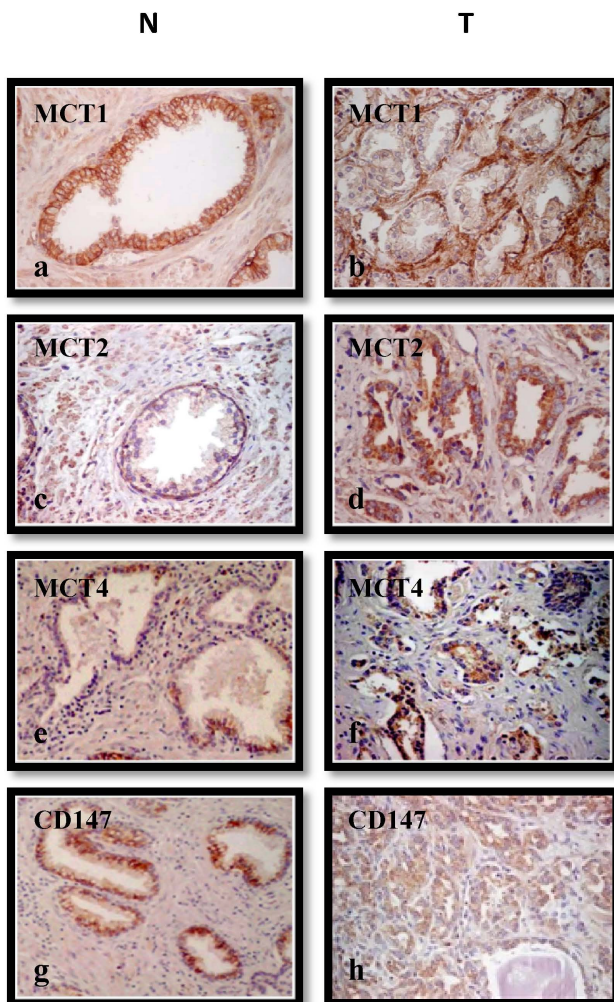


Fig.1 Immunohistochemical expression of MCT1, 2, 4 and CD147 in prostate carcinoma samples. Staining in tumour cells (T) (b, d, f and h: MCT1, MCT2, MCT4 and CD147, respectively) and in the adjacent normal epithelium (N) (a, c, e and g: MCT1, MCT2, MCT4 and CD147 respectively).