

Pathology of Eosinophilic Fasciitis and its Relation to Polymyositis

Ke-Wei Huang and Xiao-Han Chen

ABSTRACT: The anatomical substrate of eosinophilic fasciitis (EF) was studied in 15 muscle biopsy specimens of this disease, six of which included the dermis and subcutaneous tissue. As controls, 94 postmortem muscle specimens from patients dying of non-muscular diseases were used. Of these 94 specimens, 22 (23.4%) showed practically no deep fascia and 72 specimens showed a single dense bundle of collagen with no distinction between deep fascia and epimysium. The 15 specimens of EF showed thickening and inflammatory infiltration of varying degrees in the deep fascia, epimysium, perimysium, endomysium and also in muscle. We conclude that the anatomical substrate of EF is not confined to the deep fascia, but involves other structures including myofascia and muscle itself. Most reported cases of EF in the literature do not even describe muscle. A comparative study of 15 biopsy specimens of polymyositis and dermatomyositis with those of EF revealed only quantitative differences in the histopathological changes of muscle and myofascia, inflammatory infiltrate and eosinophilia. We suggest that the diseases are more closely related than previously recognized.

RÉSUMÉ: L'anatomo-pathologie de la fasciite à éosinophiles et sa relation avec la polymyosite. Quinze spécimens anatomo-pathologiques obtenus par biopsies musculaires chez des sujets atteints de fasciite à éosinophiles (FE) ont été étudiés. Six de ces spécimens comprenaient le derme et du tissu sous-cutané. Quarante-vingt-quatorze spécimens de muscle obtenus à partir de matériel d'autopsie provenant de patients décédés de maladies autres que de maladies musculaires ont été utilisés comme contrôles. Parmi ces 94 spécimens, on ne retrouvait pratiquement pas d'aponévrose profonde dans 22 (23.4%) spécimens et on ne retrouvait qu'un seul faisceau dense de collagène, sans distinction entre l'aponévrose profonde et l'épimysium, dans 72 spécimens. Dans les 15 spécimens de FE, on retrouvait un épaississement et un infiltrat inflammatoire d'importance variable dans l'aponévrose profonde, l'épimysium, le perimysium et l'endomysium ainsi que dans le muscle. Nous concluons que les lésions anatomiques de l'EF ne sont pas limitées à l'aponévrose profonde, mais impliquent d'autres structures incluant les myofascia et le muscle lui-même. Pour la majorité des cas rapportés dans la littérature, il n'y a pas de description du muscle. Une étude comparant 15 biopsies de polymyosite et de dermatomyosite avec celles de FE n'a montré que des différences quantitatives dans les changements histopathologiques au niveau du muscle et des myofascia, dans l'infiltrat inflammatoire et dans l'éosinophilie. Nous suggérons que ces maladies sont plus étroitement reliées qu'on ne le croyait antérieurement.

Can. J. Neurol. Sci. 1987; 14:632-637

Since Shulman's first report in 1974,¹ more than 100 cases of eosinophilic fasciitis (EF) have been reported from many parts of the world, including 21 cases in China.² The main symptoms are swelling and stiffening of skin on arms and legs with difficulty in movement due to flexion contracture, weakness, and muscle pain. These clinical features are associated with both peripheral and tissue eosinophilia and hyperglobulinemia, though there are 16 reported cases without eosinophilia and 11 without hyperglobulinemia.³⁻¹⁰ Histologically, there is a marked thickening of the deep fascia with striking inflammation.^{11,12} Many authors contend that thickened fascia is the hallmark of the disease, associated with no or only minimal involvement of muscle.^{4,8,13-22} A few authors have found mild involvement of muscle in eosinophilic fasciitis.^{23,24} If the pathology is limited to the deep fascia only, it is difficult to explain the contracture

and muscular induration, and still more difficult to understand the weakness of the involved limb so often encountered clinically.

Although Shulman and later workers maintain eosinophilic fasciitis to be a disease entity,¹ some authors believe that EF may not be an independent disease: Caperten et al suggest that morphea, fasciitis, and scleroderma with eosinophilia all belong to a broad spectrum of similar disease.²⁵

Since the first observation of primary idiopathic myositis made by Wagner in 1863 (quoted by Thayer 1902),²⁶ many investigators consider polymyositis and dermatomyositis a separate disease.²⁷ Recently, some authors mention polymyositis in eosinophilic fasciitis.²⁸ Hans et al believe that the clinical pattern of eosinophilic fasciitis bears a certain resemblance to polymyositis, and that many patients with polymyositis exhibit clinical features simulating Shulman syndrome.²⁹ Other authors

From the Neuropathology Laboratory, Chinese PLA General Hospital, Beijing, People's Republic of China

Received November 13, 1986. Accepted in final form July 14, 1987

Reprint requests to: Dr. Ke-Wei Huang, Professor of Neurology, Chinese PLA General Hospital, Military Post Graduate Medical School, 28 Fu-Xing Road, Beijing, People's Republic of China

have reported eosinophilic polymyositis^{6,27,30,31} or eosinophilic perimyositis.⁷

The anatomical basis of eosinophilic fasciitis is not yet firmly established and its status as an independent disease is still in question. This study was therefore undertaken to investigate the histopathological changes in this disease, in relation to those of polymyositis and dermatomyositis.

MATERIALS AND METHODS

Ninety-four postmortem muscle specimens were taken from 42 patients (22 male; 20 female) dying of non-muscular diseases (age span 5-72 years) as controls. Of these specimens, 24 were from the deltoid; 18 from forearm muscles; 23 from the quadriceps femoris; and 29 from the gastrocnemius. All specimens included skin, subcutaneous tissue and muscle, and were prosected within 48 hours after death.

The clinical diagnosis of eosinophilic fasciitis was based on the following criteria; 1) contracture and/or induration of muscle with or without skin rash; 2) weakness and/or muscle pain; 3) eosinophilia in peripheral blood; 4) increase of erythrocyte sedimentation rate; 5) increase of serum immunoglobulin (IgG). The diagnosis was established if the first criterion, contracture and/or induration of muscle, combined with two other criteria, because many previously reported cases were not associated with peripheral eosinophilia or hyperglobulinemia.

Biopsy specimens were taken from 15 patients of eosinophilic fasciitis, 9 males and 6 females whose ages ranged from 8 to 50 years. The course of the disease varied from 4 to 72 months. The clinical and laboratory findings in these patients is summarized and compared with those in 15 patients with polymyositis in Table I. Electromyography (EMG) was performed in all 15 patients with EF. Myopathic changes were demonstrated in 11, neuropathic patterns were detected in 3, and one was normal. Ten patients were treated with steroids and 7 improved.

The biopsy specimens in EF were from the following muscles: 1 pectoralis major, 2 deltoids, 2 biceps brachii, 4 forearm muscles, 2 quadriceps femoris, and 4 gastrocnemius. Five biopsies included skin, subcutaneous tissue, deep fascia and epimysium, and one biopsy did not include skin. The other 9 biopsies were of muscle alone.

A clinical diagnosis of polymyositis (including dermatomyositis) was based on weakness and muscular pain of the proximal

portions of limbs together with increased serum CK and/or myopathic change on EMG. Patients with contracture and/or induration of muscles were not included. Weakness and pain of the proximal portions of limbs were present in all 15, associated with difficulty in swallowing in 8, low-grade fever in 3, Raynaud's phenomenon in 1 and rash in 4. Serum IgG was determined in 10 and increased in 6. Serum CK was increased in 7 of the 15 patients. EMG was performed in 13, and showed myopathic changes in 11, neuropathic alterations in 1, and a normal pattern in 1. The sites of biopsy were as follows: 1 intercostal muscle; 2 supraspinatus, 5 deltoid, 3 quadriceps femoris and 4 gastrocnemius.

For light microscopy, the specimens were fixed in 4% formalin and embedded in paraffin. Routine sections were stained with hematoxylin and eosin and van Gieson connective tissue stain.

RESULTS

Cutaneous fascia consists of two portions: a superficial layer of loose connective tissue extending between the dermis and deep fascia, and a deeper thin but dense layer of connective tissue near the epimysium (Figure 1).³² Of 94 specimens of normal control muscle with covering skin, deep fascia and epimysium were observed in 85, of which the deep fascia could not be distinguished from the epimysium in 72 (Figure 2). The deep fascia and epimysium presented as a thin, loose layer of collagen fibres in 13 others (Figure 3). Among the 72 specimens with dense deep fascia and epimysium, 18 were from the deltoid, 12 from the forearm, 19 from quadriceps femoris, and 23 from gastrocnemius. Among the 13 samples with thin and loose deep fascia and epimysium, 3 were from forearm, 1 from quadriceps femoris and 4 from gastrocnemius. In the remaining 9 specimens neither deep fascia nor epimysium was found (Figure 4); 3 of these samples were from deltoid, 1 from forearm, 3 from quadriceps femoris and 2 from gastrocnemius. Of 94 cases, 23.4% exhibited little or no deep fascia.

The histological findings in the muscle specimens of patients with eosinophilic fasciitis and polymyositis are summarized in Table II. Of particular note are the contrasts in thickening of deep fascia, perimysium and endomysium, the degree of hyaline, granular, floccular, and vacuolar degeneration, myofibre atrophy, and inflammatory infiltrates (Figures 5-7). The EF cases, eosinophils infiltrated mainly in the deep fascia-epimysium and

Table 1: Clinical Features and Laboratory Findings of Patients with Eosinophilic Fasciitis and Polymyositis

Clinical features	examined cases		positive cases		Laboratory findings	examined cases		positive cases	
	EF	PM	EF	PM		EF	PM	EF	PM
muscular contracture and induration	15	15	11	0	eosinophilic count	15	12	7	0
contracture of muscle alone	15	15	2	0	erythrocyte sedimentation rate	12	7	6	5
induration of muscle alone	15	15	2	0	serum IgG	9	10	8	6
weakness and muscular pain	15	15	5	15	creatine phosphokinase (CK)	12	15	7	7
weakness of muscle alone	15	15	3	15	GPT	12	15	0	5
muscular pain alone	15	15	3	15	urinalysis	10	15	0	2
difficulty in swallowing	15	15	0	8	EMG	15	13	11	11
Raynaud's phenomenon	15	15	0	1	ECG	10	15	0	7
low-grade fever	15	15	0	3	chest X-ray	10	15	0	0
skin rash (erythema)	15	15	2	4	respond to steroid	10	11	7	3

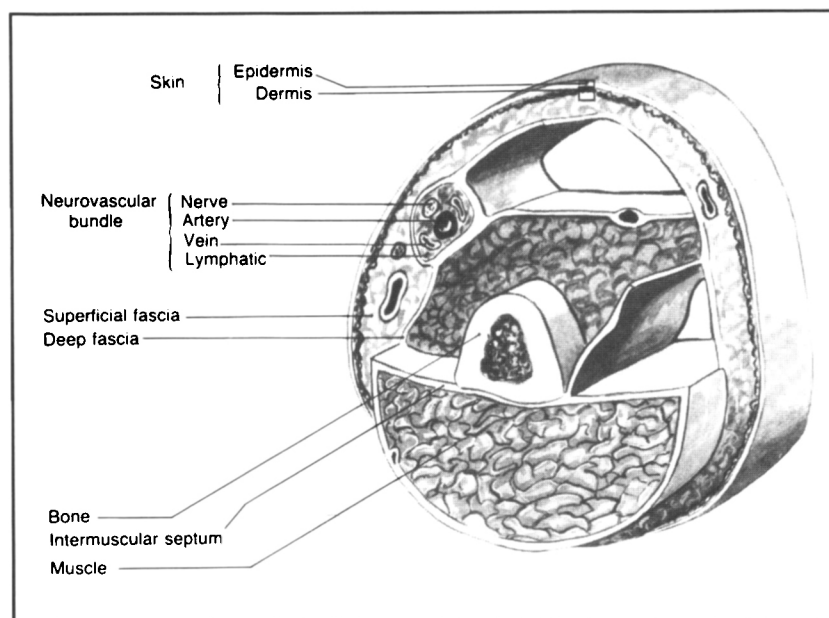


Figure 1 — Diagram of a segment of the upper arm in cross section to show the relationship between skin, superficial fascia and deep fascia.

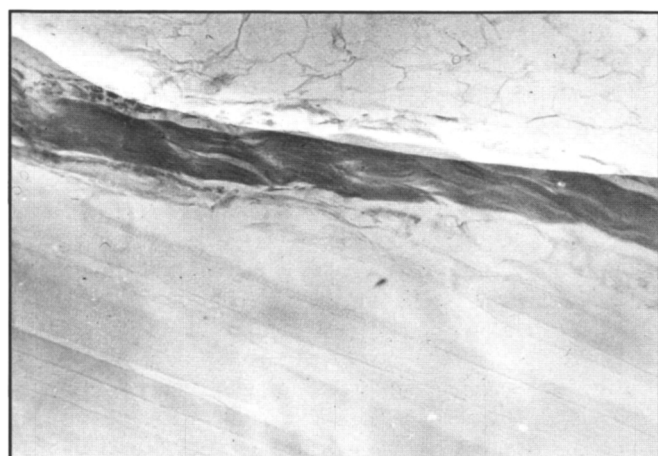


Figure 2 — Normal deep fascia-epimysium formed by a single bundle of dense collagen fibres. van Gieson stain. X500

perimysium, and less commonly in the endomysium. Of the 11 of 15 biopsies in which eosinophils were demonstrated, the intensity of infiltration was rated as mild in 3, moderate in 2, strong in 2, and intense in 4.

Inflammation was demonstrated in all 15 muscle biopsies of patients with polymyositis or dermatomyositis, in the perimysium in 14 and involving the endomysium in all cases. While the lymphocyte was the predominant inflammatory cell in all, eosinophils were found in 5 biopsies, to a mild degree in 4 and moderate in 1 (Figure 8). Histological findings are summarized in Table 2.

DISCUSSION

In 22 of 94 control samples, or 23.4% of normal individuals, the deep fascia is lacking. One may therefore conjecture that in one-fifth of all cases of eosinophilic fasciitis, the pathological

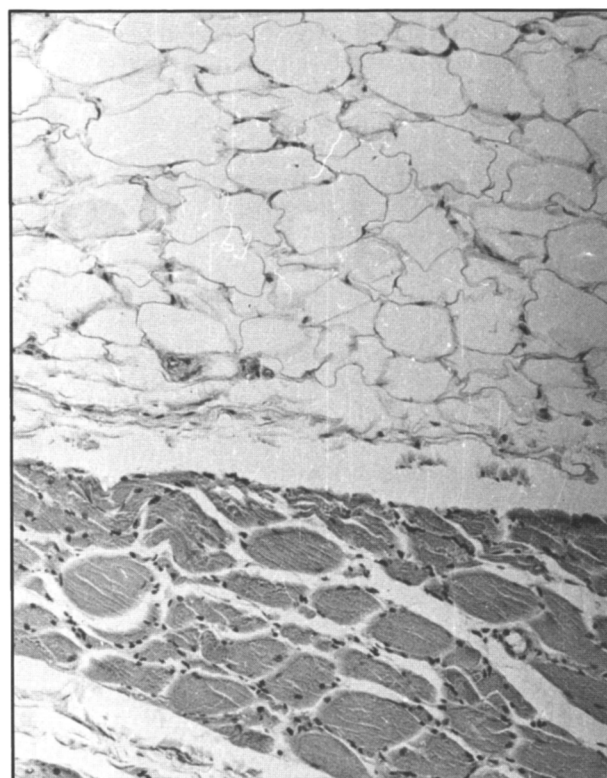


Figure 3 — Normal deep fascia-epimysium formed by a very thin and loose layer of collagen fibres. H&E. X250.

lesion is not in the deep fascia alone, though in all 6 specimens with skin and subcutaneous tissue in our series, the deep fascia-epimysium was indeed thickened. Had the skin and subcutaneous tissue been included in the other 9 cases of fasciitis, there might have been 2 or 3 specimens with no involvement of deep

fascia owing to its absence. A question thus arises whether the deep fascia or the epimysium played a major role in forming the dense bundle in 6 of the samples; the epimysium at least contributed, even if deep fascia involvement was the main component. Furthermore, 2 of the 6 specimens of fasciitis showed only slight thickening of the deep fascia-epimysium, but severe thickening of perimysium and endomysium, another argument against the view that only the deep fascia bears the brunt.

In the other 9 samples of fasciitis, detached from deep fascia-epimysium, 6 showed severe thickening of perimysium and 3 only slight thickening of perimysium, while 6 showed slight thickening of endomysium. Thus myxia, particularly perimysium, make an important contribution to the pathology.

Of the 15 samples of fasciitis, there was degeneration of muscle fibres of varying degrees in 14 specimens, 6 of which also showed atrophy and 3 with a perifascicular distribution. Besides the inflammatory infiltration in the deep fascia-epimysium of 6 cases of fasciitis, a similar infiltration was observed in perimysium of all 15 cases and in the endomysium of 10 cases. The morbid change thus was not limited to the deep fascia, but also involved epimysium, perimysium, endomysium and muscle fibres. It may be concluded that the anatomical substrate of eosinophilic fasciitis is not deep fascia alone, but includes myxia and muscle.

The discrepancy between our findings and those in previously reported cases is prominent. Reviewing the literature reveals that most reports on the pathology of eosinophilic fasciitis

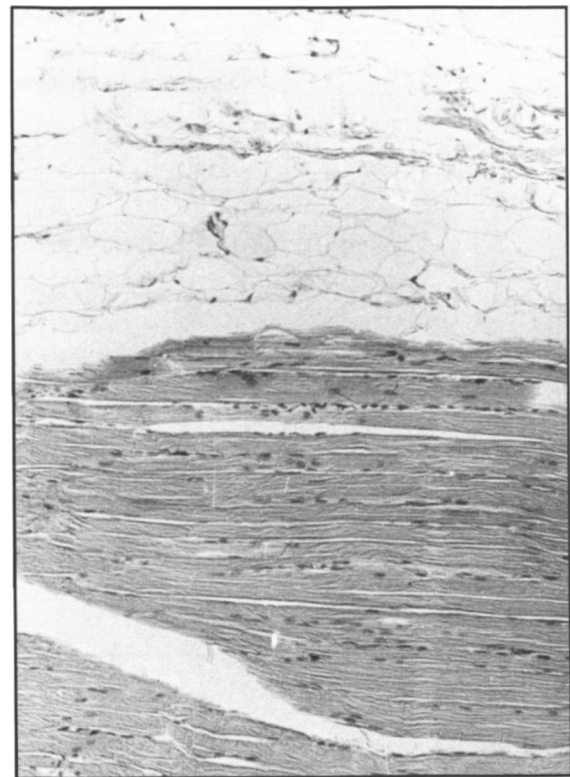


Figure 4 — Absence of deep fascia-epimysium. H&E. X250.

Table 2: Histological findings in 15 patients with eosinophilic fasciitis and 15 patients with polymyositis

	eosinophilic fasciitis															polymyositis															
	1	2	3	4	5	6	7	8	9	10	11	12	13	14	15	1	2	3	4	5	6	7	8	9	10	11	12	13	14	15	
I thickening of deep fascia-epimysium	0	0	0	0	0	0	1+	0	3+	0	1+	1+	0	3+	3+	0	0	0	0	0	0	0	0	0	0	0	0	0	0		
II thickening of perimysium	3+	3+	1+	2+	3+	1+	1+	1+	2+	3+	3+	3+	3+	3+	2+	2+	—	1+	—	2+	—	—	2+	1+	3+	—	1+	—	1+	2+	
III thickening of endomysium	2+	1+	—	1+	1+	—	1+	—	2+	3+	3+	3+	3+	1+	3+	2+	—	—	—	—	2+	—	—	1+	—	3+	—	2+	—	—	2+
IV muscular degenerations																															
hyaline	3+	—	—	—	2+	1+	1+	—	2+	2+	2+	2+	—	2+	2+	1+	1+	1+	3+	1+	2+	1+	2+	1+	1+	3+	2+	1+	2+		
granular	2+	—	—	1+	2+	—	2+	1+	2+	2+	2+	3+	1+	2+	2+	2+	2+	3+	3+	2+	2+	3+	2+	3+	3+	2+	3+	3+	2+	3+	
vacuolar	2+	—	—	—	1+	—	—	—	—	2+	1+	3+	—	1+	—	—	—	2+	3+	1+	—	1+	1+	3+	2+	1+	2+	3+	—	3+	
flocular	1+	1+	—	—	1+	—	—	—	—	—	2+	2+	—	—	—	1+	1+	2+	3+	—	—	1+	—	2+	3+	1+	2+	2+	—	2+	
phagocytosis	2+	1+	1+	1+	1+	1+	1+	1+	2+	2+	1+	2+	—	—	1+	2+	2+	2+	3+	2+	1+	2+	1+	2+	2+	2+	2+	2+	3+	2+	
V regeneration	2+	—	—	—	1+	—	1+	1+	1+	1+	1+	1+	1+	—	—	2+	1+	1+	2+	2+	2+	2+	1+	2+	2+	2+	2+	2+	2+	1+	
VI muscular atrophy																															
general	3+	—	—	—	—	—	—	—	—	2+	2+	—	3+	—	1+	2+	—	1+	2+	2+	2+	2+	3+	3+	3+	3+	2+	2+	2+	2+	2+
perifascicular	—	—	—	—	—	—	—	—	—	1+	—	—	1+	—	—	1+	—	—	—	—	—	—	1+	—	—	—	1+	—	1+	1+	
VII cellular infiltrations (lymphocytes and plasma cells)																															
subcutaneous tissue	0	0	0	0	0	0	3+	0	3+	0	2+	—	0	0	3+	0	0	0	0	0	0	0	0	0	0	0	0	0	0		
deep fascia-epimysium	0	0	0	0	0	0	2+	0	2+	0	3+	1+	0	—	3+	0	0	0	0	0	0	0	0	0	0	0	0	0	0		
perimysium	3+	3+	2+	2+	3+	2+	3+	—	3+	3+	3+	3+	2+	3+	3+	2+	2+	1+	2+	—	3+	3+	1+	1+	3+	1+	3+	2+	2+	1+	
endomysium	—	1+	—	—	1+	1+	1+	—	2+	2+	1+	1+	—	1+	2+	2+	1+	—	1+	1+	2+	2+	1+	1+	3+	—	3+	1+	—		
muscle	—	—	—	—	—	1+	1+	—	1+	1+	—	1+	1+	—	1+	1+	2+	1+	2+	1+	2+	2+	1+	2+	2+	2+	1+	1+	2+	2+	
VIII eosinophilic infiltration																															
mysiums	2+	2+	—	1+	4+	—	—	—	3+	1+	4+	—	3+	4+	1+	2+	—	1+	—	—	—	—	—	—	—	—	1+	—	—	—	
muscle	—	—	—	—	—	—	—	—	—	—	—	—	4+	—	—	—	—	—	1+	—	—	—	—	—	—	1+	—	—	—	—	

— = normal; 1+ = mild; 2+ = moderate; 3+ = marked; 0 = not done. eosinophilis were quantified according to the following scale: 1+ = 0-2/height-power field (HPF); 2+ = 3-5/HPF; 3+ = 6-9/HPF; 4+ = 10 or more/HPF.

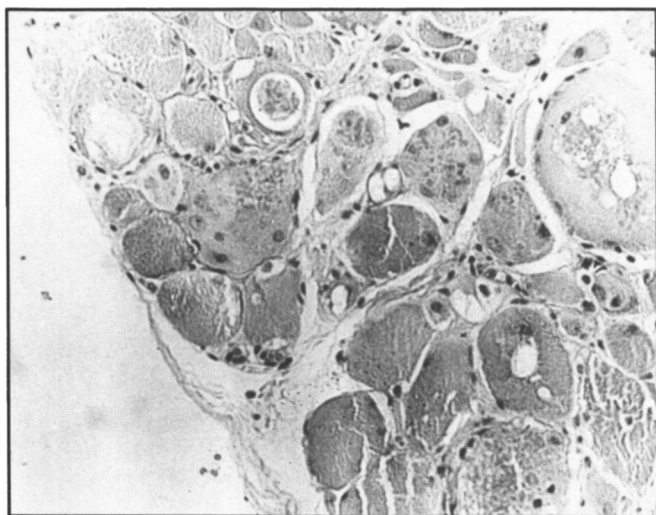


Figure 5 — Case 12. Eosinophilic fasciitis. Granular, vacuolar and floccular degeneration is accompanied by inflammatory cells. H&E. X250.

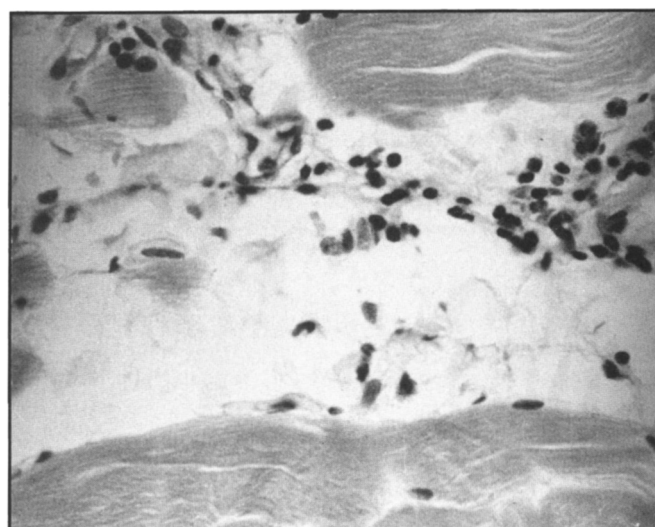


Figure 8 — Case 16. Polymyositis. Eosinophils in muscle are occasionally found, though not the predominant inflammatory cell. H&E. X500.

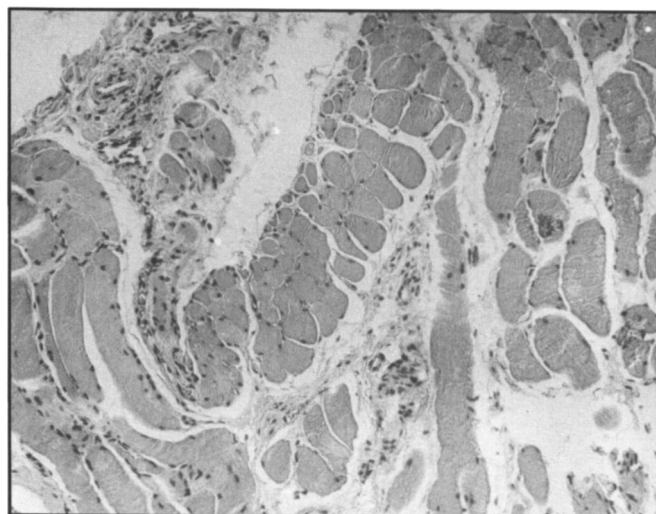


Figure 6 — Case 12. Eosinophilic fasciitis. Atrophic muscle fibres follow a perifascicular distribution similar to that of dermatomyositis. H&E. X100.

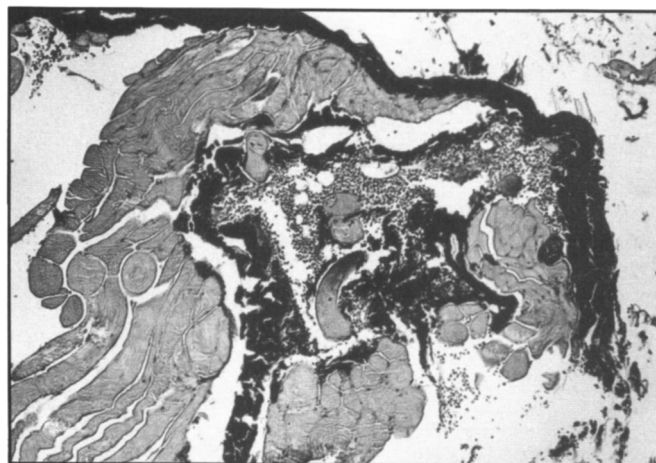


Figure 7 — Case 20. Polymyositis. Thickening of perimysium and endomysium. van Gieson stain. X100.

were based on the histological study of the skin, excluding the investigation of muscle and its myosia. Bennett et al reported one case of eosinophilic fasciitis in which muscle was not available for histological examination.¹⁵ Weinstein and Schwartz also reported a case of eosinophilic fasciitis with no muscle in the biopsy specimen.³³ Tamura et al did not mention the status of muscle in their case.¹¹ Coyle and Chapman only described the change of deep fascia without remarking on the condition of muscle in their case.³⁴ Moore and Zuckner similarly failed to provide a description of muscle in their case.¹² Patrone and Kredich stated only that the changes were consistent with a diagnosis of eosinophilic fasciitis.³⁵ Some authors examined only the most superficial portions of muscle;^{14,36} others only studied a small fragment of muscle.¹⁷ Other articles reveal interesting data, however. Fleischmajer et al reported 6 cases of eosinophilic fasciitis in which muscle was essentially normal in one, there was no necrosis of muscle in the second, and muscle was not included in the investigation of the other four.³ Moutsopoulos et al reported 3 cases of eosinophilic fasciitis, making no mention of muscle in the first, finding no lesions of muscle in the second, and stating that muscle tissue was unavailable in the third.³⁷ Most reports of eosinophilic fasciitis were made by dermatologists or rheumatologists who focussed on the skin fascia, neglecting muscle and its myosia. We thus conclude that the controversy between our view and that expressed in the literature is only apparent, because the literature provides insufficient data from which to generalize.

From our data in 15 cases of eosinophilic fasciitis and 15 cases of polymyositis and dermatomyositis, a question arises whether these two groups really represent different disease entities. Among the 15 cases of eosinophilic fasciitis, 11 patients had muscular complaints clinically (5 with weakness and pain, 3 with weakness alone, and 3 with muscular pain alone), and in 14 varying degrees of muscular degeneration and/or myofibre atrophy was demonstrated histologically. Of our 15 cases of polymyositis and dermatomyositis, by contrast, there were 9 cases with focal thickening of perimysium and endomysium, and 5 cases exhibited tissue eosinophilia. Serum IgG was increased in 6 of 10 cases studied.

Before the start of the present study, it had been accepted that contracture and induration of muscle were distinguishing clinical features of eosinophilic fasciitis. This misconception led us to exclude all patients with contracture and/or induration of muscle from the group of polymyositis. Barwick and Walton reported 52 cases of polymyositis and reviewed another 100 cases from the literature; of these 152 cases of polymyositis, 39 had contractures.³⁸ These features are therefore shared by both groups. Dancea et al, in a comparative ultrastructural study of eosinophilic fasciitis and eosinophilic polymyositis, found similar changes in both cases.³⁹ We therefore propose that the differences between eosinophilic fasciitis and polymyositis are of degree but not of fundamental nature; it is logical to conclude that they are closely related.

REFERENCES

- Shulman LE. Diffuse fasciitis with hypergammaglobulinemia and eosinophilia: A new syndrome? *J Rheumatol* 1974; 1 (suppl): 46.
- Yuan Y, Li JD, Liu JW, Li YS and Zhang BR. Sclerotic fasciitis. A clinical and pathologic analysis of 21 cases. *Chinese Med J* 1984; 97: 515-525.
- Fleischmajer R, Jacotot AB, Shore S and Binnick SA. Scleroderma, eosinophilia and diffuse fasciitis. *Arch Dermatol* 1978; 114: 1320-1325.
- Barnes L, Rodnan GP, Medsger Jr. TA, Short D. Eosinophilic fasciitis: A pathologic study of twenty cases. *Am J Pathol* 1979; 96: 493-507.
- Lupton GD and Goette DK. Localized eosinophilic fasciitis. *Arch Dermatol* 1979; 115: 85-87.
- Stark RJ. Eosinophilic polymyositis. *Arch Neurol* 1979; 36: 721-722.
- Serratrice G, Pellissier JF, Gros D, Gastaut JL, Brinisisi G. Relapsing eosinophilic perimyositis. *J Rheumatol* 1980; 7: 199-205.
- Michet CJ Jr, Doyle JA, Ginsburg WW. Eosinophilic fasciitis: Report of 15 cases. *Mayo Clin Proc* 1981; 56: 27-34.
- Cohen MD, Allen GL. Eosinophilic fasciitis and sarcoidosis: A case report. *J Rheumatol* 1982; 10: 347-349.
- Hoffman R, Young N, Ershler WB, Mazur E, Gewirtz. Diffuse fasciitis and aplastic anemia: A report of four cases revealing an unusual association between rheumatologic and hematologic disorders. *Medicine* 1982; 61: 373-381.
- Tamura T, Saito Y, Ishikawa H. Diffuse fasciitis with eosinophilia: Histological and electron microscopic study. *Acta Dermatovener* 1979; 59: 325-331.
- Moore TL and Zuckner J. Eosinophilic fasciitis. *Arthritis Rheum* 1980; 9: 228-235.
- Rodnan GP, Dibartolomeo AG, Medager TA Jr, et al. Eosinophilic fasciitis: Report of six cases of a newly recognized scleroderma-like syndrome. *Clin Res* 1975; 23: 443 (abstracted).
- Schumacher HR. A scleroderma-like syndrome with fasciitis and eosinophilia. *Ann Intern Med* 1976; 94: 49-50.
- Bennett RM, Kerran A, Keogh L. Eosinophilic fasciitis. Case report and review of the literature. *Ann Rheum Dis* 1977; 36: 354-359.
- Krause RE, Tuthill RJ. Eosinophilic fasciitis. *Arch Dermatol* 1977; 113: 1092-1093.
- Torres VM, George WM. Diffuse eosinophilic fasciitis: A new syndrome or variant of scleroderma? *Arch Dermatol* 1977; 113: 1591-1593.
- Shewmake SW, Lopez DA, and McGlamory JC. Shulman syndrome. *Arch Dermal* 1978; 114: 556-589.
- Abeles M, Belin DC, Zurier RB. Eosinophilic fasciitis. A clinicopathologic study. *Arch Intern Med* 1979; 139: 586-588.
- Sills EM. Diffuse fasciitis with eosinophilia in childhood. *Johns Hopkins Med J* 1982; 151: 203-207.
- Bertken R, Schaller D. Chronic progressive eosinophilic fasciitis: Report of a 20-year failure to attain remission. *Ann Rheumat Dis* 1983; 42: 103-105.
- Schulman LE. Diffuse fasciitis with hypergammaglobulinemia and eosinophilia: A new syndrome? *J Rheumatol* 1984; 11: 569-570.
- Kent LT, Cramer SF, Moskowitz RW. Eosinophilic fasciitis. Clinical, laboratory and microscopic consideration. *Arthritis Rheum* 1981; 24: 677-683.
- Ormerod AD, Grieve JH, Rennie TAN, Edward N. Eosinophilic fasciitis a case with hypogammaglobulinaemia. *Clin Exp Dermatol* 1984; 9: 426-418.
- Caperten EM, Hathaway DE, Dehner LP. Morphea, fasciitis and scleroderma with eosinophilia: A broad spectrum of disease. *Arthritis Rheum* 1976; 19: 792-793 (abstracted).
- Thayer WA. Notes on a case of acute hemorrhagic polymyositis. *Boston Med Surg J* 1902; 147: 313-317.
- Kakulas BA, Adams RD. Eosinophilic polymyositis. *Disease of Muscle*. 4th ed. New York: Harper and Row. 1985; 513-514.
- Bjelle A, Henriksson KG, Hofer PA. Polymyositis in eosinophilic fasciitis: Review and case report. *Eur Neurol* 1980; 19: 128-137.
- Hans L, Bulcke JA, De Meirsman J, Dom R, Velghe L. Un diagnostic différentiel de la polymyosite: Le Syndrome de Shulman. Fasciite diffuse avec éosinophilie. *Rev Neurol* 1981; 137: 203-210.
- Layzer RB, Shearn MA, Satya-Murti S. Eosinophilic polymyositis. *Ann Neurol* 1977; 1: 66-71.
- Dancea S, Montpetit V, Olberg B. Observations on two cases of eosinophilic polymyositis. *J Neuropathol Exp Neurol* 1986; 45: 371 (abstracted).
- Leeson CR, Leeson TS. The skin and fascia. Human structure. A Companion to Anatomical Study. London: WB Saunders Company. 1972; 6-8.
- Weinstein D, Schwartz RA. Eosinophilic fasciitis. *Arch Dermatol* 1978; 114: 1047-1049.
- Coyle HE, Chapman RS. Eosinophilic fasciitis (Shulman Syndrome) in association with morphea and systemic sclerosis. *Acta Dermatol* 1980; 60: 181-182.
- Patrone NA, Kredich DW. Eosinophilic fasciitis in a child. *Am J Dis Child* 1984; 138: 363-365.
- Gray RG. Eosinophilic fasciitis: A scleroderma-like illness. *JAMA* 1977; 237: 529-530.
- Moutsopoulos HM, Webber BL, Fostilopoulos G and Shulman LE. Diffuse fasciitis with eosinophilia. A clinicopathologic study. *Am J Med* 1980; 68: 701-709.
- Barwick DD, Walton JN. Polymyositis. *Am J Med* 1963; 35: 646-660.
- Dancea S, Montpetit V, Clapin D. Eosinophilic polymyositis (EP) and eosinophilic fasciitis (EF): A comparative ultrastructural study. *Can J Neurol Sci* 1987; 14: 100 (abstracted).