

## Letter to the Editor: New Observation

# A Case of Paroxysmal Tonic Spasms in Pediatric Neuromyelitis Optica Spectrum Disorder

Emanuel Mostofi<sup>1</sup>  and Colin Wilbur<sup>1,2</sup> 

<sup>1</sup>Department of Pediatrics, University of Alberta, Edmonton, AB, Canada and <sup>2</sup>Women and Children's Health Research Institute, Edmonton, AB, Canada

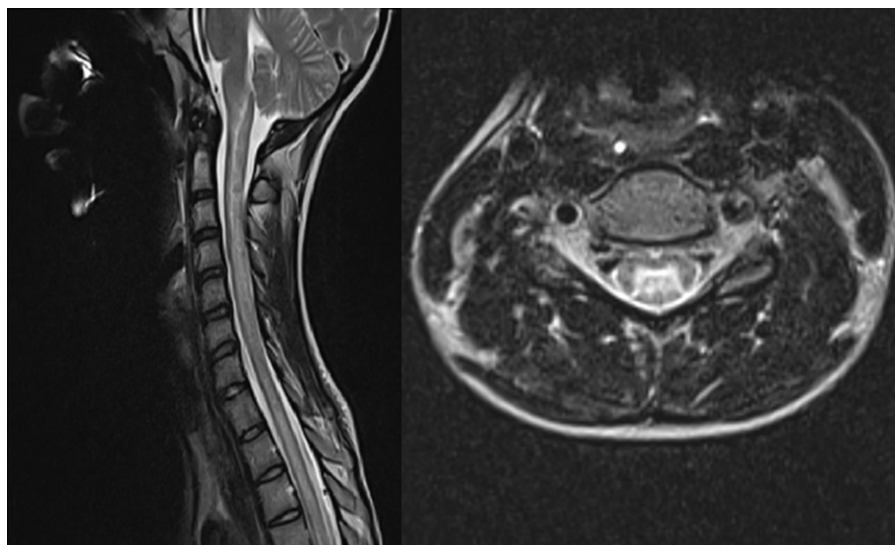
Neuromyelitis optica spectrum disorder (NMOSD) is a rare autoimmune disease of the central nervous system characterized primarily by recurrent optic neuritis and myelitis, having a strong association with aquaporin-4 (AQP4) antibody.<sup>1</sup> NMOSD is uncommon in the general population, with an estimated incidence ranging from 0.05 to 0.4 per 100,000 per year and prevalence of 0.52 to 4.4/100,000, and is even more rare in the pediatric population.<sup>2</sup> AQP4 antibody seropositivity has been reported in approximately 40% of pediatric NMOSD.<sup>3</sup>

A potential complication of NMOSD is paroxysmal (painful) tonic spasms (PTS), which have been associated with myelitis in adult NMOSD populations.<sup>4–6</sup> These are characterized by painful, stereotyped and recurrent spasms of one or more limbs and/or trunk. We present a case of PTS in pediatric NMOSD, highlighting the importance of recognizing this rare condition in children.

A 14-year-old female, with no health problems aside from short stature was admitted to a pediatric tertiary care center with a three-day history of intractable non-bloody, non-bilious emesis and excessive hiccups. She also reported numbness to her upper neck and bilateral shoulders and arms in a cape-like distribution. She

had an upper-respiratory tract illness three weeks before her presentation, which had since resolved. Her neurologic examination showed left greater than right upper extremity weakness, with normal lower extremity strength. Deep-tendon reflexes were brisk 2+ in the upper extremities and 3+ in the lower extremities, with upgoing plantar reflexes bilaterally. She had diminished pain and temperature sensation in her right arm and shoulder and decreased temperature sensation in her left shoulder. Vibration sense was severely decreased in the fingers and up to the knees bilaterally.

Magnetic resonance imaging (MRI) of the spinal cord showed diffuse intramedullary T2 hyperintensity and cord expansion extending from the distal medulla/cervicomedullary junction to the level of T8-T9 (Figure 1). The lesion demonstrated patchy partial enhancement involving the central aspect of the cord. MRI brain showed small right frontal and right parietal T2 hyperintense lesions of uncertain significance. Lumbar puncture revealed 42 leukocytes with lymphocytic predominance, protein 0.82 g/L, negative bacterial cultures and viral studies and no oligoclonal bands. Her clinical presentation and investigations were consistent with area postrema syndrome and longitudinally



**Figure 1.** Sagittal and axial T2-weighted imaging of the cervical spine reveals a longitudinally extensive lesion consistent with transverse myelitis, which extended from the distal medulla to the T8–T9 level (T4–T9 not shown).

**Corresponding author:** Colin Wilbur; Email: [wilbur@ualberta.ca](mailto:wilbur@ualberta.ca)

**Cite this article:** Mostofi E and Wilbur C. A Case of Paroxysmal Tonic Spasms in Pediatric Neuromyelitis Optica Spectrum Disorder. *The Canadian Journal of Neurological Sciences*, <https://doi.org/10.1017/cjn.2024.280>

© The Author(s), 2024. Published by Cambridge University Press on behalf of Canadian Neurological Sciences Federation. This is an Open Access article, distributed under the terms of the Creative Commons Attribution licence (<https://creativecommons.org/licenses/by/4.0/>), which permits unrestricted re-use, distribution and reproduction, provided the original article is properly cited.

extensive transverse myelitis, fulfilling criteria for a diagnosis of NMOSD. Serum was subsequently positive for anti-AQP-4 IgG. Investigations for other etiologies (including anti-myelin oligodendrocyte glycoprotein antibody, Lyme disease, syphilis, West Nile serology, anti-nuclear antibody, Vitamin B12, Vitamin E, copper) were negative. Treatment was initiated with pulse intravenous methylprednisolone for five days, followed by a prednisone taper over 12 weeks, and subsequently rituximab.

Four weeks after initiation of steroid treatment the patient presented to hospital with multiple daily episodes of painful paresthesia in the legs and associated involuntary flexion contractions of her left arm and hand lasting 30 seconds to one minute followed by complete resolution. The episodes were triggered by rapid movement and relieved with rest. There was no associated alteration of consciousness. Gabapentin was initiated and titrated up over the following three weeks to a dose of 600 mg three times daily. Despite this, her symptoms progressed to innumerable flexion spasms per day, primarily involving the upper extremities (both unilateral and bilateral) but also the lower extremities and trunk that were triggered by movement and emotional stress. The spasms disrupted her sleep and prevented her from attending school and her regular activities. The patient agreed to transition to carbamazepine, which was associated with rapid, complete and sustained resolution of her spasms at a total daily dose of 300 mg. She remained free of tonic spasms on carbamazepine monotherapy for three months, at which time carbamazepine was weaned without spasm recurrence.

Paroxysmal tonic spasms (PTS) are a common movement disorder in demyelinating diseases and are most commonly reported in NMOSD, where they are identified in approximately 20%–45% of cases.<sup>5–7</sup> The pathophysiology of PTS is not completely understood; however, a proposed mechanism is the impairment of efferent fibers at any level in the corticospinal tract leading to ephaptic activation of axons within a partially remyelinated lesion in the fiber tracts. Supporting evidence for this hypothesis includes published radiological and pathological data for patients with PTS showing demyelination within the internal capsule, midbrain and spinal cord.<sup>7</sup>

In NMOSD, PTS are almost exclusively described in the context of myelitis. This contrasts with multiple sclerosis (MS), where PTS can be seen in patients with brain lesions.<sup>8</sup> The presence of PTS in NMOSD is often associated with the first episode of myelitis, further suggesting a strong association between the two.<sup>5</sup> Like in our patient, some studies have reported the onset of PTS within weeks to months after the initial diagnosis of NMOSD, during recovery from the first myelitis episode.<sup>5</sup> In other cases, PTS can develop later, even several years after initial diagnosis.<sup>4,5</sup>

As in our pediatric case, PTS have been reported to robustly respond to sodium channel blockers, most commonly low-dose carbamazepine,<sup>4,5</sup> with a response usually seen within the first week of treatment. Other options include gabapentin or pregabalin, however studies have demonstrated increased

treatment efficacy with carbamazepine when compared to these.<sup>5,6</sup> This may reflect the importance of sodium channels in facilitating conduction, including ephaptic transmission, through demyelinated segments and a resulting sensitivity for conduction through demyelinated segments to be blocked when sodium channels are inhibited.<sup>9</sup> Likewise, our patient failed to obtain any symptom reduction despite escalating doses of gabapentin and achieved full remission of symptoms shortly after initiation of carbamazepine.

A review of the MEDLINE database for cases of PTS in pediatric NMOSD or MS reveals a paucity of data, which may reflect the rarity of this condition in children and/or a lack of recognition of the symptoms in pediatric populations. Children have rarely been included in predominantly adult case series of PTS making it unclear whether the incidence or clinical features of PTS may differ in children.<sup>4</sup>

We have presented a case of PTS in a pediatric patient with NMOSD. Clinicians caring for children with demyelinating disorders should be aware of PTS and the importance of prompt recognition and appropriate treatment in improving the quality of life of affected children.

**Author contributions.** Study conceptualization (EM, CW), data acquisition/case review (EM), drafting and critical revision of manuscript (EM, CW), study supervision (CW).

**Funding statement.** None.

**Competing interests.** EM has no conflicts of interest to declare. CW has served as a site investigator for studies sponsored by Alexion Pharmaceuticals and Hoffmann-La Roche.

## References

1. Wingerchuk DM, Banwell B, Bennett JL, et al. International consensus diagnostic criteria for neuromyelitis optica spectrum disorders. *Neurology*. 2015;85:177–89.
2. Tenenbaum S, Yeh EA. Pediatric NMOSD: a review and position statement on approach to work-up and diagnosis. *Front Pediatr*. 2020;8:339.
3. Duignan S, Wright S, Rossor T, et al. Myelin oligodendrocyte glycoprotein and aquaporin-4 antibodies are highly specific in children with acquired demyelinating syndromes. *Dev Med Child Neurol*. 2018;60:958–62.
4. Usmani N. Association between paroxysmal tonic spasms and neuromyelitis optica. *Arch Neurol*. 2012;69:121–4.
5. Kim SM, Go MJ, Sung JJ, et al. Painful tonic spasm in neuromyelitis optica. *Arch Neurol*. 2012;69:1026–31.
6. Liu J, Zhang Q, Lian Z, et al. Painful tonic spasm in neuromyelitis optica spectrum disorders: prevalence, clinical implications and treatment options. *Mult Scler Relat Disord*. 2017;17:99–102.
7. Tranchant C, Bhatia KP, Marsden CD. Movement disorders in multiple sclerosis. *Mov Disord*. 1995;10:418–23.
8. Waubant E, Alize P, Tourbah A, et al. Paroxysmal dystonia (tonic spasm) in multiple sclerosis. *Neurology*. 2001;57:2320–1.
9. Sakurai M, Kanazawa I. Positive symptoms in multiple sclerosis: their treatment with sodium channel blockers, lidocaine, and mexiletine. *Neurol Sci*. 1999;162:162–8.