

## Research Paper

**Cite this article:** Elhenawy AA, Elmehankar MS, Nabih N, Elzoheiry MA, Hany H, El-Gamal R, Aboukamar WA (2023). Biochanin A in murine *Schistosoma mansoni* infection: effects on inflammation, oxidative stress and fibrosis. *Journal of Helminthology* 97, e16, 1–14. <https://doi.org/10.1017/S0022149X22000839>

Received: 30 July 2022

Revised: 2 December 2022

Accepted: 5 December 2022

**Keywords:**



*Schistosoma*; biochanin A; transforming growth factor; cyclooxygenase; inducible nitric oxide synthase; cytochrome P450

**Author for correspondence:**

A. A. Elhenawy,

E-mail: [abirelhenawy@mans.edu.eg](mailto:abirelhenawy@mans.edu.eg)

# Biochanin A in murine *Schistosoma mansoni* infection: effects on inflammation, oxidative stress and fibrosis

A.A. Elhenawy<sup>1</sup> , M.S. Elmehankar<sup>1</sup>, N. Nabih<sup>1</sup>, M.A. Elzoheiry<sup>1</sup>, H. Hany<sup>2</sup>, R. El-Gamal<sup>3</sup> and W.A. Aboukamar<sup>1</sup> 

<sup>1</sup>Department of Medical Parasitology, Faculty of Medicine, Mansoura University, 2 El Gomhouria Street, Mansoura 35516, Egypt; <sup>2</sup>Department of Pathology, Faculty of Medicine, Mansoura University, Mansoura, Egypt and <sup>3</sup>Department of Medical Biochemistry, Faculty of Medicine, Mansoura University, Mansoura, Egypt

**Abstract**

Biochanin A (BCA) is a multifunctional natural compound that possesses anti-infective, anti-inflammatory, anti-oxidative and hepatoprotective effects. The aim of the study was to assess the therapeutic efficacy of BCA on *Schistosoma mansoni*-infected mice. Fifty mice were divided into six different groups as non-infected, non-infected BCA-treated, infected untreated, early infected BCA-treated (seven days post-infection (dpi)), late infected BCA-treated 60 dpi and infected praziquantel (PZQ)-treated groups. Parasitological, histopathological examination and immunohistochemical staining of transforming growth factor (TGF)- $\beta$ , inducible nitric oxide synthase (iNOS) and cyclooxygenase (COX-2) were investigated in liver sections. Cytochrome P450 (CYP450) gene expression of *S. mansoni* was evaluated by quantitative real-time polymerase chain reaction (RT-qPCR). A single dose of BCA significantly reduced worm burden in early (82.14%) and late infection (77.74%), mean tissue egg load in early ( $7.27 \pm 0.495$ ) and late BCA administration ( $7.63 \pm 0.435$ ) and decreased granuloma size. CYP450 mRNA expression was significantly reduced in early BCA treatment as compared to late treatment which emphasizes that early administration of BCA had more pronounced effects on worms than late administration. Both early and late BCA administration led to significant reduction in inflammatory cytokines as TGF and iNOS. Although the reduction of TGF and iNOS in BCA-treated mice was superior to PZQ, no statistically significant differences were noted. However, a significant downregulation of COX2 was noted in hepatocytes as compared to both infected control and PZQ-treated mice. BCA has schistosomicidal, anti-inflammatory, antioxidant and anti-fibrotic effects and could be regarded as a potential drug in schistosomiasis treatment.

**Introduction**

Schistosomiasis affects over 200 million people with more than 250,000 deaths per year. In 2017, 220.8 million needed schistosomiasis prophylaxes, with only 102.8 million receiving treatment (Bajracharya *et al.*, 2020). Most infections occur in rural and low-income areas of sub-Saharan Africa (Adenowo *et al.*, 2015). Depending on the region, different *Schistosoma* species can infect humans. *Schistosoma mansoni* and *Schistosoma haematobium* are endemic in Africa and the Middle East, accounting for 85% of global cases (Barakat *et al.*, 2014). Both *S. mansoni* and *S. haematobium* are found in Egypt (Adenowo *et al.*, 2015).

The World Health Organization recommends praziquantel (PZQ) as the only available drug to control and treat schistosomiasis (Tekwu *et al.*, 2016). The intensive and exclusive use of a single drug for decades may eventually lead to PZQ resistance (Cioli *et al.*, 2014). PZQ only works on adults and is ineffective on schistosomula, preadults, or juvenile adults. It is then necessary to develop effective and safe antischistosomal agents. PZQ, despite being the traditional anti-schistosomal drug therapy (Doenhoff & Pica-Mattoccia, 2006), cannot reverse hepatic fibrosis. There is a crucial need for a potent anti-fibrotic agent to prevent the progression of fibrosis especially in chronic liver diseases where reversible fibrosis is turned into irreversible cirrhosis with severe scarring of the hepatic tissues (Al-Olayan *et al.*, 2014). In recent years, the scientific community has focused on the possibility of producing a drug for schistosomiasis that is based on natural sources (Abou El-Nour & Fadladdin, 2021).

Biochanin A (BCA) is an isoflavone found in red clover, cabbage and alfalfa (Cassady *et al.*, 1988). BCA has anti-inflammatory, anti-oxidant, anti-infective, hepatoprotective and anticancer properties (Sarfraz *et al.*, 2020). Recent studies showed that BCA has potent anti-inflammatory effects in arthritis, neurological and metabolic disease models (Felix *et al.*, 2022). Kole *et al.* (2011) showed that BCA inhibited lipopolysaccharide

(LPS)-induced nitric oxide (NO) production in macrophages and inhibited inducible nitric oxide synthases (iNOS) expression through inhibition of nuclear factor- $\kappa$ B (NF- $\kappa$ B). Breikaa *et al.* (2013) found that pretreatment with BCA protected against chemokine (C-C motif) ligands 4 (CCL4)'s chronic damage, oxidative stress, inflammation and fibrosis. BCA regulates multiple biological functions by binding to DNA and proteins or acting as a substrate for enzymes (Křížová *et al.*, 2019). This immunomodulatory molecule can modulate several biological networks, so it may serve as a promising natural novel drug lead (Sarfraz *et al.*, 2020).

Schistosomiasis is the most common parasitic fibrotic disease due to inflammation and the deposition of scar tissue around trapped ova in the liver (Gryseels *et al.*, 2006). Some *Schistosoma* eggs are excreted through the stool, but others are trapped in the liver. The trapped eggs in the liver can cause inflammation. Chronic inflammation causes granulomas and eventually liver fibrosis (Colley *et al.*, 2014), characterized by an abnormal accumulation of activated hepatic stellate cells (HSCs), which produce much extracellular matrix (ECM), leading to myofibroblast development and liver fibrosis (Friedman, 2008; Zhang *et al.*, 2016).

In fibrotic disease, increased deposition of ECM components affects the tissue architecture, and interferes with normal function (Macneal & Schwartz, 2012). Fibrogenic proteins such as platelet-derived growth factor (PDGF) and transforming growth factor (TGF) promote liver fibrosis (Meng *et al.*, 2016; Ying *et al.*, 2017). TGF- $\beta$  is a widely expressed fibrogenic cytokine (Al-Olayan *et al.*, 2016) that plays an active role in proliferation, synthesis of ECM molecules and proliferation of HSCs (Du, 1999; Al-Olayan *et al.*, 2016). TGF- $\beta$ , therefore, strongly contributes to fibrotic disorders.

Nitric oxide plays a key role in both physiological inflammatory response and exaggerated pathological processes. During inflammation, there is an increased production of pro-inflammatory cytokines, including iNOSs. Increased mucosal nitric oxide synthase-2 expression and the production of NO have been reported in active inflammatory conditions as an experimental model of intestinal inflammation (Miller *et al.*, 1995; Matsumoto *et al.*, 1998).

Cyclooxygenase (COX) is the main enzyme that promotes the synthesis of prostaglandins. Two isoenzymes have been recognized: COX-1, which is expressed in many tissues to produce prostaglandins in physiological functions; and COX-2 that is induced by a variety of stimuli, and it is responsible for the production of prostaglandins under stressful conditions such as inflammation (Crofford, 1997). The downregulation of COX-2 expression has been linked to failure to synthesize prostaglandin E2, which is a potent inhibitor of fibroblast proliferation which could lead to an altered tissue repair (Keerthisingam *et al.*, 2001; Xaubet *et al.*, 2004).

There is scarce data on the direct effect of BCA on *Schistosoma* species. Most studies investigated genistein, a BCA metabolic product. Genistein affected *Schistosoma* tegument, NO, Ca<sup>2+</sup> homeostasis, carbohydrate metabolism and fibrosis in studies on *S. mansoni* and *Schistosoma japonicum* experimental infections (Faixová *et al.*, 2021). In this study, we investigated all possible effects of BCA on *S. mansoni*-induced changes in an experimental mouse model of infection, including its anti-inflammatory, anti-oxidative and anti-fibrotic properties, besides exploring its action on *S. mansoni* itself as an anti-parasitic through its effect on cytochrome P450 (CYP450) enzyme expression level.

## Materials and methods

### Animals and infection

The CD-1 Swiss female albino mice (their weight was 18–20 g), were purchased from the Medical Experimental Research Center (MERC), Mansoura University, Egypt. The mice were maintained at 20–22°C in an air-conditioned laboratory and provided with standard pelleted diet and water *ad libitum*. Each mouse (of infected groups) was infected with *S. mansoni* (Egyptian strain) cercariae by subcutaneous injection of 60  $\pm$  10 cercariae/100  $\mu$ l in dechlorinated water (Liang *et al.*, 1987).

### Drugs, animal grouping and dosing

Praziquantel® (PZQ), was purchased from Sedico Pharmaceutical Co. (6th of October City, Egypt). BCA was purchased from Sigma-Aldrich Chemical Co., (St. Louis, MO, USA). Dimethyl sulphoxide was purchased from Sigma-Aldrich (St. Louis, MO, USA) as a vehicle for dissolving BCA and PZQ. Mice were divided into six groups. Group I ( $n = 5$ ) was normal (uninfected) control mice. Group II ( $n = 5$ ) included normal uninfected mice treated with BCA (50 mg/kg/day) given orally as a single dose by intragastric gavage, seven days post-infection (dpi). Group III ( $n = 10$ ) included infected untreated mice (vehicle treated). Group IV ( $n = 10$ ) was infected PZQ-treated, orally administered 60 dpi, in a total dose of 500 mg/kg/day for two days (Gönnert & Andrews, 1977). Group V ( $n = 10$ ) was early infected BCA-treated after 7 dpi in a single dose of 50 mg/kg body weight/day (Moon *et al.*, 2006; Breikaa *et al.*, 2013). Group VI ( $n = 10$ ) was late infected BCA-treated mice 60 dpi which is the same regimen as Group V. Early intervention (one week dpi) was targeting the immature schistosomula stages and late intervention (60 dpi) was targeting mature adult worms (de Oliveira *et al.*, 2014). Mortality rate was 10–15% throughout the study. Mice of all groups were euthanized 12 weeks post-infection by a thiopental intraperitoneal injection, 100 mg/kg (Jones-Bolin, 2012).

### Parasitological assessment

Immediately after euthanizing, adult *S. mansoni* were collected by perfusions of porto-mesenteric veins of infected mice. Half of the liver specimen was processed for dissolution in 0.5% potassium hydroxide and trapped eggs were counted as per tissue gram according to Cheever (1968). Collected worms were subjected to quantitative real-time PCR (RT-qPCR), to examine the gene expression level of CYP450 in *S. mansoni*.

### Histopathological examination and morphometric assessment of fibrosis in the granuloma

Liver specimens were processed in buffered formalin (10%) and then paraffin. Liver sections were stained by Masson's trichrome (4  $\mu$ m thickness) and examined under light microscopy for granuloma size measurement. Two diameters at 90 angles to each other were measured to calculate the mean diameter of each granuloma (von Lichtenberg, 1962). Liver tissues' pathological changes were assessed for hydropic degeneration, portal tract affection and inflammatory cellular infiltrates (Knodell *et al.*, 1981; Suzuki *et al.*, 1993). The evolutionary stages of granulomas were classified according to Amaral *et al.* (2017). The studied pathological parameters were lobular inflammation, focal

necrosis, portal tract inflammation, microvesicular steatosis, collagen around granuloma and inflammatory cellular infiltrate.

In addition, stained liver sections were examined for collagen fibre deposition. Slides were photographed using an Olympus® digital camera installed on Olympus® microscope with 0.5 X photo adaptor and saved as TIFF. Then images were analysed using Video-Test Morphology® software (Russia) on Intel® Core I7® based computer with a specific built-in routine for area measurement and stain quantification. Two slides from each mouse were prepared and five random fields from each slide were analysed. The granuloma fibrosis degree was expressed as mean  $\pm$  standard error of the mean (SEM) (the percentage of the stained area compared to the total area; James *et al.* (1990)).

### Immunohistochemical staining of TGF- $\beta$ , iNOS and COX2

Immunohistochemistry (IHC) was performed to examine TGF- $\beta$ , iNOS and prostaglandin-endoperoxide synthase, known as COX2 expressions in the liver tissue hepatocytes and inflammatory cells. Liver tissues from each group were fixed in neutral buffered formalin (10%) and embedded in paraffin. For TGF- $\beta$ , the procedure was done using a specific primary anti-TGF- $\beta$  1 antibody (FNab08638, at dilution of 1:200), Fine Test® enzyme-linked immunosorbent assay test (Wuhan Fine Biotech Co., Ltd, Wuhan, Hubei, China) and appropriate secondary antibody according to Shaker *et al.* (2021). For iNOS, the procedure was done using a specific primary antibody NOS2 Rabbit pAb (A14031) at dilution of 1:100 (ABclonal, Inc., MA, USA) according to Choi *et al.* (2012), and HRP Goat Anti-Rabbit IgG (H + L) (AS014) at 1:10,000 dilution (ABclonal, Inc., MA, USA) as secondary antibody. For COX2, the procedure was done using a specific primary antibody Cox2 Rabbit pAb (A1253) at dilution of 1:200 (ABclonal, Inc., MA, USA) and appropriate secondary antibody according to Zhang *et al.* (2020). All antigens' expressions were detected in granuloma-adjacent hepatocytes' cytoplasm and inflammatory cells at the areas of the inflammation and fibrosis (according to manufacturer's instructions). Cells positivity staining was graded (Elshal *et al.*, 2015): grade 0 for 0–10% staining; grade 1 for 11–25% staining; grade 2 for 26–50% staining; and grade 3 for >50% staining. Intensity of the staining was graded as 1 for light yellow, 2 for dark yellow, and 3 for brown staining. Then the sum of both grades was scored, and results were expressed as means  $\pm$  SEM.

### Assessment of CYP450 gene expression by RT-qPCR

Adult *S. mansoni* were collected, and six worms from each infected group were homogenized by three strokes of liquid nitrogen. Total cellular RNA was extracted with QIAzol reagent (Qiagen, Germany), according to the manufacturer's instructions. RNA concentration was measured by NanoDrop 2000 (Thermo Scientific, CA, USA). Reverse transcription of 1  $\mu$ g of RNA was done with SensiFAST™ cDNA Synthesis Kit (Bioline, UK). The qRT-PCR was carried out with HERA SYBR green PCR Master Mix (Willowfort, UK) in a total volume of 20  $\mu$ l using a qRT-PCR device (Pikoreal 96): 95°C (2 min), 40 cycles of 95°C (10 s), 60°C (30 s). The primer pairs sequences were: CYP450 forward, 5' TGGGAATCGTTCGAAAGTTGG 3', reverse, 5' TTCCAGTGCCTTTTGTGTGT 3' (RefSeq; XM\_018794880.1) and the product length was 100 base pairs (bp), alpha tubulin (as a control gene) forward, 5' GAAGGCTTACCACGAGCAGT 3', reverse, 5' GGGGACAACATCACCACGAT 3' (RefSeq;

XM\_018797513.1) and the product length was 139 bp. The primer sets for both genes were designated using Primer 3 software (v.4.1.0) [<http://primer3.ut.ee>], and primer specificity was assessed using Primer-BLAST program (NCBI/ primer-BLAST [<https://www.ncbi.nlm.nih.gov/tools/primer-blast/>]). Primers' sets were synthesized and purchased from Vivantis (Vivantis Technologies, Malaysia). Reactions were done in triplicate. Relative gene expression levels were represented as  $\Delta$ Ct = Ct target gene– Ct housekeeping gene;  $2^{-\Delta\Delta$ Ct method was used to calculate the fold change in gene expression (Livak & Schmittgen, 2001). PCR products were run on 3% agarose gels and visualized on an ultraviolet transilluminator (OWI Scientific, France). Then, the gels were photographed using the Bio-Rad gel documentation system (Bio-Rad, USA).

### Statistical analysis

Data were analysed using IBM-SPSS Software Version 20 (IBM Corp., Armonk, NY, USA) and Microsoft Excel Version 2013. Quantitative values were expressed as mean  $\pm$  standard deviation. Values were expressed as mean  $\pm$  standard error. Statistics: one-way analysis of variance followed by *post-hoc* multiple comparisons; Games–Howell adjustment. Data were considered statistically significant at *P* value < 0.05.

### Results

In the current study, we investigated the effects of BCA as an anti-infective (antiparasitic), anti-inflammatory, anti-oxidative and anti-fibrotic agent.

### Parasitological parameters

Early (7 dpi) and late (60 dpi) administration of BCA in a dosage of 50 mg/Kg for two days to *S. mansoni*-infected mice significantly reduced (*P* < 0.001) the number of the total worm burden compared to the infected untreated group with a reduction rate of 82.14% and 77.74%, respectively (table 1). However, BCA did not achieve complete eradication of the worms as was the case with PZQ administration. All drug regimens: PZQ, early and late BCA significantly decreased hepatic tissue egg count compared to infected untreated group (*P* < 0.001) with reduction rates of 51.4%, 48.7 and 46.1%, respectively. Early vs. late administration of BCA drug, showed a non-significant different impact on parasitological parameters.

### Histopathological findings

All drug regimens: PZQ, early and late BCA resulted in significantly higher percentage (*P* < 0.001) of degenerated ova within the liver granulomas compared to the infected untreated group. Regarding the diameter of the hepatic granuloma among the infected groups, both early and late BCA treatment displayed significantly reduced diameter compared to the infected untreated group (*P* < 0.001) with reduction rates of 18.3% while PZQ treatment displayed hepatic granuloma diameter comparable to the infected untreated group with no statistical difference (table 2, fig. 1).

Liver tissues in all treated groups showed variable minimal to moderate degrees of focal necrosis and hydropic changes. In the PZQ-treated group, 80% of examined specimens were of minimal degree of focal necrosis and hydropic changes. In the BCA-treated group specimens, 60% of specimens were mild while 40% of

**Table 1.** Parasitological effects of different treatment regimens on *Schistosoma mansoni*-infected mice ( $n = 10/\text{group}$ ).

Parasitological parameter	Infected untreated	PZQ-treated	Early BCA-treated	Late BCA-treated
total worm burden	28.3 ± 0.60	0.00 ± 0.00 <sup>a,c,d</sup>	5.30 ± 1.23 <sup>a</sup>	6.30 ± 1.30 <sup>a</sup>
female worm count	14.30 ± 0.42	0.00 ± 0.00 <sup>a,c,d</sup>	2.90 ± 0.66 <sup>a</sup>	3.40 ± 0.67 <sup>a</sup>
egg burden/g liver ( $\times 10^3$ )	14.17 ± 0.886	6.88 ± 0.628 <sup>a</sup>	7.27 ± 0.495 <sup>a</sup>	7.63 ± 0.435 <sup>a</sup>

BCA, biochanin A; PZQ, praziquantel.

Data are presented as mean ± standard error.

<sup>a</sup>Significant difference vs. infected-control group at  $P < 0.001$ .

<sup>b</sup>Significant difference vs. infected-control group at  $P < 0.05$ .

<sup>c</sup>Significant difference vs. early BCA-treated group at  $P < 0.05$ .

<sup>d</sup>Significant difference vs. late biochanin BCA-treated group at  $P < 0.05$ .

$P$  value by one-way analysis of variance Games-Howell adjustment, *post-hoc* test.

**Table 2.** Histopathological parameters of different treatment regimens on *Schistosoma mansoni*-infected mice ( $n = 10/\text{group}$ ).

Histopathological parameter	Infected untreated	PZQ-treated	Early BCA -treated	Late BCA-treated
granuloma size ( $\mu\text{m}$ )	465.50 ± 12.64	423.00 ± 16.06	380.00 ± 13.48 <sup>a</sup>	385.50 ± 14.71 <sup>a</sup>
intact ova (%)	96.80 ± 0.84	47.1 ± 4.85 <sup>a</sup>	43.60 ± 6.86 <sup>a</sup>	49.70 ± 6.53 <sup>a</sup>
degenerated ova (%)	3.20 ± 0.84	52.9 ± 4.85 <sup>a</sup>	56.40 ± 6.86 <sup>a</sup>	50.30 ± 6.53 <sup>a</sup>
granuloma type	cellular	fibrocellular	fibrocellular	fibrocellular
fibrosis in granuloma (%)	13.73 ± 0.57	18.66 ± 2.15	11.56 ± 2.04	12.82 ± 1.80

BCA, biochanin A; PZQ, praziquantel.

Data are presented as mean ± standard error.

<sup>a</sup>Significant difference vs. infected-control group at  $P < 0.001$ .

$P$  value by one-way analysis of variance Games-Howell adjustment, *post-hoc* test.

specimens were considered moderate focal necrosis and hydropic changes. In the infected untreated group, focal necrosis was of moderate degree in most examined specimens. Regarding the inflammatory cellular infiltrates, in the infected untreated group, 60% of the examined specimens displayed a moderate degree of inflammatory infiltrate and 40% displayed marked inflammatory cellular infiltrate. In the PZQ-treated group, most of the examined liver tissue sections ranged from mild to moderate degree of inflammatory cellular infiltrates. In both the early and late BCA treated groups, most of the examined specimens (about 80% of the liver sections) showed mild inflammatory cellular infiltrates with a few numbers of moderate cellular inflammatory infiltrates.

Portal tract inflammation ranged from moderate to marked in both infected untreated and PZQ-treated group; meanwhile, the portal inflammatory infiltrate was generally a moderate degree in both infected-BCA treatment groups.

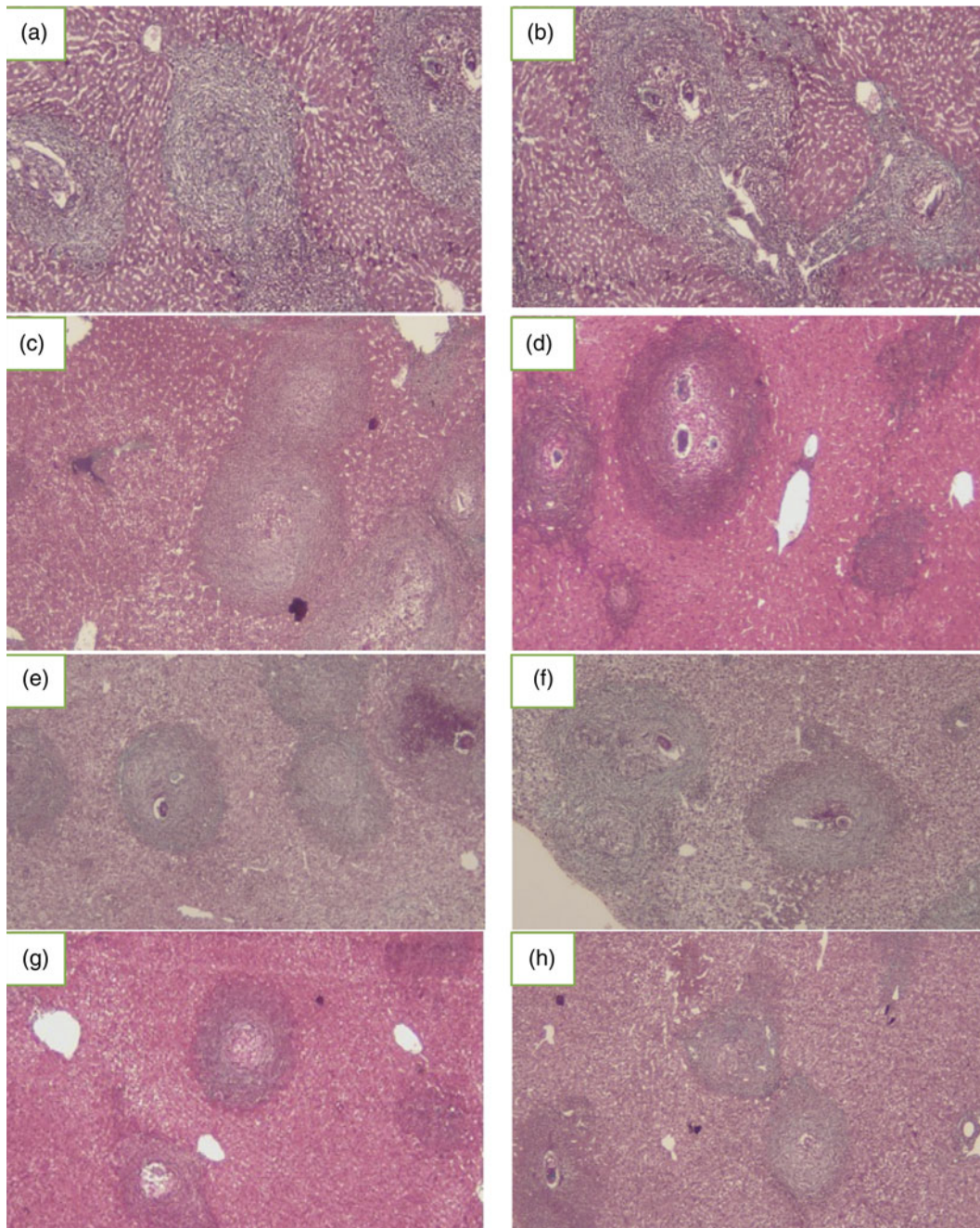
The granulomatous reaction was mainly cellular in the infected untreated group while in all treatment groups, granulomas were mainly fibrocellular. According to the classification of Amaral *et al.* (2017), in the infected untreated group, most of granulomas (80%) were pre-granulomatous exudative, and the exudative-productive type was the main granuloma stage in all treatment groups (fig. 1). Quantification of fibrosis percentage within the granulomas was performed on Masson's trichrome-stained liver sections (fig. 2), whereas the mean percentage of fibrosis was higher in the PZQ-treated group (18.66 ± 2.15) and decreased in the BCA-treated groups (11.56 ± 2.04 and 12.82 ± 1.80) compared to the infected untreated group (13.73 ± 0.57); however, with no statistical difference.

To analyse the changes of TGF- $\beta$ , iNOS and COX-2 upon BCA treatment, we analysed the baseline expression of each cytokine in normal liver tissue without BCA treatment and in a

normal liver tissue treated with BCA, and compared the staining intensity score within the different treated and control positive groups. The results demonstrated that TGF- $\beta$  and iNOS expression increased significantly after PZQ treatment in both hepatocytes and inflammatory cells; TGF- $\beta$  expression was 50% in both hepatocytes and inflammatory cells (fig. 3). However, with BCA treatment the score was significantly reduced to 25% and 20% and 20% and 10% in early and late BCA treatment, respectively (fig. 3). PRQ treated liver tissue showed strong positive iNOS expression in hepatocytes (brown staining intensity in 30% of hepatocytes) while BCA late treatment showed mild increase in expression level (25%) (fig. 4). Interestingly, increased COX2 expression was evident in the early BCA treated group: 50% in contrast with late BCA group 10%. However, the late treated group had a lower expression level compared to PZQ treated group: 10% vs. 30% (fig. 5). TGF- $\beta$  and iNOS expressions in the BCA-treated animals were significantly reduced compared with the PZQ group. At the same time, COX2 expression did not differ significantly between the two treatment arms.

### Immunohistochemical expression of TGF- $\beta$ , iNOS and COX2 receptors on liver tissues

For further evaluation of the BCA effect on the liver fibrosis, IHC of TGF- $\beta$  in liver sections was done. TGF- $\beta$  showed cytoplasmic expression in hepatocytes comparable to the infected untreated group sections, while TGF- $\beta$  expression in inflammatory cells was decreased in the treatment groups (table 3, fig. 3) compared to the infected untreated group at ( $P < 0.05$  in both the early and late BCA-treated groups and at  $P < 0.001$  in the PZQ-treated group). The control uninfected group showed minimal TGF- $\beta$



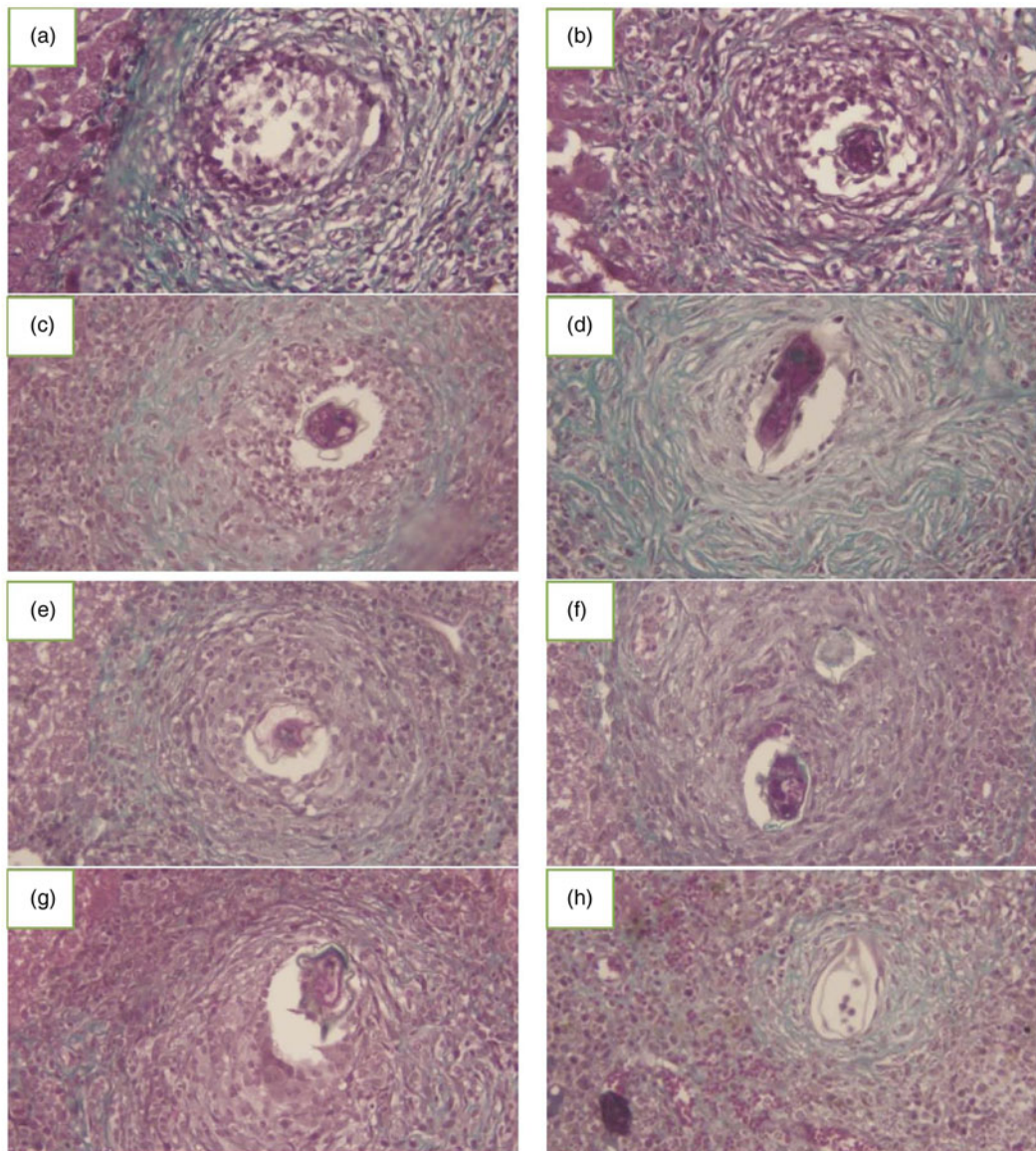
**Fig. 1.** Effect of administration of biochanin A (BCA) and praziquantel (PZQ) on the histopathological examinations of the liver sections of different mice groups of the study (Masson's trichrome  $\times 200$ ): (a, b) infected untreated control group showed multiple irregular granulomas surrounding partly or totally degenerated ova and large cellular infiltrate; (c, d) PZQ-treated infected group with lesser degree of cellular granuloma number, though approaching in its size the infected untreated group; (e, f) early BCA-treated infected group showed granulomas with less cellular infiltrate of the liver parenchyma compared to the infected control; and (g, h) late BCA-treated group with relatively less cellular and smaller granulomas.

expression in the liver tissues while all *S. mansoni*-infected groups showed a significant increase of TGF- $\beta$  expression compared to the control uninfected group ( $P < 0.05$ ). Therefore, the antifibrotic effect of BCA was significant at the inflammatory cells' expression levels (rather than the tissues) in the *S. mansoni*-infected mice model treated with either early or late BCA.

To evaluate the anti-oxidative effect of BCA on the liver cells, IHC of iNOS in liver sections was done. The iNOS cytoplasmic expression in hepatocytes was evident in comparison to the infected untreated group sections, while its expression in

inflammatory cells significantly declined in all treatment groups (table 3, fig. 4) compared to the infected untreated group ( $P < 0.001$ ). In the hepatic tissues the iNOS expression was also down-regulated in the BCA-treated groups ( $P < 0.005$ ) compared to the infected untreated group. The anti-oxidative properties of BCA were evident in this model.

The IHC of COX2 receptors in the liver sections was carried out to evaluate anti-inflammatory effects of BCA. COX2 showed significantly decreased expression in hepatocytes of both BCA-treated groups ( $P < 0.001$ ) compared to the infected



**Fig. 2.** Effect of administration of biochanin A (BCA) and praziquantel (PZQ) on the liver fibrosis of different mice groups of the study (Masson's trichrome  $\times 400$ ): (a, b) infected control group, showed large cellular granuloma surrounding degenerated ova; (c, d) PZQ-treated infected group, granuloma displayed lesser degree of cellular infiltrate and with increased fibrous tissue deposition; and (e–h) early BCA-treated infected (e, f) and late BCA-treated (g, h) showed granulomas surrounding partly degenerated ova with less fibrous tissues' deposition compared to the PZQ-treated granuloma.

untreated group and PZQ-treated group ( $P < 0.05$ ) (table 3, fig. 5). In addition, COX2 expression was downregulated in inflammatory cells in the liver, in both the early and late BCA-treated groups ( $P < 0.05$ ) compared to the infected untreated group.

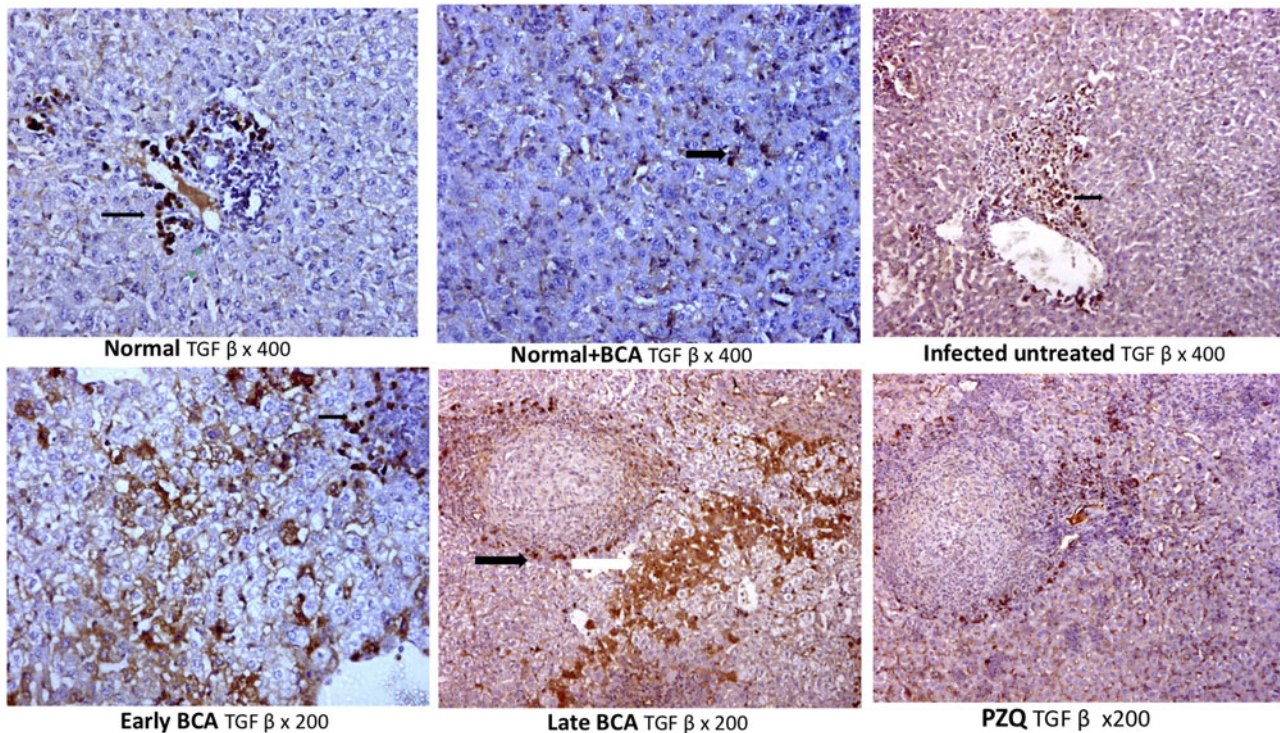
#### Effect of BCA on *S. mansoni* CYP450 mRNA expression

Collected worms were subjected to RT-qPCR to examine the gene expression level of CYP450 in *S. mansoni*. Early exposure to BCA during the first week and late exposure (60 dpi) significantly inhibited *S. mansoni* CYP450 mRNA expression in adult stage ( $P < 0.01$  and  $P < 0.05$ , respectively) compared to the mRNA expression levels in the infected untreated group adult worms (figs 6, 7). Furthermore, a significantly lower CYP450 mRNA expression was detected during early vs. late BCA treatment ( $P < 0.05$ ). Total worm burden reduction was evident in the groups

treated with BCA: 82.14% reduction in early vs. 77% reduction in late BCA administration.

#### Discussion

In *S. mansoni* infection, liver affection is a hallmark (Colley *et al.*, 2014; McManus *et al.*, 2018). Extensive granulomas could affect the liver tissues, with subsequent hepatic fibrosis, presenting as hepatosplenomegaly and portal hypertension (Andrade, 2009; Chuah *et al.*, 2014; Colley *et al.*, 2014). Granulomas which are organized collections of inflammatory cells around deposited eggs in target organs, are considered the most prominent pathological feature of schistosomiasis (Hams *et al.*, 2013; Chuah *et al.*, 2014). Although known to be protective, preventing persistent antigenic stimulation from cytokines of trapped schistosome eggs (Pagán & Ramakrishnan, 2018), granulomas themselves are



**Fig. 3.** Effect of administration of biochanin A (BCA) and praziquantel (PZQ) on the immunohistochemistry expression of transforming growth factor (TGF- $\beta$ ) in the liver of *Schistosoma mansoni*-infected mice. Normal liver showed minimal immunohistochemical expression of TGF- $\beta$  in the cytoplasm of hepatocytes (black arrow). Infected untreated mice showed strong positive expression of TGF- $\beta$  in hepatocytes with mild positive expression in the inflammatory cells (black arrow). Early BCA treatment showed mild positive expression of TGF- $\beta$  expression in hepatocyte with mild positive expression of TGF- $\beta$  in the inflammatory cells (black arrow). Late BCA showed mild positive expression of TGF- $\beta$  in hepatocytes (white arrow) with mild positive expression in the inflammatory cells (black arrow). PZQ treatment showed moderate positivity of TGF- $\beta$  in hepatocytes.

the main pathological lesions in various organs with subsequent fibrosis and scarring (Hams *et al.*, 2013).

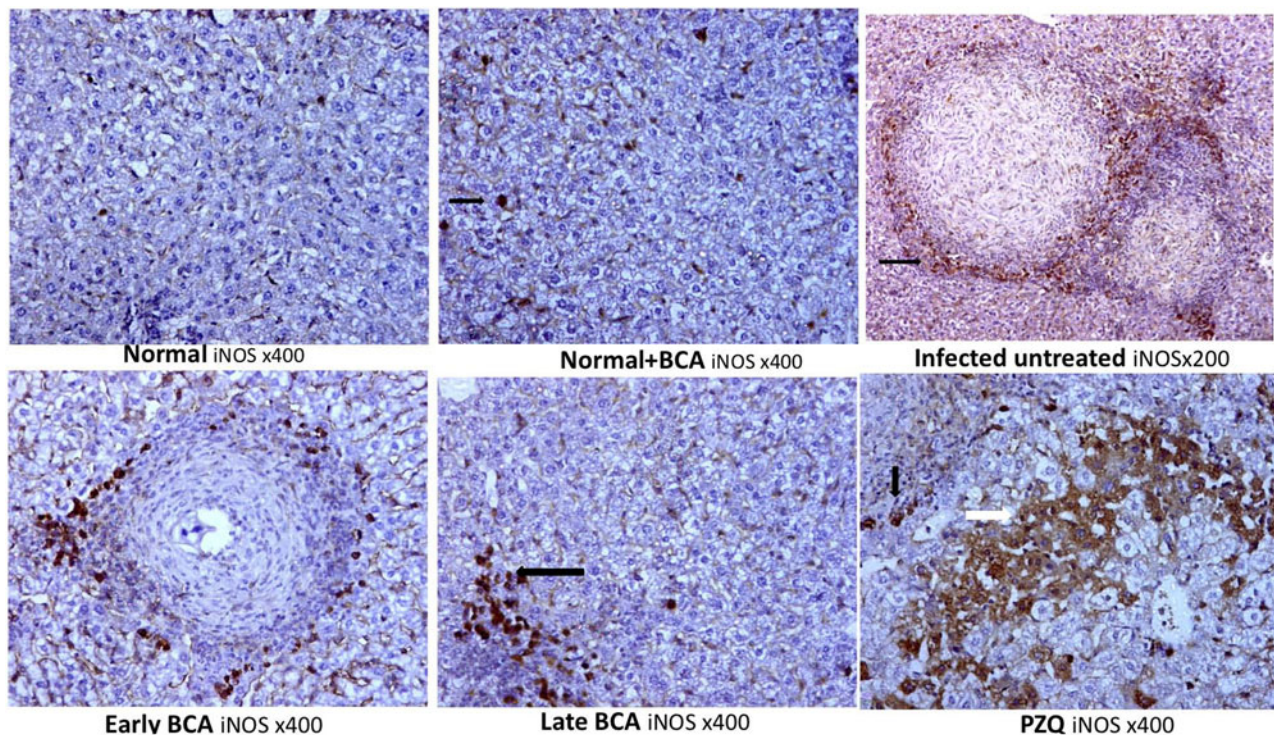
*Schistosoma* liver fibrosis is associated with HSCs' activation to myofibroblasts with accumulation of ECM proteins around the eggs. Among the most important pathways involved in hepatic fibrosis is the TGF- $\beta$  release pathway (Moreira, 2007; Fagone *et al.*, 2015) and COX-2 which is an essential factor in the progression of hepatic fibrogenesis. In response to these inflammatory changes, oxidative stress response occurs in the host leading to the release of NO and iNOS and other oxidative stress response mediators either directly or indirectly (Kole *et al.*, 2011).

Biochanin A is a bioactive isoflavone of soy, peanuts and red clover with versatile pharmacological potential. It has anti-inflammatory, anti-oxidant, neuroprotective, anti-microbial, hepatoprotective and anticancer properties (Yu *et al.*, 2019). BCA exerts its anti-tumorigenic effects by abolition of cellular growth while activating cancer cell apoptosis. BCA displays chemopreventive properties in the liver, prostate, breast and pancreatic cancers (Yu *et al.*, 2019). BCA is metabolized to genistein, BCA conjugates and genistein conjugates (Moon *et al.*, 2006). In the current study, we investigated BCA's anti-parasitic effects, anti-inflammatory (COX-2 and TGF- $\beta$ ) and antioxidant effects (iNOS) in the context of *Schistosoma* liver fibrosis. We chose BCA because it has a stronger effect both directly and after conversion to its genistein metabolite, extending its half-life and activity. Investigating its antioxidant, anti-inflammatory, in addition, to its CYP450 inhibitory activity, partially explains its mechanism of action. Hepatic granulomatous inflammation, fibrosis and cytokine production (COX-2 and TGF- $\beta$ ) were monitored.

In our study, BCA reduced *S. mansoni* egg production, possibly due to reduced worm burden. Oral BCA treatment was more effective than PZQ against immature *S. mansoni* early infection; however, in chronic infections, BCA was less effective than PZQ. Despite the modest worm and egg burden reductions, BCA was more effective than PZQ against immature parasites (early infection). It was associated with reduced morbidity because schistosome parasites do not multiply in mammals (Guerra *et al.*, 2019).

Early BCA showed smaller granulomas and more intact ova with less fibrosis than PZQ. In the *S. mansoni* infection model using red propolis that contains genistein and BCA, Silva *et al.* (2021) found that it significantly reduced *S. mansoni* egg production early in infection compared to late infection. Interfering with egg oviposition might be linked to the schistosome reproductive system changes. Because egg production is essential for schistosome transmission and pathogenesis, the impact on *S. mansoni* egg-laying is important for natural products with antischistosomal properties (Aleixo de Carvalho *et al.*, 2015; Dias *et al.*, 2017).

Another study by Mohamed *et al.* (2016) found that propolis reduced the worm and egg burden in *S. mansoni*-infected mice (chronic infection). However, in another study, Egyptian propolis had poor antischistosomal properties on adult worms (chronic infection) in the *S. mansoni*-mice model (Mahmoud *et al.*, 2014). The inconsistencies are probably due to variations in propolis and *Schistosoma* strains. Propolis is a natural resin collected by bees from various plant parts; its chemical composition varies greatly depending on the location and local flora (Rufatto *et al.*, 2017).



**Fig. 4.** Effect of administration of biochanin A (BCA) and praziquantel (PZQ) on the immunohistochemistry expression of inducible nitric oxide synthase (iNOS) in the liver of *Schistosoma mansoni*-infected mice. Normal liver showed negative iNOS expression in hepatocyte and in the inflammatory cells. Normal liver treated with BCA showed negative iNOS expression in hepatocytes with mild positive expression in the inflammatory cells (black arrow). Infected untreated mice showed mild positive iNOS expression in hepatocytes with strong positive expression in the inflammatory cells (black arrow). Early BCA treatment showed negative iNOS expression in hepatocytes with mild positive iNOS expression in the inflammatory cells. Late BCA treatment showed negative iNOS expression in hepatocytes with mild positive expression in the inflammatory cells (black arrow). PZQ treatment showed strong positive iNOS expression in hepatocytes (white arrow) with mild positive expression in the inflammatory cells (black arrow).

In accordance with previous reports about the efficiency of BCA as an anti-pathogenic agent, BCA reduced the number of bacterial colonies in the lung tissues and decreased haemolysin secretion in alveolar lavage fluid. It also diminished the degree of pulmonary oedema and protected the host from methicillin-resistant *Staphylococcus aureus* (MRSA) infection by inhibiting MRSA haemolysin expression, providing experimental evidence for its potential anti-MRSA drug development (Feng *et al.*, 2021).

Regarding parasitic infections, *in vitro* studies have shown genistein to affect several enzymatic systems, localized in the tegument and other worm compartments, indicating its multiple molecular targets (Tandon & Das, 2018). In cestodes and trematodes, genistein acts on tegument causing flaccid paralysis *in vitro*, and causes irreversible structural changes (Tandon *et al.*, 1997). *In vitro* treatment of *Echinococcus multilocularis* metacystodes by genistein on the metacystode stage of *E. multilocularis* and *Echinococcus granulosus* caused profound morphological and structural changes with loss of viability and death (Naguleswaran *et al.*, 2006). Kar *et al.* (2002) found that genistein treatment caused death of *Fasciolopsis buski*.

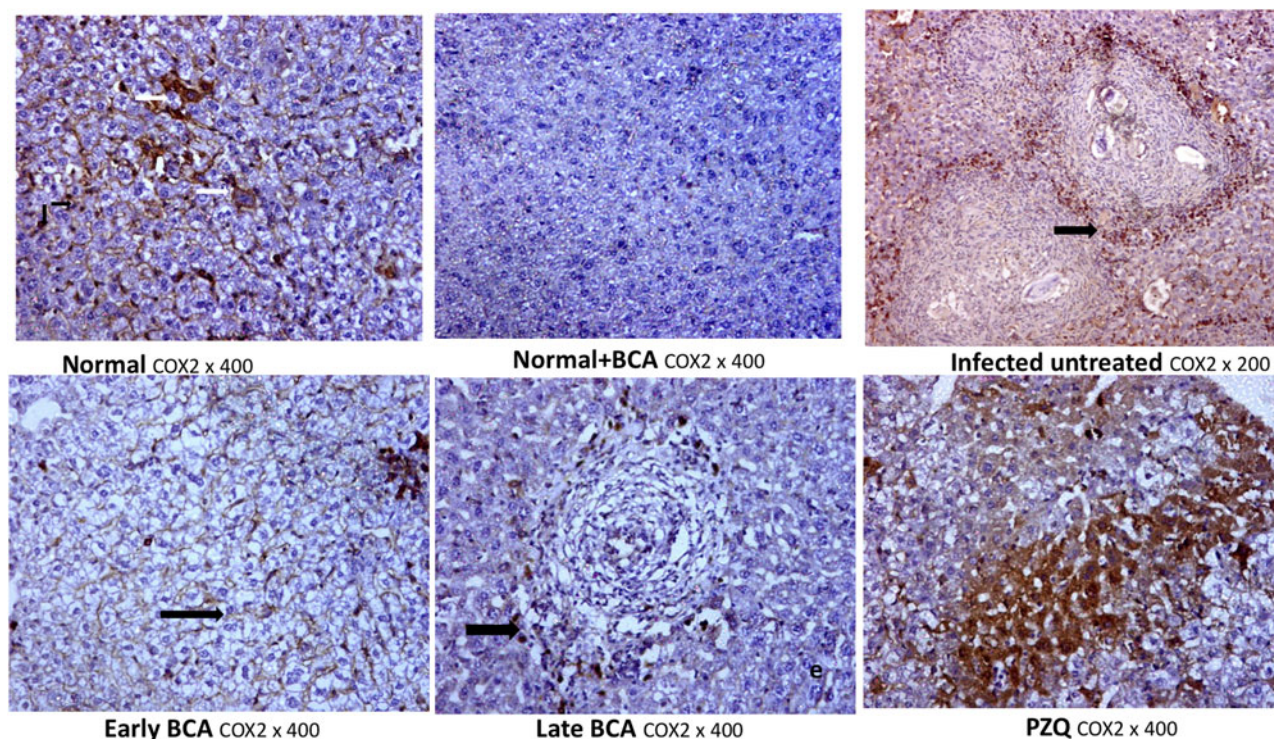
Similarly, BCA was active against *Hymenolepis diminuta*, leading to paralysis and death of the worms in a very short duration (Vijaya & Yadav, 2016). In protozoa, several isoflavones showed anti-*Cryptosporidium parvum* activity *in vitro* and *in vivo* (Stachulski *et al.*, 2006). BCA was also active against *Leishmania donovani* (Tasdemir *et al.*, 2006) and against trypanostigotes forms of *Trypanosoma cruzi* with even more efficacy than the standard drug benznidazole (Sartorelli *et al.*, 2009).

Schistosome CYP450 is essential for worm survival and egg development, and thus a druggable target. Potential schistosomiasis treatments which include drugs that target fungal CYP450 were approved for the use in humans (Goswami *et al.*, 2006). CYP450 was also a drug target in many parasitic organisms, including *T. cruzi*, schistosomes, and *Opisthorchis felineus*. Anthelmintic activity was achieved by CYP450 inhibitors at micromolar to nanomolar concentrations (Mordvinov *et al.*, 2017; Pakharukova *et al.*, 2018).

For better understanding of the activity of BCA as an anti-parasitic agent, we thought to investigate its activity as a CYP450 inhibitor. Given that schistosomes have a single druggable cytochrome gene (Berriman *et al.*, 2009), we hypothesize that BCA could be an antischistosomal drug via its CYP450 inhibitory action. Humans have 57 CYP450s genes that share 22% sequence identity (Turman *et al.*, 2006) while in schistosomal worm, CYP450 is represented with only one gene. This feature in schistosomes could be used to clear worms from mice at low doses.

In our study, early vs. late BCA treatment resulted in significantly lower CYP450 mRNA expression ( $P < 0.05$ ) compared to infected untreated adult worms. Although not examined in our study, this could help prevent and control schistosomiasis in endemic areas if used as a prophylactic agent. In agreement with our findings, Ziniel *et al.* (2015) reported that dsRNA silencing of *S. mansoni* (Sm) CYP450 causes worm death and antifungal azole CYP450 inhibitors kill larval and adult worms at low micromolar concentrations and validate SmCYP450 as a novel





**Fig. 5.** Effect of administration of biochanin A (BCA) and praziquantel (PZQ) on the immunohistochemistry expression of cyclooxygenase (COX-2) in the liver of *Schistosoma mansoni*-infected mice. Normal liver showed mild positive immunohistochemical expression of COX2 in hepatocytes (white arrow) with mild positive expression in the inflammatory cells (black arrow). Normal liver treated with BCA showed negative COX2 expression in hepatocytes and the inflammatory cells. Infected untreated mice showed mild positive COX2 expression in hepatocytes with strong positive expression in the inflammatory cells (black arrow). Early BCA treatment showed negative COX2 expression in hepatocyte with strong expression of COX2 in the inflammatory cells (black arrow). Late BCA treatment showed negative COX2 expression in hepatocytes with mild positive expression in the inflammatory cells (black arrow). PZQ treatment showed strong positive COX2 expression in hepatocytes (black arrow).

**Table 3.** Immunohistochemical expression of transforming growth factor (TGF- $\beta$ ), inducible nitric oxide synthase (iNOS) and cyclooxygenase (COX2) in the liver sections on hepatocytes and inflammatory cells ( $n = 10$  for each group).

Parameter	Infected untreated	PZQ-treated	Early BCA-treated	Late BCA-treated
TGF- $\beta$ in hepatocyte	4.10 $\pm$ 0.32	3.00 $\pm$ 0.54	4.10 $\pm$ 1.00	3.70 $\pm$ 0.95
TGF- $\beta$ in inflammatory cells	5.20 $\pm$ 0.79	2.70 $\pm$ 0.82 <sup>a</sup>	3.20 $\pm$ 1.23 <sup>b</sup>	3.30 $\pm$ 1.34 <sup>b</sup>
iNOS in hepatocyte	3.80 $\pm$ 0.92	2.90 $\pm$ 2.02	1.40 $\pm$ 1.90 <sup>b</sup>	1.50 $\pm$ 1.84 <sup>b</sup>
iNOS in inflammatory cells	5.50 $\pm$ 0.53	2.20 $\pm$ 1.55 <sup>a</sup>	2.50 $\pm$ 2.32 <sup>a</sup>	2.50 $\pm$ 2.32 <sup>a</sup>
COX2 in hepatocyte	4.20 $\pm$ 0.79	4.80 $\pm$ 0.63 <sup>b</sup>	1.40 $\pm$ 1.43 <sup>a,c</sup>	1.50 $\pm$ 1.45 <sup>a,c</sup>
COX2 in inflammatory cells	5.10 $\pm$ 0.88	4.30 $\pm$ 0.82	3.20 $\pm$ 1.81 <sup>b</sup>	2.90 $\pm$ 1.67 <sup>b</sup>

BCA, biochanin A; PZQ, praziquantel.

Immunohistochemistry parameters were presented as an expression score. Data are presented as mean  $\pm$  standard error. Statistics: one-way analysis of variance followed by *post-hoc* multiple comparisons; Games-Howell adjustment.

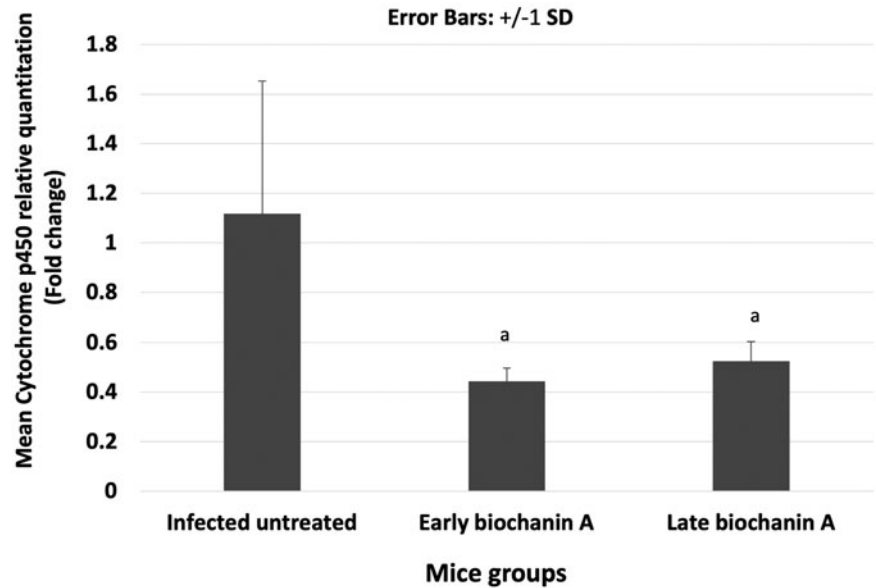
<sup>a</sup> $P < 0.001$  vs. infected control group.

<sup>b</sup> $P < 0.05$  vs. infected control group.

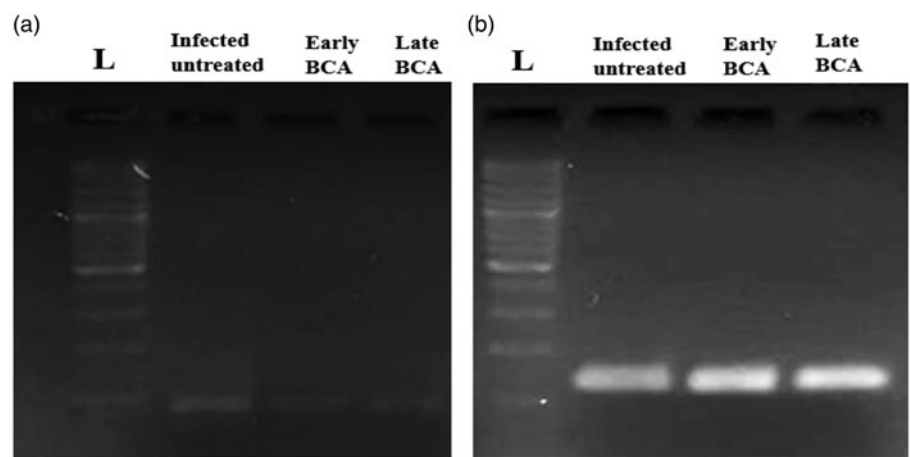
<sup>c</sup> $P < 0.001$  vs. infected PZQ-treated group.

drug target for worm survival and egg development. Similarly, slight inhibition of CY450 in the host, allows combined treatment with other effective anti-parasitic drugs to have an additive effect on elimination of schistosomes. Moreover, as an indirect effect, reduced metabolic activation of drugs by the monooxygenase (P450) system depressed the initial formation of reactive oxygen species and some intermediate toxic products, resulting in reduced lipid peroxidation and oxidative stress injury (Breikaa *et al.*, 2013; Saleh *et al.*, 2014).

Regarding fibrosis, granulomas form because of accumulation of ECM proteins such as collagen around eggs causing fibrosis, one of the most severe chronic schistosomiasis consequences. HSCs' activation to myofibroblast differentiation is a hallmark of liver fibrosis (Moreira, 2007). Among the major transcriptional targets of HSC activation are fibronectin, collagen I, smooth muscle actin (SMA), TGF, tumor necrosis factor, matrix metalloproteinase-2, matrix metalloproteinase 9 and tissue inhibitor of metalloproteinase (Fagone *et al.*, 2015). Isoflavones including genistein were



**Fig. 6.** *Schistosoma mansoni* cytochrome P450 mRNA relative expressions as quantitative real-time polymerase chain reaction in all studied animal groups: (a)  $P < 0.001$  vs. infected untreated group; (b)  $P < 0.05$  vs. infected untreated group; and (c)  $P < 0.05$  vs. infected late biochanin A-treated group.



**Fig. 7.** Gel electrophoresis of the real-time quantitative real-time polymerase chain reaction (RT-qPCR) products. Lane 1, 50 base pairs (bp) ladder (L); Lane 2, infected untreated group; Lane 3, early biochanin (BCA)-treated group; and Lane 4, late BCA-treated group: (a) cytochrome P450 RT-qPCR product (100 bp); and (b) alpha tubulin RT-qPCR product (139 bp).

known to decrease the level of TGF- $\beta$ , which activates HSCs (Huang *et al.*, 2013). Although many signalling pathways are involved in liver fibrosis, Cong *et al.* (2012) and Lam *et al.* (2021) reported that schisandrin B was effective in ameliorating *S. mansoni* liver fibrosis through downregulation of TGF- $\beta$ . BCA acted as an anti-inflammatory agent that regulates TGF- $\beta$  signalling (Cuiqiong *et al.*, 2020).

The TGF- $\beta$  promotes ECM formation, mesenchymal cell proliferation, migration and accumulation following inflammatory reactions. As a result, TGF- $\beta$  is critical in the development of fibrosis in chronic inflammatory disorders. According to the stage of disease and site of action, TGF- $\beta$  could either exacerbate or ameliorate symptoms. TGF- $\beta$  was considered as an attractive therapeutic target for severe fibrosis (Pohlner *et al.*, 2009). Furthermore, TGF- $\beta$  could act as either a tumour suppressor or promoter dependent on disease stage (Gallier *et al.*, 2006; Jakowlew, 2006). Inhibition of TGF- $\beta$  appeared to be a promising strategy for fibrosis relief and cancer prevention. Therefore, there were many clinical trials investigating the use of TGF- $\beta$  inhibitors targeting both fibrosis and cancer (Prud'homme, 2007). In the

lungs, BCA treatment showed remarkable anti-inflammatory effects in TGF- $\beta$  mediated pulmonary fibrosis. BCA inhibited TGF- $\beta$  mediated epithelial-mesenchymal transition, myofibroblast differentiation and collagen deposition *in vitro* and *in vivo* (Andugulapati *et al.*, 2020). Isoflavones (as genistein) are known to decrease the level of TGF- $\beta$ , which activates HSCs (Huang *et al.*, 2013).

The COX-2 is an essential factor in the progression of hepatic fibrogenesis. HSCs that were activated in the liver could hasten the start and progression of liver fibrosis. COX-2 overexpression causes inflammation (Crofford, 1997), which is a key factor in the development of hepatic fibrosis. COX-2 appears to play a role in the major pathophysiology of liver fibrosis, including inflammation, apoptosis and cell senescence. COX-2 expression was changed in people and animal models with cirrhosis or non-alcoholic fatty liver disease (Yang *et al.*, 2020).

In our study, hepatic granuloma size was significantly reduced in the group that received BCA in comparison to PZQ treated and infected control groups. Given the importance of liver granuloma in pathology and subsequent fibrosis, a reduction in size and

surrounding fibrosis achieved by BCA administration is an important step towards prevention of further damage and development of premalignant lesions. In our results, TGF- $\beta$  expression in inflammatory cells was decreased in treatment groups compared to the infected untreated group ( $P < 0.05$ ) in the early and late BCA-treated groups and in the PZQ-treated group. BCA also reduced fibrosis. Treatment with BCA might have reduced fibrosis in part due to its anti-inflammatory properties. Its anti-oxidant and anti-inflammatory properties had been linked to genistein (Zhao *et al.*, 2016). In agreement with our results, Breikaa *et al.* (2013) reported that pretreatment with BCA prevented chronic CCl<sub>4</sub> induced hepatic damage, oxidative stress, inflammation, and reduced fibrosis markers. BCA's anti-oxidative effects improved remodelling of cardiac tissue after myocardial infarction in diabetic rats (Sangeethadevi *et al.*, 2022) which prevented liver fibrosis (Sobhy *et al.*, 2018) compared genistein's anti-schistosomal and antifibrotic activity to PZQ in acute and chronic *S. mansoni* infections. In both the acute and chronic stages, the percentage of collagen decreased, as did the expression of TGF- $\beta$  in the examined hepatocytes. The findings suggested that genistein, especially in combination with PZQ, might protect against *S. mansoni*-induced liver damage and fibrosis.

These results corroborate ours, as TGF- $\beta$  expression in inflammatory cells was decreased in treatment groups compared to the infected untreated group ( $P < 0.05$ ) in early and late BCA-treated groups and in comparison to the PZQ-treated group.

In schistosomiasis, the cellular antioxidant system is disrupted, and the hepatocyte membrane is damaged (El-Sokkary *et al.*, 2002). Adult parasites with a long life-span inside the mammalian bodies face redox challenges (Song *et al.*, 2016; West *et al.*, 2017). Thus, parasite survival may be dependent on the ability to maintain a balance of oxidation and antioxidation. The number of relevant genes in helminth genomes, their levels of expression, and their presence in the secretome highlight the importance of redox metabolism for parasites (Ershov *et al.*, 2019). Oxidative processes are involved in pathogenesis and referred to the suggested role of free radicals as major deleterious factors in schistosomiasis (El-Sokkary *et al.*, 2002). Compounds that can effectively inhibit the redox system are promising drugs. Recent research on antioxidants as anthelmintic agents had shown some promising results (Song *et al.*, 2016; Ruan *et al.*, 2020; Vale *et al.*, 2020). The role of BCA as an antioxidant is well known (Kole *et al.*, 2011; Sadri *et al.*, 2017; Sarfraz *et al.*, 2020). NO has a well-established role in inflammation. Inflammation increases mediators that directly or indirectly induce iNOSs (Kole *et al.*, 2011). In schistosomiasis, at the onset of *Schistosoma* egg laying, the expression of iNOS mRNA was detected in the liver then its levels increased with more eggs' deposition and accumulation, while the anti-microbial activity of iNOS against the *S. mansoni* eggs' deposition, led to undesirable deleterious effects in the liver tissue (Abdallahi *et al.*, 2001). There were increased levels of lipid peroxidation and NO in the liver, kidney and spleen of infected mice with *S. mansoni*, which declined with administration of melatonin resulting in prevention of granuloma formation in the liver, reduction of megakaryocytes' number in the spleen, and degeneration and necrosis of the kidney cortex (El-Sokkary *et al.*, 2002). BCA inhibited LPS-induced I $\kappa$ B kinase activity, NF- $\kappa$ B and consequentially iNOS expression (Kole *et al.*, 2011). Our results exhibited significant reduction of iNOS either in early or late BCA-treated groups vs. infected untreated mice, supporting the antioxidant and anti-inflammatory activity of BCA.

In our study, BCA-treated hepatocytes and inflammatory cells had lower COX-2 and iNOS expression than PZQ-treated hepatocytes and inflammatory cells. *In vitro* studies of BCA on macrophage cell lines and mouse peritoneal macrophages documented anti-cell proliferation and anti-inflammatory effects as BCA inhibited LPS-induced NO production in macrophages and iNOS expression, by inhibition of NF- $\kappa$ B binding activity (Kole *et al.*, 2011). BCA reduced inflammation and tissue injury via a cascade of reactions that inhibited mitogen-activated protein kinases' signalling pathways leading to NF- $\kappa$ B-driven inhibition of gene transcription and decreased expression of iNOS and COX-2 (Kole *et al.*, 2011; Qiu *et al.*, 2012). This matches our findings of decreased iNOS and COX-2 expression in hepatocytes and inflammatory cells.

In conclusion, BCA could be regarded as a potential drug in schistosomiasis treatment. Although the mechanism of its anti-schistosomal action needs further research to be elucidated, we can suggest that considering our results, the effect of BCA could be due to its inhibitory action on CYP450 in the adult worms. Moreover, BCA showed evident anti-inflammatory, anti-oxidant and anti-fibrotic effects on the host tissues in a schistosomiasis-mice model. Further studies should be conducted to corroborate these results.

**Financial support.** This research received no specific grant from any funding agency, commercial or not-for-profit sectors.

**Conflicts of interest.** None.

**Ethical standards.** This experimental study was approved by the Institutional Review Board Ethical Committee of Mansoura University Faculty of Medicine, code number R.19.04.493.

## References

- Abdallahi OMS, Bensalem H, Diagana M, De Reggi M and Gharib B (2001) Inhibition of nitric oxide synthase activity reduces liver injury in murine schistosomiasis. *Parasitology* 122(3), 309–315.
- Abou El-Nour MF and Fadladdin Y (2021) Antischistosomal activity of *Zingiber officinale*, *Piper nigrum*, and *Coriandrum sativum* aqueous plant extracts on hamster infected with *Schistosoma mansoni*. *Journal of Parasitology Research* 2021, 1–21.
- Adenowo AF, Oyinloye BE, Ogunyinka BI and Kappo AP (2015) Impact of human schistosomiasis in sub-Saharan Africa. *The Brazilian Journal of Infectious Diseases* 19(2), 196–205.
- Aleixo de Carvalho LS, Geraldo RB, de Moraes J, Silva Pinto PL, de Faria Pinto P, Pereira Odos S and Da Silva Filho AA (2015) Schistosomicidal activity and docking of *Schistosoma mansoni* ATPDase 1 with licoflavone B isolated from *Glycyrrhiza inflata* (Fabaceae). *Experimental Parasitology* 159(1), 207–214.
- Al-Olayan EM, El-Khadragy MF, Aref AM, Othman MS, Kassab RB and Abdel Moneim AE (2014) The potential protective effect of *Physalis peruviana* L. Against carbon tetrachloride-induced hepatotoxicity in rats is mediated by suppression of oxidative stress and downregulation of MMP-9 expression. *Oxidative Medicine and Cellular Longevity* 2014, 1–12.
- Al-Olayan EM, El-Khadragy MF, Alajmi RA, Othman MS, Bauomy AA, Ibrahim SR and Abdel Moneim AE (2016) *Ceratonia siliqua* pod extract ameliorates *Schistosoma mansoni*-induced liver fibrosis and oxidative stress. *BMC Complementary and Alternative Medicine* 16(1), 434.
- Amaral KB, Silva TP, Dias FF, Malta KK, Rosa FM, Costa-Neto SF, Gentile R and Melo RCN (2017) Histological assessment of granulomas in natural and experimental *Schistosoma mansoni* infections using whole slide imaging. *PLoS One* 12(9), e0184696.
- Andrade ZA (2009) Schistosomiasis and liver fibrosis: schistosomiasis and liver fibrosis. *Parasite Immunology* 31(11), 656–663.

- Andugulapati SB, Gourishetti K, Tirunavalli SK, Shaikh TB and Sistla R (2020) Biochanin-A ameliorates pulmonary fibrosis by suppressing the TGF- $\beta$  mediated EMT, myofibroblasts differentiation and collagen deposition in *in vitro* and *in vivo* systems. *Phytomedicine* **78**(1), 153298.
- Bajracharya D, Pandit S and Bhandari D (2020) First case report of *Schistosoma japonicum* in Nepal. *Access Microbiology* **2**(6), acmi000117.
- Barakat R, El Morshedy H and Farghaly A (2014) Human Schistosomiasis in the Middle East and North Africa region. pp. 23–57. In McDowell MA and Rafati S (Eds) *Neglected tropical diseases—Middle East and North Africa*. Vienna, Springer.
- Berriman M, Haas BJ, LoVerde PT, et al. (2009) The genome of the blood fluke *Schistosoma mansoni*. *Nature* **460**(7253), 352–358.
- Breikaa RM, Algendaby MM, El-Demerdash E and Abdel-Naim AB (2013) Multimechanistic antifibrotic effect of Biochanin A in rats: implications of proinflammatory and profibrogenic mediators. *PLoS One* **8**(7), e69276.
- Cassady JM, Zennie TM, Chae YH, Ferin MA, Portuondo NE and Baird WM (1988) Use of a mammalian cell culture benzo(a)pyrene metabolism assay for the detection of potential anticarcinogens from natural products: inhibition of metabolism by biochanin A, an isoflavone from *Trifolium pratense* L. *Cancer Research* **48**(22), 6257–6261.
- Cheever AW (1968) Conditions affecting the accuracy of potassium hydroxide digestion techniques for counting *Schistosoma mansoni* eggs in tissues. *Bulletin of the World Health Organization* **39**(2), 328–331.
- Choi J-Y, Nam S-A, Jin D-C, Kim J and Cha J-H (2012) Expression and cellular localization of inducible nitric oxide synthase in lipopolysaccharide-treated rat kidneys. *Journal of Histochemistry & Cytochemistry* **60**(4), 301–315.
- Chuah C, Jones MK, Burke ML, McManus DP and Gobert GN (2014) Cellular and chemokine-mediated regulation in schistosome-induced hepatic pathology. *Trends in Parasitology* **30**(3), 141–150.
- Cioli D, Pica-Mattoccia L, Basso A and Guidi A (2014) Schistosomiasis control: praziquantel forever? *Molecular and Biochemical Parasitology* **195**(1), 23–29.
- Colley DG, Bustinduy AL, Secor WE and King CH (2014) Human schistosomiasis. *The Lancet* **383**(9936), 2253–2264.
- Cong M, Iwasako K, Jiang C and Kisseleva T (2012) Cell signals influencing hepatic fibrosis. *International Journal of Hepatology* **2012**, 158547.
- Crofford LJ (1997) COX-1 and COX-2 tissue expression: implications and predictions. *The Journal of Rheumatology Supplement* **49**, 15–19.
- Cuiqiong W, Chao X, Xinling F and Yinyan J (2020) Schisandrin B suppresses liver fibrosis in rats by targeting miR-101-5p through the TGF- $\beta$  signaling pathway. *Artificial Cells, Nanomedicine, and Biotechnology* **48**(1), 473–478.
- de Oliveira RN, Rehder VLG, Oliveira ASS, Jeraldo VDLS, Linhares AX and Allegretti SM (2014) Anthelmintic activity *in vitro* and *in vivo* of *Baccharis trimera* (Less) DC against immature and adult worms of *Schistosoma mansoni*. *Experimental Parasitology* **139**(1), 63–72.
- Dias MM, Zuza O, Riani LR, et al. (2017) *In vitro* schistosomicidal and antiviral activities of *Arctium lappa* L. (Asteraceae) against *Schistosoma mansoni* and herpes simplex virus-1. *Biomedicine & Pharmacotherapy* **94**, 489–498.
- Doenhoff MJ and Pica-Mattoccia L (2006) Praziquantel for the treatment of schistosomiasis: its use for control in areas with endemic disease and prospects for drug resistance. *Expert Review of Anti-Infective Therapy* **4**(2), 199–210.
- Du W-D (1999) Dynamic changes of type I, III and IV collagen synthesis and distribution of collagen-producing cells in carbon tetrachloride-induced rat liver fibrosis. *World Journal of Gastroenterology* **5**(5), 397–403.
- El-Sokkary GH, Omar HM, Hassanein A-FMM, Cuzzocrea S and Reiter RJ (2002) Melatonin reduces oxidative damage and increases survival of mice infected with *Schistosoma mansoni*. *Free Radical Biology & Medicine* **32**(4), 319–332.
- Elmorshedy H, Bergquist R, Fayed A, Guirguis W, Abdel-Gawwad E, Eissa S and Barakat R (2020) Elimination of schistosomiasis requires multifactorial diagnostics: evidence from high- and low-prevalence areas in the Nile Delta, Egypt. *Infectious Diseases of Poverty* **9**(1), 31.
- Elshal M, Abu-Elsaad N, El-Karef A and Ibrahim TM (2015) The multi-kinase inhibitor pazopanib targets hepatic stellate cell activation and apoptosis alleviating progression of liver fibrosis. *Naunyn-Schmiedeberg's Archives of Pharmacology* **388**(12), 1293–1304.
- Ershov NI, Mordvinov VA, Prokhortchouk EB, et al. (2019) New insights from *Opisthorchis felineus* genome: update on genomics of the epidemiologically important liver flukes. *BMC Genomics* **20**(1), 399.
- Fagone P, Mangano K, Mammanna S, et al. (2015) Identification of novel targets for the diagnosis and treatment of liver fibrosis. *International Journal of Molecular Medicine* **36**(3), 747–752.
- Faixová D, Hřčková G, Mačák Kubašková T and Mudroňová D (2021) Antiparasitic effects of selected isoflavones on flatworms. *Helminthologia* **58**(1), 1–16.
- Felix FB, Vago JP, Beltrami VA, Araújo JMD, Grespan R, Teixeira MM and Pinho V (2022) Biochanin A as a modulator of the inflammatory response: an updated overview and therapeutic potential. *Pharmacological Research* **180**(1), 106246.
- Feng J, Sun D, Wang L, et al. (2021) Biochanin A as an  $\alpha$ -hemolysin inhibitor for combating methicillin-resistant *Staphylococcus aureus* infection. *World Journal of Microbiology & Biotechnology* **38**(1), 6.
- Friedman SL (2008) Mechanisms of hepatic fibrogenesis. *Gastroenterology* **134**(6), 1655–1669.
- Gallagher AJ, Neil JR and Schiemann WP (2006) Role of transforming growth factor-beta in cancer progression. *Future Oncology (London, England)* **2**(6), 743–763.
- Gönnert R and Andrews P (1977) Praziquantel, a new broad-spectrum anti-schistosomal agent. *Zeitschrift für Parasitenkunde (Berlin, Germany)* **52**(2), 129–150.
- Goswami D, Goswami R, Banerjee U, Dadhwal V, Miglani S, Lattif AA and Kochupillai N (2006) Pattern of *Candida* species isolated from patients with diabetes mellitus and vulvovaginal candidiasis and their response to single dose oral fluconazole therapy. *Journal of Infection* **52**(2), 111–117.
- Gryseels B, Polman K, Clerinx J and Kestens L (2006) Human schistosomiasis. *Lancet (London, England)* **368**(9541), 1106–1118.
- Guerra RA, Silva MP, Silva TC, Salvadori MC, Teixeira FS, de Oliveira RN, Rocha JA, Pinto PLS and de Moraes J (2019) *In vitro* and *in vivo* studies of spironolactone as an antischistosomal drug capable of clinical repurposing. *Antimicrobial Agents and Chemotherapy* **63**(3), e01722–18.
- Hams E, Avielle G and Fallon PG (2013) The *Schistosoma* granuloma: friend or foe? *Frontiers in Immunology* **4**(1), 89.
- Huang Q, Huang R, Zhang S, Lin J, Wei L, He M, Zhuo L and Lin X (2013) Protective effect of genistein isolated from *Hydrocotyle sibthorpioides* on hepatic injury and fibrosis induced by chronic alcohol in rats. *Toxicology Letters* **217**(2), 102–110.
- Jakowlew SB (2006) Transforming growth factor-beta in cancer and metastasis. *Cancer Metastasis Reviews* **25**(3), 435–457.
- James J, Bosch KS, Aronson DC and Houtkooper JM (1990) Sirius red histophotometry and spectrophotometry of sections in the assessment of the collagen content of liver tissue and its application in growing rat liver. *Liver* **10**(1), 1–5.
- Jones-Bolin S (2012) Guidelines for the care and use of laboratory animals in biomedical research. *Current Protocols in Pharmacology*. Appendix 4, Appendix 4B.
- Kar PK, Tandon V and Saha N (2002) Anthelmintic efficacy of *Flemingia vesitita*: genistein-induced effect on the activity of nitric oxide synthase and nitric oxide in the trematode parasite, *Fasciolopsis buski*. *Parasitology International* **51**(3), 249–257.
- Keerthisingam CB, Jenkins RG, Harrison NK, Hernandez-Rodriguez NA, Booth H, Laurent GJ, Hart SL, Foster ML and McNulty RJ (2001) Cyclooxygenase-2 deficiency results in a loss of the anti-proliferative response to transforming growth factor-beta in human fibrotic lung fibroblasts and promotes bleomycin-induced pulmonary fibrosis in mice. *The American Journal of Pathology* **158**(4), 1411–1422.
- Knodell RG, Ishak KG, Black WC, Chen TS, Craig R, Kaplowitz N, Kiernan TW and Wollman J (1981) Formulation and application of a numerical scoring system for assessing histological activity in asymptomatic chronic active hepatitis. *Hepatology (Baltimore, Md.)* **1**(5), 431–435.
- Kole L, Giri B, Manna SK, Pal B and Ghosh S (2011) Biochanin-A, an isoflavone, showed anti-proliferative and anti-inflammatory activities through the inhibition of iNOS expression, p38-MAPK and ATF-2 phosphorylation

- and blocking NF $\kappa$ B nuclear translocation. *European Journal of Pharmacology* **653**(1–3), 8–15.
- Křížová L, Dadáková K, Kašparovská J and Kašparovský T** (2019) Isoflavones. *Molecules* **24**(6), 1076.
- Lam HYP, Liang T-R and Peng S-Y** (2021) Ameliorative effects of Schisandrin B on *Schistosoma mansoni*-induced hepatic fibrosis *in vivo*. *PLOS Neglected Tropical Diseases* **15**(6), e0009554.
- Liang YS, Bruce JI and Boyd DA** (1987) Laboratory cultivation of schistosome vector snails and maintenance of schistosome life cycles. pp. 34–48. In *Proceeding of the 1st Sino-American Symposium*, Vol. 1.
- Livak KJ and Schmittgen TD** (2001) Analysis of relative gene expression data using real-time quantitative PCR and the 2(-Delta Delta C(T)) method. *Methods (San Diego, Calif)* **25**(4), 402–408.
- Macneal K and Schwartz DA** (2012) The genetic and environmental causes of pulmonary fibrosis. *Proceedings of the American Thoracic Society* **9**(3), 120–125.
- Mahmoud TY, Rizk SM, Maghraby AS and Shaheen AA** (2014) Propolis enhances the effectiveness of praziquantel in experimental schistosomiasis: biochemical and histopathological study. *Parasitology Research* **113**(12), 4513–4523.
- Matsumoto S, Okabe Y, Setoyama H, Takayama K, Ohtsuka J, Funahashi H, Imaoka A, Okada Y and Umesaki Y** (1998) Inflammatory bowel disease-like enteritis and caecitis in a senescence accelerated mouse P1/Yit strain. *Gut* **43**(1), 71–78.
- McManus DP, Dunne DW, Sacko M, Utzinger J, Vennervald BJ and Zhou X-N** (2018) Schistosomiasis. *Nature Reviews Disease Primers* **4**(1), 13.
- Meng X-M, Nikolic-Paterson DJ and Lan HY** (2016) TGF- $\beta$ : the master regulator of fibrosis. *Nature Reviews. Nephrology* **12**(6), 325–338.
- Miller MJ, Thompson JH, Zhang XJ, et al.** (1995) Role of inducible nitric oxide synthase expression and peroxynitrite formation in guinea pig ileitis. *Gastroenterology* **109**(5), 1475–1483.
- Mohamed AH, Hassab El-Nabi SE, Bayomi AE and Abdelaal AA** (2016) Effect of bee venom or propolis on molecular and parasitological aspects of *Schistosoma mansoni* infected mice. *Journal of Parasitic Diseases: Official Organ of the Indian Society for Parasitology* **40**(2), 390–400.
- Moon YJ, Sagawa K, Frederick K, Zhang S and Morris ME** (2006) Pharmacokinetics and bioavailability of the isoflavone biochanin A in rats. *The AAPS Journal* **8**(3), E433–E442.
- Mordvinov VA, Shilov AG and Pakharukova MY** (2017) Anthelmintic activity of cytochrome P450 inhibitors miconazole and clotrimazole: *in-vitro* effect on the liver fluke *Opisthorchis felinus*. *International Journal of Antimicrobial Agents* **50**(1), 97–100.
- Moreira RK** (2007) Hepatic stellate cells and liver fibrosis. *Archives of Pathology & Laboratory Medicine* **131**(11), 1728–1734.
- Naguleswaran A, Spicher M, Vonlaufen N, Ortega-Mora LM, Torgerson P, Gottstein B and Hemphill A** (2006) *In vitro* metacystocidal activities of genistein and other isoflavones against *Echinococcus multilocularis* and *Echinococcus granulosus*. *Antimicrobial Agents and Chemotherapy* **50**(11), 3770–3778.
- Pagán AJ and Ramakrishnan L** (2018) The formation and function of granulomas. *Annual Review of Immunology* **36**, 639–665.
- Pakharukova MY, Pakharukov YV and Mordvinov VA** (2018) Effects of miconazole/clotrimazole and praziquantel combinations against the liver fluke *Opisthorchis felinus* *in vivo* and *in vitro*. *Parasitology Research* **117**(7), 2327–2331.
- Pohlars D, Brennoehl J, Löffler I, Müller CK, Leipner C, Schultze-Mosgau S, Stallmach A, Kinne RW and Wolf G** (2009) TGF- $\beta$  and fibrosis in different organs—molecular pathway imprints. *Biochimica Et Biophysica Acta* **1792**(8), 746–756.
- Prud'homme GJ** (2007) Pathobiology of transforming growth factor beta in cancer, fibrosis and immunologic disease, and therapeutic considerations. *Laboratory Investigation; A Journal of Technical Methods and Pathology* **87**(11), 1077–1091.
- Qiu L, Lin B, Lin Z, Lin Y, Lin M and Yang X** (2012) Biochanin A ameliorates the cytokine secretion profile of lipopolysaccharide-stimulated macrophages by a PPAR $\gamma$ -dependent pathway. *Molecular Medicine Reports* **5**(1), 217–222.
- Ruan B, Zhang Y, Tadesse S, et al.** (2020) Synthesis and structure–activity relationship study of pyrrolidine-oxadiazoles as anthelmintics against *Haemonchus contortus*. *European Journal of Medicinal Chemistry* **190**, 112100.
- Rufatto LC, dos Santos DA, Marinho F, Henriques JAP, Roesch Ely M and Moura S** (2017) Red propolis: chemical composition and pharmacological activity. *Asian Pacific Journal of Tropical Biomedicine* **7**(7), 591–598.
- Sadri H, Goodarzi MT, Salemi Z and Seifi M** (2017) Antioxidant effects of biochanin A in streptozotocin induced diabetic rats. *Brazilian Archives of Biology and Technology* **60**(0).
- Saleh DO, Abdel Jaleel GAR, El-Awdan SA, Oraby F and Badawi M** (2014) Thioacetamide-induced liver injury: protective role of genistein. *Canadian Journal of Physiology and Pharmacology* **92**(11), 965–973.
- Sangeethadevi G, Sathibabu Uddand Rao VV, Jansy Isabella RAR, Saravanan G, Ponmurugan P, Chandrasekaran P, Sengottuvelu S and Vadivukkarasi S** (2022) Attenuation of lipid metabolic abnormalities, proinflammatory cytokines, and matrix metalloproteinase expression by biochanin-A in isoproterenol-induced myocardial infarction in rats. *Drug and Chemical Toxicology* **45**(5), 1951–1962.
- Sarfraz A, Javed M, Shah MA, et al.** (2020) Biochanin A: a novel bioactive multifunctional compound from nature. *The Science of the Total Environment* **722**(1), 137907.
- Sartorelli P, Carvalho CS, Reimão JQ, Ferreira MJP and Tempone AG** (2009) Antiparasitic activity of biochanin A, an isolated isoflavone from fruits of *Cassia fistula* (Leguminosae). *Parasitology Research* **104**(2), 311–314.
- Shaker ME, Eisa NH, Elgaml A, El-Mesery A, El-Shafey M, El-Dosoky M, El-Mowafy M and El-Mesery M** (2021) Ingestion of mannose ameliorates thioacetamide-induced intrahepatic oxidative stress, inflammation and fibrosis in rats. *Life Sciences* **286**(1), 120040.
- Silva MP, Silva TM, Mengarda AC, Salvadori MC, Teixeira FS, Alencar SM, Luz Filho GC, Bueno-Silva B and de Moraes J** (2021) Brazilian red propolis exhibits antiparasitic properties *in vitro* and reduces worm burden and egg production in an [sic] mouse model harboring either early or chronic *Schistosoma mansoni* infection. *Journal of Ethnopharmacology* **264**(1), 113387.
- Sobhy MMK, Mahmoud SS, El-Sayed SH, Rizk EMA, Raafat A and Negr MSI** (2018) Impact of treatment with a protein tyrosine kinase inhibitor (genistein) on acute and chronic experimental *Schistosoma mansoni* infection. *Experimental Parasitology* **185**(1), 115–123.
- Song L-J, Luo H, Fan W-H, et al.** (2016) Oxadiazole-2-oxides may have other functional targets, in addition to SjtGR, through which they cause mortality in *Schistosoma japonicum*. *Parasites & Vectors* **9**(1), 26.
- Stachulski AV, Berry NG, Lilian Low AC, Moores SL, Row E, Warhurst DC, Adagu IS and Rossignol J-F** (2006) Identification of isoflavone derivatives as effective anticryptosporidial agents *in vitro* and *in vivo*. *Journal of Medicinal Chemistry* **49**(4), 1450–1454.
- Suzuki S, Toledo-Pereyra LH, Rodriguez FJ and Cejalvo D** (1993) Neutrophil infiltration as an important factor in liver ischemia and reperfusion injury. Modulating effects of FK506 and cyclosporine. *Transplantation* **55**(6), 1265–1272.
- Tandon V and Das B** (2018) Genistein: is the multifarious botanical a natural anthelmintic too? *Journal of Parasitic Diseases* **42**(2), 151–161.
- Tandon V, Pal P, Roy B, Rao HSP and Reddy KS** (1997) *In vitro* anthelmintic activity of root-tuber extract of *Flemingia vestita*, an indigenous plant in Shillong, India. *Parasitology Research* **83**(5), 492–498.
- Tasdemir D, Kaiser M, Brun R, Yardley V, Schmidt TJ, Tosun F and Rüedi P** (2006) Antitrypanosomal and antileishmanial activities of flavonoids and their analogues: *in vitro*, *in vivo*, structure–activity relationship, and quantitative structure–activity relationship studies. *Antimicrobial Agents and Chemotherapy* **50**(4), 1352–1364.
- Tekwu EM, Anyan WK, Boamah D, Baffour-Awuah KO, Keyetat Tekwu S, Penlap Beng V, Nyarko AK and Bosompem KM** (2016) Mechanically produced schistosomula as a higher-throughput tools for phenotypic pre-screening in drug sensitivity assays: current research and future trends. *Biomarker Research* **4**, 21.
- Turman CM, Hatley JM, Ryder DJ, Ravindranath V and Strobel HW** (2006) Alternative splicing within the human cytochrome P450 superfamily with an emphasis on the brain: the convolution continues. *Expert Opinion on Drug Metabolism & Toxicology* **2**(3), 399–418.

- Vale N, Gouveia MJ and Gärtner F (2020) Current and novel therapies against helminthic infections: The potential of antioxidants combined with drugs. *Biomolecules* **10**(3), E350.
- Vijaya and Yadav AK (2016) *In vitro* anthelmintic assessment of selected phytochemicals against *Hymenolepis diminuta*, a zoonotic tapeworm. *Journal of Parasitic Diseases* **40**(3), 1082–1086.
- von Lichtenberg L (1962) Host response to eggs of *S. mansoni*. I. Granuloma formation in the unsensitized laboratory mouse. *The American Journal of Pathology* **41**(6), 711–731.
- West RA, O'Doherty OG, Askwith T, et al. (2017) African trypanosomiasis: synthesis & SAR enabling novel drug discovery of ubiquinol mimics for trypanosome alternative oxidase. *European Journal of Medicinal Chemistry* **141**, 676–689.
- Xaubet A, Roca-Ferrer J, Pujols L, Ramírez J, Mullol J, Marin-Arguedas A, Torrego A, Gimferrer JM and Picado C (2004) Cyclooxygenase-2 is up-regulated in lung parenchyma of chronic obstructive pulmonary disease and down-regulated in idiopathic pulmonary fibrosis. *Sarcoidosis, Vasculitis, and Diffuse Lung Diseases: Official Journal of WASOG* **21**(1), 35–42.
- Yang H, Xuefeng Y, Shandong W and Jianhua X (2020) COX-2 in liver fibrosis. *Clinica Chimica Acta; International Journal of Clinical Chemistry* **506**(1), 196–203.
- Ying H-Z, Chen Q, Zhang W-Y, Zhang H-H, Ma Y, Zhang S-Z, Fang J and Yu C-H (2017) PDGF signaling pathway in hepatic fibrosis pathogenesis and therapeutics (review). *Molecular Medicine Reports* **16**(6), 7879–7889.
- Yu C, Zhang P, Lou L and Wang Y (2019) Perspectives regarding the role of biochanin A in humans. *Frontiers in Pharmacology* **10**(1), 793.
- Zhang C-Y, Yuan W-G, He P, Lei J-H and Wang C-X (2016) Liver fibrosis and hepatic stellate cells: etiology, pathological hallmarks and therapeutic targets. *World Journal of Gastroenterology* **22**(48), 10512–10522.
- Zhang H, Gu H, Jia Q, Zhao Y, Li H, Shen S, Liu X, Wang G and Shi Q (2020) Syringin protects against colitis by ameliorating inflammation. *Archives of Biochemistry and Biophysics* **680**(1), 108242.
- Zhao L, Wang Y, Liu J, Wang K, Guo X, Ji B, Wu W and Zhou F (2016) Protective effects of genistein and puerarin against chronic alcohol-induced liver injury in mice via antioxidant, anti-inflammatory, and anti-apoptotic mechanisms. *Journal of Agricultural and Food Chemistry* **64**(38), 7291–7297.
- Ziniel PD, Karumudi B, Barnard AH, Fisher EMS, Thatcher GRJ, Podust LM and Williams DL (2015) The *Schistosoma mansoni* cytochrome P450 (CYP3050A1) is essential for worm survival and egg development. *PLoS Neglected Tropical Diseases* **9**(12), e0004279.