

Vitamin B₆ deficiency experimentally-induced bone and joint disorder: microscopic, radiographic and biochemical evidence

BY PRISCILLE G. MASSÉ¹, KENNETH P. H. PRITZKER², MARIA G. MENDES²,
ADELE L. BOSKEY³ AND HARALD WEISER⁴

¹ *École de nutrition et d'études familiales, Université de Moncton, Moncton, New Brunswick, Canada E1A 3E9*

² *The Connective Tissue Research Group, Department of Pathology, Mount Sinai Hospital, University of Toronto, Toronto, Canada M5G 1X5*

³ *The Laboratory of Ultrastructural Biochemistry, The Hospital for Special Surgery, New York 10021, USA*

⁴ *Department of Vitamin Research and Development, Hoffmann–La Roche Ltd, Basel, Switzerland*

(Received 24 June 1993 – Revised 20 September 1993 – Accepted 23 September 1993)

In the present study the effect of pyridoxine deficiency on the ultrastructure and morphology of bone and its metabolism was examined in the rapidly growing chick. Pyridoxine-deficient animals had tibias of reduced dry weight and cortical thickness. Histomorphometry demonstrated a disproportionately high eroded surface, lower amount of osteoid tissue and reduced mineralized trabecular width. Anterior–posterior radiographs of the tibiotarsometatarsal joint showed reduced secondary ossification centres and coarse trabeculation. Decalcified metaphyseal cartilage showed irregular trabeculas and a markedly reduced amount of Fast-green counterstain matrix suggesting that there is less collagen present and in turn less availability for matrix to be laid down for later calcification. Plasma activity of the bone alkaline phosphatase isoenzyme (EC 3.1.3.1) was decreased. Plasma Ca and PO₄ levels did not vary. The present bone study referring to a pseudo-lathyritic state in which collagen maturation is not completely achieved supports the hypothesis that pyridoxine is an essential nutrient for the connective tissue matrix.

Pyridoxine deficiency: Osteogenic disorder: Connective tissue: Osteoid mineralization

With all the synthetic activity accompanying growing bone it is obvious that the growth pattern can be affected by any metabolic alterations that interfere with the formation of the extracellular matrix. The need for proteins, Ca, and vitamin D in the mineralization of connective tissue has been emphasized repeatedly. The role of pyridoxine in the central nervous system is well known. However, there exist few reports on the need for this B-complex vitamin to maintain the structural integrity of the connective tissue, particularly the one having mineralizing properties. Collagen provides an organized matrix for the deposition of bone mineral crystals (Reddi, 1981; Heinegard *et al.* 1989). Mineralization of bone can take place only after a suitable matrix has been established (Reddi, 1981; Vetter *et al.* 1991). This is apparent from studies of situations where collagen synthesis is altered, such as vitamin C deficiency (Boskey *et al.* 1991). The metabolic defect in osteolathyrism produces connective tissue abnormalities which result in an accumulation of soluble collagen (Levine & Gross, 1959). As a consequence, the collagen of these animals is weak and fragile, giving rise to scoliosis and severe limb deformities. Dodds *et al.* (1986) demonstrated histological bone lesions in vitamin B₆ deficiency which were similar to those seen in osteoporosis.

The main objective of the present investigation was to correlate the vitamin B₆ deficiency-induced ultrastructural defect in cartilage collagen previously described by electron microscopy (Massé *et al.* 1990) with bone collagen metabolism. The osteoporotic-like bone disorder induced by vitamin B₆ deficiency has been previously described roentgenographically by Benke *et al.* (1972). The aim of the present study was to demonstrate histological and biochemical evidence for the consequences of a lack of vitamin B₆ on growth and development of chick bones located at the tibiotarsometatarsal joint involved in the weight-bearing load.

MATERIALS AND METHODS

Animals and diets

Male Lohmann chicks (1-d-old; rapidly growing commercial broilers) were randomly assigned to a control vitamin B₆-adequate (3 mg/kg) diet or a vitamin B₆-deficient diet (0.4 mg/kg). They were weighed at the beginning of the experiment; each group had a similar mean initial body weight (43 (SD 5) g). The chicks were housed in an animal room in thermostatically controlled starter batteries (31°) for the first week, and then reared to 6 weeks of age in broader wire-bottom cages kept at a constant ambient temperature (28°). A 12 h light-dark schedule was maintained daily. The animals were treated according to animal care regulations established at Hoffmann-La Roche, Basel, Switzerland.

The experimental basal diet corresponded to that published previously except that it did not contain yeast (Massé *et al.* 1988). This diet, based on a soy protein isolate (90% protein; Soyamin; Sugro Ltd., Basel, Switzerland), was vitamin- and mineral-supplemented to fulfil all nutritional requirements during growth. The vitamin D level was kept constant and the Ca:P molar ratio of 1.5:1 was optimal for chick bone growth (Scott *et al.* 1982). Microbiological analysis revealed that the control and the experimental rations contained 3 and 0.4 mg vitamin B₆/kg respectively. In order to ensure normal growth and to maintain an anabolic state, the vitamin B₆-deficient diet was initiated only after the first or second week of age following a short period of vitamin B₆ ingestion (3 or 1.5 mg/kg diet respectively). Such an experimental design was aimed at producing a moderate pyridoxine deficiency characterized by a reduction in pyridoxal phosphate (PLP) in erythrocytes (Saubertlich, 1981). Feed and water were provided *ad lib.* throughout the 6-week experiment. Chicks were weighed twice weekly and examined to make sure they did not suffer a loss of appetite, growth retardation and neurological symptoms, characteristics of a severe vitamin B₆ deficiency.

Biochemical determinations in plasma and erythrocytes

At the end of the experiment, 5 ml fasting blood was collected by jugular venepuncture using a heparinized syringe. A volume of approximately 2 ml was immediately transferred to a brown vacutainer tube (vitamin B₆ is light-sensitive) containing heparin plus phosphatase inhibitors for use in the determination of erythrocyte PLP using a tyrosine apodecarboxylase (EC 4.1.1.25) assay (Vuilleumier *et al.* 1983). The vials were stored at 4–6° before analysis. The blood was centrifuged for 10 min at 1000 g. After the removal of plasma, erythrocytes were resuspended in an equal volume of isotonic saline (9 g NaCl/l) and centrifuged for 10 min at 1000 g. The rest of the blood was centrifuged at 3000 g for 20 min and plasma was removed. Plasma samples were processed to determine Ca, P and alkaline phosphatase (ALP; orthophosphoric monoester phosphohydrolyse alkaline, EC 3.1.3.1) by means of an automated COBAS Bio analyser (Hoffmann-La Roche, Basel, Switzerland). ALP is present in the plasma in amounts that vary with osteoblastic activity

provided that liver function is normal. Plasma ALP bone isoenzyme was determined by using bromotetramisole as inhibitor (Borgers & Thoné, 1975). Hydroxyproline (OH-Pro) in plasma was another biochemical indicator that was used to assess collagen metabolism. A first set of plasma samples was deproteinized with trichloroacetic acid (TCA) and the supernatant fraction was analysed after HCl hydrolysis to determine free OH-Pro; a second set of plasma samples was analysed immediately after HCl hydrolysis in order to determine the total OH-Pro content. The difference in values obtained, corresponding to the collagen-like protein as described by LeRoy *et al.* (1964), served to estimate collagen degradation. The procedure used in both determinations involves oxidation of the iminoacid and decarboxylation to pyrrole, followed by condensation with *p*-dimethylaminobenzaldehyde (Woessner, 1961).

Bone X-rays and histomorphometry

Immediately after killing the animals by cervical dislocation, the left tibiotarsometatarsal (hock) joint, with the long bones cut at mid-shaft, was removed and fixed in neutral buffered formalin. Lateral and anterior-posterior X-rays of control and vitamin B₆-deficient bones were taken ($\times 5$ magnification) by microfocal radiography using 3MR2 film (Cashin *et al.* 1980). Morphological changes, e.g. widths of hock joint and diaphyseal tibia and cortical thickness at mid-shaft, were measured with a micrometer. The right tibia was also removed for the study of biomechanical properties.

Control and vitamin B₆-deficient distal tibias (in total eight samples) were fixed in alcohol (700 ml/l) and hand processed in ascending grades of acetone for dehydration purposes, in order to perform a pilot static histomorphometric study. The samples were then placed in ascending grades of plastic-acetone (Spurr) and were eventually embedded in Spurr and placed in a 60° oven for 48 h to polymerize. The specimen blocks were cut on a Reichert-Jung microtome using a tungsten carbide knife. The sections (5 μm) were placed on gelatinized slides and placed in a 60° oven overnight. The sections were deplasticized in a sodium ethoxide solution (30 g/l) and then stained using the von Kossa/Basic Fuchsin method (Lillie, 1965). Mid-coronal sections were used for trabecular measurements. The morphometric assessment was performed using the Bioquant system (IV) coupled with a Leitz microscope. The software used was Bone Morphometry, version 8.14 (Bioquant; R & M Biometrics, Nashville, IN, USA). Measurements were taken in the appendicular skeleton, at a magnification of $\times 94$, and did not include the growth plate. These measurements are described with reference to the nomenclature and symbols recommended by the Bone Histomorphometry Nomenclature Committee of the American Society for Bone and Mineral Research (Parfitt *et al.* 1987) as follows: (1) bone volume (BV/TV), the proportion of tissue volume occupied by trabecular bone; (2) osteoid volume (OV/BV), the percentage of trabecular bone consisting of osteoid; if 100% of the bone surface were covered by osteoid, trabecular thickness would be made up of the mineralized core trabecula and an osteoid seam on either side, that is, twice the osteoid width. At lower percentages of osteoid surface, a correspondingly smaller proportion of the trabecular thickness would be made up of osteoid (Schnitzler *et al.* 1990); (3) osteoid width (O.Wi), the mean distance between mineralization fronts and osteoid surface; (4) osteoid surface (OS/BS), the proportion of trabecular surface covered by osteoid; (5) eroded surface (ES/BS), the proportion of trabecular surface occupied by eroded surface.

Proximal tibiotarsometatarsal bone was dissected and transferred to buffered neutral formalin (100 ml/l) for histological study on metaphyseal cartilage. After decalcification in formic acid they were then transferred at daily intervals to 400, 700 and 850 ml ethanol/l for dehydration. The cartilage tissues were then embedded in paraffin. Five sections (5 μm) were stained with Safranin O (orthochromatic form) as described by Rosenberg (1971).

Fast-green was used in sequence with Safranin O to counterstain protein with a contrasting colour according to Lillie's procedure (1965).

Chemical analysis of cartilage extract

Ossa tarsi cartilage, located at the distal end of the tibia, was excised and diced with a scalpel blade into cubes (approximately 1 mm³) and immediately immersed in 50 mM-sodium phosphate buffer (pH 7.4) containing protease inhibitors. Following homogenization and demineralization in 0.5 M-EDTA (pH 7.5), proteoglycans (PG) were extracted with constant gentle stirring in polycarbonate tubes adapted to a Beckman 30 rotor at 4° for 18 h with ten volumes of 4.0 M-guanidine hydrochloride (Fluka, Buchs, Switzerland) containing 50 mM-sodium acetate, 0.005 M-benzamidine hydrochloride (Sigma, St Louis, MO, USA), 0.1 M-6-aminohexanoic acid (Sigma) and 0.05 M-sodium acetate (pH 7.5; Reddi *et al.* 1978). Solubilized PG were separated from the collagen matrix by centrifugation (30000 g) at 4° for 20 min. The supernatant fraction was diluted 1:10 (v/v) and analysed to determine the hexuronic acid (Bitter & Muir, 1962) and protein contents (Bradford, 1976). The protein:uronic acid ratio was calculated to assess the degree of maturity of the cartilaginous tissue.

Collagen cartilage was thoroughly rinsed with water, lyophilized and weighed. Collagen was sequentially extracted with a neutral salt and a dilute organic acid solvent as follows. Cartilage was homogenized and stirred for 16 h in ten volumes of 1 M-NaCl. After centrifugation at 30000 g for 1 h the residue was extracted for another 8 h and then centrifuged again. The combined supernatant fractions were used as a source of salt-soluble collagen. After removing the supernatant fraction the pellet was dissolved by shaking with ten times its volume of 0.5 M-acetic acid overnight and centrifuged at 100000 g for 1 h to remove insoluble residue. All these operations were conducted at 4° using inhibitors for serine-, metallo-, thiol- and carboxyl-proteinases (1 mM-*p*-toluenesulphonyl fluoride, 10 µM-sodium *p*-chloromercuribenzoate, 5 mM-*N*-ethylmaleimide, 50 mM-disodium ethylenedinitriloacetate, 5 mM-benzamidine hydrochloride and 50 mM- ϵ -aminocaproic acid. Following hydrolysis in 6 M-HCl at 100° for 24 h, OH-Pro was determined to estimate the collagen content in soluble and insoluble fractions of cartilage extracts (Woessner, 1961) using a factor of 7.6.

Statistical analysis

Statistical analysis was by analysis of variance, with statements of significance based on $P < 0.05$. The Bonferroni adjustment was applied to the significance level. Because of the small number of animals used for the pilot histomorphometric study, conventional statistical analysis could not be used to compare differences between experimental and control bones. Z scores were utilized, therefore, to determine whether measurements lay within the normal range of variation for each histomorphometric variable (Snedecor & Cochran, 1982). The Z score indicates the distance, in standard deviation units, that a measurement lies from the control value. Z scores > 2.0 (95% probability) or > 3.0 (99% probability) lie outside the normal range of variability. Z scores < 2.0 were considered to be not significantly different from control values.

RESULTS

Table 1 summarizes data pertinent to the vitamin B₆ status at time of death. Vitamin B₆ deficiency was characterized by a two-thirds decrease in PLP in erythrocytes. The erythrocyte PLP reduction varied depending on the age of the birds at the time of depletion.

Table 1. Effect of vitamin B₆ deficiency on growth and erythrocyte pyridoxal phosphate (PLP) levels in the chick after 6 weeks of experiment†

(Mean values and standard deviations)

Dietary treatment	Expt no.	n	Weight gain (g)		PLP (nmol/l blood)	
			Mean	SD	Mean	SD
Vitamin B ₆ -adequate diet		15	1670	118	316	50
Vitamin B ₆ -deprivation after:						
First week of age	1	13	1490	221	72***	16
Second week of age	2	14	1506	212	97***	42

Mean value was significantly different from that of the vitamin B₆-adequate group: *** $P < 0.001$.

† For details of diets and procedures, see pp. 920-921.

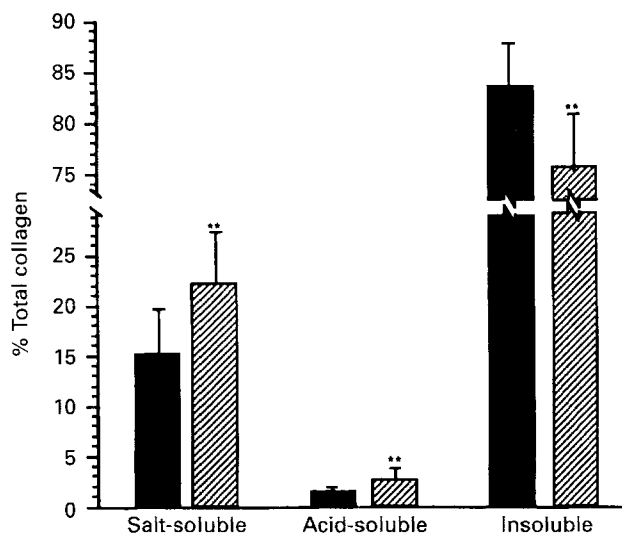


Fig. 1. Comparison between control (■, $n = 7$) and vitamin B₆-deficient (▨, $n = 13$) groups with respect to solubility of collagen in *Ossa tarsi* cartilage. Relative proportions of collagen fractions are expressed as mean percentage of total collagen. Salt- and acid-soluble collagen concentrations were increased in the experimental groups whereas the insoluble collagen fraction was reduced. ** $P < 0.01$.

The most severe decline occurred when the deficiency started after the first week of age (72 (SD 16) nmol/l). Deficient chicks grew normally and their weight gain at the end of the 6-week experiment was slightly lower but the difference was not significantly different from controls. Chemical analysis of cartilage extract showed no difference in the protein:uronic acid ratio, used to assess the degree of maturity of the connective tissue, excluding the possibility of a delay in tissue development. The protein content of vitamin B₆-deficient extracts was identical to that of controls (results not shown). Fig. 1 shows the relative proportion of collagen in each fraction extract of *Ossa tarsi* cartilage, expressed as percentage of total collagen. The amounts of collagen extracted by neutral salt and acetic acid from vitamin B₆-deficient cartilage were significantly ($P < 0.01$) greater than those from controls, indicating a marked increase in the solubility of cartilage collagen. The

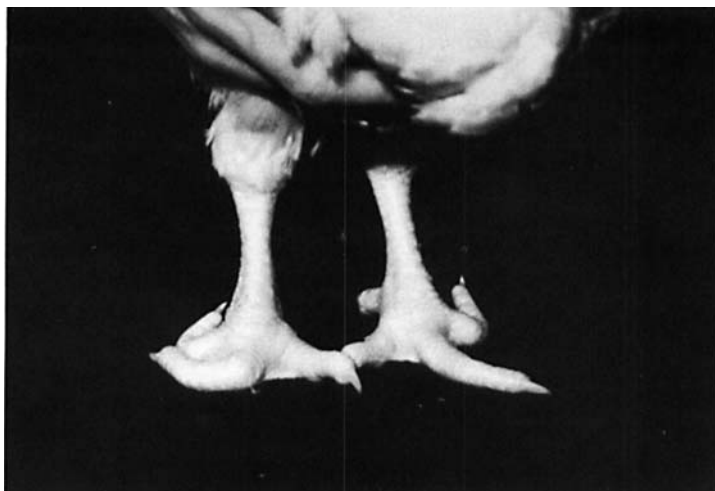


Plate 1. Abnormal flexion of digits (crooked toes) in both extremities of a vitamin B₆-deficient chick.

amount of insoluble collagen in vitamin B₆-deficient cartilage extract was lower in comparison with controls ($P < 0.01$).

Vitamin B₆-deficient birds did not suffer from neurological symptoms but bone and joint abnormalities were apparent. Crooked toes (Plate 1), leg weakness, periarticular enlargement of the long bones and long-bone deformities (Plate 2) of one or both legs occurred in nine out of twenty-seven birds. The tibiotarsometatarsal (hock) joint was unstable and subluxation of the *Achilles* tendon was observed in 13% of the vitamin B₆-deficient birds. Table 2 depicts some biological characteristics of the weight-bearing joint. Vitamin B₆-deficient tibias weighed less than those of the control group ($P < 0.01$). Linear bone growth did not seem to be affected; in fact, length of tibia was unchanged by the dietary vitamin B₆-restriction. The hock joint was enlarged ($P < 0.01$). The osteoblastic activity as assessed by plasma ALP bone isoenzyme and used as a biochemical index of bone formation was significantly ($P < 0.05$) reduced in vitamin B₆ deficiency (Table 3). The activity of this enzyme is normally high in chick plasma. Compared with controls, the plasma OH-Pro level was significantly ($P < 0.01$) lower in vitamin B₆-deficiency. The proportion of collagen-like protein identified as hyproprotein OH-Pro, which was used as an index for collagen catabolism, was significantly ($P < 0.05$) greater but the difference was significant only when the vitamin B₆-restriction started early after the first week of age. Plasma Ca and inorganic P levels did not vary significantly.

The right side of the upper part of the anterior-posterior microfocal radiography shows the wading bone, the fibula; it is thin and fused with the tibia (Plate 3A). On the distal epiphysis is a *Throchlea* tibia with two joint ridges corresponding to *Ossa tarsi*. The metatarsal bones (II, III, IV) are fused with each other. Located at the proximal end of *Metatarsus* (lower bone) is *Ossa tarsalia*, which fuses with the aforementioned bones at a later stage, so that a single bone, the running bone, results. In vitamin B₆ deficiency, the fusions between tibia and fibula to form *Ossa curis*, between the two ridges of *Ossa tarsi*, and between *Ossa tarsalia* and the three *Metatarsus* II, III and IV to form *Tarsometatarsus* (Plate 3B) were not as complete as in controls, indicating a delay in bone formation. Moreover, *Ossa tarsi* and *Ossa tarsalia* ossification centres were reduced compared with age-matched controls. Joint laxity was evident at the time of arthrocentesis. Lateral roentgenograms of tibias from the two experimental groups exhibited similar changes of

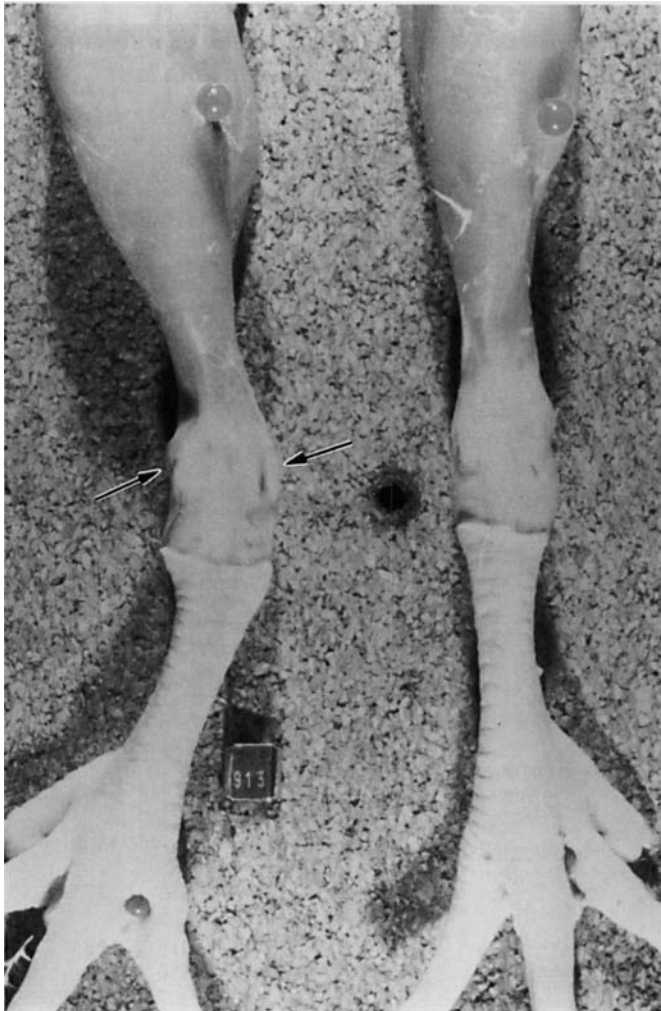


Plate 2. Long bone deformities: plantar view of tibiotarsus (upper bone) and tarsometatarsus (lower bone) of the left leg (on the left side) of a vitamin B₆-deficient chick compared with the right leg which was normal in this case; note the enlargement of the hock joint (arrows). Distally, the metatarsus carries three protrusions with one joint condyle each for the first phalanges, *Phalanges primae*.

varying degrees when compared with controls (Plate 4). These changes were characterized by the appearance of a thin, very sharply defined cortex on the one side, a remarkable area of patchy thickening of the periosteal and endosteal surfaces of the metaphysis on the other, with a very lucent central trabecular bone. Roentgenographically, the amount of trabeculation within the medullary bone decreased, and the trabeculation present was coarse and thick. A very distinct margin between cortical and medullary bone is seen. The cortices were thinner (Table 2). Group 2, being deprived after the second week of age (Plate 4C), demonstrated milder changes in comparison with group 1, deprived after the first week of age (Plate 4B).

According to bone histomorphometry, the interval range of values for eroded surface was much higher in vitamin B₆ deficiency, which was 430 score units above the value of the control group (Table 4). Moreover, mineralized trabecular width was lower. Light

Table 2. *Biological characteristics of the tibiotarsometatarsal (hock) joint in chicks fed on vitamin B₆-adequate and -deficient diets†*
(Mean values and standard deviations)

Diets	Tibia									
	Hock joint width (mm)		Dry wt (g)		Length (mm)		Diaphyseal width‡ (mm)		Cortical thickness‡ (mm × 10 ⁻³)	
	Mean	SD	Mean	SD	Mean	SD	Mean	SD	Mean	SD
Vitamin B ₆ -adequate	13.0	0.5	14.1	1.2	109	3	6.5	1.0	6.00	0.24
Vitamin B ₆ -deficient										
Expt 1	14.0**	0.8	11.9**	2.0	105	7	5.8	0.2	5.42*	0.35
Expt 2	15.1**	0.9	12.0**	1.5	106	5	6.5	0.9	5.50**	0.31

Mean value was significantly different from that of the vitamin B₆-adequate group: * $P < 0.05$, ** $P < 0.01$.

† For details of diets and procedures, see pp. 920–922.

‡ At mid-shaft.

Table 3. *Effect of vitamin B₆ deficiency on plasma biochemical markers of bone and collagen metabolism in chicks†*
(Mean values and standard deviations)

Diets	Free OH-Pro‡ (µg/ml)		Hydroprotein OH-Pro§ (µg/ml)		ALP bone isoenzyme (µmol/min per l)		Ca ²⁺ (mmol/l)		P (mmol/l)	
	Mean	SD	Mean	SD	Mean	SD	Mean	SD	Mean	SD
Vitamin B ₆ -adequate	20.2	2.9	8.1	2.9	1613	263	2.75	0.11	2.61	0.24
Vitamin B ₆ -deficient										
Expt 1	13.6**	2.3	11.4*	2.3	1341*	168	2.85	0.08	2.62	0.17
Expt 2	14.0**	2.4	9.4	2.0	1384*	250	2.81	0.06	2.65	0.26

OH-Pro, hydroxyproline; ALP, alkaline phosphatase (*EC* 3.1.3.1).

Mean value was significantly different from that of the vitamin B₆-adequate group: * $P < 0.05$, ** $P < 0.01$.

† For details of diets and procedures, see pp. 920–921.

‡ Hydrolysis of supernatant after trichloroacetic acid-deproteinization of sample.

§ Difference between total (direct hydrolysis of sample without deproteinization) and free OH-Pro.

photomicrography of vitamin B₆-deficient metaphyseal cartilage of decalcified proximal tarsometatarsus showed a markedly reduced area of counterstaining with Fast-green, indicating less matrix available for the formation of osteoid tissue (Plate 5). The reduction of osteoid tissue has been substantiated by histomorphometry (Table 4).

DISCUSSION

Of all animal structures, the legs of the chicken are one of the most complex and grow the most rapidly. It is evident that the effects of any nutrient deficiency on bone metabolism are much more pronounced, and more readily detected, in a fast-growing organism. These factors explain the choice of male broiler chicks in the present investigation. The bone and joint disorder reported here was specific to vitamin B₆ deficiency because dietary conditions

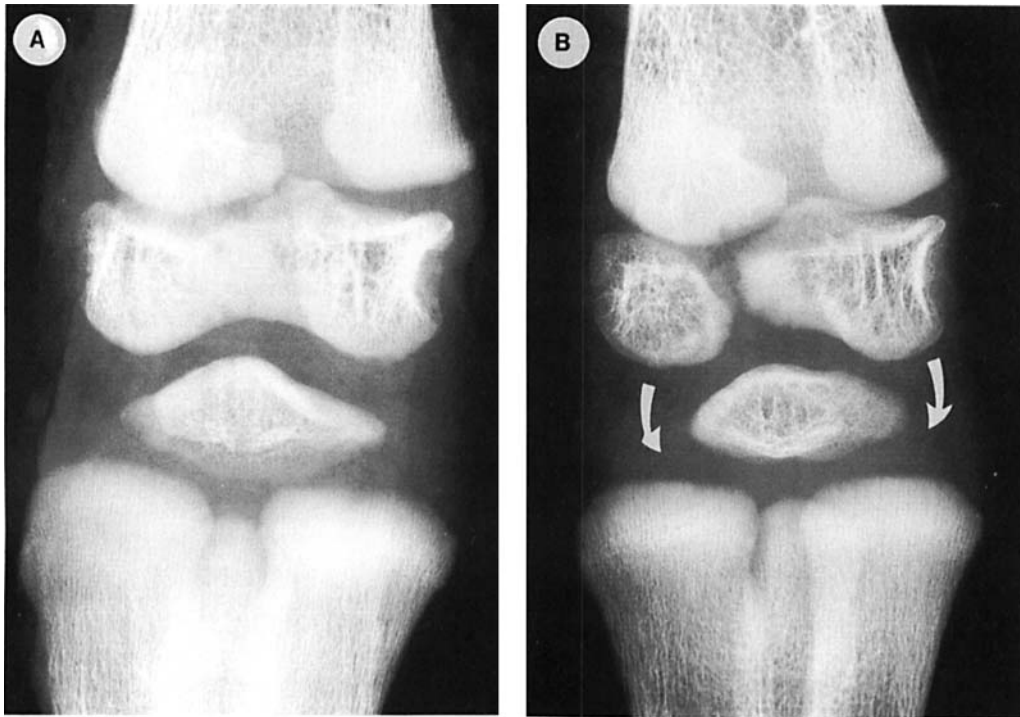


Plate 3. Anterior-posterior microfocal roentgenograms (magnification $\times 5$) of tibiotarsometatarsal (hock) joint: distal end of tibiotarsus (upper) and proximal end of tarsometatarsus (lower); (A) adequate diet: 3 mg pyridoxine-HCl/kg, for six weeks (B) 5-week vitamin B₆-depletion following 1 week of 3 mg pyridoxine-HCl/kg diet. Ossification centres are reduced and bone is less dense. Reduced soft tissue density (arrows) is indicative of ligamentous thinning and synovial oedema.

were well controlled. Overall growth and development of pyridoxine-deficient chickens were normal and the bone abnormalities produced were neither a result of inactivity or a lack of nutrients such as Ca and vitamin D, nor a direct result of decreased procollagen synthesis as in vitamin C deficiency. In contrast to this vitamin which is involved in the intracellular hydroxylation reaction of proline, the role of pyridoxine is localized in the matrix of the connective tissue. In vitamin B₆ deficiency, the regulation of bone turnover seems to be compromised due to the fact that a soluble immature collagen (Fig. 1) is produced but cannot accumulate to provide a stable protein matrix for mineralization to take place.

The ultrastructural alteration in vitamin B₆-deficient articular cartilage, which results in a significant expansion of type I collagen fibres, has been demonstrated already (Massé *et al.* 1990). Collagen fibres looked 'swollen' and seemed to be engorged with water. Collagen in vitamin B₆-deficient mineralizing cartilage differs from normal by its increased solubility as revealed by the higher proportions of salt- and acid-soluble collagens (Fig. 1), a chemical feature characterizing lathyrctic collagen. Since the neutral-salt solvent used essentially extracts molecules that are not bound within the fibres through covalent intermolecular cross-links, an increased collagen solubility is indicative of defective collagen cross-linking. Lathrogens induce connective tissue abnormalities which result in accumulation of soluble collagen (Levine, 1966). The hydrating effect of β -aminopropionitrile in lathyrism has been evidenced by chemical analysis on chick embryo cartilage. The increased collagen solubility observed in vitamin B₆ deficiency could be explained by the fact that the newly synthesized

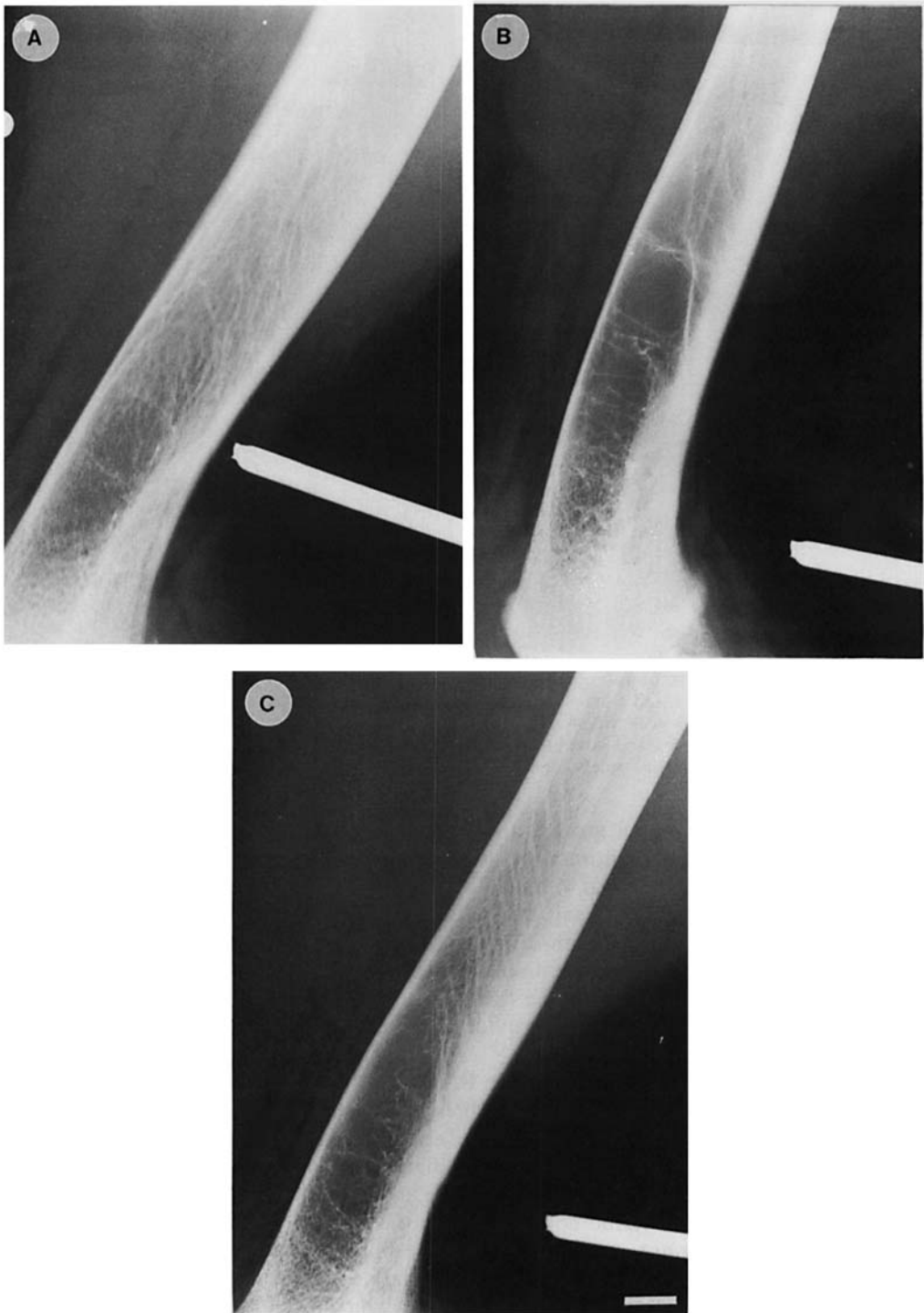

Plate 4. Lateral microfocal roentgenograms (magnification $\times 5$) of metaphysis and diaphysis of 6-week-old distal tibia: (A) adequate diet: 3 mg pyridoxine-HCl/kg for six weeks, (B) 5-week vitamin B₆ deficiency following 1 week of 3 mg pyridoxine-HCl/kg diet, (C) 4-week vitamin B₆-depletion following 2 weeks of 1.5 mg pyridoxine-HCl/kg diet. The amount of trabecula in the metaphysis is markedly reduced in both experimental groups (bar = 1 cm).

Table 4. *Static histomorphometric description of distal tibia of chicks fed on vitamin B₆-adequate or -deficient diets**

(Mean values and standard deviations for four bones in each group)

	Abbreviation†	Vitamin B ₆ -adequate			Vitamin B ₆ -deficient			Z score
		Mean	SD	Range	Mean	SD	Range	
Trabecular bone volume (%)	BV/TV	21.8	2.0	20-23	19.8	4.2	15-23	1.00
Mineralized trabecular width (μm)	Tb.Wi	60.1	4.8	56-63	43.7	6.7	38-51	3.42
Osteoid volume (%)	OV/BV	9.1	0.5	8-9	6.0	2.5	3-8	6.20
Osteoid surface (%)	OS/BS	35.5	3.4	33-37	18.0	3.2	15-18	5.15
Osteoid width (μm)	O.Wi	9.5	0.6	9.0-9.9	9.0	1.9	6-10	0.83
Eroded surface/trabecular surface (%)	ES/BS	1.1	0.02	1.12-1.15	9.8	0.9	4-18	430.00

* For details of diets and procedures, see pp. 920-922.

† Parfitt *et al.* (1987).

mature cross-link aldehydes are no longer capable of undergoing extracellular stabilization. A high collagen turnover rate would preclude the formation of cross-links since a short residence period of aldehydes in the connective tissue does not favour further reactions. In osteoporosis, Yamauchi *et al.* (1988), from their immobilized monkey model, concluded that collagen turnover in bone was increased with degradation exceeding synthesis.

Normal values herein reported for chick plasma OH-Pro levels were similar to those found by other investigators (Bannister & Burns, 1970). Since deficient animals were kept in a steady-state, protein synthesis was not expected to be affected. Moreover, all substrates known to influence hydroxylation of proline (initial reaction in procollagen synthesis) such as α -ketoglutarate from the Krebs cycle (anabolic state), dietary Fe and ascorbic acid, were present in adequate amounts. Because of the unlikelihood of a reduced procollagen synthesis, it was assumed that the decreased plasma OH-Pro level resulted from a high collagen turnover rate probably due to a higher solubility. In healthy human adults the plasma concentration of protein-bound OH-Pro is fairly stable (LeRoy & Sjoerdsma, 1965). Normal values are in the range of 4.7-9.7 $\mu\text{g}/\text{ml}$, as also found for control chicks in the present study (Table 3). The significantly higher value obtained from the more severe vitamin B₆ deficiency (11.4 (SD 2.3) $\mu\text{g}/\text{ml}$) corresponds to that of patients having a bone disease such as osteogenesis imperfecta or a disorder of connective tissue such as Ehlers-Danlos syndrome or rheumatoid arthritis.

Histological abnormalities at the level of the epiphyseal growth plate as described by Gries & Scott (1972) can explain the weakening and bending of the growing bone observed in the present study. Subluxation of the *Achilles* tendon, enlargement of the hock joint and inflammation were also displayed. Similar skeletal abnormalities, characterized by periarticular enlargement of the long bones, have been observed in young horses fed on a Cu-deficient diet (Eamens *et al.* 1984). Dodds *et al.* (1986) showed that a lack of vitamin B₆ in the diet for only 4 weeks caused transient changes in the histological appearance of rat metatarsal bones in the shaft, and more particularly in the region close to the growth plate, almost resembling osteoporotic bone with cavities lined with osteoclasts. These microscopic changes were suggestive of an imbalance in the coupling between osteoblasts and osteoclasts. Our histological study on vitamin B₆-deficient metaphyseal cartilage showed a markedly reduced area of counterstaining with Fast-green, indicating less collagen

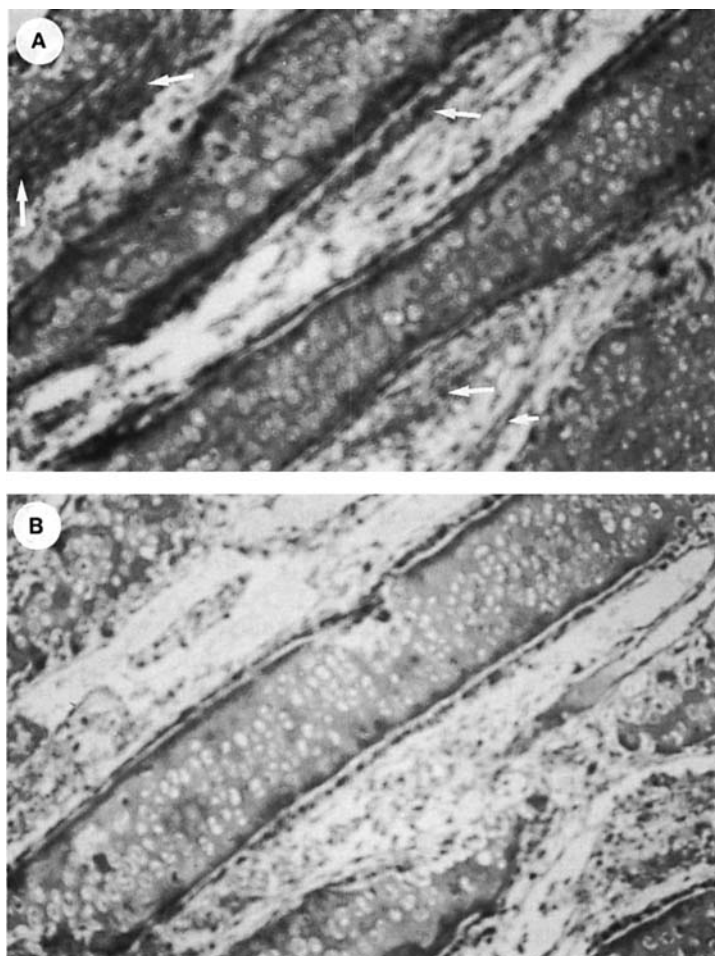


Plate 5. Decalcified metaphyseal cartilage of proximal tarsometatarsus stained with Safranin O after passage through alcohol and xylene. Safranin O stains specifically matrix proteoglycans (darker stain); collagen fibres retain the protein counterstain of contrasting colour (Fast-green; white arrows). (A) control, (B) vitamin B₆-deficient: note the reduction and irregularity of trabeculas and the reduced amount of collagen ($\times 60$).

to be present. The magnitude of histological change was sufficient to produce a sizeable decrease in mineralized trabecular width (Table 4) and some porosity at the mineralized trabecular level as viewed by X-rays (Plates 3 and 4). The seriousness of a slight decline in mineralized trabecular width is appreciated when one considers that a reduction in the cross-sectional area of a trabecular rod by a factor of two decreases its buckling resistance exponentially, that is, by a factor of four (Bell *et al.* 1967). The loss in bone strength is, therefore, disproportionately greater than the decline in mineralized trabecular width and might explain the reduced bone strength of vitamin B₆-deficient long bones. Given a constant load applied to the mid-shaft, the preliminary biomechanical study indicated a significant ($P < 0.001$) decrease in breaking time ((3.9 (SD 0.9) and 4.8 (SD 0.6) s for experiments 1 and 2 respectively) compared with controls (5.1 (SD 0.8) s).

Although histomorphometric data should be interpreted with some caution because of the limited number of vitamin B₆-deficient bones that could be examined, a disproportionate increase in eroded surface tended to occur concomitantly with a reduction

in osteoid tissue (Table 4). The eroded surface probably represented old resorption cavities that remained devoid of osteoid due to a reduced osteoblastic activity (Table 3). Mineralized bone was not formed presumably because the collagen forming within the osteoid was more soluble and, therefore, more susceptible to dissolution and catabolism. Whether the consequent low bone turnover state would lead to osteoporosis remains unanswered.

The authors wish to thank Aline Page for her skilled secretarial assistance, Dr Jean-Paul Vuilleumier for the B₆-nutritional status evaluation at Hoffmann-La Roche (Switzerland), Colin Cashin at Roche Welwyn (England) for performing the radiographic evaluation and Dr Patricia Hogan (Atlantic Veterinary College at University of Prince Edward Island, Canada) for her comments on the radiographs. They are also grateful to Manfred Schlachter for biochemical determinations. This investigation has been supported by Natural Sciences and Engineering Research Council of Canada grant OGP0046650.

REFERENCES

- Bannister, D. W. & Burns, A. B. (1970). Adaptation of the Bergman and Loxley technique for hydroxyproline determination to the autoanalyser and its use in determining plasma hydroxyproline in the domestic fowl. *Analyst* **95**, 596–600.
- Bell, G. H., Dunbar, O. & Beck, J. S. (1967). Variation in strength of vertebrae with age and their relation to osteoporosis. *Calcified Tissue Research* **1**, 75–86.
- Benke, P. J., Fleshood, H. L. & Pitot, H. C. (1972). Osteoporotic bone disease in the pyridoxine-deficient rat. *Biochemical Medicine* **6**, 526–535.
- Bitter, T. & Muir, H. M. (1962). A modified uronic acid carbazole reaction. *Analytical Biochemistry* **4**, 330–334.
- Borgers, M. E. & Thoné, F. (1975). The inhibition of alkaline phosphatase by L-bromotetramisole. *Histochemistry* **44**, 277–280.
- Boskey, A. L., Stiner, D., Doty, S. B. & Binderman, I. (1991). Requirement of vitamin C for chick cartilage calcification in a differentiating chick limb-bud mesenchymal cell culture. *Bone* **12**, 277–282.
- Bradford, M. A. (1976). A rapid and sensitive method for the quantitation of microgram quantities of protein utilizing the principle of protein-dye binding. *Analytical Biochemistry* **72**, 248–254.
- Cashin, C. H., Doherty, N. S. & Jeffries, B. L. (1980). An investigation of the effect of anti-inflammatory and anti-rheumatoid drugs in cell-mediated immune arthritis in guinea-pigs by microfocal radiography. *British Journal of Experimental Pathology* **61**, 296–302.
- Dodds, R. A., Catterall, A., Bitensky, L. & Chayen, J. (1986). Abnormalities in fracture healing induced by vitamin B₆-deficiency in rats. *Bone* **7**, 489–495.
- Eamens, G. J., Macadam, J. F. & Laing, E. A. (1984). Skeletal abnormalities in young horses associated with zinc toxicity and hypocuprosis. *Australian Veterinary Journal* **61**, 205–207.
- Gries, C. L. & Scott, M. L. (1972). The pathology of pyridoxine deficiency in chicks. *Journal of Nutrition* **102**, 1259–1268.
- Heinegard, D., Hultenby, K., Oldberg, A., Reinholt, F. & Wendel, M. (1989). Macromolecules in bone matrix. *Connective Tissue Research* **21**, 3–14.
- LeRoy, E. C., Kaplan, A., Udenfriend, S. & Sjoerdsma, A. (1964). A hydroxyproline-containing, collagen-like protein in plasma and a procedure for its assay. *Journal of Biological Chemistry* **239**, 3350–3356.
- LeRoy, C. E. & Sjoerdsma, A. (1965). Clinical significance of a hydroxyproline-containing protein in human plasma. *Journal of Clinical Investigation* **44**, 914–919.
- Levine, C. I. (1966). The hydrating effect of lathyrogenic compounds on chick-embryo cartilage in vivo. *Biochemical Journal* **101**, 441–447.
- Levine, C. I. & Gross, J. (1959). Alterations in state of molecular aggregation of collagen induced in chick embryos by β -aminopropionitrile (Lathyrus factor). *Journal of Experimental Medicine* **110**, 771–790.
- Lillie, R. D. (1965). *Histopathologic Technic and Practical Histochemistry*, 3rd ed., pp. 611–678. New York: McGraw-Hill Book Company.
- Massé, P. G., Colombo, V. E., Howell, D. S. & Weiser, H. (1990). Morphological abnormalities in vitamin B₆ tarsometatarsal chick cartilage. *Scanning Microscopy* **4**, 667–674.
- Massé, P. G., Schlachter, M. & Weiser, H. (1988). Is pyridoxine essential for bone metabolism? *International Journal for Vitamin and Nutrition Research* **58**, 295–299.
- Parfitt, A. M., Drezner, M. K., Glorieux, F. H., Kanis, J. A., Malluche, H., Meunier, P. J., Ott, S. M. & Recker, R. R. (1987). Bone histomorphometry: standardization of nomenclature, symbols and units. *Journal of Bone and Mineral Research* **2**, 595–610.

- Reddi, A. H. (1981). Cell biology and biochemistry of endochondral bone development. *Collagen Related Research* **1**, 209–226.
- Reddi, A. H., Hascall, V. C. & Hascall, G. H. (1978). Changes in proteoglycan types during matrix-induced cartilage and bone development. *Journal of Biological Chemistry* **253**, 2429–2436.
- Rosenberg, L. (1971). Chemical basis for the histological use of Safranin O in the study of articular cartilage. *Journal of Bone and Joint Surgery* **53A**, 69–82.
- Sauberlich, H. E. (1981). Vitamin B₆ status past and present. In *Methods in Vitamin B₆ Nutrition. Analysis and Status Assessment*, pp. 203–251 [J. E. Leklem and R. D. Reynolds, editors]. New York: Plenum Press.
- Schnitzler, C. M., Mesquita, J. M., Gear, K. A., Robson, H. J., Moddley, G. P. & Smyth, A. E. (1990). Iliac bone biopsies at the time of periarticular stress fractures during fluoride therapy: comparison with pretreatment biopsies. *Journal of Bone and Mineral Research* **5**, 141–152.
- Scott, M. L., Nesheim, M. C. & Young, R. J. (1982). *Nutrition of the Chicken*. Ithaca: M. L. Scott & Associates.
- Snedecor, C. W. & Cochran, W. G. (1982). *Statistical Methods*. Ames: The Iowa State University Press.
- Vetter, U., Eanes, E. D., Kopp, J. B., Termine, J. D. & Robey, P. G. (1991). Changes in apatite crystal size in bones of patients with osteogenesis imperfecta. *Calcified Tissue International* **49**, 248–250.
- Vuilleumier, J. P., Keller, H. E., Rettenmaier, R. & Hunziker, F. (1983). Clinical chemical methods for the routine assessment of the vitamin status in human populations. II. The water-soluble vitamins B₁, B₂ and B₆. *International Journal of Vitamin and Nutrition Research* **53**, 359–370.
- Woessner, J. F. Jr (1961). The determination of hydroxyproline in tissue and protein samples containing small proportions of this imino acid. *Archives of Biochemistry and Biophysics* **93**, 440–447.
- Yamauchi, M., Young, D. R., Chandler, G. S. & Mechanic, G. L. (1988). Cross-linking and new bone collagen synthesis in immobilized and recovering primate osteoporosis. *Bone* **9**, 415–418.