

Very high take-off the right coronary artery with double outlet right ventricle

Musa Öztürk and Hayrettin Hakan Aykan

Department of Pediatric Cardiology, Hacettepe University Hospital, Ankara, Turkey

Images in Congenital Cardiac Disease

Cite this article: Öztürk M and Aykan HH (2024). Very high take-off the right coronary artery with double outlet right ventricle. *Cardiology in the Young*, page 1 of 2. doi: [10.1017/S1047951124026878](https://doi.org/10.1017/S1047951124026878)

Received: 12 September 2024
Revised: 22 September 2024
Accepted: 24 September 2024

Keywords:

High take-off coronary artery; double outlet right ventricle; coronary anomaly

Corresponding author:

Musa Öztürk; Email: mozturk91@gmail.com

Abstract

This article presents an anatomical variation of the very high take-off right coronary artery from the ascending aorta. Clinical care is complicated by the patient's double outlet right ventricle and right aortic arch associated with this situation.

Case report

Our case is a 10-year-old girl, weighing 28 kg and 138 cm tall. The patient has a diagnosis of double outlet right ventricle with D-malposition of the great arteries (S, D, D) and severe infundibular stenosis accompanied by right aortic arch. Right modified Blalock–Taussig shunt in infancy, surgical correction was applied at the age of five

The patient complained of fatigue and shortness of breath. Echocardiographic evaluation revealed severe pulmonary valve insufficiency and right heart chamber enlargement. Angiography was performed to evaluate the pulmonary valve and right ventricular outflow tract.

In the injection made into the aortic root, it was seen that the aorta was 35 mm (+4.8 Z score) at the level of the sinus valsa and the left coronary artery had a normal anatomical origin. The right coronary artery originated from the left anterior superior of the ascending aorta. (Figure 1)

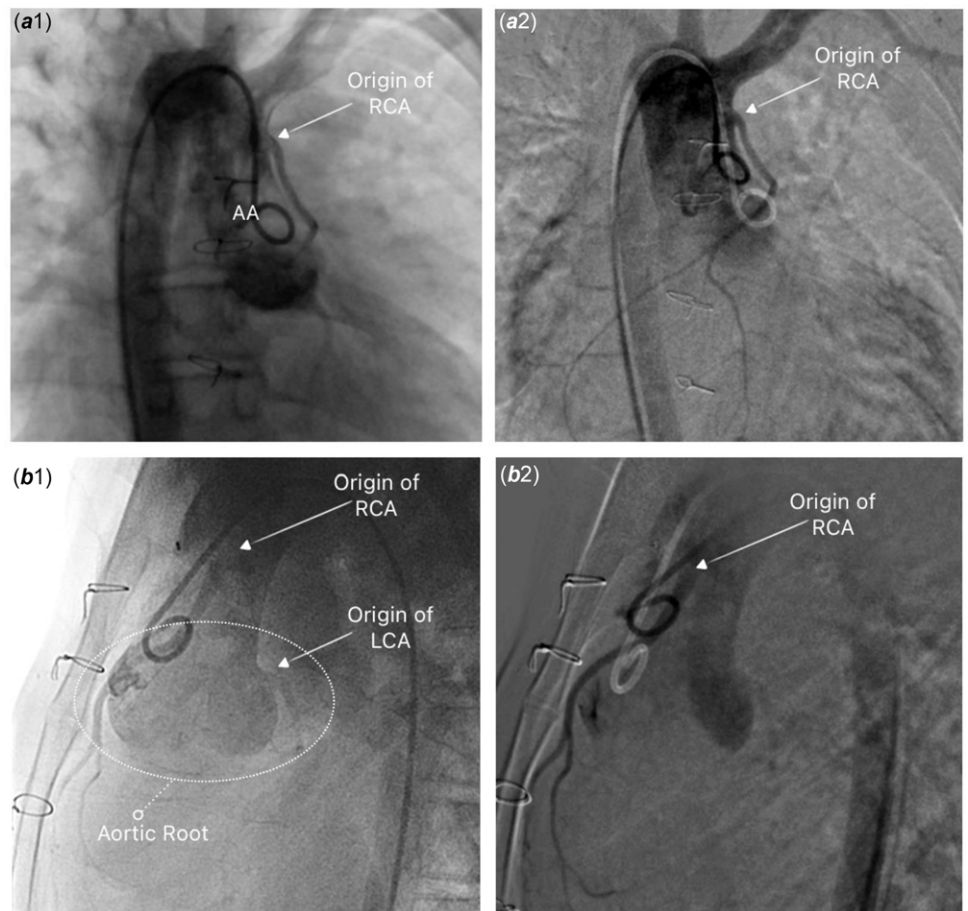


Figure 1. *a*: In the anteroposterior fluoroscopic position, the right coronary artery (RCA) originating from the distal ascending aorta (AA) is seen. *b*: In the lateral fluoroscopic position, aneurysmal dilated aortic root, normal left coronary artery (LCA) origin, and RCA origin from the anterior superior are seen.

The distance of the right coronary artery ostium to the sinotubular junction was measured as 30 mm, and the course of the right coronary artery was seen to be parallel to the ascending aorta.

High take-off coronary artery is a rare anatomic variation, and its frequency is between 0.006% and 0.25% in the healthy population.¹ Clinical findings associated with coronary hypoperfusion may be caused in adult patients. When it is present together with CHDs, such as the one our patient has, it may result in surgical complications. Coronary artery origin anomalies, despite their rarity, should be considered in the management of CHDs.

Supplementary material. The supplementary material for this article can be found at <https://doi.org/10.1017/S1047951124026878>.

Acknowledgements. None.

Author contributions. Musa Ozturk wrote article and critical revision. Hayrettin Hakan Aykan developed concept of publication, critical revision, and approval of article.

Financial support. None.

Competing interests. None.

Ethical standard. Informed consent was obtained from patient and his family to share patient clinical information and imaging photographs anonymously for the scientific purposes.

Reference

1. Loukas M, Andall RG, Khan AZ, et al. The clinical anatomy of high take-off coronary arteries. *Clin Anat* 2016; 29: 408–419.