


Neglected food-borne trematodiasis: echinostomiasis and gastrodiscoidiasis

Rafael Toledo , María Álvarez-Izquierdo, J. Guillermo Esteban and Carla Muñoz-Antoli

Review

Cite this article: Toledo R, Álvarez-Izquierdo M, Esteban JG, Muñoz-Antoli C (2022). Neglected food-borne trematodiasis: echinostomiasis and gastrodiscoidiasis. *Parasitology* 1319–1326. <https://doi.org/10.1017/S0031182022000385>

Received: 2 February 2022
Revised: 10 March 2022
Accepted: 19 March 2022
First published online: 28 March 2022

Key words:

Echinostomatidae; echinostomes; food-borne trematode infections; Gastrodiscidae; *Gastrodiscoides hominis*; intestinal trematodes

Author for correspondence:

Rafael Toledo,
E-mail: rafael.toledo@uv.es

Área de Parasitología, Departamento de Farmacia y Tecnología Farmacéutica y Parasitología, Facultad de Farmacia, Universitat de València, Avda, Vicent Andrés Estellés s/n, 46100 Burjassot, Valencia, Spain

Abstract

In the present paper, we review two of the most neglected intestinal food-borne trematodiasis: echinostomiasis, caused by members of the family Echinostomatidae, and gastrodiscoidiasis produced by the amphistome *Gastrodiscoides hominis*. Both parasitic infections are important intestinal food-borne diseases. Humans become infected after ingestion of raw or insufficiently cooked molluscs, fish, crustaceans, amphibians or aquatic vegetables. Thus, eating habits are essential to determine the distribution of these parasitic diseases and, traditionally, they have been considered as minor diseases confined to low-income areas, mainly in Asia. However, this scenario is changing and the population at risk are currently expanding in relation to factors such as new eating habits in developed countries, growing international markets, improved transportation systems and demographic changes. These aspects determine the necessity of a better understanding of these parasitic diseases. Herein, we review the main features of human echinostomiasis and gastrodiscoidiasis in relation to their biology, epidemiology, immunology, clinical aspects, diagnosis and treatment.

Introduction

Digenea is a class of Trematoda that comprises a large group of organisms with significant medical and veterinary interest. Over 100 species of digenetic trematodes have been reported infecting humans, many of them transmitted through food. Food-borne trematodiasis constitute one of the most neglected tropical diseases group and includes liver flukes, lung flukes and intestinal flukes. Commonly, these parasitic infections have been ignored both in terms of research funding and presence in the public media. More than 40 million people are currently infected and about 10% of the world's population live at risk of infection (Keiser and Utzinger, 2009; Sripa *et al.*, 2010; Toledo *et al.*, 2019). In the past, these infections were limited for the most part in populations living in low-income countries, particularly in southeast Asia, and were associated with poverty. However, the geographical limits and the population at risk are currently expanding and changing in relation to factors such as growing international markets, improved transportation systems and demographic changes.

The present review focuses on two intestinal food-borne trematodiasis of importance: echinostomiasis, caused by members of the family Echinostomatidae, and gastrodiscoidiasis produced by the amphistome *Gastrodiscoides hominis*. These parasitic diseases are associated with practices of eating raw or insufficiently cooked molluscs, fish, crustaceans, amphibians, aquatic plants, promiscuous defecation and the use of human excrements collected from latrines for fertilization of ponds. They are aggravated by socioeconomic factors including poverty, malnutrition, a growing free-food market, a lack of supervised food inspection, poor or insufficient sanitation, other helminthiasis and declining economic conditions. In this context, further studies are urgently needed to clarify the current epidemiology of these helminth infections and to identify new and specific targets for both effective diagnosis and treatments (Graczyk and Fried, 1998; Chai, 2009; Toledo and Esteban, 2016; Toledo *et al.*, 2019).

Herein, we will summarize the main features of the biology, clinical, epidemiology and current diagnostic tools of these food-borne trematode infections and the corresponding diseases they cause.

Echinostomiasis

Echinostomiasis is the parasitic disease caused by echinostomes. Under this term are included the trematodes belonging to the family Echinostomatidae. This family constitutes a heterogeneous group of hermaphroditic digeneans comprising 50 genera and more than 350 species (Yamaguti, 1971; Chai and Jung, 2020). Adult echinostomes commonly inhabit the intestine of a wide range of birds and mammals, including humans. Eventually, some species of echinostomes have been also recorded in reptiles and fishes (Toledo and Esteban, 2016; Toledo *et al.*, 2019). Echinostomes are characterized by the presence of a head collar of spines arranged in one or two circles around the oral sucker. The number and disposition of the spines constitute an important taxonomic feature (Fig. 1). However, systematics of

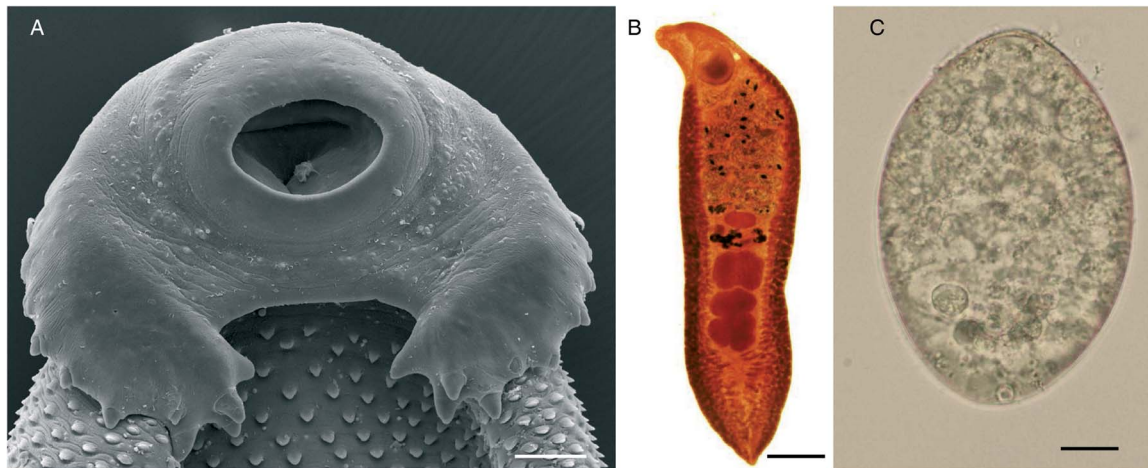


Fig. 1. *Echinostoma* sp.: (A) scanning electron micrographs of the cephalic collar of spines (scale bar: 100 μ m); (B) adult worm (scale bar: 1 mm) and (C) unembryonated egg (scale bar: 10 μ m).

echinostomes is very complex and a subject of continuous reviews and phylogenetic analyses (Chai *et al.*, 2020a; Izrailiskaia *et al.*, 2021; Pham *et al.*, 2022).

Although echinostomes are distributed worldwide, human echinostomiasis mainly occurs at endemic foci in southeast Asia and Far East due to the eating habits of those areas. However, this scenario may be changing due to several factors such as changes in the eating habits in Western countries, internationalization of food markets, migratory flows and the progressive improvement of transportation systems (Graczyk and Fried, 1998; Chai, 2009; Toledo and Esteban, 2016; Toledo *et al.*, 2019).

Morphology and life cycle

Adult worms of the family Echinostomatidae are characterized by the presence of a head collar with collar spines around the oral sucker (Fig. 1A). The number and arrangement of collar spines are important features for taxonomic purposes. Considerable variation exists in size of echinostomes depending upon species, fixation procedures, definitive host and crowding effect and size ranges about 2–10 \times 1–2 mm². The spines of the cephalic collar may be arranged in one or two circles and the number of spines is constant within the species. The tegument contains scale-like spines on both dorsal and ventral surfaces, though the number and size of the spines are reduced in the posterior half of the body. The oral and ventral suckers are close to each other. The two testes, usually in tandem, are posterior to the ovary. The uterus is intercaecal and normally pre-ovarian. The vitellarium is follicular, in two lateral fields, usually in the hindbody but may extend into the forebody (Fig. 1B).

Members of the Echinostomatidae follow a three-host life cycle (Fig. 2). The first intermediate hosts are aquatic snails in which subsequently a single generation of sporocysts, two generations of rediae and, finally, cercariae develop within the second generation of rediae. After emergence of the cercariae in an aquatic environment, they infect the second intermediate host, which may be several species of snails, clams, frogs and even fishes in which cercariae encyst to form the metacercariae. The definitive host becomes infected after eating of the second intermediate host harbouring the encysted metacercariae (Huffman and Fried, 1990; Fried *et al.*, 2004; Toledo *et al.*, 2009).

Strikingly, Miao *et al.* (2021) recently detected an ectopic echinostomiasis. An adult worm of *Echinostoma* sp. was detected in the urinary bladder of a 67-year-old man in Zhejiang (China) by cystoscopy. The patient complained of haematuria and dysuria

but he did not show intestinal symptoms. The authors suggested that the metacercariae could penetrate through the intestinal wall into the urinary bladder, where the parasite attained maturity.

Epidemiology

Human echinostome infections are a common feature since ancient times (Seo *et al.*, 2020). Currently, human echinostomiasis is endemic in southeastern and northeastern Asia. However, the number and identity of the species involved in human infections are difficult to ascertain in relation to: (1) problematical taxonomy of the family that complicates the specific description due to continuous synonymies and misidentifications; (2) a lack of systematic surveys and (3) most of the reports are based on occasional records with uncertain, incomplete or lacking specific identifications, even today. For example, Li *et al.* (2019) detected eggs of an echinostome in the feces of a 42-year-old man from the northern area of China that was simply diagnosed as a member of Echinostomatidae. Similarly, Sah *et al.* (2018) reported the first case of human echinostomiasis in Nepal in a 62-year-old male resident in Gorkha district caused by an unidentified member of the genus *Echinostoma*. Consumption of insufficiently cooked snails and fishes appeared to be the cause of infection. Khanna *et al.* (2019) recorded a single case attributed to an *Echinostoma* species in a 3-year-old male child with severe anaemia in Karnataka (India). In fact, most recent reviews differ in the number of species causing this parasitic disease. Toledo and Esteban (2016) compiled a total of 23 species belonging to 9 different genera of Echinostomatidae. Toledo *et al.* (2019) listed a total of 20 species but, more recently, Chai and Jung (2020) considered 15 major species (having more than 6 reports each) and other 8 species (with fewer than 5 reports). Although these difficulties exist, we have listed a total of 23 species of echinostomes that have been recorded in humans, together with their main features. Table 1 compiles these species, together with the geographical locations of human infections.

Although echinostomes are spread worldwide, the source of infection strongly determines the geographical distribution of human echinostomiasis. Humans become infected after eating raw or undercooked freshwater or brackish water molluscs, fishes, snakes, crustaceans and amphibians (tadpoles or frogs) harbouring the infective metacercariae (Carney, 1991; Toledo *et al.*, 2012, 2019; Toledo and Esteban, 2016; Chai and Jung, 2020). Thus, echinostomiasis mainly occurs in areas where traditional cultural practices encourage ingestion of those types of foods such as Asia,

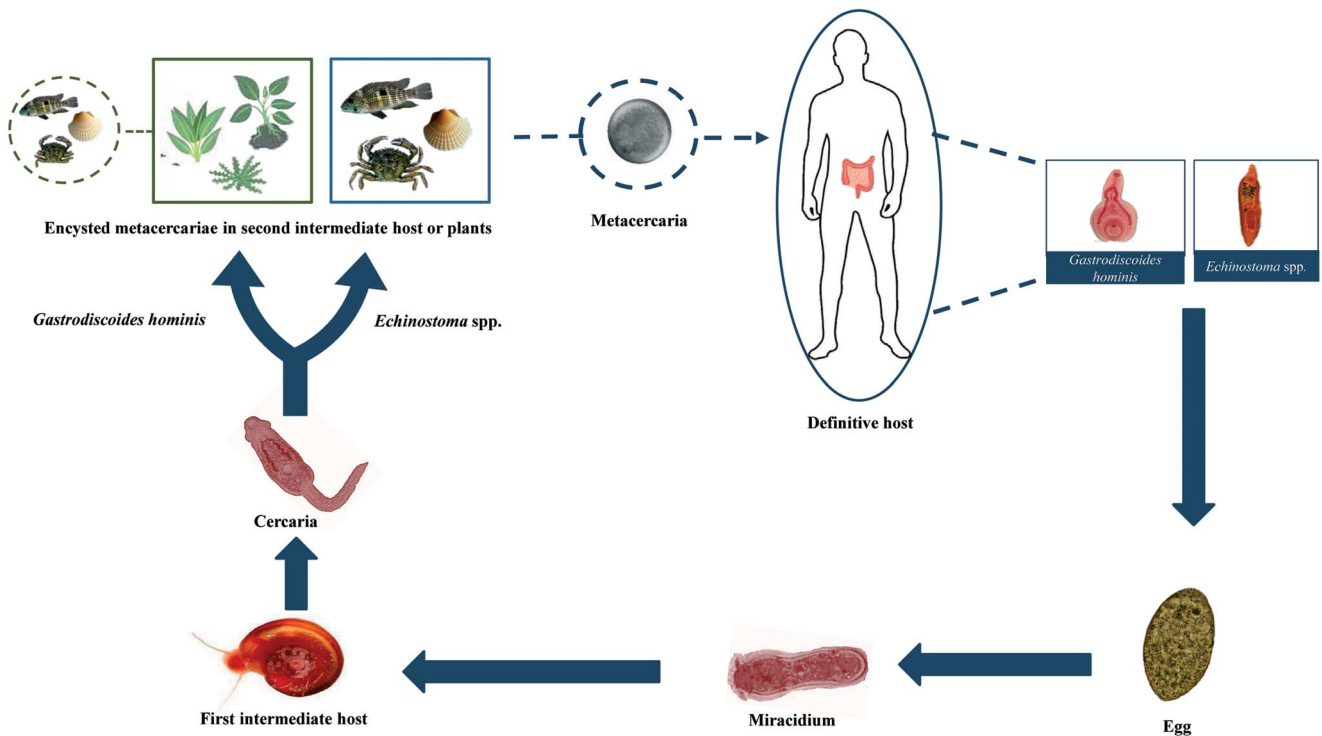


Fig. 2. Generalized life cycle of echinostomes and *Gastrodiscoides hominis*: adult worms inhabit the small intestine of several vertebrate hosts, including humans; eggs are voided with host feces and miracidia hatch in freshwater and actively infect the snail first intermediate host; cercariae are released by the first intermediate host and swim to locate the second intermediate host (snails, amphibians, bivalves and fishes) which they penetrate in the case of echinostomes and on aquatic plants or, alternatively, aquatic animals in the case of *G. hominis*; cercariae become metacercariae after encystation; metacercariae are ingested by the definitive host and excyst to become adults.

mainly in southeastern and northeastern Asia. Commonly, echinostomiasis is highly focal and most of the cases have been reported in China, India, Indonesia, Korea, Malaysia, the Philippines, Russia, Taiwan and Thailand (Chai, 2009; Toledo and Esteban, 2016). Occasional cases have also been reported in other countries (see Table 1).

The current incidence of human echinostomiasis is not known. Most of the available information is based on sporadic reports with scarce information and, in many cases, lacking specific identification as mentioned above. Moreover, microscopists may misinterpret echinostome eggs, particularly considering that eggs of different echinostome species markedly resemble making difficult specific diagnosis (Esteban *et al.*, 2019; Chai *et al.*, 2020b). The only estimate available is the one made by WHO (2004) for *Echinostoma hortense* (currently synonym of *Isthmiophora hortensis*) (50 000 people infected), *Echinochasmus japonicus* (about 5000 cases) and *Echinostoma cinetorchis* and *Acanthoparyphium tyosenense* (with about 1000 cases each). This evidences the need for systematic epidemiological surveys, especially in areas where consumption of raw or undercooked intermediate hosts of echinostomes is a common habit.

As mentioned above, most of the cases of human echinostomiasis have been reported in Asia and commonly appear as endemic foci in areas where the presence of intermediate host and the natural definitive hosts (mainly waterfowls) coexist with the human practice of eating undercooked intermediate hosts (Toledo and Esteban, 2016). Exceptionally, drinking of contaminated water harbouring metacercariae may be the source of infection (Xiao *et al.*, 1995). There are no data on the seasonality of the transmission, but it cannot be discarded as those that occurred with other trematodes (Kopolrat *et al.*, 2020).

The highest number of echinostome species has been reported in China. A total of 13 species has been recorded in this country, especially in provinces of southeast China such as Fujian,

Guangdong, Liaoning, Anhui, Yunnan and Hubei (Toledo *et al.*, 2019). *Echinochasmus liliputanus* was the first species discovered in humans from China. A prevalence of 13.4% was reported in Anhui in 1991 (Yu and Mott, 1994) and, therefore, more than 2500 human infections have been recorded in this province (Xiao *et al.*, 2005). In Fujian province, *Echinochasmus fujianensis* appears to be the most common species attaining a prevalence of 1.6–7.8% among residents of 5 areas, children from 3 to 15-year-old being the most affected population segment with about two-thirds of all cases (Yu and Mott, 1994). In some counties of Guangdong and Fujian, *E. japonicus* is a common human infection with prevalences of 4.9%, whereas *Echinochasmus perfoliatus* has been usually reported attaining prevalences of 1.8% (Yu and Mott, 1994). Human infections with other echinostome species in China are more anecdotal. *Echinostoma revolutum* has been found in Yunnan and Guangdong provinces and 6 patients who had eaten raw loach were found to be infected with *I. hortensis* in Liaoning province (Chen *et al.*, 1993). Moreover, a single case of infection with *Echinochasmus jiufoensis* was detected during the autopsy of a 6-month-old girl in Guangzhou (Liang and Ke, 1988).

A total of five species has been reported in humans from Indonesia, mainly in the major islands (Sumatra, Java and Sulawesi). Infections were related to the local habit of eating raw bivalves (*Corbicula* spp.) from lakes. An average prevalence of 43%, but attaining 96%, of *Echinostoma lindoense* was reported from 1937 to 1956 in residents in the lake Lindu Valley (Sulawesi) (Carney *et al.*, 1980). Moreover, in the area of Borneo the finding of echinostome eggs in stool specimens of residents was common (Cross and Basaca-Sevilla, 1986). The popularity of Korean and Japanese restaurants in Indonesia led to an increase in the number of cases (Kusharyono and Sukartinah, 1991).

In Lao PDR, Eom *et al.* (2014) estimated a prevalence of 0.7%. A total of 6 species of echinostomes has been found

Table 1. Species of Echinostomatidae involved in human infections and geographical location of cases (only those reports with specific description have been considered)

<i>Acanthoparyphium tyosenense</i>	Korea
<i>Artyfechinostomum malayanum</i> ^a	Cambodia, India, Indonesia, Lao PDR, Malaysia, Philippines, Singapore, Thailand
<i>Artyfechinostomum oraoni</i>	India
<i>Artyfechinostomum sufrartyfex</i>	India
<i>Echinochasmus caninus</i> ^b	Thailand
<i>Echinochasmus fujianensis</i>	China
<i>Echinochasmus japonicus</i>	China, Korea, Japan ^c , Lao PDR
<i>Echinochasmus jiufuensis</i>	China
<i>Echinochasmus liliputanus</i>	China
<i>Echinochasmus perfoliatus</i>	China, Japan, Korea
<i>Echinoparyphium recurvatum</i>	Egypt, Indonesia, Korea, Taiwan
<i>Echinostoma aegyptica</i>	China
<i>Echinostoma angustitestis</i>	China
<i>Echinostoma cinetorchis</i>	China, Japan, Korea, Taiwan
<i>Echinostoma ilocanum</i>	Cambodia, China, India, Indonesia, Malaysia, Philippines, Thailand
<i>Echinostoma lindoense</i> ^d	Indonesia, Lao PDR
<i>Echinostoma macrorchis</i>	Japan, Korea, Lao PDR
<i>Echinostoma mekongi</i>	Cambodia
<i>Echinostoma revolutum</i>	Cambodia, China, Egypt, Indonesia, Lao PDR, Russia, Europe
<i>Himasthla muehlensi</i>	USA ^e
<i>Hypoderaeum conoideum</i>	Thailand
<i>Isthmiophora hortensis</i> ^f	China, Japan, Korea
<i>Isthmiophora melis</i>	China, Romania, Taiwan

^aSyn. *Echinostoma malayanum*.

^bSyn. *Episthmium caninum*.

^cExperimental infection.

^dSyn *Echinostoma echinatum*.

^eImported infection.

^fSyn. *Echinostoma hortense*.

infecting humans, with special incidence in Riparian villages along the Mekong river. In Khammouane province, a prevalence of 1.1% of echinostome eggs belonging to *E. revolutum*, *Artyfechinostomum malayanum*, *E. japonicus* and *Echinoparyphium recurvatum* was detected in the feces of residents (Chai et al., 2012). Moreover, Sayasone et al. (2009) detected three human cases of *E. japonicus*. *Echinochasmus caninus* has been recently recorded for the first time in Lao PDR infecting humans. Cases of *E. japonicus* were associated with eating raw or insufficiently cooked freshwater fish in a traditional food locally known as 'lap-pa', 'Koi-pa' or 'som-pa'. A total of 11 cases in Riparian people was detected in Khammouane (Chai et al., 2019). All the patients were co-infected other intestinal helminths. In Savannakhet province, Sayasone et al. (2009) detected three cases. Recently, several cases have been additionally reported in this province. Chai et al. (2018) recorded the first human case of *Echinostoma ilocanum* in Lao PDR and, moreover, *Echinostoma aegyptica* was found in five Riparian people for the first time in this country (Chai et al., 2020b). In southern Lao PDR, a prevalence of 6% was estimated by Sayasone et al. (2011).

Several species of echinostomes have been discovered infecting humans in Cambodia (Table 1). A prevalence of 1% of *E. ilocanum* was estimated in the Oddar Meanchey province (Sohn et al., 2011a) and of 7.5–22.4% of *E. revolutum* in schoolchildren from the Pursat province causing gastrointestinal symptoms (Chai et al., 2009, 2018; Sohn et al., 2011b). The source of infection appeared to be the eating of undercooked snails or clams sold on the way back home from school (Sohn et al., 2011b). Recently, a new species (*Echinostoma mekongi*) has been described on the basis of adult flukes collected from Riparian people residing along the Mekong river. Parasites were detected in six Riparian people from the localities of Kratie and Takeo (Cho et al., 2020).

In Taiwan, three species of echinostomes have been recorded with a prevalence ranging from 0.11 to 0.65% in some areas (Lu, 1982; Carney, 1991). A total of four species has been found in Thailand, seven species in Korea, four different species in India and two in the Philippines (Table 1). However, most of these cases were occasional.

Human echinostomiasis is very uncommon outside Asia. Moreover, most of these cases were imported, occurring mainly in Asian refugees or tourists to Africa (DeGirolami and Kimber, 1983; Poland et al., 1985; Chai, 2007; Chungue and Chungue, 2017).

Immunology

Little is known about the immunology of human echinostomiasis. Most of the current knowledge on immunology of echinostome infections is based on experimental studies in laboratory rodents. Echinostomes induce strong antibody responses both at systemic and mucosal levels (Graczyk and Fried, 1994; Cho et al., 2007; Sotillo et al., 2007, 2014). However, this response markedly depends on the host species. At the serum level, energetic immunoglobulin M (IgM), total IgG, IgG1 and IgG3 have been observed in mice infected with *Echinostoma caproni*, but, in contrast, only weak responses were observed in rats (Sotillo et al., 2007). In *I. hortensis*-infected mice an elevation of IgG1, IgE and IgA was detected (Cho et al., 2007). At the mucosal level, intense responses of IgM, IgA, IgG1 and IgG2a were reported in *E. caproni*-infected mice and only elevated levels of IgG2a were observed in rats (Sotillo et al., 2007). A total of four proteins (enolase, aldolase, actin and the 70 kDa heat-shock protein) was found to be the most immunogenic antigens (Sotillo et al., 2007). Moreover, the glycosylation of parasite antigens appears to be essential for antibody responses, suggesting that T-independent responses are of great importance (Sotillo et al., 2014). Strikingly, it has been shown that echinostomes are able to trap and degrade antibodies bound to their surface by secreted cathepsin L-like peptidases (Cortés et al., 2017a, 2019).

Resistance to echinostome infections has been traditionally associated with the development of Th2 responses, mainly mediated by interleukin 4 (IL-4) and/or IL-13 (Brunet et al., 2000; Toledo and Fried, 2005; Sotillo et al., 2011; Cortés et al., 2017b; Toledo et al., 2019). However, recent studies suggest that resistance depends on the ability of the host to maintain the mucosal homeostasis in a process mediated by IL-25 (Muñoz-Antoli et al., 2016; Álvarez-Izquierdo et al., 2020a, 2020b). Resistance is associated with hyperplasia of local tuft cells and production of IL-25 which operates by facilitating the maintenance of the epithelial homeostasis that could be ultimately responsible for parasite rejection (Muñoz-Antoli et al., 2016; Cortés et al., 2017b; Álvarez-Izquierdo et al., 2020a, 2020b).

Echinostoma spp. also induces changes at the cellular level and in the expression of certain glycoconjugates in the intestinal mucosa (Toledo et al., 2006a). Mastocytosis, eosinophilic infiltration and increase in the goblet cells and mast cell populations

have been observed (Fujino *et al.*, 1993, 1996a, 1996b; Fujino and Fried, 1993, 1996; Kim *et al.*, 2000; Park *et al.*, 2005; Toledo *et al.*, 2006b; Muñoz-Antoli *et al.*, 2007; Ryang *et al.*, 2007). Moreover, alterations of the terminal sugar of the mucins produced by goblet cells may regulate the worm expulsion (Fujino and Fried, 1993, 1996; Park *et al.*, 2005).

Clinical manifestations

In heavy infections, echinostomes may cause more severe symptoms than other intestinal trematodes. Commonly, major clinical symptoms of human echinostomiasis may include unspecific symptoms such as diarrhoea, loss of body weight, epigastric and abdominal pain or easy fatigue. However, additional symptoms may include local eosinophilia, anaemia, oedema and anorexia (Graczyk and Fried, 1998; Toledo *et al.*, 2006a, 2019; Toledo and Esteban, 2016). Recently, severe anaemia has been associated with echinostomiasis in a 3-year-old male child concomitantly infected with *Echinostoma* sp., *Trichuris trichiura* and *Ascaris lumbricoides* in India (Khanna *et al.*, 2019). In *I. hortensis*-infected patients, nausea and vomiting, headache, acid belching and urinary incontinence were observed (Chang *et al.*, 2005). Mucosal damage may include signs of chronic gastritis, infiltration of inflammatory cells, mucosal erosion and bleeding and lesions similar to adenocarcinoma (Chang *et al.*, 2005).

In ectopic locations such as the urinary bladder, infection was characterized by haematuria with 305 red blood cells per μL (normal 0–13), 297 white blood cells per μL (normal 0–9) and a positive result of 2+ for occult blood in the urine. Moreover, haematuria was accompanied by urgency and dysuria (Miao *et al.*, 2021).

Diagnosis and treatment

Laboratory diagnosis of echinostomiasis is based on the finding of eggs in feces. The eggs are yellow-brown and thin-shelled with an operculum, and a slight thickening of the shell at the abopercular end. They are unembryonated when passed in feces. The size of human-infecting echinostome eggs ranges 66–145 $\mu\text{m} \times 43$ –90 μm (Esteban *et al.*, 2019). However, differentiation of echinostome species, and even from other trematodes, on the basis of the egg morphology is difficult and recovery and identification of adult worms if possible is recommended. The similarity among the eggs of other trematodes must be taken into account to avoid confusion, especially with those that are carcinogenic such as *Opisthorchis viverrini* (Crellen *et al.*, 2021). Occasionally, human echinostomiasis has been revealed by gastroduodenal endoscopy performed in relation to severe epigastric symptoms and ulcerative lesions in the stomach and duodenum (Lee and Hong, 2002; Cho *et al.*, 2003; Park and Kim, 2006; Jung *et al.*, 2014).

Praziquantel is the drug of choice for intestinal fluke infections although it is not included in the US product labelling for these infections. A single dose of 25 mg kg^{-1} of praziquantel is recommended for treatment of intestinal fluke infections. Echinostome infections can be treated successfully with slightly lower – single, oral 10–20 mg kg^{-1} praziquantel (Chai *et al.*, 2009). Praziquantel is 90% absorbed after ingestion and then rapidly metabolized in the liver and the hydroxylated and conjugated products are excreted mainly in the urine within 24 h. Side-effects are minimal and include abdominal pain, nausea, headache and dizziness (WHO, 1995).

Gastrodiscoidiasis

Gastrodiscoidiasis is a plant-borne parasitic disease caused by the intestinal amphistome *G. hominis*. Adult worms are pyramidal in

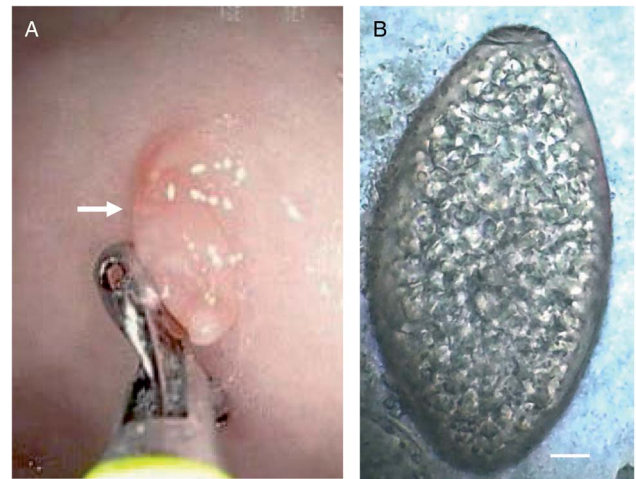


Fig. 3. *Gastrodiscoides hominis*: (A) image of an upper endoscopy showing a juvenile living adult worm fixed in the mucosa of a human patient (arrow) and (B) egg isolated from the stools of a human patient (scale bar: 10 μm). Photomicrographs: courtesy of Dr Ranjit Sah.

shape and measure 8–14 \times 5.5–7.5 mm^2 (Mas-Coma *et al.*, 2005, 2006). Morphologically, they are characterized by a dorsoventrally flattened body with an anterior part short and cylindrical and the posterior portion larger and discoidal. The most characteristic features of *G. hominis* include a subterminal pharynx, tandem, lobed testes, a post-testicular ovary, an ascending uterus and a ventral genital pore (Mas-Coma *et al.*, 2005, 2006).

Life cycle

Life cycle of *G. hominis* is not well known (Fig. 2). Adult flukes inhabit the caecum and colon of several mammals, where it remains attached to the mucosa (Fig. 3A). Pigs appear to be the normal definitive host (Dutt and Srivastava, 1972), but it also has been reported in monkeys, mice, rats, wild boars, muskrats and humans (Easwaran *et al.*, 2003; Mas-Coma *et al.*, 2005, 2006). Unembryonated eggs (Fig. 3B) are laid in freshwater environments and a miracidium hatches and swims to infect the first intermediate host. Only the aquatic snail *Helicorbis coenosus* is known to act as the first intermediate host (Mas-Coma *et al.*, 2006; Toledo *et al.*, 2019). After the development of daughter and mother rediae, cercariae emerge and swim in the freshwater to reach aquatic plants, where they encyst as metacercariae. Metacercarial encystment can also occur in snails, tadpoles, frogs and crayfishes. Definitive host becomes infected when encysted metacercariae are swallowed with tainted vegetation or with animal products, such as raw or undercooked crustaceans, molluscs or amphibians (Fried *et al.*, 2004; Mas-Coma *et al.*, 2005, 2006; Toledo *et al.*, 2019).

Epidemiology

First cases of human gastrodiscoidiasis were reported in India. Thereafter, human cases have been found in Burma, Nepal, Pakistan, Myanmar, Vietnam, the Philippines, Thailand, China, Kazakhstan, Indian immigrants in Guyana, Zambia, Nigeria and the Volga Delta in Russia (Yu and Mott, 1994; Mas-Coma *et al.*, 2005; Sah *et al.*, 2019; Toledo *et al.*, 2019). Although *G. hominis* is not a common parasite of humans, high prevalences have been found in some areas, especially in India. Buckley (1939) reported a prevalence of 41% in children from Assam and a prevalence of 27% was recorded in people from Bareilly (Dutt and Srivastava, 1972).

Most of the cases appear to be related to the consumption of tainted vegetables directly collected from ponds and rivers, which is a common practice in some Asian countries (Sah *et al.*, 2019) or even of vegetables bought in local markets. Uzairue *et al.* (2013) analysed a total of 250 samples of 7 different vegetables in markets from Ekpoma (Nigeria) and detected that 0.9% of cabbage samples were contaminated with metacercariae of *G. hominis*. Moreover, infection with metacercariae encysted in animal products, such as raw or undercooked crustaceans, molluscs or amphibians also may occur (Fried *et al.*, 2004).

Clinical symptoms, diagnosis and treatment

Human gastrodiscoidiasis is commonly asymptomatic. In heavy infections, epigastric pain, abdominal discomfort, diarrhoea and headache may occur (Toledo *et al.*, 2019). Moreover, other symptoms including lymphadenopathy, hepatosplenomegaly or anaemia have been reported in individual patients (Dada-Adegbola *et al.*, 2004; Sah *et al.*, 2019). At the local level, inflammation at the site of attachment due to dragging with the acetabulum, surface desquamation, infiltration with eosinophils, lymphocytes and plasma cells appears in the lesions caused by the fixation of the parasites to the mucosa. Hypersecretion of mucus and necrosis of the mucous glands are also observed (Mas-Coma *et al.*, 2005, 2006).

Diagnosis of human gastrodiscoidiasis is performed by detection of eggs in feces. The egg is operculated, non-embryonated and measuring about $150 \times 70 \text{ mm}^2$ (Fig. 3B) (Mas-Coma *et al.*, 2005, 2006; Esteban *et al.*, 2019; Toledo *et al.*, 2019). Praziquantel is the drug of choice. However, a single dose of 500 mg mebendazole also may be efficient (Dada-Adegbola *et al.*, 2004; Mas-Coma *et al.*, 2005).

Concluding remarks

Human echinostomiasis and gastrodiscoidiasis are among the most neglected intestinal trematode infections. Both parasite infections have been considered as minor diseases mainly confined to some areas of Asia. However, the real prevalence of these infections is not known, which makes necessary further efforts and systematic helminthological surveys to determine the real impact on human health. This is of particular importance considering that several factors such as growing international markets, new eating habits in developed countries or demographic changes may be expanding their risk of infection and prevalence in areas where these diseases were not known. Thus, further studies are required to elaborate new maps of risk and a more detailed follow-up may be useful to gain a better understanding of the current incidence of these diseases.

Financial support. Research at Universitat de València was supported by Ministerio de Sanidad y Consumo (Madrid, Spain) (No. RD12/0018/0013, Red de Investigación Cooperativa en Enfermedades Tropicales – RICET, IV National Program of I+D+I 2008–2011, ISCIII–Subdirección General de Redes y Centros de Investigación Cooperativa and FEDER).

Conflict of interest. The authors declare none.

References

Álvarez-Izquierdo M, Pérez-Crespo M, Esteban JG, Muñoz-Antoli C and Toledo R (2020a) Interleukin-25-mediated resistance against intestinal trematodes does not depend on the generation of Th2 responses. *Parasites & Vectors* **13**, 608.

Álvarez-Izquierdo M, Esteban JG, Muñoz-Antoli C and Toledo R (2020b) Ileal proteomic changes associated with IL-25-mediated resistance against intestinal trematode infections. *Parasites & Vectors* **13**, 336.

Brunet LR, Joseph S, Dunne DW and Fried B (2000) Immune responses during the acute stages of infection with the intestinal trematode *Echinostoma caproni*. *Parasitology* **120**, 565–571.

Buckley JJC (1939) Observations on *Gastrodiscoides hominis* and *Fasciolopsis* in Assam. *Journal of Helminthology* **17**, 1–12.

Carney WP (1991) Echinostomiasis – a snail-borne intestinal disease. *Southeast Asian Journal of Tropical Medicine and Public Health* **22**, 206–211.

Carney WP, Sudomo M and Purnomo A (1980) Echinostomiasis: a disease that disappeared. *Tropical and Geographical Medicine* **32**, 101–105.

Chai JY (2007) Intestinal flukes. In Murrell KD and Fried B (eds) *Food-Borne Parasitic Zoonoses: Fish and Plant-Borne Parasites, World Class Parasites*. New York, USA: Springer, pp. 53–115.

Chai JY (2009) Echinostomes in humans. In Fried B and Toledo R (eds) *The Biology of Echinostomes. From the Molecule to the Community*. New York, USA: Springer, pp. 147–183.

Chai JY and Jung BK (2020) Foodborne intestinal flukes: a brief review of epidemiology and geographical distribution. *Acta Tropica* **201**, 105210.

Chai JY, Shin EH, Lee SH and Rim HJ (2009) Foodborne intestinal flukes in southeast Asia. *Korean Journal of Parasitology* **47**(Suppl.), S69–S102.

Chai JY, Sohn WM, Yong TS, Eom KS, Min DY, Hoang EH, Phammasack B, Insiengmay B and Rim HJ (2012) Echinostome flukes recovered from humans in Khammouane province, Lao PDR. *Korean Journal of Parasitology* **50**, 269–272.

Chai JY, Sohn WM, Cho J, Eom KS, Yong TS, Min DY, Hoang EH, Phommasack B, Insiengmay B and Rim HJ (2018) *Echinostoma ilocanum* infection in two residents of Savannakhet province, Lao PDR. *Korean Journal of Parasitology* **56**, 75–79.

Chai JY, Chang T, Jung BK, Shin H, Sohn WM, Eom KS, Yong TS, Min DY, Phammasack B, Insiengmay B and Rim HJ (2019) *Echinochasmus caninus* n. comb. (Trematoda: Echinostomatidae) infection in eleven Riparian people in Khammouane province, Lao PDR. *Korean Journal of Parasitology* **57**, 451–456.

Chai JY, Cho J, Chang T, Jung BK and Sohn WM (2020a) Taxonomy of *Echinostoma revolutum* and 37-collar-spined *Echinostoma* spp.: a historical review. *Korean Journal of Parasitology* **58**, 343–371.

Chai JY, Jung BK, Chang T, Shin H, Sohn WM, Eom KS, Yong TS, Min DY, Phammasack B, Insiengmay B and Rim HJ (2020b) *Echinostoma aegyptica* (Trematoda: Echinostomatidae) infection in five Riparian people in Savannakhet province, Lao PDR. *Korean Journal of Parasitology* **58**, 67–72.

Chang YD, Sohn WM, Ryu JH, Kang SY and Hong SJ (2005) A human infection of *Echinostoma hortense* in duodenal bulb diagnosed by endoscopy. *Korean Journal of Parasitology* **43**, 57–60.

Chen XQ, Feng GX and Qian ZF (1993) Survey on infection due to *Echinostoma hortense* in Liaoning province. *Chinese Journal of Parasitology and Parasitic Diseases* **11**, 226.

Cho CM, Tak WY, Kweon YO, Kim SK, Choi YH, Kong HH and Chung DI (2003) A human case of *Echinostoma hortense* (Trematoda: Echinostomatidae) infection diagnosed by gastroduodenal endoscopy in Korea. *Korean Journal of Parasitology* **41**, 117–120.

Cho J, Jung BK, Chang T, Sohn WM, Sinuon M and Chai JY (2020) *Echinostoma mekongi* n. sp. (Digenea: Echinostomatidae) from Riparian people along the Mekong river in Cambodia. *Korean Journal of Parasitology* **58**, 431–443.

Cho YK, Ryang YS, Kim IS, Park SK, Im JA and Lee KJ (2007) Differential immune profiles following experimental *Echinostoma hortense* infection in BALB/c and C3H/HeN mice. *Parasitology Research* **100**, 1053–1061.

Chunge RN and Chunge CN (2017) Infection with *Echinostoma* sp. in a group of travellers to lake Tanganyika, Tanzania, in January 2017. *Journal of Travel Medicine* **24**, 5.

Cortés A, Sotillo J, Muñoz-Antoli C, Molina-Durán J, Esteban JG and Toledo R (2017a) Antibody trapping: a novel mechanism of parasite immune evasion by the trematode *Echinostoma caproni*. *PLoS Neglected Tropical Diseases* **11**, e0005773.

Cortés A, Muñoz-Antoli C, Esteban JG and Toledo R (2017b) Th2 and Th1 responses: clear and hidden sides of immunity against intestinal helminths. *Trends in Parasitology* **33**, 678–693.

Cortés A, Mikeš L, Muñoz-Antoli C, Álvarez-Izquierdo M, Esteban JG, Horák P and Toledo R (2019) Secreted cathepsin L-like peptidases are involved in the degradation of trapped antibodies on the surface of *Echinostoma caproni*. *Parasitology Research* **118**, 3377–3386.

Crellen T, Sithithaworn P, Pitaksakulrat O, Khuntikeo N, Medley GF and Hollingsworth TD (2021) Towards evidence-based control of *Opisthorchis viverrini*. *Trends in Parasitology* **37**, 370–380.

- Cross JH and Basaca-Sevilla V** (1986) Studies on *Echinostoma ilocanum* in the Philippines. *Southeast Asian Journal of Tropical Medicine and Public Health* **17**, 23–26.
- Dada-Adegbola HO, Falade CO, Oluwatoba OA and Abiodun OO** (2004) *Gastrodiscoides hominis* infection in a Nigerian – case report. *West African Journal of Medicine* **23**, 185–186.
- DeGirolami PC and Kimber J** (1983) Intestinal parasites among southeast Asian refugees in Massachusetts. *American Journal of Clinical Pathology* **79**, 502–504.
- Dutt SC and Srivastava HD** (1972) The life history of *Gastrodiscoides hominis* (Lewis and McConnel, 1876) Leiper, 1913, the amphistome parasite of man and pig. *Journal of Helminthology* **46**, 35–46.
- Easwaran KR, Reghu R and Pillai KM** (2003) Parasitic infection of some wild animals at Thekkady in Kerala. *Zoos' Print Journal* **18**, 1030.
- Eom KS, Yong TS, Sohn WM, Chai JY, Min DY, Rim HJ, Jeon HK, Banoung V, Insiengmay B and Phommassack B** (2014) Prevalence of helminthic infections among inhabitants of Lao PDR. *Korean Journal of Parasitology* **52**, 51–56.
- Esteban JG, Muñoz-Antoli C, Toledo R and Ash LR** (2019) Diagnosis of human trematode infections. *Advances in Experimental Medicine and Biology* **1154**, 437–471.
- Fried B, Graczyk TK and Tamang L** (2004) Food-borne intestinal trematodiasis in humans. *Parasitology Research* **93**, 159–170.
- Fujino T and Fried B** (1993) Expulsion of *Echinostoma trivolvis* (Cort, 1914) Kanev, 1985 and retention of *E. caproni* Richard, 1964 (Trematoda, Echinostomatidae) in C3H mice: pathological, ultrastructural, and cytochemical effects on the host intestine. *Parasitology Research* **79**, 286–292.
- Fujino T and Fried B** (1996) The expulsion of *Echinostoma trivolvis* from C3H mice: differences in glycoconjugates in mouse versus hamster small intestinal mucosa during infection. *Journal of Helminthology* **70**, 115–121.
- Fujino T, Fried B and Tada I** (1993) The expulsion of *Echinostoma trivolvis*: worm kinetics and intestinal cytopathology in conventional and congenitally athymic BALB/c mice. *Parasitology* **106**, 297–304.
- Fujino T, Fried B, Ichikawa H and Tada I** (1996a) Rapid expulsion of the intestinal trematodes *Echinostoma trivolvis* and *E. caproni* from C3H mice by trapping with increased goblet cell mucins. *International Journal for Parasitology* **26**, 319–324.
- Fujino T, Fried B, Ichikawa H and Tada I** (1996b) The expulsion of *Echinostoma trivolvis*: suppressive effects of dexamethasone on goblet cell hyperplasia and worm rejection in C3H/HeN mice. *Parasite* **3**, 283–289.
- Graczyk TK and Fried B** (1994) ELISA method for detecting anti-*Echinostoma caproni* (Trematoda: Echinostomatidae) immunoglobulins in experimentally infected ICR mice. *Journal of Parasitology* **80**, 544–549.
- Graczyk TK and Fried B** (1998) Echinostomiasis: a common but forgotten food-borne disease. *American Journal of Tropical Medicine and Hygiene* **58**, 501–504.
- Huffman JE and Fried B** (1990) *Echinostoma* and echinostomiasis. *Advances in Parasitology* **29**, 215–269.
- Izrailiskaia AV, Besprozvannykh VV and Tatonova YV** (2021) *Echinostoma chankensis* nom. nov., other *Echinostoma* spp. and *Isthmiophora hortensis* in East Asia: morphology, molecular data and phylogeny within Echinostomatidae. *Parasitology* **148**, 1366–1382.
- Jung WT, Lee KJ, Kim HJ, Kim TH, Na BK and Sohn WM** (2014) A case of *Echinostoma cinetorchis* (Trematoda: Echinostomatidae) infection diagnosed by colonoscopy. *Korean Journal of Parasitology* **52**, 287–290.
- Keiser J and Utzinger J** (2009) Food-borne trematodiasis. *Clinical Microbiology Reviews* **22**, 466–483.
- Khanna V, Ashraf AA and Khanna R** (2019) Echinostomiasis in a child with severe anemia. *Tropical Parasitology* **9**, 54–56.
- Kim I, Im JA, Lee KJ and Ryang YS** (2000) Mucosal mast cell responses in the small intestine of rats infected with *Echinostoma hortense*. *Korean Journal of Parasitology* **38**, 139–143.
- Kopolrat K, Sithithaworn P, Kiatsopit N, Namsanor J, Laoprom N, Tesana S, Andrews RH and Petney TN** (2020) Influence of water irrigation schemes and seasonality on transmission dynamics of *Opisthorchis viverrini* in the snail intermediate host, *Bithynia siamensis goniomphalos* in rice paddy fields in Northeast Thailand. *American Journal of Tropical Medicine and Hygiene* **103**, 276–286.
- Kusharyono C and Sukartinah S** (1991) The current status of foodborne parasitic zoonoses in Indonesia. *Southeast Asian Journal of Tropical Medicine and Public Health* **22**, 8–10.
- Lee OJ and Hong SJ** (2002) Gastric echinostomiasis diagnosed by endoscopy. *Gastrointestinal Endoscopy* **55**, 440–442.
- Li L, Liu X, Zhou B, Zhang S, Wang G, Ma G, Chen R, Zou Y, Cao W and Li T** (2019) Multiple food-borne trematodiasis with profound systemic involvement: a case report and literature review. *BMC Infectious Diseases* **19**, 526.
- Liang C and Ke XL** (1988) *Echinochasmus jiufuensis* sp. nov., a human parasite from Guangzhou (Trematoda: Echinostomatidae). *Acta Zootaxonomica Sinica* **13**, 4–8.
- Lu SC** (1982) Echinostomiasis in Taiwan. *International Journal of Zoonoses* **9**, 33–38.
- Mas-Coma S, Bargues MD and Valero MA** (2005) Fascioliasis and other plant-borne trematode zoonoses. *International Journal for Parasitology* **35**, 1255–1278.
- Mas-Coma S, Bargues MD and Valero MA** (2006) Gastrodiscoidiasis, a plant-borne zoonotic disease caused by the intestinal amphistome fluke *Gastrodiscoides hominis* (Trematoda: Gastrodiscidae). *Revista Ibérica de Parasitología* **66**, 75–81.
- Miao F, Dong C, Zhou C and Zhou H** (2021) First case of human echinostomiasis in the urinary bladder. *Journal of Travel Medicine* **28**, 1–2.
- Muñoz-Antoli C, Sotillo J, Monteagudo C, Fried B, Marcilla A and Toledo R** (2007) Development and pathology of *Echinostoma caproni* in experimentally infected mice. *Journal of Parasitology* **93**, 854–859.
- Muñoz-Antoli C, Cortés A, Santano R, Sotillo J, Esteban JG and Toledo R** (2016) Interleukin-25 induces resistance against intestinal trematodes. *Scientific Reports* **6**, 34142.
- Park CJ and Kim J** (2006) A human case of *Echinostoma hortense* infection diagnosed by endoscopy in area of southwestern Korea. *Korean Journal of Internal Medicine* **71**, 229–234.
- Park KY, Lee KJ and Kim IS** (2005) Reaction of mast cells and goblet cells in the small intestine of C57BL/6 and C3H/HeN mice infected with *Echinostoma hortense*. *Korean Journal of Biomedical Laboratory Science* **11**, 259–266.
- Pham LTK, Sajuntha W, Lawton SP and Le TH** (2022) Mitophylogenomics of the zoonotic fluke *Echinostoma malayanum* confirms it as a member of the genus *Artyfechinostomum* Lane, 1915 and illustrates the complexity of Echinostomatidae systematics. *Parasitology Research* **121**, 899–913.
- Poland GA, Navin TR and Sarosi GA** (1985) Outbreak of parasitic gastroenteritis among travelers returning from Africa. *Archives of Internal Medicine* **145**, 2220–2221.
- Ryang YS, Yang EJ, Kim JL, Lee KJ, Sung HJ, Kim JB and Kim IS** (2007) Immune response and inhibitory effect of ketotifen on the BALB/c and C3H/HeN mice infected with *Echinostoma hortense*. *Parasitology Research* **101**, 1103–1110.
- Sah R, Khadka S, Hamal R and Poudyal S** (2018) Human echinostomiasis: a case report. *BMC Research Notes* **11**, 17.
- Sah R, Acosta L and Toledo R** (2019) A case report of human gastrodiscoidiasis in Nepal. *Parasitology International* **71**, 56–58.
- Sayasone S, Tesana S, Utzinger J, Hatz C, Akkhavong K and Odermatt P** (2009) Rare human infection with the trematode *Echinochasmus japonicus* in Lao PDR. *Parasitology International* **58**, 106–109.
- Sayasone S, Mak TK, Vanmany M, Rasphone O, Vounatsou P, Utzinger J, Akkhavong K and Odermatt P** (2011) Helminth and intestinal protozoa infections, multiparasitism and risk factors in Champasack province, Lao People's Democratic Republic. *PLoS Neglected Tropical Diseases* **5**, e1037.
- Seo M, Shim SY, Lee HY, Kim Y, Hong JH, Kim JE, Chai JY and Shin DH** (2020) Ancient echinostome eggs discovered in archaeological strata specimens from a Baekje Capital Ruins of South Korea. *Journal of Parasitology* **106**, 184–187.
- Sohn WM, Kim HJ, Yong TS, Eom KS, Jeong HG, Kim JK, Kang AR, Kim MR, Park JM, Ji SH, Sinuon M, Socheat D and Chai JY** (2011a) *Echinostoma ilocanum* infection in Oddar Meanchey province, Cambodia. *Korean Journal of Parasitology* **49**, 187–190.
- Sohn WM, Chai JY, Yong TS, Eom KS, Yoon CH, Sinuon M, Socheat D and Lee SH** (2011b) *Echinostoma revolutum* infection in children, Pursat province, Cambodia. *Emerging Infectious Diseases* **17**, 117–119.
- Sotillo J, Muñoz-Antoli C, Marcilla A, Fried B, Guillermo Esteban J and Toledo R** (2007) *Echinostoma caproni*: kinetics of IgM, IgA and IgG subclasses in the serum and intestine of experimentally infected rats and mice. *Experimental Parasitology* **116**, 390–398.
- Sotillo J, Trellis M, Cortés A, Fried B, Marcilla A, Esteban JG and Toledo R** (2011) Th17 responses in *Echinostoma caproni* infections in hosts of high and low compatibility. *Experimental Parasitology* **129**, 307–311.

- Sotillo J, Cortés A, Muñoz-Antoli C, Fried B, Esteban JG and Toledo R (2014) The effect of glycosylation of antigens on the antibody responses against *Echinostoma caproni* (Trematoda: Echinostomatidae). *Parasitology* **141**, 1333–1340.
- Sripa B, Kaewkes S, Intapan PM, Maleewong W and Brindley PJ (2010) Food-borne trematodiasis in southeast Asia epidemiology, pathology, clinical manifestation and control. *Advances in Parasitology* **72**, 305–350.
- Toledo R and Esteban JG (2016) An update on human echinostomiasis. *Transactions of the Royal Society of Tropical Medicine and Hygiene* **110**, 37–45.
- Toledo R and Fried B (2005) Echinostomes as experimental models for interactions between adult parasites and vertebrate hosts. *Trends in Parasitology* **21**, 251–254.
- Toledo R, Esteban JG and Fried B (2006a) Immunology and pathology of intestinal trematodes in their definitive hosts. *Advances in Parasitology* **63**, 285–365.
- Toledo R, Monteagudo C, Espert A, Fried B, Esteban JG and Marcilla A (2006b) *Echinostoma caproni*: intestinal pathology in the golden hamster, a highly compatible host, and the Wistar rat, a less compatible host. *Experimental Parasitology* **112**, 164–171.
- Toledo R, Esteban JG and Fried B (2009) Recent advances in the biology of echinostomes. *Advances in Parasitology* **69**, 147–204.
- Toledo R, Esteban JG and Fried B (2012) Current status of food-borne trematode infections. *European Journal of Clinical Microbiology and Infectious Diseases* **31**, 1705–1718.
- Toledo R, Álvarez-Izquierdo M, Muñoz-Antoli C and Esteban JG (2019) Intestinal trematode infections. *Advances in Experimental Medicine and Biology* **1154**, 181–213.
- Uzairue LI, Ugbor CI, Ezeah GAC, Eze NO and Nwadike IG (2013) *Gastrodiscoides hominis* infestation on vegetables (cabbages) sold in Ekpoma markets, Edo state, southern Nigeria – a case report. *International Journal of Basic, Applied and Innovative Research* **2**, 37–39.
- World Health Organization (1995) Control of Foodborne Trematode Infections. Technical Series Report No. 849. Geneva, Switzerland: World Health Organization.
- World Health Organization (2004) *Food-Borne Trematode Infections in Asia*. Manila, Philippines: World Health Organization Regional Office for the Western Pacific.
- Xiao X, Dabing L, Tianping W, Jianfeng G, Chuang Z, Banju Z, Jingshen A, Hongchuan P, Mingrong X, Weido W, Jide M and Xu F (1995) Studies on mode of human infection with *Echinochasmus liliputanus*. *Chinese Journal of Parasitology and Parasitic Diseases* **13**, 197–199.
- Xiao X, Wang T, Zheng X, Shen G and Tian Z (2005) In vivo and in vitro encystment of *Echinochasmus liliputanus* cercariae and biological activity of the metacercariae. *Journal of Parasitology* **91**, 492–498.
- Yamaguti S (1971) *Synopsis of Digenetic Trematodes of Vertebrates*. Tokyo, Japan: Keigaku Publishing Company.
- Yu S and Mott K (1994) Epidemiology and morbidity of food-borne intestinal trematode infections. *Tropical Diseases Bulletin* **91**, R125–R152.