





Fusion imaging for guidance of pulmonary arteriovenous malformation embolisation with minimal radiation and contrast exposure

Original Article

Catalina Vargas-Acevedo , Ernesto Mejia, Jenny E. Zablah and Gareth J. Morgan 

Cite this article: Vargas-Acevedo C, Mejia E, Zablah JE, and Morgan GJ (2024). Fusion imaging for guidance of pulmonary arteriovenous malformation embolisation with minimal radiation and contrast exposure. *Cardiology in the Young*, page 1 of 5. doi: [10.1017/S1047951124000349](https://doi.org/10.1017/S1047951124000349)

Received: 10 October 2023

Revised: 5 December 2023

Accepted: 23 January 2024

Keywords:

pulmonary artery embolisation; fusion imaging; hereditary haemorrhagic telangiectasia

Corresponding author:

G. J. Morgan;

Email: drjarethmorgan@gmail.com

Department of Pediatric Cardiology, University of Colorado, The Heart Institute, Children's Hospital Colorado, Aurora, CO, USA

Abstract

Hereditary haemorrhagic telangiectasia is an inherited disorder characterised by vascular dysplasia that leads to the development of arteriovenous malformations. Pulmonary arteriovenous malformations occur in approximately 30% of patients with haemorrhagic telangiectasia. Given the complex characteristics of haemorrhagic telangiectasia lesions, the application of three-dimensional fusion imaging holds significant promise for procedural guidance and decrease in contrast and radiation dosing. We reviewed all patients who underwent transcatheter approach for pulmonary arteriovenous malformation occlusion with fusion image guidance from June 2018 to September 2023 from a single centre. A total of nine cases with haemorrhagic telangiectasia and transcatheter occlusion of pulmonary arteriovenous malformations using fusion imaging were identified. Five (56%) were male, mean age at procedure was 15.7 years (10–28 years) and mean number of pulmonary arteriovenous malformations intervened was three per patient (1–7). Two of the cases were complex repeat embolisations. The mean fluoroscopy time was 40.6 min (10.7–68.8 min), with mean contrast dose of 28.8 mL (11–60 mL; mean of 0.51 mL/kg) and mean radiation dose of 66.3 mGy (25.6–140 mGy; mean of 40.5 mGy/m²). There were no complications reported during the procedures, with no additional interventions necessary. Fusion imaging in pulmonary arteriovenous malformations embolisation for patients with haemorrhagic telangiectasia is feasible and has the potential to reduce contrast and radiation doses. To our knowledge, we describe the lowest radiation and contrast doses per patient using fusion imaging technology reported in the literature to date.

Hereditary haemorrhagic telangiectasia is characterised by vascular dysplasia that leads to the development of arteriovenous malformations that are commonly found in the liver, brain, gastrointestinal tract, and lungs.^{1,2} These vascular anomalies pose a substantial risk of bleeding, contributing to the chronic anaemia frequently observed in affected individuals. Among the various manifestations of haemorrhagic telangiectasia, pulmonary arteriovenous malformations occur in approximately 30% of patients with haemorrhagic telangiectasia.² The presence of pulmonary arteriovenous malformations, which bypass the pulmonary capillary bed, increases the risk of embolic events and can cause low oxygen saturations, necessitating transcatheter closure to prevent complications.^{3–5}

Recent studies that support the use of three-dimensional fusion imaging in procedural guidance, with pre-procedural advanced imaging datasets (CT or MRI), suggest that it decreases contrast dose and radiation exposure and results in shorter procedural times.^{6–9} CT or MRI fusion with fluoroscopy requires three preparatory steps: segmentation, planning and image registration, to facilitate the live procedural guidance.^{10–12} In pulmonary arteriovenous malformations, inherent challenges posed by vascular tortuosity, intricate and distal locations, and often multiple lesions, lend themselves to the application of three-dimensional fusion imaging procedural guidance. This technology could enhance the precision of transcatheter pulmonary arteriovenous malformation treatment and minimise contrast dose, limit radiation exposure, and decrease procedural time. Here, we report our experience with the use of fusion imaging technology to guide percutaneous intervention of pulmonary arteriovenous malformations in patients with haemorrhagic telangiectasia using minimal radiation and contrast.

Methods and settings

Retrospective reviews of all patients with evidence of pulmonary arteriovenous malformations who underwent transcatheter approach for vessel occlusion from June 2018 to September 2023 were reviewed. All procedures were performed at Children's Hospital Colorado and all the cases reviewed used fusion imaging. Patients were referred for pulmonary arteriovenous

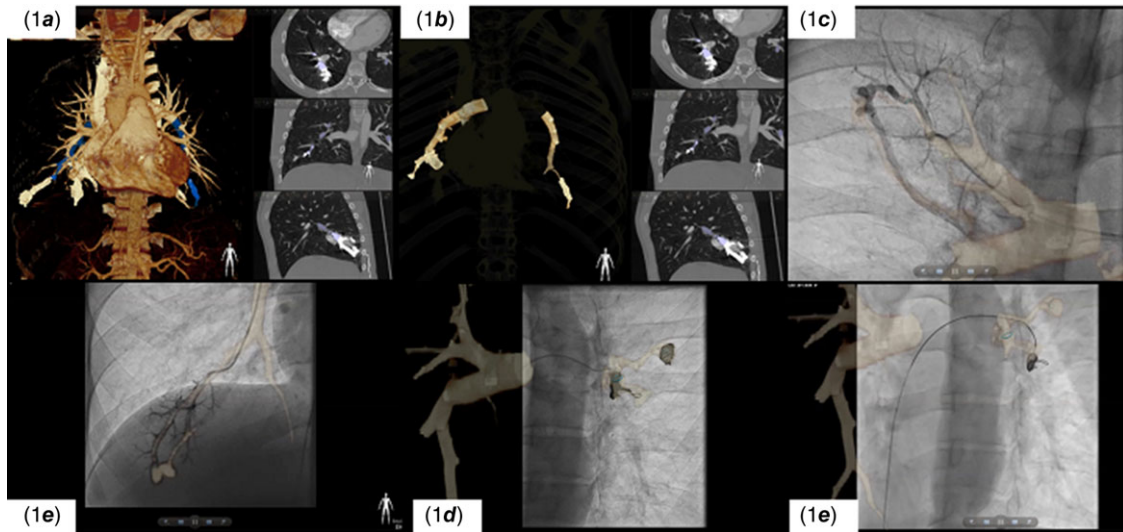


Figure 1. VesselNavigator™ images during pulmonary arteriovenous malformation embolisation. VesselNavigator™ images during pulmonary arteriovenous malformation embolisation. **a:** Segmentation of cardiac and vascular structures and selection of vessels for embolisation (Patient #9). **b:** Limited segmentation of selected vessels. **c:** Using live fusion guidance, a 4Fr Glide catheter is fed into the previously identified pulmonary arteriovenous malformation (right lower lobe pulmonary arteriovenous malformation in patient #8). **d** and **e:** Embolisation coils are fed into a previously identified pulmonary arteriovenous malformation (Left lower lobe in patient #8).

malformation occlusion after review at the institution's multi-disciplinary vascular anomaly clinic. Outcome measures included angiographic results, procedural time, radiation doses, contrast volume, complications, and need for reintervention. Variables are reported as numbers and percentages for qualitative values and mean (range) for quantitative values. The study protocol was submitted and approved by institutional review board.

Description of procedure

Cross-sectional imaging acquired prior to the catheterisation as part of the routine diagnostic work-up is post-processed and segmented to facilitate interventional planning and live guidance during the case. As per current protocol in our institution, all patients were screened using computed tomographic angiogram. The segmentation is carried out by the interventionalist prior to the procedure. Pulmonary arteriovenous malformations indicated for transcatheter closure are identified and marked on Phillips VesselNavigator™ (Philips, Amsterdam, Netherlands) and projected on fluoroscopy (Fig. 1a,b). After obtaining vascular access, and under fusion image guidance, a diagnostic catheter such as a 4-Fr Terumo glide catheter is fed through branch pulmonary arteries and into each of the previously identified arteriovenous malformations (Fig. 1c,d). The catheter is advanced and hand angiography is used to confirm the position of the arteriovenous malformation. Depending on the size and characteristics of each vessel, either a Medtronic Microvascular Plug (MVP™) is used with or without additional coils (Medtronic Concerto® coil system, (Medtronic Inc., Dublin, Ireland) or Penumbra Ruby® coil system (Penumbra, Alameda, CA, USA)). For small vessels coils are used alone (Image 1E and 1D). Angiography is used to confirm adequate occlusion of the vessel.

Results

Between 2018 and 2023, a total of nine cases with haemorrhagic telangiectasia and transcatheter occlusion of pulmonary arteriovenous malformations using fusion imaging were identified with five (56%) males. Two of the patients were referred for complex

repeat procedures resulting from incomplete or failed occlusion of pulmonary arteriovenous malformation's during previous attempts. The mean age at diagnosis of haemorrhagic telangiectasia was 12.9 years (3–27 years) and the mean age at procedure was 15.7 years (10–28 years). The mean weight at procedure was 56.2 kg (37.6–77 kg). Seven patients (78%) had evidence of endoglin mutation. All patients had normal cardiac anatomies, and no patients showed evidence of pulmonary hypertension. Other related findings included gastrointestinal and intracranial arteriovenous malformations and mucosal telangiectasias with epistaxis, as expected per their diagnosis. The mean number of pulmonary arteriovenous malformations indicated for intervention was three per patient (1–7).

Devices used during the procedure included Medtronic Concerto® coils and Penumbra Ruby® coils. In larger pulmonary arteriovenous malformations, Medtronic MVP™ was used alone or in addition to coils. The mean number of devices implanted per case was 4.2 (1–9). The mean fluoroscopy time was 40.6 min (10.7–68.8 min), with a mean total contrast dose of 28.8 mL (11–60 mL), indexed contrast dose of 0.51 mL/kg (0.25–0.88 mL/kg), a mean radiation dose of 66.3 mGy (25.6–140 mGy), and indexed dose of 40.5 mGy/m² (15.8–80.5 mGy/m²). There were no complications reported during the procedures, with no additional interventions necessary. When we exclude the two complex redo patients, the mean radiation dose was 55.5 mGy (mean of 34.4 mGy/m²), mean fluoroscopy time of 36.5 minutes, and a mean contrast dose of 26.6 ml (mean of 0.47 ml/kg).

Table 1 represents all demographic, clinical characteristics, and procedural results for each patient.

Discussion

Haemorrhagic telangiectasia is a chronic disease that needs multi-disciplinary management and follow-up with multiple radiographic imaging modalities used on a regular basis resulting in an overall radiation burden which places these patients in a higher risk group for radiation-induced malignancies.^{13–15} Transcatheter closure of pulmonary arteriovenous malformations is a well

Table 1. Patient characteristics

Patient #	Sex	Age at procedure (Years)	Weight at procedure (Kg)	BSA (m ²)	Age at diagnosis of HHT (Years)	Baseline oxygen saturation (%)	Number of PAVMs for device closure	Location of PAVMs	# of devices used	Devices used	Radiation dose (mGy)	Radiation dose (mGy/m ²)	Fluoroscopy time (min)	Contrast dose (ml/kg)	Contrast dose (ml)
1	F	16	51.2	1.55	12	96	3	LUL and RLL	3	LUL: 1 Penumbra Coil RLL: 3 mm MVP and 1 Penumbra Coil	68	43.9	49.2	0.88	45
2	F	12	77	1.76	12	94	3	LLL and RUL	2	RUL: MVP 5 mm LLL: 2 MVP 5 mm	95.1	54.0	31.1	0.78	60
3	F	10	37.6	1.24	7	92	7	6 on the left, 1 on the right	9	RLL: MVP 3 mm Left Coll#1: Concerto coils Coll#2: MVP 3 mm Coll#3: MVP 3 mm Coll#4 Concerto Coils Coll#5 Concerto Coils + MVP 3 mm Coll#6 two Concerto coils	55.2	44.5	57.2	0.80	30
4	M	18	62	1.82	18	97	1	LLL	3	3 Concerto coils	28.7	15.8	17.2	0.26	16
5	M	13	51.9	1.59	13	96	1	1 RLL (two tiny in the periphery 1 RML and 1 LLL)	1	Concerto coil	32.5	20.4	25.8	0.25	13
6	M	15	61	1.74	16	92	2	3 right sided AVMs	4	AVM#1: 5 mm MVP AVM#2: Concerto 16 mm x 40 mm AVM #3: 5 mm MVP and Concerto 12 mm x 30cm	94	54.0	45	0.43	26
7	F	13	37.6	1.29	3	94	1	Large AVM to LLL	1	7 mm MVP	25.6	19.8	10.7	0.29	11
8	M	28	64.6	1.81	27	91	5	3 in the LLL, RUL, RLL	6	Middle superior LLL: 2 Penumbra coils Superior LLL: 2 Penumbra coils Posterior RUL: 3 mm MVP + Penumbra coils RLL: 5 mm MVP	57.8	31.9	68.8	0.46	30

(Continued)

Table 1. (Continued)

Patient #	Sex	Age at procedure (Years)	Weight at procedure (kg)	BSA (m ²)	Age at diagnosis of HHT (Years)	Baseline oxygen saturation (%)	Number of PAVMs for device closure	Location of PAVMs	# of devices used	Devices used	Radiation dose (mGy)	Radiation dose (mGy/m ²)	Fluoroscopy time (min)	Contrast dose (ml/kg)	Contrast dose (ml)
9	M	16	63.3	1.74	8	88	4	2 in the RLL, 2 in the LLL	9	Superior RLL: 1 Penumbra coil Inferior RLL: 4 Penumbra coils Superior LLL: 1 Penumbra coil + 3 mm MVP Inferior LLL: 1 Penumbra coil + 3 mm MVP	140	80.5	60.5	0.44	28
Mean (range)	Male 5 (56%)	15.7 (10-28)	56.2 (37.6-77)	1.6 (1.2-1.8)	12.9 (3-27)	93.3 (88-97)	3.0 (1-7)		4.2 (1-9)		66.3 (25.6-140)	40.5 (15.8-80.5)	40.6 (10.7-68.8)	0.51 (0.25-0.88)	28.8 (11-60)

PAVM = pulmonary arteriovenous malformation; GI = gastrointestinal tract; Coll = collateral; LUL = left upper lobe; LLL = left lower lobe; RUL = right upper lobe; RML = right middle lobe; RLL = right lower lobe; MVP = microvascular plug; HHT = haemorrhagic telangiectasia.
Patient #1 and patient #9 were reinterventions of previous incompletely embolised vessels.

described and accepted therapy.^{1,5} The lesions are usually multiple, very distal in the lung parenchyma, and have complex morphology, which can make transcatheter embolisation a long and challenging procedure. This is further complicated by the need for multiple angiograms, which are challenging to interpret given numerous overlapping pulmonary branches on fluoroscopy.

In our experience, the added value of fusion imaging technology in these procedures is as follows. Firstly, as part of procedural planning, to determine the correct angiographic angles of interrogation and the size of the vessels involved, thus, narrowing the scope of devices that need to be available. This in itself can aid planning and reduce case time and complexity. Second, the initial diagnostic angiographic imaging is likely reduced due to the use of VesselNavigator™ live guidance images superimposed on fluoroscopy. Thirdly, the combination of these features can lead to less contrast volume, fluoroscopy, and cine-angiographic image acquisition. As expected with our limited patient population, and the lack of a control group, we have a limited ability to demonstrate statistical superiority of fusion imaging over standard two-dimensional imaging. Nonetheless, this expected benefit has been previously demonstrated in other interventional procedures such as transcatheter pulmonary valve replacement, pulmonary vein stenosis, as well as other oncological and vascular interventions, showing a significant decrease in contrast dose and procedural duration.^{8,10,11}

The first report to our knowledge, of the use of fusion imaging technology specific for pulmonary arteriovenous malformations embolisation, was recently published and showed a significant decrease in contrast dose when compared to standard two-dimensional imaging in this single centre (118.3 mL versus 285.3 mL; $p < 0.002$) but with no statistically significant difference found in procedural duration (19.5 min versus 31.4 min $p = 0.054$).⁹ In our series, predominantly paediatric, which inherently increases complexity of interventional procedures, we report a mean contrast dose of 28.8 mL (11–60 mL, 0.51 mL/kg), far lower (approx. 20%) than that reported by Garnier et al. (118.3 mL, range 50–300 mL) with a 29% higher mean number pulmonary arteriovenous malformations treated per patient in our series (3 versus 2.33). The same is true for radiation dose, where we report a mean of 66.3 mGy (25.6–140 mGy and an indexed mean dose of 40.5 mGy/m²) compared to 599.9 mGy. When excluding patients with reintervention of previously embolised pulmonary arteriovenous malformation, the mean radiation dose was even lower at 55.6 mGy (34.4 mGy/m²). Nevertheless, we show a longer mean fluoroscopy time of 40.6 min (10.7–68.8 min) compared to the extremely low 19.5 min (range 8–44 min) reported by Garnier. This may be partially explained by the higher number of treated lesions per case. However, despite the longer fluoroscopy time, it is important to note that the total and indexed radiation doses are significantly lower than those reported elsewhere. Thus, we consider this a technique with minimal radiation and contrast exposure important in a predominantly paediatric population.

The most significant advantage to the use of fusion imaging technology for embolisation of pulmonary arteriovenous malformations seems to be related to the dose of contrast and radiation. However, we must highlight the importance of using fusion imaging for pre-procedural case planning, to generate angiographic angles and select occlusion devices, which can further decrease the use of contrast and radiation dose as well as optimising efficiency and resource utilisation in these and other patients. We report a contrast and radiation dose far below that previously reported in the literature, likely due to our use of customised low radiation and contrast protocols, which are made

feasible by the reliance on overlay fusion imaging.¹⁶ The recognition that haemorrhagic telangiectasia patients require recurring ionising radiation-based diagnostic and intervention procedures for various arteriovenous malformations behoves us to minimize contrast and radiation dose to help preserve renal function and decrease lifetime radiation-based complications.^{6,7,9}

Conclusions

Fusion imaging in pulmonary arteriovenous malformations embolisation for paediatric and young adult patients with haemorrhagic telangiectasia is feasible and has the potential of reducing contrast and radiation doses. Further studies are necessary to clearly establish this association.

Limitations

This is a single-centre experience with retrospective analysis. Due to the small group of patients, no subgroup analyses were conducted to measure outcomes.

Acknowledgements. None.

Financial support. None.

Competing interests. None.

References

- Garg N, Khunger M, Gupta A, Kumar N. Optimal management of hereditary hemorrhagic telangiectasia. *J Blood Med* 2014; 5: 191. DOI: [10.2147/JBM.S45295](https://doi.org/10.2147/JBM.S45295).
- Azad F, Miranda CJ, Sparacino GM. Pulmonary arteriovenous malformation in a rare case of hereditary hemorrhagic telangiectasia. *Cureus* 2022; 14(12): e32365. DOI: [10.7759/cureus.32365](https://doi.org/10.7759/cureus.32365).
- Rajesh GN, Sajeer K, Nair A, Haridasan V, Sajeev CG, Krishnan MN. Device closure of pulmonary arteriovenous malformation using Amplatzer vascular plug II in hereditary hemorrhagic telangiectasia. *Indian Heart J* 2015; 67: 455–458.
- Tau N, Atar E, Mei-Zahav M, et al. Amplatzer vascular plugs versus coils for embolization of pulmonary arteriovenous malformations in patients with hereditary hemorrhagic telangiectasia. *Cardiovasc Intervent Radiol* 2016; 39: 1110–1114.
- Muhammad A, Rauf Z, Shahid J, Iqbal J, Haq TU, Zafar U. Endovascular embolisation of pulmonary arteriovenous malformation using amplatzer vascular plugs. *Cureus* 2022; 14(4): e24214. DOI: [10.7759/cureus.24214](https://doi.org/10.7759/cureus.24214).
- Nobre C, Oliveira-Santos M, Paiva L, Costa M, Gonçalves L. Fusion imaging in interventional cardiology PALAVRAS-CHAVE. *Rev Port Cardiol* 2020; 39: 463–473.
- Goreczny S, Morgan GJ, McLennan D, Rehman R, Zablah JE. Comparison of fusion imaging and two-dimensional angiography to guide percutaneous pulmonary vein interventions. *Kardiol Pol* 2022; 80: 476–478.
- Markelj P, Tomažević D, Likar B, Pernuš F. A review of 3D/2D registration methods for image-guided interventions. *Med Image Anal* 2012; 16: 642–661.
- Garnier M, Curado A, Grancher A, et al. Fusion imaging for pulmonary artery embolization: impact on fluoroscopy duration and contrast agent exposure. *Br J Radiol* 2023; 96(1151): 20220815. DOI: [10.1259/bjr.20220815](https://doi.org/10.1259/bjr.20220815).
- Ehret N, Alkassar M, Dittrich S, et al. A new approach of three-dimensional guidance in paediatric cath lab: segmented and tessellated heart models for cardiovascular interventions in CHD. *Cardiol Young* 2018; 28: 661–667.
- Goreczny S, Moszura T, Dryzek P, et al. Three-dimensional image fusion guidance of percutaneous pulmonary valve implantation to reduce radiation exposure and contrast dose: a comparison with traditional two-dimensional and three-dimensional rotational angiographic guidance. *Neth Heart J* 2017; 25: 91–99.
- Zablah JE, Morgan GJ. Innovations in congenital interventional cardiology. *Pediatr Clin North Am* 2020; 67: 973–993.
- Cevallos PC, Armstrong AK, Glatz AC, et al. Radiation dose benchmarks in pediatric cardiac catheterization: a prospective multi-center C3PO-QI study. *Catheter Cardio Interv* 2017; 90: 269–280.
- Kleinerman RA. Cancer risks following diagnostic and therapeutic radiation exposure in children. *Pediatr Radiol* 2006; 36: 121–125.
- Miglioretti DL, Johnson E, Williams A, et al. The use of computed tomography in pediatrics and the associated radiation exposure and estimated cancer risk. *JAMA Pediatr* 2013; 167: 700–707.
- Zablah JE, Rodriguez SA, Leahy R, Morgan GJ. Novel minimal radiation approach for percutaneous pulmonary valve implantation. *Pediatr Cardiol* 2021; 42: 926–933.