

ENTAMOEBEA HISTOLYTICA IN WILD RATS CAUGHT IN LONDON

By R. A. NEAL, *Wellcome Laboratories of Tropical Medicine,*
183 Euston Road, London, N.W.1

(With Plate 4 and 1 Figure in the Text)

INTRODUCTION

The natural infection of wild rats with *Entamoeba histolytica* was first reported by Lynch (1915) working in Charleston, U.S.A. This author described an amoeba found by him in six rats, which he thought to be identical with *E. histolytica*. He observed that the caecum was ulcerated, but he did not state whether amoebae were found in histological sections of the ulcers. Though Lynch did not give a description of any cysts, he mentioned that 'the same amoeba was present mainly in the resting state in the rectum', it is possible, however, these were rounded amoebae or tissue cells. He was criticized later (Chatton, 1917; Dobell, 1919; and others), on the grounds that he did not describe the cyst stages of the amoeba in question, or give any details distinguishing it morphologically from *E. muris*, of the existence of which he appeared to be unaware. In view of later reports of natural infection of rats with *E. histolytica*, it is possible that he was actually dealing with this species, although a definite conclusion cannot be reached.

In 1919, Brug working in the Dutch East Indies, published a paper describing an amoeba he found in two rats. From his figures of amoebae and cysts, it is evident that it was *E. histolytica*, although some of his cysts are mis-shapen. He was doubtful of its complete identity with *E. histolytica* since he could not find any amoebae invading the intestinal wall.

Chiang (1925) found that seven of his laboratory rats were spontaneously infected with *E. histolytica*. The amoebae grew in culture and when inoculated into kittens, invaded the intestinal wall and produced lesions. Chiang considered this to be a separate variety, *E. histolytica* var. *murina*.

Working in Moscow, Epstein & Awakian (1937) reported the discovery of wild rats harbouring *E. histolytica*. They published figures of the amoebae and cysts, showing that the morphology was indistinguishable from that of *E. histolytica*. The strain grew well in culture, and two kittens infected with cultured amoebae developed amoebic dysentery. These naturally infected rats were associated with cases of human amoebiasis.

Senekji (1940) stated that he found two rats

(0.59 %) infected with an *E. histolytica*-like amoeba, during his survey of the parasites of wild rats caught in Iraq.

The observations reported in the present work were made during a survey of the incidence of amoebae parasitic in wild rats.

EXPERIMENTAL RESULTS

I. Description of the Amoeba

Seven out of eleven rats examined from a particular source were found to harbour an amoeba possessing the characteristics of *E. histolytica*; of these, two were detected by culture methods only. The host rats varied in weight between 210 and 400 g. (3-12 months old).

The amoebae were restricted to the caecum of the rats and were distributed throughout the lumen. The caecal walls were examined carefully but no macroscopic lesions were detected.

The amoebae when moving actively produced hyaline, ectoplasmic pseudopodia. In stained preparations, rounded amoebae measured 10-16 μ in diameter, although when flattened or extended, larger dimensions were recorded. The endoplasm was granular and contained food vacuoles. From the contents of these, it was evident that bacteria and intestinal debris were ingested, but no red blood corpuscles were observed in them. The vesicular nucleus measured 3-5 μ in diameter, and contained a small central karyosome. The peripheral chromatin was arranged in fine granules; no other chromatin granules were observed between the karyosome and nuclear membrane (Text-fig. 1 (1)).

Cultures of amoebae were obtained using the inspissated horse serum slope, with either egg-Ringer liquid phase (HSre), or horse-serum Ringer liquid phase (HShs), media of Dobell & Laidlaw (1926). The cultural forms of the amoebae of the rats were identical with those found in the caeca (Text-fig. 1 (2)). The cultures were maintained for experiments described below.

II. Description of the cysts

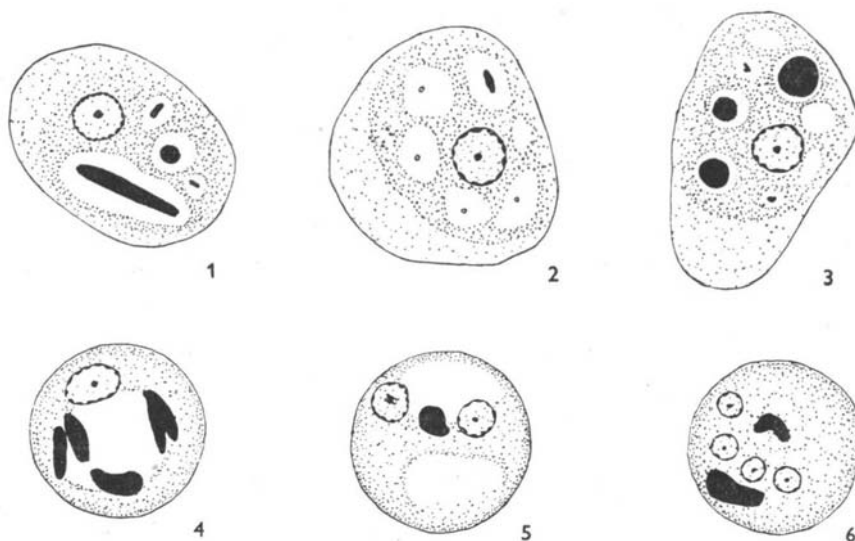
Cysts were extremely scanty; after a prolonged examination of stained smears, only a few uninucleate (Text-fig. 1 (4)) and binucleate cysts were

seen. The zinc sulphate concentration technique for cysts was carried out on the faeces before the animals were killed, and upon the caecal contents, without success. In culture, however, after inoculation into appropriate media, cysts in all stages of development were obtained (Text-fig. 1 (5, 6)) which were identical with those observed in the wild rats.

Measurement of 100 mature quadrinucleate cysts stained in iodine showed that the diameter varied between 9 and 19 μ , but the majority measured 12 to 15 μ . The cyst nuclei had a small central karyosome, while the cytoplasm contained bar-shaped chromatoid bodies with rounded ends. The

being exposed through a small incision in the abdominal wall under ether anaesthesia. The animals were killed after 6 days, and the results assessed by the presence or absence of amoebae as demonstrated by direct examination, and by culture. The condition of the caecum was assessed by an arbitrary scoring method. The condition of the wall [varying from normal (= 0) to extensive ulceration (= 4)] was scored separately from the condition of the contents [varying from normal (= 0) to mucus only (= 4)].

The effect of treatment with emetine was investigated by feeding the rats for 6 days upon a



Text-fig. 1. Preparations were fixed in Schaudinn's fixative with 5% acetic acid added, and stained in phosphotungstic haematoxylin (Dobell, 1942), unless otherwise stated. Magnified $\times 2000$. (1) Trophic amoeba from a wild rat showing ingested bacteria. (2) Amoeba from culture, food vacuoles containing starch grains. (3) Amoeba showing ingested red-blood cells. From an experimental infection. (4) Uninucleate cyst from a wild rat with a glycogen vacuole and chromatoid bodies. (5) Binucleate cyst from culture showing a glycogen vacuole and a rounded chromatoid body. Stained with Heidenhain's iron haematoxylin. (6) Quadri-nucleate cyst from culture. Heidenhain's iron haematoxylin.

glycogen vacuole had usually disappeared in the mature cysts, but occasionally the last vestiges were seen. However, the uninucleate and binucleate cysts contained a large glycogen vacuole, around the edge of which were chromatoid bodies.

III. In vivo Experiments with cultures

Cultures of *E. histolytica* from the wild rats were used for producing experimental infections in laboratory animals, and investigating the effect of drug treatment.

(1) Technique

The animals used for experimental infections were newly weaned rats, which were inoculated with cultures of amoebae intracaecally, the caecum

dry mash diet, with which emetine hydrochloride was mixed in a known proportion. The rats were then killed and the results assessed as above. This technique is described in detail by Goodwin, Hoare & Sharp (1948).

(2) Virulence

The virulence of three strains is shown in Table 1.

All the rats were parasitized, and the caecum was attacked with varying degrees of severity. When ulcers were formed, they were shallow, the mucosa being completely eroded and with ragged edges, in some cases the ulcers covered large areas which measured up to 0.5 cm. in diameter. The surface of the ulcer was composed of necrotic tissue, bacteria, leucocytes and amoebae. A section of an ulcer

from a rat infected with strain WR 22 is shown in Pl. 4, figs. 1 and 2.

A stained smear showed that the amoebae ingested tissue fragments, bacteria and red blood cells (Text-fig. 1 (3)).

Table 1. *The virulence of three strains to young rats*

| Strain | No. of rats infected | Average caecal scores | |
|--------|----------------------|-----------------------|----------|
| | | Wall | Contents |
| WR14 | 4/4 | 2.2 | 2.0 |
| WR18 | 3/3 | 1.0 | 1.3 |
| WR22 | 6/6 | 1.7 | 2.0 |

(3) *Therapeutic effect of emetine hydrochloride*

Using the technique outlined above and strain WR 22, it was found that emetine hydrochloride at a dilution of 0.002% in the diet, cleared 5 rats out of 6 of amoebic infection, and prevented the ulceration of the caecum wall of all 6 animals. On the other hand, all 6 of the untreated control rats showed amoebic infection, with marked thickening and ulceration of the caecum.

DISCUSSION

The morphology of the amoebae and cysts is identical with that of *E. histolytica* as described by Dobell (1919) and others. The amoeba described above is quite different from *E. muris*, which produces 8-nucleate cysts, is non-pathogenic, and has not yet been successfully cultivated *in vitro*. The biology of the amoeba under consideration is also identical with that of *E. histolytica* except for the rarity of cysts in the rats. This observation agrees with those of Lynch (1915) who only observed trophic amoebae, and also with observations on experimental infection of rats with *E. histolytica* from man (Jones, 1946). However, Brug (1919) and Chiang (1925) record the finding of cysts in rats naturally infected with *E. histolytica*, while in the cases described by Epstein & Awakian (1937) the rats are said to have passed large numbers of cysts, 1-4 nucleate in their faeces.

The absence of lesions in the gut of the naturally infected wild rats reported in the literature and also in this paper is probably due to the age of the rats. Jones (1946) has shown that the age of the rat is an important factor influencing the type of infection produced, and rats weighing 40 g. or over have a greater resistance to the parasite than younger rats, little or no ulceration being produced.

The inhabitants of the house in which the infected rats were caught were Cypriots, one family of five having arrived from Cyprus within the last 6 months. Seven of these people were examined for intestinal

protozoa and two were found to be passing abundant *E. histolytica* cysts in their faeces. Four clean rats, of a weight comparable to that of the naturally infected wild rats, were inoculated orally with cysts from these persons, and two developed amoebic infections without producing any lesions. An investigation of the circumstances in which the infected rats were discovered revealed the absence of a trap between the sewers and the drainage system of the house in which the human cases were found. Owing to this defect the rats were able to gain access to the house from the sewerage.

Twelve wild rats from other sources have been examined, and all proved to be negative for *E. histolytica*, but *E. muris* was present in some.

From these facts, it is probable that the *E. histolytica* infection in the rats was of local origin, and the evidence, although circumstantial, suggests that they were infected by cysts of a human strain of *E. histolytica*.

The discovery of naturally infected rats in association with human cases of amoebiasis reported in this paper, and by previous authors, as well as the susceptibility of these animals to experimental infection with *E. histolytica*, might prove to be of greater epidemiological importance than has hitherto been suspected, for it is conceivable that rats occasionally act as reservoir hosts of human amoebiasis.

There are no grounds for regarding this amoeba as a separate variety, owing to its complete identity with *E. histolytica*, and its probable origin from human strains.

SUMMARY

1. A description is given of active forms and cysts of an amoeba found in wild London rats, and morphologically identical with *E. histolytica*.
2. When inoculated into the caeca of young rats, the amoebae invade the wall and produce lesions.
3. Acute infections produced in experimental rats respond to treatment with emetine hydrochloride.
4. The naturally infected rats were restricted to a localized focus, in which cases of human amoebiasis were discovered, thus providing circumstantial evidence of the human origin of the infection, and throwing light on the possible role of rats as reservoir hosts.

I would like to thank Dr C. A. Hoare and Mr L. G. Goodwin for their advice and interest in this work, and Miss S. I. Pluthero for technical assistance. I am also indebted to Dr D. H. Geffin, M.O.H., and Mr Westripp of the Public Health Dept., St Pancras Borough Council, for supplying the rats and faecal specimens.



Fig. 1

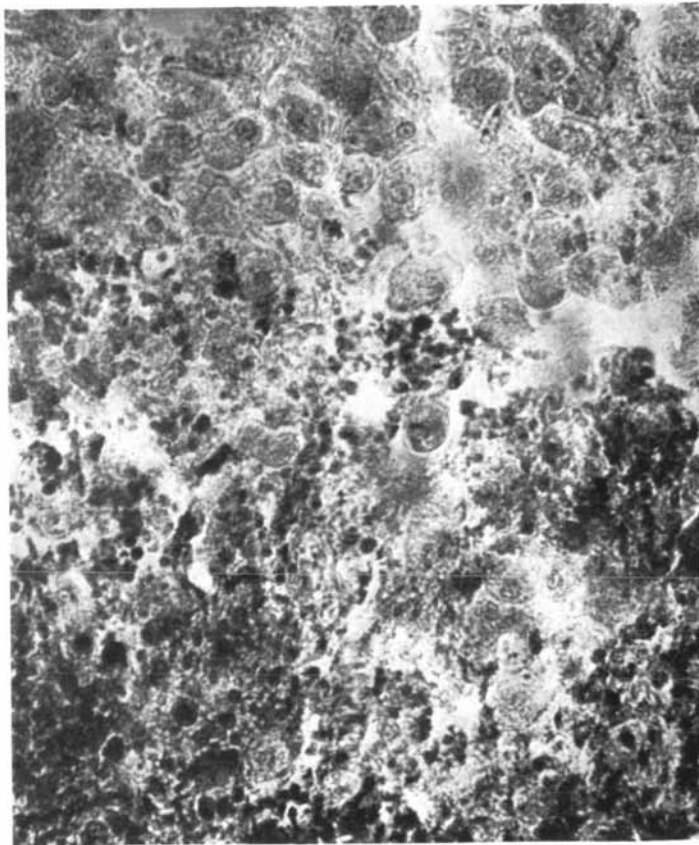


Fig 2.

REFERENCES

- BRUG, S. L. (1919). De entamoeba van de rat. *Geneesk Tijdschr. Ned.-Ind.* **59**, 1.
- CHATTON, E. (1917). Realisation expérimentale chez la cobaye de l'amibiase intestinale à *Entamoeba dysenteriae*. *Bull. Soc. Path. exot.* **10**, 794.
- CHIANG, S. F. (1925). The Rat as possible carrier of the dysentery amoeba. *Proc. nat. Acad. Sci., Wash.*, **11**, 239.
- DOBELL, C. (1919). *The Amoebae Living in Man*. London: John Bale, Sons and Danielsson.
- DOBELL, C. (1942). Some new methods for studying intestinal amoebae and other protozoa. *Parasitology*, **34**, 101.
- DOBELL, C. & LAIDLAW, P. P. (1926). On the cultivation of *Entamoeba histolytica* and some other entozoic amoebae. *Parasitology*, **18**, 283.
- EPSTEIN, G. W. & AWAKIAN, A. (1937). Rats as carriers of dysenteric entamoebae. *Trans. R. Soc. trop. Med. Hyg.* **31**, 87.
- GOODWIN, L. G., HOARE, C. A. & SHARP, T. (1948). *Brit. J. Pharmacol.* (In the Press.)
- JONES, W. R. (1946). The experimental infection of rats with *Entamoeba histolytica*, with a method for evaluating the anti-amoebic properties of new compounds. *Ann. trop. Med. Parasit.* **40**, 130.
- LYNCH, K. M. (1915). The rat as a carrier of a Dysenteric Amoeba. *J. Amer. med. Ass.* **65**, 2232.
- SENEKJI, H. A. (1940). Bacteriological and Parasitological Survey of Rats in Iraq. *Trans. R. Soc. trop. Med. Hyg.* **33**, 655.

EXPLANATION OF PLATE 4

- Fig. 1. Section of an ulcer in the caecal wall of an experimentally infected rat. Fixed in Duboscq-Brazil, and stained with Heidenhains' iron haematoxylin and eosin. $\times 50$.
- Fig. 2. Higher magnification of Fig. 1. $\times 600$.

(MS. received for publication 10. XII. 47.—Ed.)