

***Paraspiralatus sakeri* n. g., n. sp.
(Nematoda: Spiruroidea, Spirocercidae)
from saker falcons, *Falco cherrug* in Saudi
Arabia and the first report of larvae from the
subcutaneous tissues of houbara bustards,
Chlamydotis undulata macqueeni in
Pakistan**

L.M. Gibbons^{1*}, P.K. Nicholls², T. Bailey³ and J. Samour⁴

¹Department of Pathology and Infectious Diseases, The Royal Veterinary College, University of London, Hawkshead Lane, North Mymms, Hatfield, Hertfordshire, AL9 7TA, UK: ²Division of Veterinary and Biomedical Sciences, Murdoch University, South Street, Murdoch, WA 6150, Australia:

³Dubai Falcon Hospital, PO Box 23919, Dubai, United Arab Emirates:

⁴Fahad Bin Sultan Falcon Center, PO Box 55, Riyadh 11322, Saudi Arabia

Abstract

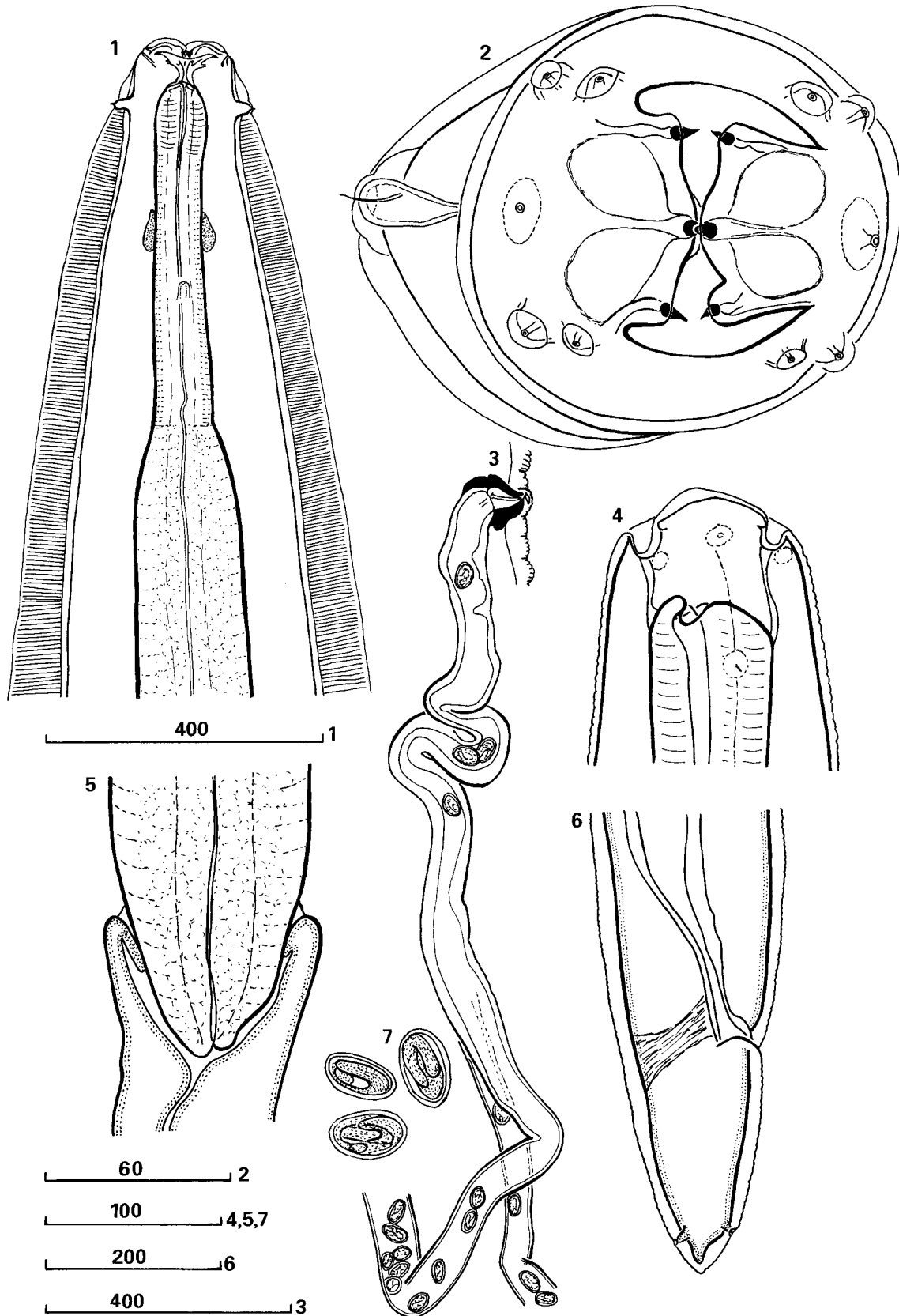
A new nematode genus and species, *Paraspiralatus sakeri*, is described from the stomach of a wild-caught, female saker falcon in Saudi Arabia. This spirurid differs from the nearest genus and species *Spiralatus baeri* Chabaud, Brygoo & Durette, 1963 in the shape of the pseudolabia, shape of the buccal capsule and absence of a large cephalic vesicle. In addition, third stage spirurid larvae were recovered for the first time from subcutaneous tissues of two houbara bustards. These had died in the Rahim Yar Khan Rehabilitation Center (Houbara Foundation International, Lahore, Pakistan) in Pakistan and were examined at the National Avian Research Center in the United Arab Emirates. The morphology of the larvae and host pathology are described. Comparative studies with the adult spirurids from the saker falcon showed each to have similar cephalic and pharyngeal morphological features to the adults described indicating they are probably the same species. Spirurid nematodes of the suborder Spirurina normally have an arthropod intermediate host. In view of the host, the site from which the larvae were recovered and the fact that this is a rare occurrence, the houbara bustard is considered to be a paratenic host.

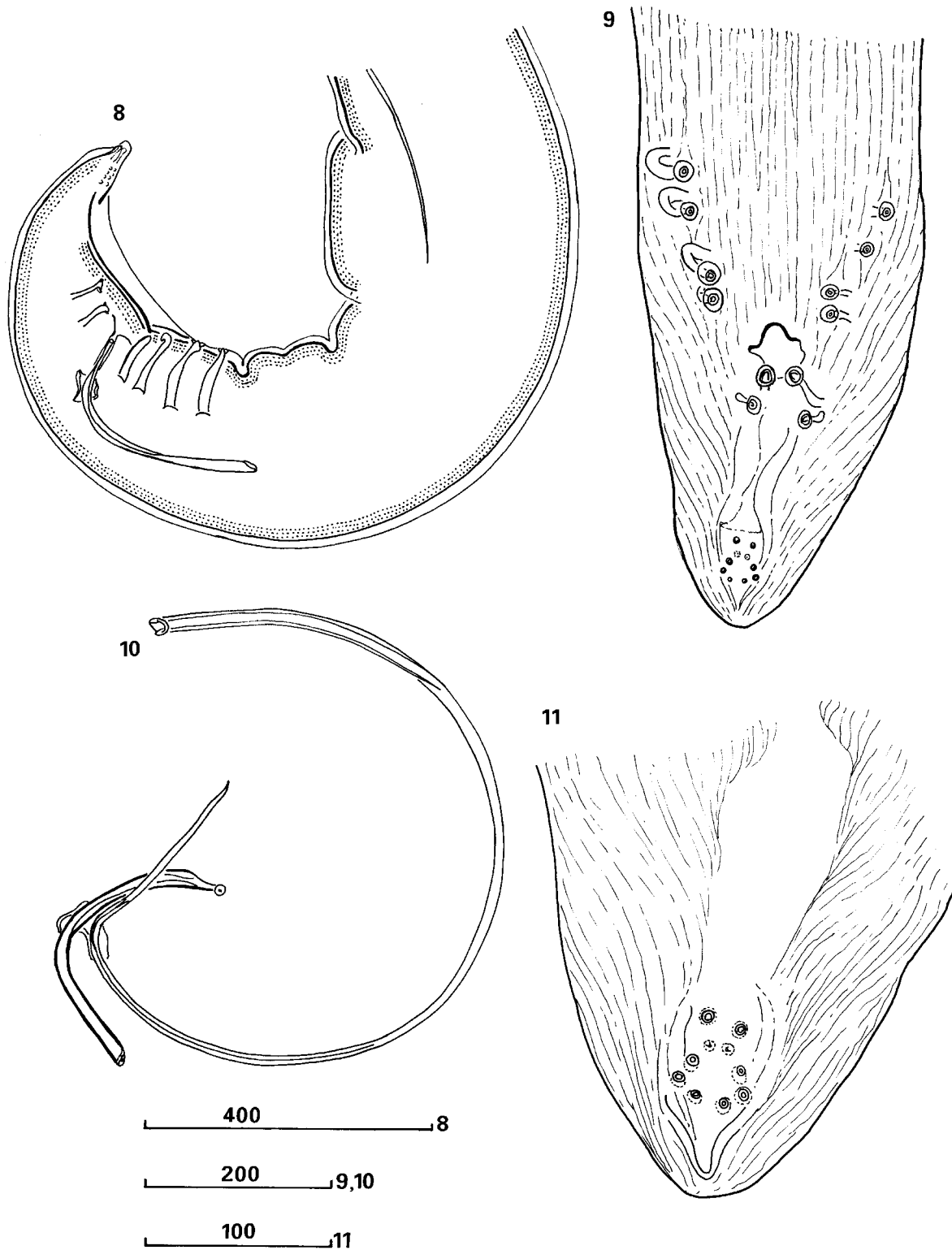
Introduction

Nematodes were recovered from the stomach of a wild-caught adult female saker falcon, *Falco cherrug*, through the oesophagus by stomach wash at the Fahad bin Sultan

Center, Riyadh, Saudi Arabia. An additional male and female were recovered from another adult female saker falcon during a routine gastric lavage at the Center to retrieve a lead pellet from the gizzard. The specimens were compared to other spirurid nematodes from birds and were found to share some similarities to the species *Spiralatus baeri* Chabaud, Brygoo & Durette, 1963 from *Leptosomus discolor* in Madagascar. Differences in the cephalic region and buccal capsule from *Spiralatus*

*Fax: +44 (0) 1707 661464
E-mail: LGibbons@rvc.ac.uk





Figs 1–11. *Paraspiralatus sakeri* n. g., n. sp. adult. 1, Female, anterior end, dorso-ventral view; 2, female, *en face* view, slightly tilted to show position of one of the cervical papillae; 3, female vulvar region showing lateral view of vagina and proximal end of reproductive tract; 4, male cephalic region, lateral view; 5, male showing pharyngeo-intestinal junction; 6, female tail in latero-ventral view; 7, embryonated eggs dissected out of uterus. 8, Posterior end of male, lateral view; 9, Posterior end of male, ventral view; 10, male, spicules and gubernaculum, lateral view; 11, distal end of male tail. Scale bars in microns.

indicate that they belong to a new genus and species which are described and illustrated.

In addition, specimens were recovered from a dead female houbara bustard, *Chlamydotis undulata macqueeni* (reference number HB 35) from the Rahim Yar Khan Rehabilitation Center, Pakistan (GPS location N28.54970/E70.92997) in February 1998 which had been frozen prior to post mortem examination at the National Avian Research Center, United Arab Emirates. The bird was decomposed but large numbers of nematodes were revealed under the skin, particularly in between the legs but also in the neck and back regions. The cause of the death of the bird was not determined. Nematodes recovered from the tissues revealed that they were immature life-cycle stages. A second bird from the same centre was studied (reference number HB 332) and immature nematodes were found overlying the muscles of the upper hind limb. These represent the first report of subcutaneous nematodes in houbara bustards in Pakistan and are the only records made during a study on houbara bustard populations in the region. Similarities in the features of the cephalic region instigated a comparative study with the adult nematodes recovered from the saker falcon. The results of these morphological and pathological studies are presented. The morphological terminology follows Gibbons (2002).

Materials and methods

Adults

Four male and five female nematodes were recovered from the stomach of a wild-caught adult female saker falcon, *Falco cherrug*. An additional male and female were recovered from another adult female saker falcon. All the nematodes recovered were fixed and preserved in 70% ethanol and 5% glycerine. The specimens were examined as temporary mounts in lactoglycerol. The heads of two female specimens were cut with a fragment of razor blade mounted in a needle holder to prepare end on views of the cephalic region and were mounted in glycerine jelly. The remaining part of the body was dissected to examine the female reproductive system.

Larvae

Six whole specimens and some fragments of nematodes were recovered from preserved tissues of a houbara bustard, *Chlamydotis undulata mcqueeni*. The tissues were formalin fixed and the larvae recovered transferred to 70% alcohol for storage. Specimens were prepared for microscopical examination by clearing in lactoglycerol as temporary mounts. One specimen was cut with a fragment of razor blade mounted in a needle holder to prepare an end on view of the cephalic region and was mounted in glycerine jelly.

Tissues containing the nematodes were prepared for histological section using standard procedures. Separate sections were stained using Periodic Acid-Schiff (PAS), Gram and Ziehl-Neelsen (ZN) techniques.

Illustrations for both adults and larvae were made with the aid of a drawing tube.

Paraspiralatus n. g.

Family Spirocercidae (Chitwood & Wehr, 1932 subfamily)
Subfamily Spirocercinae Chitwood & Wehr, 1932

Description. Medium sized nematodes, cuticle with distinct transverse striations. Pseudolabia present. Cephalic vesicle absent. Buccal capsule with three teeth on each lateral proximal margin. Median teeth or lobes absent. Buccal capsule compressed laterally, funnel-shaped in dorso-ventral view. Wide lateral alae on anterior half of body. Cervical papillae very large near anterior end at level of proximal end of pharynx. Pharynx long with distinct anterior muscular region and posterior glandular region. Pharyngo-intestinal valve projects into the intestine. Posterior end of male with caudal alae, ornamented on ventral surface, pedunculate papillae arranged in typical spirurid format, four pairs precloacal, two pairs postcloacal and a cluster of sessile papillae near distal tip. Spicules unequal and dissimilar. Gubernaculum present. Vulva opens in mid region of body. Didelphic. Mature eggs thick-walled, embryonated, slightly flattened on one side. Parasites of stomach of *Falco* spp.

Paraspiralatus sakeri n. sp.

(figs 1–11)

Description. Body with broad lateral alae arising at base of pseudolabia, narrows towards posterior end in male and vulva region in female. Cephalic region with two lateral pseudolabia present. Cephalic sensory organs consist of four pairs of large, submedian papillae and two lateral amphids. Buccal capsule, lightly sclerotized, laterally compressed, narrowing posteriorly in dorso-ventral view, almost straight-sided in lateral view, three teeth on each lateral proximal margin. Median teeth or lobes absent. Cervical papillae situated at margin of cephalic and cervical regions. Cervical papillae cylindrical, rounded at outer margin with a central, needle-like projection. Pharynx divided into shorter, narrower muscular region and longer wider glandular region. Pharyngo-intestinal valve projects into the intestine.

Male (figs 4, 5, 8–11; measurements based on three specimens): body 16.04–17.40 mm long, 0.328–0.336 mm wide at level of posterior end of pharynx. Head 0.120 mm wide. Buccal cavity 0.044–0.048 mm wide in lateral view; 0.080 mm at proximal margin, 0.016 mm at distal margin in dorso-ventral view; 0.036–0.044 mm deep. Pharynx 5.38–5.65 mm long; anterior muscular region 0.504–0.520 mm long. Anterior to cervical papillae, nerve ring and secretory–excretory pore 0.076–0.088 mm, 0.256–0.312 mm and 0.300–0.360 mm respectively. Spicules unequal, dissimilar, right 0.335–0.390 mm with bluntly pointed tip, left 1.27–1.47 mm with sharply pointed tip. Gubernaculum 0.056–0.072 mm long, irregular in shape. Ventral surface of posterior end ornamented with longitudinal and oblique cuticular ridges. Papillae arranged on ventral surface at posterior end. Four pairs of precloacal, two pairs of postcloacal pedunculate papillae present. Four pairs of small, sessile papillae in cluster near tail tip. Phasmids between first, from anterior,

and second pair of sessile papillae. Tail 0.240–0.304 mm long, curved ventrally.

Female (figs. 1–3, 6, 7; measurements based on two specimens): body length 23.06–23.86 mm, 0.456–0.460 mm wide at level of posterior end of pharynx. Head 0.152–0.160 mm wide. Buccal cavity 0.080 wide in lateral view; 0.080 mm at proximal margin, 0.008 at distal margin in dorso-ventral view; 0.052–0.056 mm deep. Pharynx 5.98–6.34 mm long; anterior muscular region 0.496–0.520 mm long. Anterior to cervical papillae, nerve ring and secretory-excretory pore 0.088–0.104 mm, 0.260–0.344 mm and 0.356–0.416 mm respectively. Vulva opens 10.53–11.33 mm from anterior end. Uterus divides 1.15 mm from proximal end. Undivided uterus opens into short ovejector. Vulva forms simple pore on body surface. Tail 0.280–0.304 mm long, bluntly pointed. Phasmids 0.040–0.096 mm from distal tip. Eggs 0.042–0.044 mm × 0.026–0.027 mm, thick-walled, slightly flattened on one side.

Type host. Saker falcon, *Falco cherrug*.

Habitat. Stomach.

Locality. Saudi Arabia.

Etymology. Species named after type host.

Deposition of type specimens. The Natural History Museum, London, UK, collection numbers – holotype 2003.3.27.1, paratypes 2003.3.27.2–4.

Larvae

(figs 12–21)

Description. (based on three whole specimens and two large fragments). Body coiled, 13.58–16.37 mm long; 0.360–0.392 mm wide at level of pharyngo-intestinal junction. Head 0.054–0.072 mm wide. Mouth oval, laterally compressed. Cephalic sensory organs consists of two pairs of large submedian papillae, two lateral amphids. Buccal capsule compressed laterally, 0.040–0.048 mm wide, 0.028–0.038 mm long in lateral view; funnel-shaped in dorso-ventral view, 0.066 mm long (one specimen), 0.014 mm at anterior rim, narrowest width near base of 0.006 mm. Six teeth present on proximal margin of buccal capsule, three on each lateral margin. Anterior to cervical papillae, nerve ring and secretory-excretory pore 0.074–0.122 mm, 0.226–0.232 mm and 0.268–0.300 mm respectively. Pharynx 4.70–5.48 mm long. Pharyngo-intestinal valve projects into the intestine. Tail 0.160–0.200 mm long, terminal knob present.

Host. Houbara bustard, *Chlamydotis undulata macqueeni*.

Habitat. Under skin between legs, neck, back and overlying muscles of upper hind limb.

Locality. Pakistan at the Rahim Yar Khan Rehabilitation Center (Houbara Foundation International, Lahore, Pakistan).

Deposition of specimens. The Natural History Museum, London, UK, collection number 2003.3.27.5–6.

Pathology. Sections of muscle show extramuscular encysted parasitic nematodes on the epimysial aspect. The parasites are surrounded by a dense connective tissue capsule 500–750 μm thick, with no significant inflammatory infiltrate (fig. 21). Several sections of muscle showed similar features. The parasitic nematodes stained strongly with PAS. No acid-fast organisms were seen on the ZN stain. The Gram stain did not reveal any bacterial organisms associated with the lesion.

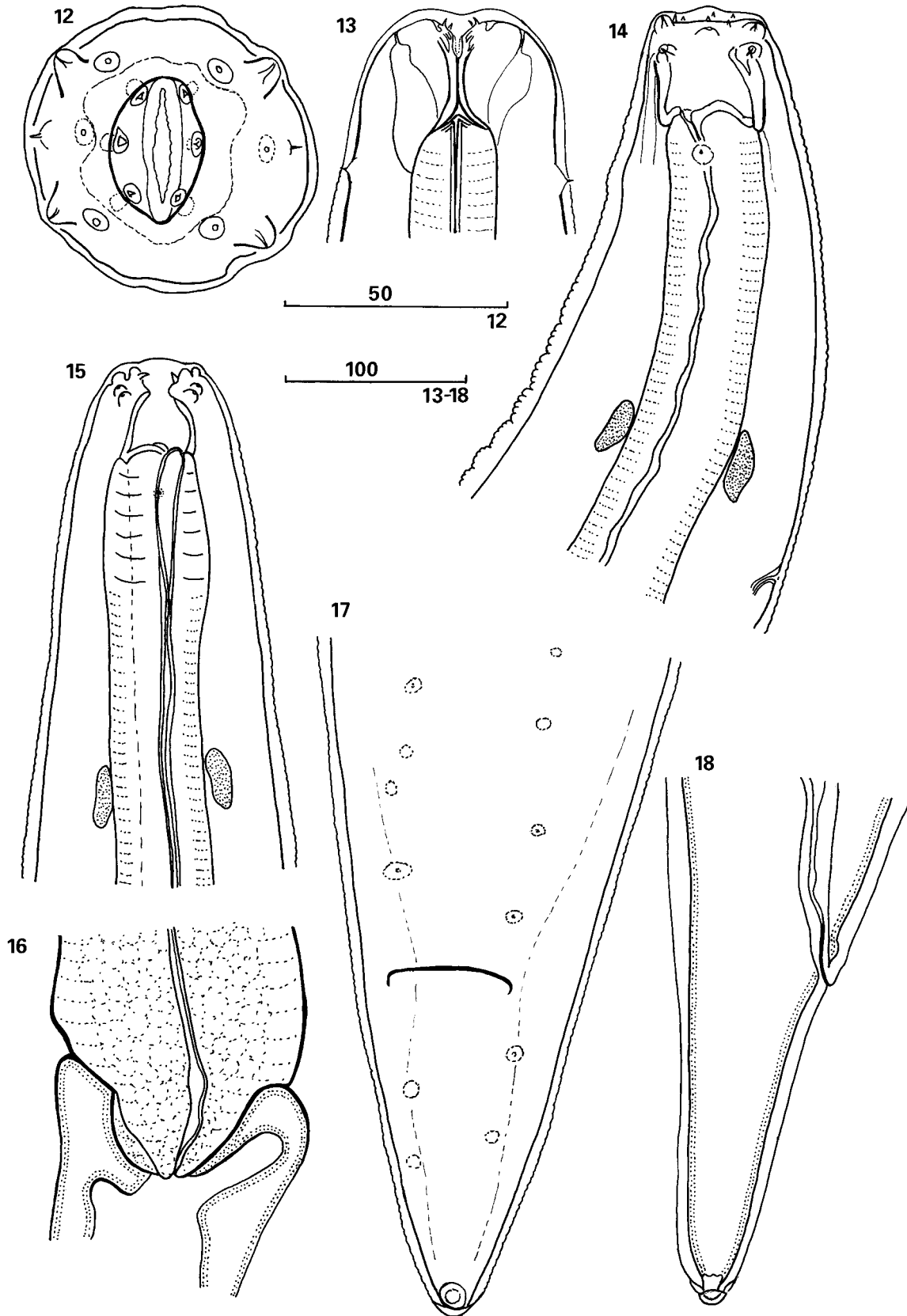
Discussion

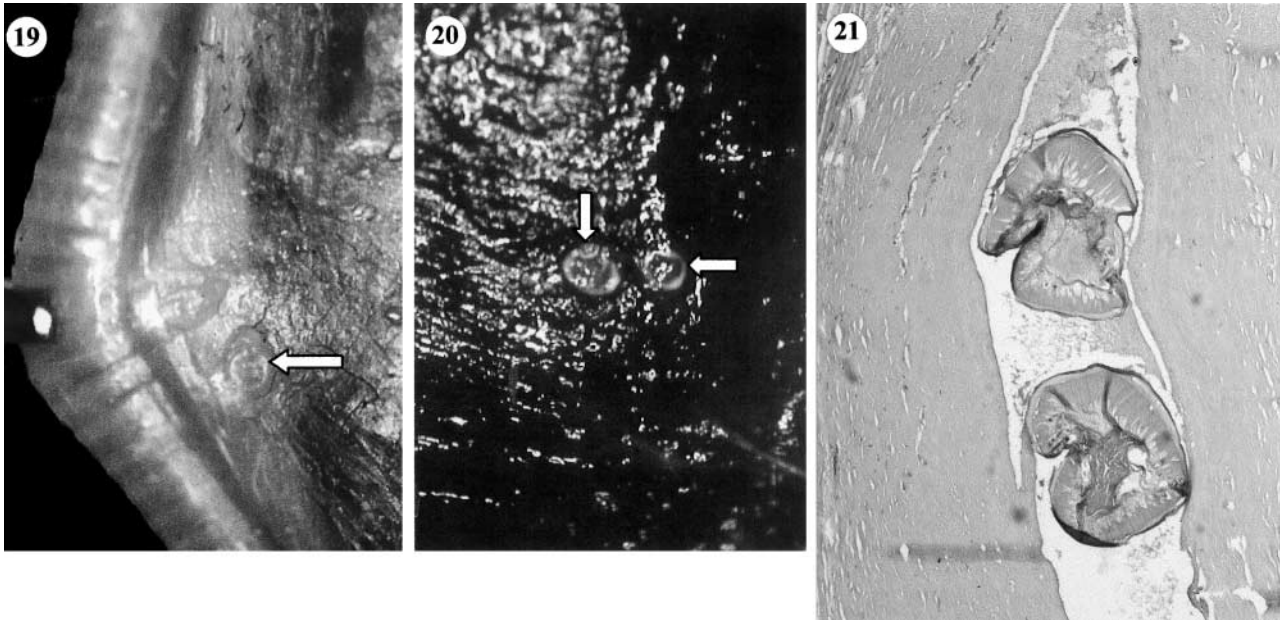
Adults

Chabaud *et al.* (1963) established the genus *Spiralatus* for a single species *S. baeri* from *Leptosomus discolor* in Madagascar on the basis of a mouth without median lobes, an oval buccal capsule with six teeth on the under rim of the lips, a long pharynx clearly divided into muscular and glandular regions, large cervical papillae positioned near the anterior end, the presence of large lateral alae, the vulva opening in the middle of the body, the female tail with a spinous tip, the females being viviparous, the male tail with large caudal alae, caudal papillae arranged in a typical primitive spirurid format, the presence of unequal spicules and a gubernaculum. These features, coupled with the specimens having been recovered from an avian host and not a mammalian host, separated the genus from other members of the subfamily Spirurinae, the subfamily to which the genus was considered to correspond. Later Chabaud (1975) moved the genus to the family Spirocercidae (Chitwood & Wehr, 1932 subfamily) and the subfamily Spirocercinae Chitwood & Wehr, 1932.

The specimens described are similar to the genus *Spiralatus* in the presence of cervical papillae close to the anterior end, large lateral alae, long pharynx with distinct muscular and glandular regions, unequal spicules, large caudal alae on the male tail, large pedunculate caudal papillae arranged in a typical spirurid format and the vulva opening in the middle of the body. The specimens described differ mainly in the features of the cephalic region. They can be distinguished from *Spiralatus* in the absence of a cephalic vesicle, the presence of distinct pseudolabia, the shape of the buccal capsule (cylindrical in *Spiralatus*, funnel-shaped in the present specimens), the general body measurements including the spicules (spicules 0.240 mm and 0.520 mm in *Spiralatus baeri*, 0.335–0.390 mm and 1.27–1.47 mm in the present specimens), the absence of spines on the female tail and being oviparous not viviparous.

Chabaud (1975) states that 'the classification of the Spirurida is based mainly on cephalic features'. Chabaud & Bain (1994) discuss the evolutionary expansion of the order Spirurida and underline the value of the cephalic structures and sensory organs referring to the studies of Chabaud (1959), who used these features in his classification of the Spiruroidea, and Quentin (1971), who supported this classification





Figs 19–21. *Paraspiralatus sakeri* n. g., n. sp., larvae. 19, 20, Larvae (arrowed) in the subcutaneous connective tissue of the neck of houbara bustard; 21, histological section of the subcutis over the thigh musculature (HB 35) including two transverse sections of the larval nematode, surrounded by a prominent fibrous reaction but without significant inflammation. Haemotoxylin and eosin, $\times 10$ objective.

by his studies on the morphology of this region in larval development.

In view of the importance of cephalic features for the classification of the Spirurida, the presence of pseudolabia, the absence of a cephalic vesicle and the shape of the buccal capsule indicate these specimens belong to a separate genus and the name *Paraspiralatus* is proposed with *Paraspiralatus sakeri* for the type and only species named after the host from which the specimens were recovered.

Following the classification of Chabaud (1975) and the shared features with the genus *Spiralatus*, the genus is also assigned to the family Spirocercidae and subfamily Spirocercinae. Chabaud (1975) separates the family Spirocercidae from the Spiruridae on the basis of the buccal capsule (laterally flattened in Spiruridae, not in Spirocercidae), the oral opening (dorso-ventrally elongate in the Spiruridae, hexagonal in the Spirocercidae), and the presence or absence of teeth (absent in the buccal capsule of Spiruridae, generally present in Spirocercidae). In view of the presence of distinct pseudolabia and a laterally flattened buccal capsule, the new genus appears to have some intermediary characters shared with other families within the Spiruroidea.

Larvae

According to Anderson (2000) the third stage larvae of the Spiruroidea are generally large and possess some of

the cephalic features of the adult. Examination of the immature nematodes from the houbara bustards revealed cervical papillae near the anterior end, four pairs of large submedian cephalic papillae, a pair of lateral amphids, a laterally compressed buccal capsule which is funnel-shaped in dorso-ventral view, six teeth on the proximal margin of the buccal capsule, a long pharynx and the pharyngo-intestinal valve projecting into the intestine all similar features to the adults described. For these reasons the larvae are considered to be third stage larvae belonging to the same species as the adults described from the saker falcon.

Members of the superfamily Spiruroidea require an insect intermediate host for their transmission and development (Anderson, 2000). Anderson (2000) also indicates that 'paratenesis is a common phenomenon in the transmission of spiruroids and the third stage larvae of several species have been found in tissues of a variety of vertebrates which ingest infected insects'. In view of this and the recovery of these nematodes from only two of the birds examined in the houbara bustard study in Pakistan, the bustards are considered paratenic hosts for this species. This is further supported by the likelihood of houbara bustards only rarely being prey of wild saker falcons, although trained female saker falcons, larger than the males, will catch houbara bustards. Juvenile houbara bustards are commonly predated in the wild by long-legged buzzards (*Buteo*

Figs 12–18. *Paraspiralatus sakeri* n. g., n. sp. larvae. 12, *En face* view; 13, cephalic region, dorso-ventral view, optical section at level of amphids; 14, anterior end, lateral view; 15, anterior end showing different stage of development of buccal capsule and proximal pharynx, lateral view; 16, pharyngo-intestinal junction; 17, posterior end showing primordia of caudal papillae, ventral view; 18, lateral view of tail. Scale bars in microns.

rufinus) and eagles (Olivier Combreau, personal communication) and it is possible that these may be definitive hosts for this parasite.

Acknowledgements

We thank our colleagues from the Houbara Foundation International and Dr Olivier Combreau from the National Avian Research Center (NARC) for his assistance. Tom Bailey was employed by the NARC when the larval samples were collected and he would like to thank Mr M. Al Bowardi, ERWDA Managing Director, for his support of the veterinary science programme of NARC from 1993–2001. We would also like to thank Professor D.E. Jacobs of The Royal Veterinary College, University of London, UK for his constructive comments on the draft manuscript.

References

- Anderson, R.C.** (2000) *Nematode parasites of vertebrates their development and transmission*. 2nd edn. xx + 650 pp. Wallingford, Oxon, CAB International.
- Chabaud, A.G.** (1959) Phénomène d'évolution régressive des structures céphaliques et classification des nematodes Spiruroidea. *Parassitologia* **1**, 11–20.
- Chabaud, A.G.** (1975) No. 3. Keys to genera of the order Spirurida. Part. 2. Spiruroidea, Habronematoidea and Acuaroidea. pp. 29–58 in Anderson, R.C., Chabaud, A.G. & Willmott, S. (Eds) *CIH Keys to the nematode parasites of vertebrates*. Farnham Royal, Bucks, Commonwealth Agricultural Bureaux.
- Chabaud, A.G. & Bain, O.** (1994) The evolutionary expansion of the Spirurida. *International Journal for Parasitology* **24**, 1179–1201.
- Chabaud, A.G., Brygoo, E.R. & Durette, M.C.** (1963) Spirurides parasites d'oiseaux malgaches. *Annales de Parasitologie Humaine et Comparée* **37**, 93–108.
- Gibbons, L.M.** (2002) Chapter 2. General organisation. pp. 31–59 in Lee, D.L. (Ed.) *The biology of nematodes*. London and New York, Taylor and Francis.
- Quentin, J.C.** (1971) Sur les modalités d'évolution chez quelques lignées d'helminthes de rongeurs Muroidea. *Cahiers de l'Office de la Recherche Scientifique et Technique Outre-mer, Entomologie Médicale et Parasitologie* **9**, 103–176.

(Accepted 1 August 2003)
© CAB International, 2004