


Sule Arıcı¹ , Figen Akalın² and Bilgen Bilge Geckinli³

Brief Report

Cite this article: Arıcı S, Akalın F, and Geckinli BB (2024) A case of Carvajal syndrome presenting with dilated cardiomyopathy. *Cardiology in the Young* **34**: 1131–1133. doi: [10.1017/S1047951124000222](https://doi.org/10.1017/S1047951124000222)

Received: 30 June 2023
Accepted: 4 February 2024
First published online: 4 March 2024

Keywords:

Carvajal syndrome; dilated cardiomyopathy; arrhythmia

Corresponding author:

S. Arıcı; Email: dr.suledarende@gmail.com

¹Pediatric Cardiology, Kartal Kosuyolu Training and Research Hospital, Istanbul, Turkey; ²Pediatric Cardiology, Marmara University School of Medicine, Istanbul, Turkey and ³Medical Genetics, Marmara University School of Medicine, Istanbul, Turkey

Abstract

Objectives: Carvajal syndrome is a very rare autosomal recessive cardiocutaneous disorder caused by a desmosomal mutation in exon 24 of the desmoplakin gene. It manifests with woolly hair, epidermolytic palmoplantar keratoderma, and arrhythmogenic right ventricular cardiomyopathy. We herein present a patient with heart failure and dilated cardiomyopathy who was diagnosed with Carvajal syndrome because of dermatologic manifestations. **Case Presentation:** A seven-year-old girl was referred to our clinic due to decompensated heart failure and clinical deterioration. The patient had severe weakness, tachycardia, and tachypnea. She had a complaint of getting tired quickly for three weeks, and she had shortness of breath and abdominal pain for the last two days. She had hepatomegaly and woolly hair. Mild keratoderma was present on the soles of her feet. Echocardiography demonstrated biventricular dilatation, significantly impaired left ventricular systolic function (ejection fraction 22%), and moderate to severe mitral and tricuspid regurgitation. Molecular genetic evaluation was performed because of cutaneous and cardiac findings, which demonstrated a desmoplakin gene mutation. Homozygous mutation *c.4297C > T* (p.Gln1433*) was identified in desmoplakin gene, and the diagnosis of Carvajal syndrome was confirmed. **Conclusions:** Syndromic types of arrhythmogenic right ventricular cardiomyopathy such as Carvajal syndrome are rare diseases. Awareness about cutaneous manifestations and genetic evaluation would help diagnosis and prevention of sudden death. Genetic counselling is needed in familial cases.

Arrhythmogenic right ventricular dysplasia/cardiomyopathy is characterised by the progressive fibro-fatty degeneration of the right ventricular myocardium as well as ventricular arrhythmia originating from the right ventricle. Clinical genetic studies suggest that at least 60 per cent of arrhythmogenic right ventricular cardiomyopathy cases are familial with autosomal dominant inheritance. Moreover, the syndromic types of arrhythmogenic right ventricular dysplasia, such as Naxos disease and Carvajal syndrome, are autosomal recessive inherited diseases with associated cutaneous manifestations. Although the right ventricular myocardium is the main target of arrhythmogenic right ventricular dysplasia/cardiomyopathy, left ventricular dysfunction and myopathy may also occur. Carvajal syndrome is a very rare autosomal recessive cardiocutaneous disorder that is caused by a desmosomal mutation in exon 24 of the desmoplakin gene. It is characterised by woolly hair, epidermolytic palmoplantar keratoderma, and arrhythmogenic right ventricular cardiomyopathy.^{1,2}

This case report concerns a patient who presented with heart failure and dilated cardiomyopathy and who was diagnosed with Carvajal syndrome as a result of dermatologic manifestations.

Case report

A seven-year-old female patient was referred to our clinic due to decompensated heart failure and clinical deterioration. The patient exhibited severe weakness, tachycardia, and tachypnoea. She had complained of becoming tired very quickly for three weeks, and she had reported shortness of breath and abdominal pain over the last two days. Her parents were consanguineous (first-degree cousins). A physical examination performed at the time of admission revealed that the patient's heart rate was 150 bpm, respiratory rate was 50 breaths per minute, blood pressure was 60/40 mmHg, and oxygen saturation was 91 per cent on room air. Moreover, a 2/6 systolic murmur and galloping rhythm were heard during auscultation of the mesocardial focus. The patient had hepatomegaly and woolly hair (Fig. 1). Furthermore, mild keratoderma was present on the soles of her feet. Teleradiography revealed severe cardiomegaly (cardiothoracic ratio: 0.70), and the patient's pulmonary vascular markings were found to be increased. Electrocardiography showed left axis deviation, wide and pointed P waves, a

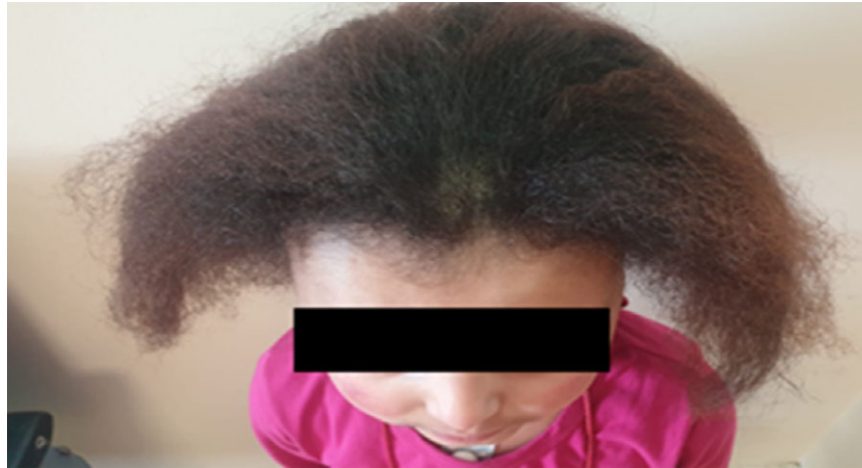

Figure 1. Woolly hair of the patient.

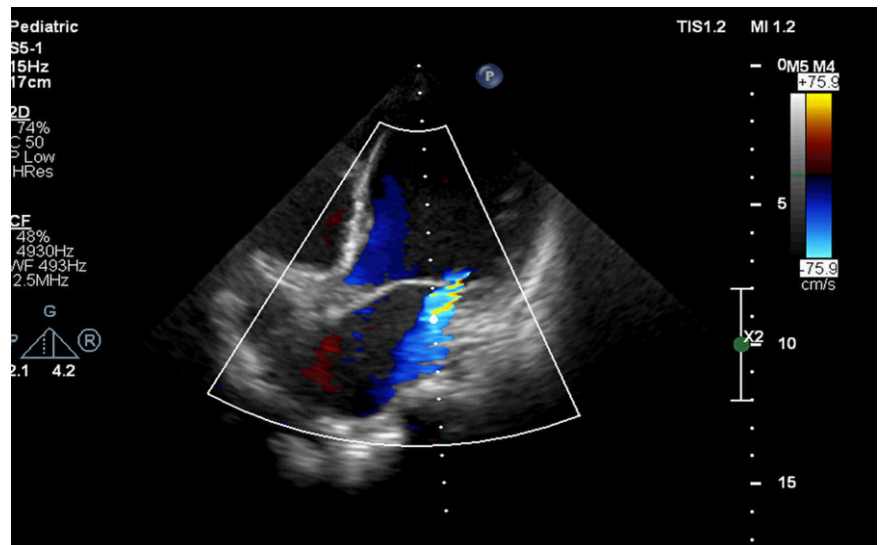


Figure 2. Echocardiographic views showing left ventricular dilatation and dysfunction.

prolonged PR interval, flattened T waves, and low-voltage QRS complexes. Echocardiography demonstrated biventricular dilatation, significantly impaired left ventricular systolic function (ejection fraction: 22 per cent), and moderate to severe mitral and tricuspid regurgitation (Fig. 2). Cardiac MRI demonstrated the global hypokinesia of both ventricles, while midmyocardial contrast enhancement was observed on the left ventricle and interventricular septum. Multifocal ventricular extrasystoles were detected via the 24-hour Holter recordings.

The patient responded well to the prescribed anticongestive medications and her heart failure was controlled. As a result, the patient's clinical condition improved. Yet, echocardiography showed left ventricular systolic dysfunction to persist. A molecular genetic evaluation was performed due to the cutaneous and cardiac findings, which revealed a desmoplakin gene mutation. More specifically, the homozygous mutation *c.4297C > T* (p.Gln1433*) was identified in the desmoplakin gene, which meant that the diagnosis of Carvajal syndrome was confirmed. As a consequence, an implantable cardioverter defibrillator and transfer to cardiac transplantation centre were planned in order to prevent sudden cardiac death. However, the family rejected both treatment

modalities, and eventually, we lost the patient with an acute exacerbation of heart failure due to non-compliance to medical treatment two years after diagnosis.

Discussion

Arrhythmogenic right ventricular cardiomyopathy is a genetic form of primary cardiomyopathy. Clinical studies have shown that at least 60 per cent of arrhythmogenic right ventricular cardiomyopathy cases are familial with autosomal dominant inheritance. Moreover, the syndromic types of arrhythmogenic right ventricular dysplasia are autosomal recessive diseases with cutaneous manifestations, including Naxos disease and Carvajal syndrome.²

As it is a rare disease, no clinical studies concerning Carvajal syndrome are available in the literature. Thus, the reporting of new cases represents a valuable means of increasing clinicians' awareness of the disease. To date, the number of reported cases of arrhythmogenic right ventricular cardiomyopathy stands at 45, while the mutation found in our patient has not previously been reported.

The genetically defective desmosomal proteins found in arrhythmogenic right ventricular cardiomyopathy patients result in the dissociation and death of the myocytes, eventually leading to fibrous and adipose tissue infiltration.³ Mutations in the desmoplakin gene encoding desmoplakin cause Carvajal syndrome, a cardiocutaneous form of arrhythmogenic right ventricular cardiomyopathy. Carvajal syndrome is an autosomal recessive hereditary disease, although rare autosomal dominant forms accompanied by dental anomalies have also been reported.⁴ During the genetic analysis, the homozygous mutation c.4297C > T (p.Gln1433*) was detected in our patient's desmoplakin gene. This mutation has not previously been reported. A heterozygous mutation of the same gene was detected in the patient's mother and brother. A genetic analysis of her father could not be performed because he died during the ongoing war in Syria (non-cardiac death).

Carvajal syndrome is characterised by left ventricular involvement, epidermolytic palmoplantar keratoderma, and woolly hair.⁵ In the literature, cases involving left ventricular hypertrabeculation/noncompaction and biventricular cases have also been reported.^{2,6–8} In our patient, biventricular involvement was evident.

The clinical symptoms of Carvajal syndrome are caused by structural and functional abnormalities in the right ventricle and arrhythmias, which can lead to sudden death. The most important treatment strategy following a diagnosis of arrhythmogenic right ventricular cardiomyopathy involves the prevention of sudden cardiac death (SCD). Neither antiarrhythmic drugs that suppress ventricular arrhythmias nor catheter ablation that eliminates the arrhythmic substrate are successful in preventing sudden cardiac death. In addition, due to the progressive nature of the disease, new arrhythmogenic substrates may emerge. Therefore, the only effective means of preventing sudden cardiac death is implantable cardioverter defibrillator implantation.^{9,10} In patients with severe ventricular dysfunction, heart transplantation may be considered. Implantable cardioverter defibrillator implantation and cardiac transplantation were planned for our patient, however, could not be performed.

In conclusion, while the syndromic types of arrhythmogenic right ventricular cardiomyopathy, including Carvajal syndrome, remain a rare disease, increasing clinicians' awareness of cutaneous

manifestations and the benefits of genetic evaluation would help with the diagnosis of arrhythmogenic right ventricular cardiomyopathy and, therefore, with the prevention of sudden death among patients. Moreover, genetic counselling should be provided in familial cases.

References

1. Norgett EE, Hatsell SJ, Carvajal-Huerta L, et al. Recessive mutation in desmoplakin disrupts desmoplakin-intermediate filament interactions and causes dilated cardiomyopathy, woolly hair and keratoderma. *Hum Mol Genet* 2000; 9: 2761–2766.
2. Kaplan SR, Gard JJ, Carvajal-Huerta L, Ruiz-Cabezas JC, Thiene G, Saffitz JE. Structural and molecular pathology of the heart in Carvajal syndrome. *Cardiovasc Pathol* 2004; 13: 26–32.
3. Que D, Yang P, Song X, Liu L. Traditional vs. genetic pathogenesis of arrhythmogenic right ventricular cardiomyopathy. *Europace* 2015; 17: 1770–1776.
4. Finsterer J, Stollberger C, Wollmann E, Dertinger S, Laccone F. Autosomal dominant Carvajal plus syndrome due to the novel desmoplakin mutation c.1678A > T (p.Ile560Phe). *Mol Genet Metab Rep* 2016; 8: 1–3.
5. Garcia-Pavia P, Syrris P, Salas C, et al. Desmosomal protein gene mutations in patients with idiopathic dilated cardiomyopathy undergoing cardiac transplantation: a clinicopathological study. *Heart* 2011; 97: 1744–1752.
6. Mohammadpour B, Ahranjani P, Moradi S, Nazari S, Farshadfar A. A nine-year-old girl with left ventricle non-compaction and skin lesions (Carvajal syndrome). *Iran J Pediatr* 2015; 25: e370.
7. Williams T, Machann W, Kuhler L, et al. Novel desmoplakin mutation: juvenile biventricular cardiomyopathy with left ventricular non-compaction and acantholytic palmoplantar keratoderma. *Clin Res Cardiol* 2011; 100: 1087–1093.
8. Nehme N, Malti RE, Roux-Buisson N, Cagnault JR, Bouvagnet P. Evidence for genetic heterogeneity in Carvajal syndrome. *Cell Tissue Res* 2012; 348: 261–264.
9. Bhonsale A, James CA, Tichnell C, et al. Incidence and predictors of implantable cardioverter-defibrillator therapy in patients with arrhythmogenic right ventricular dysplasia/cardiomyopathy undergoing implantable cardioverter-defibrillator implantation for primary prevention. *J Am Coll Cardiol* 2011; 58: 1485–1496.
10. Erolu E, Akalin F, Cevik BS, Yucelten D. Arrhythmogenic right ventricular dysplasia, cutaneous manifestations and desmoplakin mutation: Carvajal syndrome. *Pediatr Int* 2018; 60: 987–989.