

The spectrum of psychiatric manifestations in subacute sclerosing panencephalitis: A systematic review of published case reports and case series

Review

Cite this article: Garg RK, Kar SK, Malhotra HS, Pandey S, Jain A, Rizvi I, Uniyal R, and Kumar N (2024). The spectrum of psychiatric manifestations in subacute sclerosing panencephalitis: A systematic review of published case reports and case series. *CNS Spectrums* 29(2), 87–95. <https://doi.org/10.1017/S1092852924000038>

Received: 10 October 2023



Accepted: 23 November 2023

Keywords:

Catatonia; Extrapyrimal disorder; Myoclonus; Measles; schizophrenia; encephalitis

Corresponding author:

Ravindra K. Garg;
Email: garg50@yahoo.com

Ravindra K. Garg¹ , Sujita K. Kar² , Hardeep S. Malhotra¹, Shweta Pandey¹, Amita Jain³, Imran Rizvi¹, Ravi Uniyal¹ and Neeraj Kumar¹

¹Department of Neurology, King George's Medical University, Lucknow, India, ²Department of Psychiatry, King George's Medical University, Lucknow, India and ³Department of Microbiology, King George's Medical University, Lucknow, India

Abstract

Data related to psychiatric manifestations in subacute sclerosing panencephalitis (SSPE) is currently available only in the form of isolated case reports. In this systematic review, we evaluated the spectrum of psychiatric manifestations and their impact on the course and outcome of SSPE. Data were obtained from 4 databases (PubMed, Embase, Scopus, and Google Scholar), with the most recent search conducted on March 27, 2023. The PRISMA guidelines were followed, and the PROSPERO registration number for the protocol is CRD42023408227. SSPE was diagnosed using Dyken's criteria. Extracted data were recorded in an Excel spreadsheet. To evaluate the quality of the data, the Joanna Briggs Institute Critical Appraisal tool was employed. Our search resulted in 30 published reports of 32 patients. The mean age was 17.9 years. Schizophrenia, catatonia, and poorly characterized psychotic illnesses were the 3 most common psychiatric presentations that were seen in 63% (20/32) of cases. Catatonia was seen in 4 patients. Affective disorders, mania, and depression were reported among 22% (7/32) cases. In approximately 81% (26/32) cases, the course of SSPE was acute fulminant. Treatment with antipsychotic drugs had poor or no response. Out of 17 patients, who received antipsychotic drugs, 6 patients noted severe extrapyramidal adverse effects. SSPE often masquerades as a psychiatric disorder. Unresponsive psychiatric symptoms, early extrapyramidal signs, and progressive encephalopathy indicate SSPE.

Introduction

Subacute sclerosing panencephalitis (SSPE) is a relentlessly progressive brain disorder caused by the defective measles virus. SSPE is common in measles-endemic areas.¹ SSPE usually presents with progressive cognitive deterioration and myoclonus. Children between 8 and 12 years of age are more frequently affected. SSPE is generally fatal within 1 to 3 years from the onset. However, long-term spontaneous remission and stabilization of disease course occurs in about 6% of patients. In an acute-fulminant variant of SSPE, the patient either dies or becomes akinetic mute within 6 months of disease onset. Electroencephalography (EEG) reveals periodic discharges. Brain imaging reveals periventricular T2/FLAIR white matter abnormalities. The advanced stage of SSPE is characterized by marked brain atrophy. A definitive diagnosis needs the demonstration of elevated measles antibody titers in the cerebrospinal fluid (CSF).^{1,2} Infrequently, psychiatric manifestations (like mania, psychosis, catatonia, and malingering) have also been reported in many SSPE patients. In this systematic review, we evaluated the spectrum of psychiatric manifestations of SSPE.

Material and methods

Protocol registration

We conducted a thorough analysis of published case reports and case series of SSPE patients, who either had psychiatric manifestations at the time of diagnosis or who later developed psychiatric manifestations. We used the Preferred Reporting Items for Systematic Reviews and Meta-Analyses (PRISMA) standards for our systematic review. The protocol was made pre-registered in PROSPERO (CRD42023408227).³

Literature search

A literature search was done in the databases of PubMed, Scopus, Embase, and Google Scholar. In the Google Scholar database, first 50 pages were screened for relevant articles. No language restrictions were imposed, while databases are searched. Articles, other than in English language were translated into English with the help of “A Google translator.”

The following search items were used in our search strategy: (((((((((((((PSYCHIATRIC) OR (Neuropsychiatric)) OR (Schizophrenia)) OR (Mania)) OR (Psychosis)) OR (Depression)) OR (Catatonia)) OR (Attention deficits)) OR (Anxiety)) OR (Panic attacks)) OR (Sleep disorders)) OR (Nightmares)) OR (Parasomnias)) AND (SSPE). The date of the last search was March 27, 2023.

Exclusion criteria

The articles that were omitted, included editorials, comments on previously published cases, and review articles. Conference abstracts were also not taken into account.

Data extraction

The study was conducted in 2 stages. Titles and abstracts were assessed by 2 independent reviewers in the initial phase (RK and IR). The full texts of the chosen papers were then examined by an additional set of 2 reviewers to determine their eligibility following the inclusion criteria (RK and IR). A third author was brought in to settle any differences between the 2 authors (AJ).

Dyken's criteria were used to identify cases with a confirmed diagnosis of SSPE.⁴ Studies were considered if they fulfilled the following criteria: (a) they were case reports or case series; (b) they described cases of psychiatric manifestations in a case of SSPE; (c) cohort studies were included only if, individual patient data were available; and (d) they comprehensively described the psychiatric manifestations in confirmed SSPE cases. Acute fulminant SSPE refers to a rapidly progressing condition where a patient either becomes akinetic mute or dies within 6 months of disease onset.²

Quality of studies

The critical appraisal checklist for case reports and case series given by the Joanna Briggs Institute (JBI) was used to assess the quality of published case reports.

The critical appraisal tool we used was an 8-item scale including the patient's demographic characteristics, clinical details, details of laboratory workup, the treatment administered, the follow-up clinical condition, adverse events, and the main takeaways from the case reports. Each of these criteria was used to evaluate every case. “Yes” or “No” was indicated for each point.⁵ Two independent reviewers (SKK and RU) assessed the quality of the included cases, and any disagreements between them were resolved by mutual agreement. If still there was a dispute, it was resolved via discussion with a third reviewer (AJ).

Data analysis

Each patient's demographic information, history of measles infection or vaccination in infancy, length of illness, type of psychiatric manifestations, workup procedures, results of neuroimaging, and

course and outcome were all noted. Four reviewers (RK, IR, HSM, and RU) completed all of them; in the event of a disagreement, assistance from a fifth reviewer was sought (AJ). To manage duplicate records, the web tool EndNote 20 (Clarivate Analytics) was employed. Two reviewers independently completed this process once more (SKK and AJ). Any problems were rectified with the assistance of another reviewer. A PRISMA flow chart was used to present the number of records that were retrieved and evaluated at each stage. PRISMA flow chart was prepared with the help of EndNote 20 (Clarivate Analytics) (Figure 1).

We used Microsoft Excel software, for data analysis. The necessary data was taken out and put together in an Excel document. The information we compiled included the first author, the nation of the report, the demographics of the patients, the status of childhood measles vaccination, childhood measles infection, length of illness, types of psychiatric manifestations, other clinical presentations, specifics of the reported diagnostic workup, neuroimaging, and the outcome. We focussed on the descriptive and qualitative aspects of the data. Frequencies and percentages were employed to represent the categorical variables. Means, medians, or ranges were employed for reporting continuous variables.

Results

Our search resulted in 30 reports with information on 32 patients (Supplementary Item 1 and Table 1).^{6–35} We compiled our data as per PRISMA standards (Supplementary Item 2). Figure 1 shows the PRISMA flowchart for our systematic review. Table 2 and Figure 2 summarize the demographic, clinical, neuroimaging, and brain biopsy information of SSPE cases with psychiatric manifestations.

Supplementary Item 3 contains the critical appraisal report of each included case, according to the Joanna Briggs Institute (JBI) checklist. In an 8-item scale, the majority of cases (26/32) complied with all the points. Only 6 cases faltered on the point “post-intervention clinical condition.”

The mean age of SSPE patients was 17.9 years (median 15 years and range 2–62 years). Men outnumbered the females (21: 11). The majority (94%) of SSPE patients with psychiatric presentations either did not have childhood measles vaccination, or a reliable vaccination history was not retrievable. In one-third of instances, childhood measles infection was reported by relatives. The majority of reports (73.3%) on SSPE patients with psychiatric presentations were from Turkey and India. After the year 2005, all such reports were reported exclusively from these 2 countries only.

Schizophrenia, catatonia, and poorly characterized psychotic illnesses were the 3 most common psychiatric presentations, these were seen in approximately 63% (20/32) of cases. Catatonia was seen in approximately 13% (4/32) of patients. Affective disorders, mania, and depression were reported among 22% (7/32) cases. In 81% (26/32) cases, the course of SSPE was acute fulminant.

Neuroimaging abnormalities were detected in 63% (10/16) of patients, periventricular T2/FLAIR MR hyperintensities were the most frequently noted abnormalities. Brain biopsy findings were noted in 3 patients. On histopathological examination of brain tissue, inflammatory cell infiltration, an increase in activated microglial cells, diffuse or focal demyelination, the presence of inclusion bodies in neurons and oligodendroglia as well as evidence of neuronal loss.

Treatment with antipsychotic drugs had poor or no response. Out of 17 patients who received antipsychotic drugs 6 (35%) patients noted severe extrapyramidal adverse effects. The

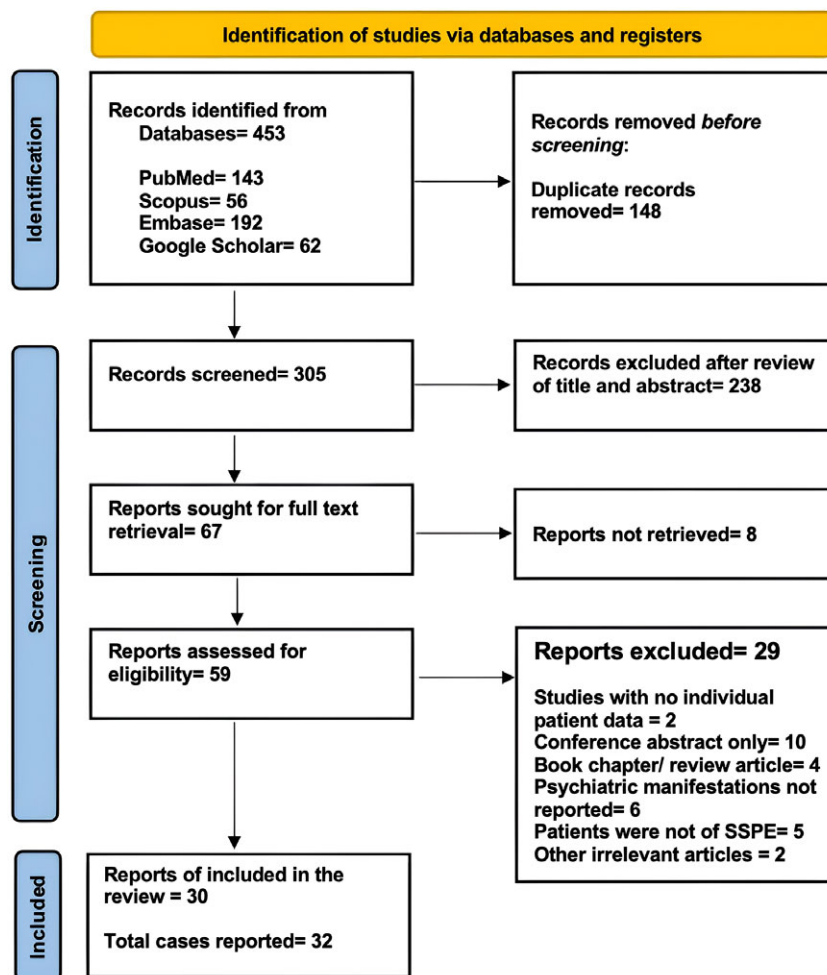


Figure 1. PRISMA flow diagram of the study shows the process of article selection for systematic review.

extrapyramidal side effects observed soon after initiating antipsychotic treatment included cervical dystonia, sialorrhea, static tremor, and cogwheel rigidity.

Discussion

In this systematic review, we noted that patients with SSPE were mistakenly referred to psychiatric care because of their initial psychiatric presentations. The majority (83%) of patients received diagnoses of affective disorders, including mania and depression, as well as psychotic diseases like schizophrenia, catatonia, and poorly defined psychotic illnesses. In these patients, treatment with antipsychotic drugs often failed. Instead, 35% of patients experienced severe extrapyramidal adverse effects.

Our review found that schizophrenia was the most common psychiatric diagnosis for many cases of SSPE. Schizophrenia is a mental disorder characterized by delusions, hallucinations, disorganized thinking, and other symptoms. Anti-*N*-methyl-D-aspartate (NMDA) receptor encephalitis is another brain disorder that can cause similar symptoms. It is often misdiagnosed as a psychiatric disorder, just as SSPE was in our review. NMDA receptor encephalitis is characterized by psychotic and affective symptoms, catatonic signs, and mental decline. It is also often associated with seizures, abnormal movements, and a fluctuating

course. Fulminant SSPE can mimic NMDA receptor encephalitis, making it difficult to distinguish between the 2 conditions.³⁶⁻³⁸ Should a patient with progressive encephalopathy develop classic periodic myoclonus, it is imperative to examine the CSF for anti-measles antibodies.

The pathophysiology of underlying schizophrenia in SSPE is difficult to elucidate. Schizophrenia is typically a long-term psychiatric disorder involving a breakdown in the relation between thought, emotion, and behavior, leading to faulty perception, inappropriate actions and feelings, withdrawal from reality and personal relationships into fantasy and delusion, and a sense of mental fragmentation.

The term “schizophrenia-like behavior” refers to a variety of symptoms that resemble schizophrenia but might not fully satisfy its diagnostic criteria. Delusions, chaotic speech or thought patterns, and social disengagement are examples of this. People may experience paranoia, hear voices, or have unfounded ideas that are at odds with reality. They may have trouble focusing or remembering things, and their speech may be irrational or nonsensical. These behaviors have a major impact on daily activities, work, and social interactions. They may be temporary or indicative of deeper underlying disorders. For example, schizophrenia-like psychosis in epilepsy often does not fit neatly into existing psychiatric classifications. The chronic form of this psychosis is often compared to schizophrenia, marked by severe and intractable epilepsy, early

Table 1. Psychiatric Diagnosis of 32 SSPE Patients Presenting with Psychiatric Manifestations

References	Age/sex	Duration of illness before presentation	Clinical presentations	Psychiatric diagnosis (as per DSM-5 criteria)	Treatment and Outcome
Koehler and Jakumeit ⁶	20/F Pregnant	2 weeks	Vision loss Denial of vision loss She was cheerful despite vision loss Auditory hallucinations Generalized catatonic rigidity Soon progressed to encephalopathy	Dissociative disorder	NA Delivered a normal baby Akinetic mute
Moodie et al. ⁷	16/F	2 days	Paranoid behavior and auditory hallucinations	Schizophrenia	NA Died
Caplan et al. ⁸	9/F	6 months	Psychomotor agitation Insomnia Delusions Declining scholastic performance Speech Incoherence Echolalia, Auditory hallucinations Myoclonus	Schizophrenia	Thioridazine Extrapyramidal side effects Later Phenothiazine and chlorpromazine Died
	11/M	Sudden	Hyperactivity, Aggressive behavior Inappropriate laughing Suicidal ideation Neologisms Perseveration, and echolalia Formal thought disorders Social withdrawal Myoclonus	Schizophrenia	Chlorpromazine Died
Salib ⁹	21/M	8 months	Withdrawn and apathetic Preoccupied with the shape of various body parts Anxious, restless, and agitated	Schizophrenia (Body Dymorphic Disorder)	Died
Duncalf et al. ¹⁰	21/F	2 months	Delusions Fearful and perplexed with echolalia Lately withdrawn, agitated, and had echolalia	Schizophrenia	Fluphenazine Psychotic symptoms improved But had extrapyramidal side effects Died
Mattinson ¹¹	44/F	Sudden	Impaired recent memory Emotional lability Social disinhibition Dysarthria Gait abnormality	Functional psychiatric disorders	Died
Forrest and Stores ¹²	9/F	4 months	Nightmares of seeing "aliens" in a dream Alleged attack by a bald man Disorientated and uncooperative Myoclonus and progressive encephalopathy	Schizophrenia	Died
Jähnel ¹³	19/M	2 months	Auditory and visual hallucinations Lack of interest Decreased drive Seizures and Myoclonus	Schizophrenia	Flupentixol Died
Datta et al. ¹⁴	24/M	5 months Acute fulminant	Feeling sad Loss of interest Increased fatigue and lethargy Multiple somatic complaints Insomnia 2 months later, Myoclonus and encephalopathy	Major depressive disorder	Sertraline Died
Kayal et al. ¹⁵	13/M	2 months	Quiet and withdrawn Confined to home Apathy Inappropriate crying and laughter	Major depressive disorder	Fluoxetine Rapidly became bedridden

Table 1. Continued

References	Age/sex	Duration of illness before presentation	Clinical presentations	Psychiatric diagnosis (as per DSM-5 criteria)	Treatment and Outcome
			Difficulty in walking Myoclonus and encephalopathy		
Theethira et al. ¹⁶	15/M	Several months	Paranoid and self-referential Delusions Later Recurrent falls Myoclonus and encephalopathy	Schizophrenia	A first-generation antipsychotic drug
Baran et al. ¹⁷	31/M	1 year	Delusions Depressive mood Catatonia Cognitive decline Akinetic mutism	Schizophrenia	Olanzapine Extrapyramidal side effects ECT
Aggarwal et al. ¹⁸	13/M	5 months	Withdrawn behavior and decreased interaction, mutism Prolonged standing, clenching of teeth, violent behavior Poor scholastic performance Akinetic mutism	Catatonic schizophrenia (2024 ICD-10-CM Diagnosis Code F20.2)	Lorazepam
Aggarwal et al. ¹⁹	14/M	1 month	Behavioral changes Became talkative, Irritable and angry Frequent bathing and reduced sleep Increased psychomotor activity Myoclonus and encephalopathy	Manic episode (Bipolar and Related Disorders)	Olanzapine
Altunkaynak et al. ²⁰	19/F	1 year	Behavioral changes Later, myoclonus and encephalopathy	Schizophrenia	Antipsychotic treatment Died within 1 year
Dayal and Balhara ²¹	14/M	6 months	Reduced interaction Mutism Catatonic odd posturing Poor eye contact Negativism	Catatonic schizophrenia (2024 ICD-10-CM Diagnosis Code F20.2)	Lorazepam Reduction in BFCRS score to 4. 4 months later developed encephalopathy
Kartal et al. ²²	14/F	3 months	Insomnia Visual and auditory hallucinations Disorganized behavior and poor self-care Agitation	Schizophrenia	Olanzapine
Erdogan et al. ²³	20/M	6 months	Increased irritability and increased psychomotor activity decreased need for sleep and increased goal-directed activity Reckless spending Increased subjective energy	Manic episode (Bipolar and Related Disorders)	Olanzapine Died 2 years
Manoj et al. ²⁴	23/F	1 year	Behavioral abnormalities (increased libido, disinhibited sexual behavior)	Excessive sexual drive (Nymphomania)	Risperidone Died after 1 year
	27/M	2 year	Behavioral abnormalities (increased libido, disinhibited sexual behavior)	Excessive sexual drive (satyriasis)	Risperidone Akinetic mute
Parmar et al. ²⁵	15/M	5 months	Behavioral changes Insomnia Delusions and hallucination Smiling and muttering to self Incontinence Repeated motor acts (stereotypy) Catatonic odd posturing	Schizophrenia	Risperidone
Tak et al. ²⁶	14/M	9 months	Poor scholastic performance Decreased communication Difficulty in finding appropriate words Lately, myoclonus and diffuse encephalopathy	Nonspecific symptoms led to psychiatric consultation	Akinetic mute

Table 1. Continued

References	Age/sex	Duration of illness before presentation	Clinical presentations	Psychiatric diagnosis (as per DSM-5 criteria)	Treatment and Outcome
Ahmad et al. ²⁷	26/M	2 months	Withdrawn behavior Muttering to self and inappropriate smiling, Reduced self-care Impaired sleep Disorganized behavior Myoclonus and encephalopathy	Psychosis	Olanzapine Severe extrapyramidal side effects Improvement in his psychotic symptoms
Bhat et al. ²⁸	8/M	7 days	Change in behavior Excessive talking, overfamiliar behavior Decreased sleep Spitting Excessive playing and hyperactivity	Depressive episode (Bipolar Disorder)	Fluoxetine No improvement after 2 weeks
Reddy et al. ²⁹	17/M	1 year	Poor scholastic performance Crying spells, and irritability Sudden drop of objects from hands 4 months later, Repeated fall Myoclonus and encephalopathy	Moderate depressive disorder	Psychotherapy and fluoxetine
Gökoglu and Gözdaş ³⁰	62/F	3 years	Meaningless speech Memory loss Gait disorder	Moderate depressive disorder	Amantadine Clinical and radiological improvement
Arora et al. ³¹	19/M	3 years	Apathy, personality change Auditory and tactile hallucinations Severe cognitive decline Myoclonus	Schizophrenia	Aripiprazole No further deterioration after 6 months
Sutar and Rai ³²	13/M	8 months	Acute abnormalities in sleep cycle (circadian rhythm disturbances; insomnia) Episodes of slowness and excitement Poor scholastic performance Alternating episodes of slowness and excitation Recurrent falls Mutism, and psychomotor slowing Intermittently, period of psychomotor agitation and irritability 4 months later, Myoclonus and encephalopathy	Catatonic schizophrenia (2024 ICD-10-CM Diagnosis Code F20.2)	Lorazepam Intrathecal interferon His oral intake and sleep improved
Chakraborty et al. ³³	15/M	6 months	Smiling and muttering to self Catatonia Episodes of aggression Attempts to run out of home Poor self-care Myoclonus	Catatonic schizophrenia (2024 ICD-10-CM Diagnosis Code F20.2)	Multiple antipsychotic drugs Acute extrapyramidal side effects Alive after more than 3 years
Kaur ³⁴	17/F	1 year	Behavioral changes Social withdrawal Irrelevant talk and laughter	Schizophrenia	Risperidone Became akinetic mute within a few weeks
Jain et al. ³⁵	18/M	4 months	Behavioral changes Episodes of stupor Soon became mute and had catatonic odd posturing Encephalopathy and myoclonus	Catatonic schizophrenia (2024 ICD-10-CM Diagnosis Code F20.2)	Levetiracetam Lorazepam

Abbreviations: BFCRS score, Bush-Francis Catatonia Rating Scale; CT, computed tomography; DSM-5, Diagnostic and Statistical Manual of Mental Disorders, Fifth Edition; ECT, electroconvulsive therapy; FLAIR, fluid attenuated inversion recovery; ICD-10, International Classification of Diseases 10th Revision; NA, not available.

onset of epilepsy, and secondary generalization of seizures. Neuropathological studies have hinted at underlying factors such as cortical dysgenesis or diffuse brain damage, suggesting that structural brain abnormalities might be a common denominator for

both epilepsy and psychosis. Traumatic brain injury can also lead to schizophrenia-like psychosis. Its clinical presentation often overlaps with primary schizophrenic disorders, primarily featuring delusions and auditory hallucinations but fewer negative

Table 2. Summary of Epidemiological, Clinical Features, Neuroimaging Findings, Histopathological Features, and Outcome of Patients of Subacute Sclerosing Panencephalitis (SSPE) with Psychiatric Manifestations (n = 32)

Age (in years)	Mean = 19.4 Median = 17 Mode = 14 Range = 8-62 Interquartile range = 7
Sex	Female = 11 (34.3%) Male = 21 (65.6%)
Measles vaccination	Yes = 2 (6.2%) No/NA = 30 (93.7%)
Childhood measles	Yes = 10 (31.2%) No or NA = 22 (68.8%)
Geographical areas of reported cases (total 30 reports)	India = 16 (53.3%) Europe, except Turkey = 5 (16.7%) Turkey = 6 (20%) USA = 1 (3.3%) Australia = 1 (3.3%) Africa = 1 (3.3%)
Course of the disease	Acute fulminant = 19 (59.3%) Subacute = 7 (21.9%) Chronic = 5 (16.6%) NA = 1 (3.1%)
Most frequent psychiatric diagnoses	Schizophrenia/ill-defined psychotic disorders = 15 (46.9%) Catatonic schizophrenia = 5 (15.6%) Major depressive disorder = 5 (15.6%) Mania = 2 (6.3%) Dissociative disorder = 1 (3.1%) Functional neurological disorder/ Hysterical = 1 (3.1%) Hypersexuality = 2 (6.3%) Nonspecific = 1 (3.1%)
Neuroimaging	NA = 16 (50%) Normal = 6 (18.8%) T2/FLAIR periventricular hyperintensity = 8 (25%) Pontine hyperintensity = 1 (3.1%) Splenum of the corpus callosum hyperintensity = 1 (3.1%)
Brain biopsy	NA = 29 (90.6%) Done = 3 (9.4%)

Abbreviations: FLAIR, fluid attenuated inversion recovery; NA, not available.

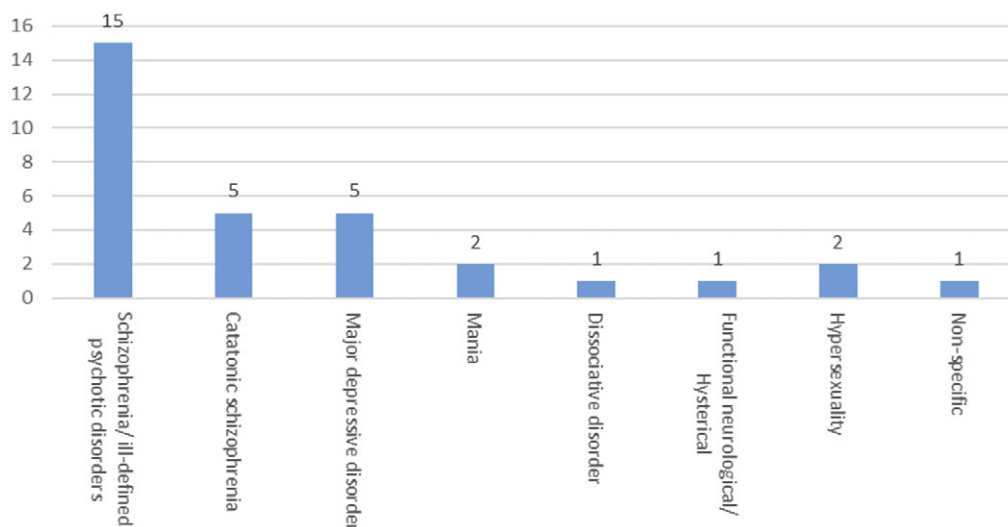


Figure 2. Bar diagram depicts the frequency of psychiatric manifestations in patients with SSPE.

symptoms. The severity and location of brain injury, particularly in the temporal and frontal lobes, are significant risk factors.³⁹⁻⁴¹

In SSPE, the psychotic symptoms may result from the progressive destruction of brain tissue caused by chronic measles virus infection. One report indicated that individuals with persistent schizophrenia had significantly higher blood antimeasles antibody titers than those without a history of a psychiatric disorder.⁴² Many studies have shown that schizophrenia is associated with lower brain volume particularly of gray matter and cortical thickness, increasing gray matter loss, and abnormal gyral patterns.⁴³ Research has shown that there are structural changes in the brains of individuals with schizophrenia and similar changes have been observed in the brains of individuals with SSPE. These changes include a reduction in brain volume, particularly in the frontal lobes, temporal lobes, and hippocampus, which are regions of the brain involved in cognitive and emotional processing. In patients with schizophrenia, neuropathological examinations and brain imaging studies suggest a variety of abnormalities in many brain regions, including the cerebral cortex, hippocampus, thalamus, and amygdala.⁴⁴ Extrapyramidal reactions following treatment with antipsychotic medications were seen in almost one-third of the patients and frequently led to rapid clinical deterioration.

Catatonia was seen in approximately 16% of SSPE patients presenting with a psychiatric manifestation. The pathogenesis of catatonia in SSPE is also not fully understood. Catatonia is believed to result from dysfunction of the frontostriatal network in the brain, which regulates motor and behavioral functions. The SSPE virus also targets the basal ganglia, which are a part of the frontostriatal circuitry. Damage to the basal ganglia can disrupt the normal functioning of this circuitry, leading to motor and behavioral abnormalities characteristic of catatonia. The measles virus targets the limbic system, which is responsible for emotional regulation. Damage to the limbic system may lead to dysfunction of the neural circuits involved in mood regulation, leading to depression. In addition to direct damage to brain tissue, alterations in neurotransmitter and immune system function are possible mechanisms involved in the pathogenesis of depression in SSPE.⁴⁵⁻⁴⁷

In its initial phases, SSPE is often mistakenly identified as malingering. “Malingering” refers to the intentional feigning or exaggeration of symptoms for external gain, such as to avoid school

work, or to gain attention or sympathy.^{48,49} Prashanth et al. analyzed the diagnostic errors in identifying SSPE over a 10-year period. Of 307 patients, 78.8% were initially misdiagnosed with psychiatric conditions like catatonic schizophrenia, postpartum depression, acute psychosis, depression, functional and malingering. The average delay from symptom onset to correct diagnosis was about 6.2 months. Notably, patients who experienced a delay of over a year in diagnosis had a significantly more prolonged disease course.⁴⁹

Our review has certain limitations. In many of the case reports, use of the term schizophrenia was inappropriately applied to these patients. The diagnostic criteria for schizophrenia are more specific and involve a constellation of symptoms that must be present for a sustained period of time—usually at least 6 months—according to psychiatric standards like the DSM-5 (Diagnostic and Statistical Manual of Mental Disorders, Fifth Edition) or ICD-10/ICD-11 (International Classification of Diseases).⁵⁰

SSPE infrequently masquerades as psychiatric disorders, which can lead to erroneous diagnoses. Eventually, all these patients develop periodic myoclonus and encephalopathy.

Supplementary material. The supplementary material for this article can be found at <https://doi.org/10.1017/S1092852924000038>.

Author contribution. Conceptualization: S.K.K., A.J., S.P., H.S.M., N.K., I.R., R.U., R.K.G.; Data curation: S.K.K., S.P., H.S.M., I.R., R.K.G.; Funding acquisition: S.K.K., H.S.M.; Methodology: S.K.K., H.S.M., N.K., R.K.G.; Resources: S.K.K., A.J., S.P., H.S.M., I.R., R.U., R.K.G.; Software: S.K.K., A.J., S.P., H.S.M., N.K., I.R., R.K.G.; Supervision: S.K.K., A.J., S.P., H.S.M., I.R., R.K.G.; Validation: S.K.K., A.J., S.P., R.K.G.; Visualization: S.K.K., S.P., R.K.G.; Writing – original draft: S.K.K., A.J., N.K., I.R., R.U., R.K.G.; Writing – review & editing: S.K.K., A.J., N.K., I.R., R.U., R.K.G.; Formal analysis: A.J., S.P., I.R., R.U., R.K.G.; Investigation: H.S.M.

Disclosure. All the authors have no competing interests to declare.

References

- Garg RK, Mahadevan A, Malhotra HS, Rizvi I, Kumar N, Uniyal R. Subacute sclerosing panencephalitis. *Rev Med Virol.* 2019;**29**(5):e2058.
- Nair SS, Vysakha KV, Menon RN, Sundaram S. Adult-onset subacute sclerosing panencephalitis. *Pract Neurol.* 2021;practneurol-2020-002880.
- Garg RK, Rizvi I, Malhotra HS, et al. The spectrum of neuropsychiatric manifestations in subacute sclerosing panencephalitis: a systematic review of published case reports and case series. PROSPERO 2023 CRD42023408227. https://www.crd.york.ac.uk/prospero/display_record.php?ID=CRD42023408227. Assessed March 27, 2023.
- Joanna Briggs Institute. 2017 critical appraisal checklist for case reports. https://jbi.global/sites/default/files/2019-05/JBI_Critical_Appraisal-Checklist_for_Case_Reports2017_0.pdf. Assessed April 1, 2023.
- Dyken PR. Subacute sclerosing panencephalitis. Current status. *Neurol Clin.* 1985;**3**(1):179–196.
- Koehler K, Jakumeit U. Subacute sclerosing panencephalitis presenting as Leonhard's speech-prompt catatonia. *Br J Psychiatry.* 1976;**129**:29–31.
- Moodie JW, Philcox D, Naudé WD, Lipper S, Kipps A. Atypical presentation of subacute sclerosing panencephalitis in 3 patients. *S Afr Med J.* 1980;**58**(24):968–971.
- Caplan R, Tanguay PE, Szekely AG. Subacute sclerosing panencephalitis presenting as childhood psychosis. *J Am Acad Child Adolesc Psychiatry.* 1987;**26**(3):440–443.
- Salib EA. Subacute sclerosing panencephalitis (SSPE) presenting at the age of 21 as a schizophrenia-like state with bizarre dysmorphic features. *Br J Psychiatry.* 1988;**152**:709–710.
- Duncalf CM, Kent JN, Harbord M, Hicks EP. Subacute sclerosing panencephalitis presenting as schizophreniform psychosis. *Br J Psychiatry.* 1989;**155**:557–559.
- Mattinson PJ. Suspected SSPE - a delayed psychiatric presentation. *Br J Psychiatry.* 1989;**154**:116–118.
- Forrest G, Stores G. Subacute sclerosing panencephalitis presenting with psychosis and possible sexual abuse. *Eur Child Adolesc Psychiatry.* 1996;**5**(2):110–113.
- Jähnel M. Paranoid-halluzinatorische Psychose als Erstmanifestation einer subakuten sklerosierenden Panencephalitis (SSPE) bei einem 19-jährigen Mann. *Psychiatrische Praxis.* 2003;**30**(S 2):70–72.
- Datta SS, Jacob R, Kumar S, Jayabalan S. A case of subacute sclerosing panencephalitis presenting as depression. *Acta Neuropsychiatr.* 2006;**18**(1):55–57.
- Kayal M, Varghese ST, Balhara YP. Psychiatric manifestation of SSPE. *J Neuropsychiatry Clin Neurosci.* 2006;**18**(4):560.
- Theethira TG, Ravat SH, Shah PU, Oak PJ, Godge YR, Chengappa KR. Subacute sclerosing panencephalitis presenting as schizophreniform disorder. *Acta Neuropsychiatrica.* 2009;**21**(1):45–47.
- Baran Z, Hanağasi H, Uçok A. An unusual late presentation of subacute sclerosing panencephalitis with psychotic symptoms. *J Neuropsychiatry Clin Neurosci.* 2010;**22**(1):123.E13.
- Aggarwal A, Jain M, Jiloha R. Catatonia as the initial presenting feature of subacute sclerosing panencephalitis. *J Neuropsychiatry Clin Neurosci.* 2011;**23**(1):E29–E31.
- Aggarwal A, Khandelwal A, Jain M, Jiloha RC. Subacute sclerosing panencephalitis presenting as mania. *Ann Indian Acad Neurol.* 2011;**14**(2):120–121.
- Altunkaynak Y, Yıldırım Z, Ertem DH, Dirican AC, Baybaş S. Late onset subacute sclerosing panencephalitis: presenting psychosis. *J Clin Anal Med.* 2013;**4**(suppl2):220–222.
- Dayal P, Balhara YP. Catatonia as presenting clinical feature of subacute sclerosing panencephalitis. *J Pediatr Neurosci.* 2014;**9**(1):57–59.
- Kartal A, Kurt AN, Gürkaş E, Aydın K, Serdaroglu A. Subacute sclerosing panencephalitis presenting as schizophrenia with an alpha coma pattern in a child. *J Child Neurol.* 2014;**29**(10):NP111–NP113.
- Erdogan S, Yilmaz R, Sorgun MH, Aydın N. Mania as a presenting clinical feature of subacute sclerosing panencephalitis. *Acta Neurol Belg.* 2015;**115**(4):803–805.
- Manoj S, Mukherjee A, Kumar KV. Subacute sclerosing panencephalitis presenting with hypersexual behavior. *Indian J Psychiatry.* 2015;**57**(3):321–322.
- Parmar A, Ranjan R, Sagar R. Subacute sclerosing panencephalitis presenting with isolated positive psychotic and catatonic symptoms. *Indian J Psychol Med.* 2017;**39**(4):534–536.
- Tak ZA, Celik M, Kalenderoglu A, Sağlam S, Ekmekci B, Altun Y. A case of sub-acute sclerosing panencephalitis presenting with nonspecific psychiatric symptoms. *Turk Psikiyatri Dergisi.* 2017;**28**(3):221.
- Ahmad J, Kar SK, Uniyal R. Acute and transient psychotic disorder as a rare early manifestation of late-onset sub-acute sclerosing panencephalitis. *Neurol Psychiat Brain Res.* 2018;**30**:35–38.
- Bhat BA, Dar SA, Hussain A. Sub-acute sclerosing panencephalitis presenting as anti-depressant induced childhood mania. *J Psychiatry.* 2018;**21**:1000452.
- Reddy B, Das S, Guruprasad S. Primary psychiatric manifestations of subacute sclerosing panencephalitis: a case report and literature review. *Psychosomatics.* 2018;**59**(4):408–412.
- Gokoglu A, Gozdas HT. Adult-onset subacute sclerosing panencephalitis presented with neuropsychiatric symptoms. *J Coll Physicians Surg Pak.* 2019;**29**(6):S29–S30.
- Arora S, Jolly AJ, Suhas S, et al. Subacute sclerosing panencephalitis masquerading as schizophrenia: an example of diagnostic overshadowing in neuropsychiatry. *Prim Care Companion CNS Disord.* 2022;**24**(3):21cr02997.

32. Sutar R, Rai NK. Revisiting periodic catatonia in a case of SSPE and response to intrathecal interferon: a case report. *Asian J Psychiatr*. 2020;**51**:101996.
33. Chakraborty K, Chatterjee M, Bhattacharyya R, Neogi R. Case of subacute sclerosing pan-encephalitis (SSPE) presenting as catatonic schizophrenia. *J Ind Assoc Child Adol Mental Health*. 2021;**17**(2):204–209.
34. Kaur G. Sub-acute sclerosing panencephalitis manifesting as psychiatric illness: a case report. *Sch J Med Case Rep*. 2021;**10**:938–941.
35. Jain P, Sehgal A, Purohit K, Sajan C. SSPE presented as catatonia: case report. *World J Pharma Res*. 2022;**11**:1723–1726.
36. Espinola-Nadurille M, Restrepo-Martínez M, Bayliss L, et al. Neuropsychiatric phenotypes of anti-NMDAR encephalitis: a prospective study. *Psychol Med*. 2022;**10**:1–9.
37. Hinotsu K, Miyaji C, Yada Y, et al. The validity of atypical psychosis diagnostic criteria to detect anti-NMDA receptor encephalitis with psychiatric symptoms. *Schizophr Res*. 2022;**248**:292–299.
38. Garg RK, Kumar N, Rizvi I, Pandey S, Malhotra HS, Uniyal R. Fulminant subacute sclerosing panencephalitis mimicking autoimmune encephalitis. *Pediatr Infect Dis J*. 2019;**38**(3):e64.
39. Sachdev P. Schizophrenia-like psychosis and epilepsy: the status of the association. *Am J Psychiatry*. 1998;**155**(3):325–336.
40. Garakani A. Commentary: psychiatric presentations of nonpsychiatric illness or treatment. *J Psychiatr Pract*. 2021;**27**(5):404–405.
41. Ardila A. Psychiatric disorders associated with acquired brain pathology. *Appl Neuropsychol Adult*. 2019;**26**(6):591–597.
42. Dickerson F, Stallings C, Origoni A, Copp C, Khushalani S, Yolken R. Antibodies to measles in individuals with recent onset psychosis. *Schizophr Res*. 2010;**119**(1–3):89–94.
43. Howes OD, Cummings C, Chapman GE, Shatalina E. Neuroimaging in schizophrenia: an overview of findings and their implications for synaptic changes. *Neuropsychopharmacology*. 2023;**48**(1):151–167.
44. Insel TR. Rethinking schizophrenia. *Nature*. 2010;**468**(7321):187–193.
45. Tandra HV, Roy PS, Sharma R, Bhatia V, Saini AG. Subacute sclerosing panencephalitis presenting as choreoathetosis and basal ganglia hyperintensities. *Neurohospitalist*. 2019;**9**(1):26–29.
46. Lebon S, Maeder P, Maeder-Ingvar M, et al. An initial MRI picture of limbic encephalitis in subacute sclerosing panencephalitis. *Eur J Paediatr Neurol*. 2011;**15**(6):544–546.
47. Sawaishi Y, Yano T, Watanabe Y, Takada G. Migratory basal ganglia lesions in subacute sclerosing panencephalitis (SSPE): clinical implications of axonal spread. *J Neurol Sci*. 1999;**168**(2):137–140.
48. Prashanth LK, Taly AB, Sinha S, Ravi V. Subacute sclerosing panencephalitis (SSPE): an insight into the diagnostic errors from a tertiary care university hospital. *J Child Neurol*. 2007;**22**(6):683–688.
49. Sutton T. Psychological testing: art, science and mysticism. *PRECEDENT*. 2010;**99**:39–43.
50. American Psychiatric Association. *Diagnostic and Statistical Manual of Mental Disorders: DSM-5*. Washington, DC: American Psychiatric Association; 2013. doi:10.1176/appi.books.9780890425596.