


Letter to the Editor: New Observation

Frontal Lobe Status Epilepticus Related to CAR T-Cell Therapy Responsive to Anakinra

Umberto Pensato^{1,2} , Chiara de Philippis³, Daniele Mannina³, Daniela Taurino³, Barbara Sarina³, Jacopo Mariotti³, Federico Villa¹, Elena Costantini¹, Simona Marcheselli¹ and Stefania Bramanti³

¹IRCCS Humanitas Research Hospital, Milan, Italy, ²Department of Biomedical Sciences, Humanitas University, Milan, Italy and ³BMT and Cell Therapy Unit, Humanitas Cancer Center, IRCCS Humanitas Research Hospital, Milan, Italy

Keywords: CAR-T cells; CNS inflammation; Neuroinflammation; Neuro-Oncology; Lymphoma

Dear Editor,

Chimeric antigen receptor (CAR) T-cell therapy is a novel adoptive immunotherapy that has progressively improved the standard of care for hematological cancer, especially non-Hodgkin Lymphoma. Nonetheless, its efficacy is burdened by substantial rates of novel systemic and neurological toxicities, namely cytokine release syndrome (CRS) and immune effector cell-associated neurotoxicity syndrome (ICANS).¹ CRS is a cytokine storm disorder that usually presents with fever, hypoxia, and arterial hypotension and may evolve into multi-organ failure.¹ ICANS is a cytokine-driven neuroinflammatory syndrome that may present with a wide range of neurological manifestations, including encephalopathy, frontal lobe dysfunction, dysgraphia, headache, tremors, and expressive aphasia.^{2–4} While some ICANS patients experience mild symptoms with spontaneous recovery, a subgroup may progress to akinetic mutism, seizure, coma, and diffuse cerebral edema, with a potentially fatal outcome.¹ Notably, up to 10% of patients may exhibit seizures or non-convulsive status epilepticus,⁵ but frontal lobe status epilepticus related to CAR T-cells has never been reported.

A 31-year-old female with a one-year history of refractory primary mediastinal B-cell lymphoma was referred to our center as a candidate for CAR T-cell treatment. A comprehensive screening assessment (including neurological examination and contrast brain MRI) excluded lymphomatous central nervous system involvement and other potential contraindications. She received two cycles of pembrolizumab (200 mg spaced two weeks apart) as bridging therapy, and a subsequent PET scan showed stable oncological disease. One month later, she received axicabtagene ciloleucel (anti-CD19 CAR T-cells), preceded by lymphodepleting chemotherapy according to the standard conditioning with fludarabine (30 mg/m² once daily for three days) and cyclophosphamide (500 mg/m² once daily for three days (Figure 1). Two days after CAR T-cells infusion, she developed persistent grade 1 CRS responsive to two tocilizumab cycles (8 mg/kg). On the fifth day, she exhibited an irregular bilateral postural myoclonic tremor and an expressive language disturbance consistent with anomic aphasia

(ICANS grade 2). Her neurological status rapidly evolved into global aphasia accompanied by verbal and motor perseveration (ICANS grade 3). She was promptly transferred to the intensive care unit and treated with high-dose steroids (1 g daily) and anti-seizure medication (levetiracetam 2 g daily). Blood tests showed only a relatively slight increase of systemic inflammatory markers: interleukin-6 275 pg/mL (n.v. <6.4), ferritin 153 mg/mL (n.v. <306.8), C-reactive protein 1.09 mg/dL (n.v. <0.50), yet peripheral CAR T-cells expansion was observed (300 cells/microL). Contrast brain MRI and CSF analysis (including extensive microbiological tests) were unremarkable.

Conversely, continuous electroencephalography (cEEG) revealed a continuous, generalized, frontally predominant, rhythmic delta activity with superimposed sharp waves and evolving morphological changes consistent with non-convulsive status epilepticus (ICANS grade 4) (Figure 2A). Despite increasing levetiracetam dosage (3 g/daily) and administration of lacosamide (400 mg/daily), we obtained no significant improvement in cEEG. Therefore, propofol was rapidly titrated up to 24 cc/h to achieve a Burst-Suppression pattern. Concomitantly, in consideration of steroid-refractory neurotoxicity, high-dose anakinra (100 mg q6h) was started. The following day, the anesthetics dosage was slowly halved, yet continuous epileptiform discharges reappeared and the patient was diagnosed with super-refractory status epilepticus. Valproic acid (800 mg/daily) was added as a third ASM, and propofol was replaced by ketamine (up to 8 mg/kg/h) and midazolam (up to 1.2 mg/kg/h) until a Burst-Suppression pattern was reobtained. After a few days, a dramatic electroclinical response was observed. Indeed, no epileptiform discharges were detected during rapid weaning of anesthetics, allowing complete suspension within 48 hours. Notably, frontal intermittent rhythmic delta activity (FIRDA) during anesthetics weaning was observed (Figure 2B). Thereafter, neurological examination was unremarkable, except for selective amnesia of the neurotoxicity days and a moderate length-dependent quadriparesis consistent with critical illness neuropathy. Brain MRI and EEG follow-up showed no abnormalities, and ASMs were slowly titrated to a single ASM. No new

Corresponding author: Umberto Pensato; Email: umbertopensato91@gmail.com

Cite this article: Pensato U, de Philippis C, Mannina D, Taurino D, Sarina B, Mariotti J, Villa F, Costantini E, Marcheselli S, and Bramanti S. Frontal Lobe Status Epilepticus Related to CAR T-Cell Therapy Responsive to Anakinra. *The Canadian Journal of Neurological Sciences*, <https://doi.org/10.1017/cjn.2024.7>

© The Author(s), 2024. Published by Cambridge University Press on behalf of Canadian Neurological Sciences Federation. This is an Open Access article, distributed under the terms of the Creative Commons Attribution licence (<http://creativecommons.org/licenses/by/4.0/>), which permits unrestricted re-use, distribution and reproduction, provided the original article is properly cited.

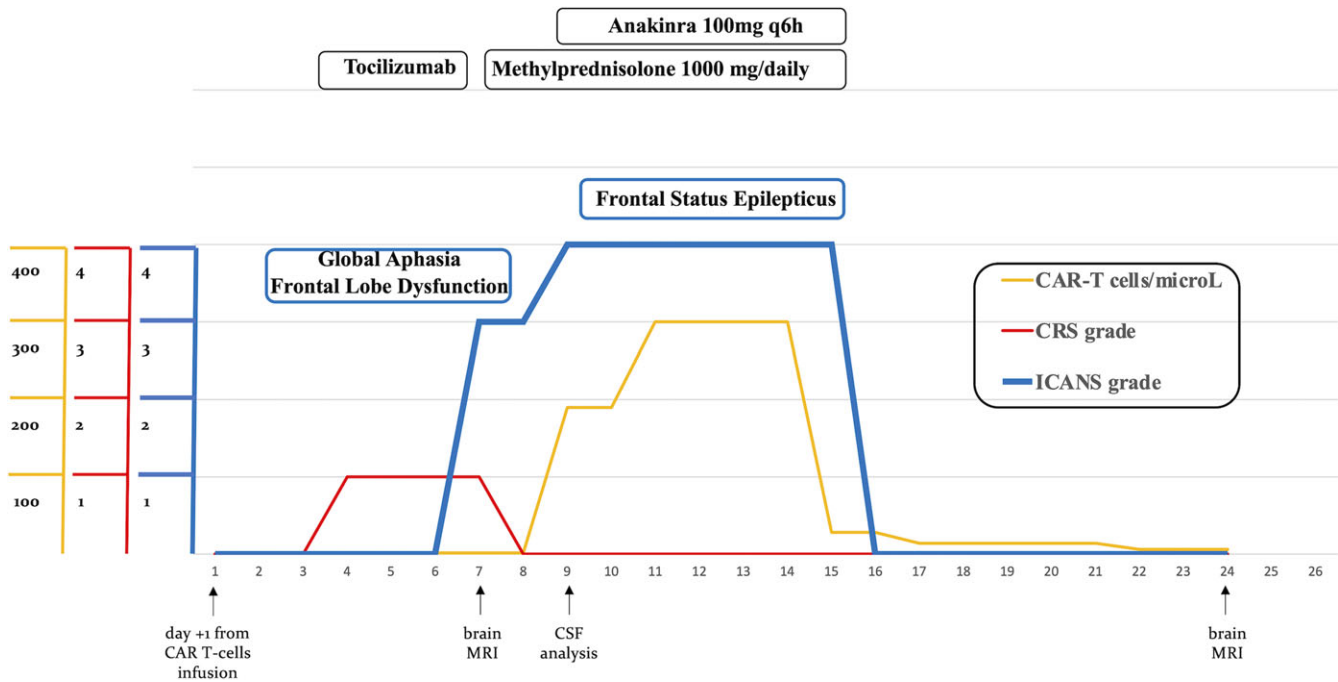


Figure 1: Disease course. Clinical manifestations of neurotoxicity, CRS grading, and serum CAR T-cells levels, along with immunotherapy and diagnostic investigation timing, are illustrated. CRS: cytokine release syndrome. ICANS: immune effector cell-associated neurotoxicity syndrome. CSF: cerebrospinal fluid.

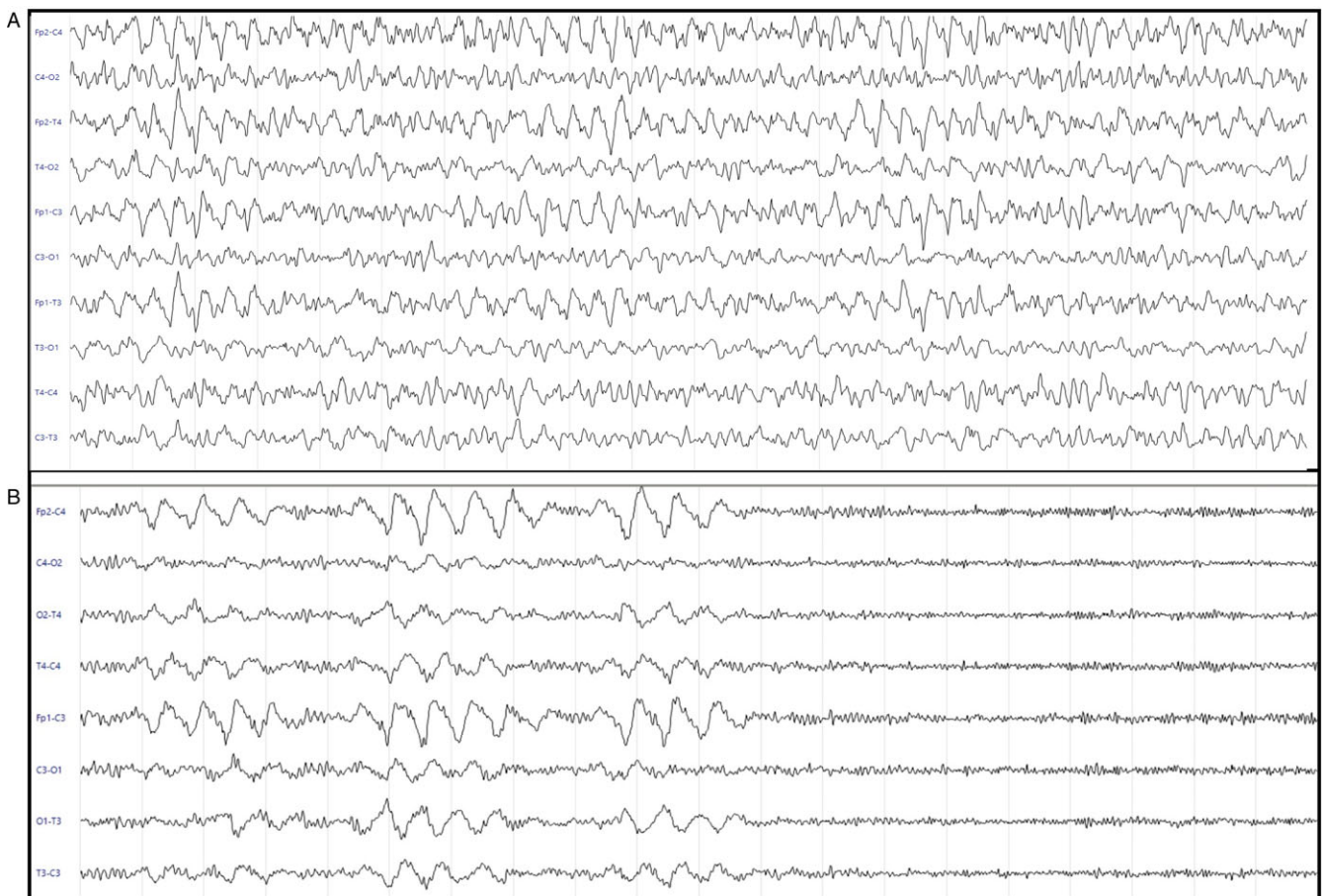


Figure 2: Eight-channel continuous EEG recording via subdermal needle electrode recordings. **A** shows a continuous, generalized, frontally predominant, rhythmic delta activity pattern at about 2-3 Hz with superimposed sharp waves and evolving morphology changes consistent with electrographic status epilepticus (day +9). Sensitivity: 14 microv/mm. Epoch 20 s. **B** shows frontal intermittent rhythmic delta activity (FIRDA) alternating with iatrogenic beta activity (day +15). Sensitivity: 10microv/mm. Epoch: 20 s.

neurological manifestations were experienced by the patient and her motor function slowly improved. The patient was discharged home one month after the CAR T-cells infusion. At the 2-month follow-up, a PET scan documented a complete remission of the underlying hematological disease. At the same time, the comprehensive neurological assessment (neurological examination, EEG, and contrast brain MRI) did not reveal any neurological sequelae.

We described a novel case of frontal lobe status epilepticus related to CAR T-cell therapy, which initially presented with an expressive language disturbance that rapidly progressed to global aphasia and perseveration.¹ Unfortunately, EEG was not recorded at disease onset, yet we can speculate that she presented with aphasic status or that her neurological manifestations rapidly evolved into an epileptic disorder. Interestingly, EEG findings revealed bilateral frontal epileptiform discharges despite the absence of MRI abnormalities, supporting a functional, rather than structural, frontal lobe disorder. Yet, the sparse spatial sampling of the subdermal electrode array limited, to some extent, the topographical interpretation of the EEG. Notably, a clinical frontal lobe dysfunction has been recurrently observed in ICANS, arguably reflecting an intrinsic vulnerability of frontal lobes to cytokine-mediated neuroinflammation.^{2,4} The findings from our patient's investigations provide valuable insight into the potential epileptic origin of previously reported frontal lobe dysfunction ICANS cases.

Further corroborating the frontal lobe involvement, after the resolution of status epilepticus, our patient displayed frontal intermittent rhythmic delta activity (FIRDA), a non-epileptic electrographic pattern revealing a frontal predominant brain dysfunction. Specifically, it underlines a structural or functional, subcortical gray matter dysfunction involving the thalamocortical network.⁶ Notably, this pattern has been reported to be very sensitive for ICANS, yet whether it reflects a persistent frontal subcortical dysfunction or a post-ictal phenomenon in these patients remains unexplained so far.⁷ It is possible that ICANS presents with a frontal electroclinical spectrum⁸ where frontal lobe status epilepticus represent the extreme end, whereas isolated FIRDA is the most common presentation. Our patient's electroclinical status dramatically ameliorated a few days following anakinra. This drug has recently proven efficacy and safety in high-dose (up to 400mg/day) in steroid-refractory ICANS.⁹ Notably, administration of anakinra has been associated with improvement in patients with febrile infectious-related epileptic syndrome, a cytokine-driven prolonged status epilepticus, as well as in patients with drug-resistant epilepsy.¹⁰ This suggests that anakinra potentially had both disease-modifying and symptomatic (anti-convulsant) properties; hence, combined with symptomatic treatment (anesthetics and ASMs), it might be of utmost importance in neuroinflammatory-driven status epilepticus.

At the 2-month follow-up, she had a complete oncological response without any neurological sequelae. The latter data is consistent with recent evidence of long-term safety following ICANS.² We hypothesize that bridging therapy with an immune checkpoint inhibitor (ICI) may have contributed to toxicity development and anti-tumor efficacy. Indeed, recent evidence suggests that these drugs may increase CAR T-cell therapy efficacy and toxicity rate by restraining physiological T-cell exhaustion.¹¹ It is very unlikely that primary ICI-related neurotoxicity was

responsible for the neurological condition in our patient. Indeed, the timing of presentation and evolution of the neurotoxicity, as well as the clinical and EEG features are more consistent with ICANS.^{1,12}

In conclusion, CAR T-cell therapy-related neurotoxicity can present with frontal lobe status epilepticus. In such cases, aggressive immunotherapy should be advocated to manage neurotoxicity manifestations since ICANS is a life-threatening condition, yet with a potential complete neurological recovery. Further studies should determine whether aggressive immunosuppression impacts the hematological prognosis.

Acknowledgments. None.

Statement of authorship. UP drafted the manuscript and contributed to the acquisition of data; CdP, DM, DT, BS, JM, FV, EC, SM, and SB critically revised the manuscript and contributed to the acquisition of data.

Funding. No funding was received to assist in the preparation of this manuscript.

Competing interests. The authors declare they have no competing interests.

Ethics approval. Informed written consent was signed by the patient.

References

1. Lee DW, Santomasso BD, Locke FL, et al. ASTCT consensus grading for cytokine release syndrome and neurologic toxicity associated with immune effector cells. *Biol Blood Marrow Transpl.* 2019;25:625–38.
2. Pensato U, Amore G, Muccioli L, et al. CAR t-cell therapy in BologNA-NEUrotoxicity TRreatment and Assessment in Lymphoma (CARBON-NEUTRAL): proposed protocol and results from an Italian study. *J Neurol.* 2023;270:2659–73.
3. Gust J, Taraseviciute A, Turtle CJ. Neurotoxicity associated with CD19-targeted CAR-T cell therapies. *CNS Drugs.* 2018;32:1091–101.
4. Pensato U, Muccioli L, Cani I, et al. Brain dysfunction in COVID-19 and CAR-T therapy: cytokine storm-associated encephalopathy. *Ann Clin Transl Neurol.* 2021;8:968–79.
5. Gust J, Ponce R, Liles WC, Garden GA, Turtle CJ. Cytokines in CAR T cell-associated neurotoxicity. *Front Immunol.* 2020;11:577027.
6. Kim KT, Roh YN, Cho NH, Jeon JC. Clinical correlates of frontal intermittent rhythmic delta activity without structural brain lesion. *Clin EEG Neurosci.* 2021;52:69–73.
7. Huby S, Gelisse P, Tudesq JJ, et al. Frontal intermittent rhythmic delta activity is a useful diagnostic tool of neurotoxicity after CAR T-cell infusion. *Neurol Neuroimmunol Neuroinflamm.* 2023;10:e200111.
8. Saw JL, Sidiqi MH, Ruff M, et al. Acute seizures and status epilepticus in immune effector cell associated neurotoxicity syndrome (ICANS). *Blood Cancer J.* 2022;12:62.
9. Jain MD, Smith M, Shah NN. How I treat refractory CRS and ICANS after CAR T-cell therapy. *Blood.* 2023;141:2430–42.
10. Yamanaka G, Ishida Y, Kanou K, et al. Towards a treatment for neuroinflammation in epilepsy: Interleukin-1 receptor antagonist, Anakinra, as a potential treatment in intractable epilepsy. *Int J Mol Sci.* 2021;22:6282.
11. Nakajima M, Sakoda Y, Adachi K, Nagano H, Tamada K. Improved survival of chimeric antigen receptor-engineered T (CAR-T) and tumor-specific T cells caused by anti-programmed cell death protein 1 single-chain variable fragment-producing CAR-T cells. *Cancer Sci.* 2019;110:3079–88.
12. Guidon AC, Burton LB, Chwalisz BK, et al. Consensus disease definitions for neurologic immune-related adverse events of immune checkpoint inhibitors. *J Immunother Cancer.* 2021;9:e002890.