

repetitive transcranial magnetic stimulation (rTMS), improves hyperactivity, impulsivity, and attention deficit of individuals with ADHD.

**Objectives:** The aim of this case study is to present the effectiveness of rTMS on hyperactivity, impulsivity, and attention deficit of an individual with ADHD.

**Methods:** This is a case study of a 22 year old male diagnosed with ADHD. The protocol applied was 2 weeks of daily rTMS sessions. This involved repetitive TMS to the right dorsomedial prefrontal cortex (10 Hz, 3.000 pulses, 120% motor threshold) to treat attention deficit, hyperactivity and impulsivity. Assessments were conducted using Adult ADHD Questionnaires, the Jasper and Goldberg questionnaire and WHO self- reported scale at baseline, 1 month and up to 3 months follow up.

**Results:** The patient showed overall improvement in scores in both ADHD scales with scores dropping more than 50 % in both scales from pre treatment to 3 months follow up. No side effects were recorded during therapy

**Conclusions:** Our findings suggest that the use of rTMS therapy in individuals with ADHD, is an efficacious and safe therapeutic treatment option.

**Keywords:** rTMS; Attention- Deficit Hyperactivity Disorder

EPP1092

**Electroconvulsive therapy practice in a general hospital in chile**

V. Saitua\*, N. Schneider and J. Libuy

Psiquiatría, Pontificia Universidad Católica de Chile, Santiago, Chile

\*Corresponding author.

doi: 10.1192/j.eurpsy.2021.1318

**Introduction:** Electroconvulsive therapy (ECT) is a current, relevant treatment for severe mental illness. In this article we describe our experience on ECT in a public hospital in Chile.

**Objectives:** Describe a 34 patients’ cohort who received ECT and their outcomes.

**Methods:** Data was extracted from ECT records between 2018-2020, patients’ evaluations before and after ECT, and case files. Data was then analyzed and described.

**Results:** ECT was received by 18 males and 16 females. Age ranged from 19 to 73 years (41 average). More than 75% had 12 or more years of education. Patients’ diagnoses and indications for ECT are shown in Figures 1-2

Figure 1: Patients’ psychiatric diagnoses

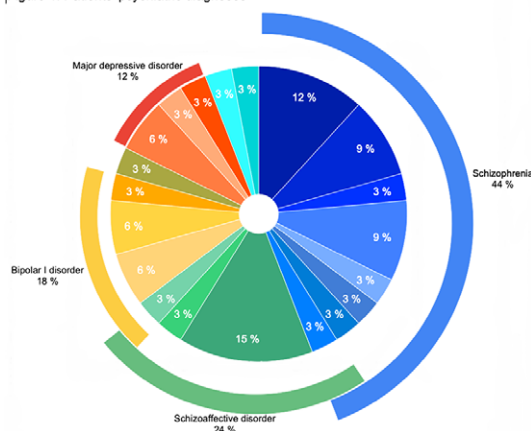
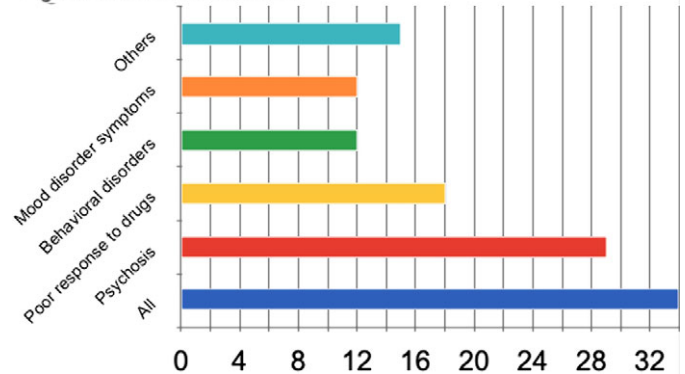


Figure 2: Indications for ECT



The CGI-SI scale was applied to subjects before treatment, and 85% had a score of 5 or more. On average, patients received 8.7 ECT sessions. Right unilateral electrode placement (RUL) was preferred initially for 94% of patients. Brief pulse width (0.3ms) was most commonly used (76%). Seizure duration averaged in 29 seconds. Adverse reactions presented on 32%, most being mild. One treatment had to be stopped due to confusional symptoms post ECT. After ECT, 91% of patients improved according to CGI-GI scale. 55% were assessed CGI-GI 1 “very much improved”. MoCA scale was also evaluated, showing a 2,1 point gain.

**Conclusions:** Schizophrenia and psychosis were the most frequent diagnosis and indication for ECT. RUL and brief pulse width were the preferred settings. This cohort suggests that ECT had an impact on markedly ill patients, based on CGI and MoCA scales.

**Keywords:** psychosis; Electroconvulsive therapy; General Hospital; schizophrenia

Psychotherapy

EPP1093

**The association between work-related factors and use of psychotherapeutic methods with burnout rates in family physicians.**

L. Rubene<sup>1,2\*</sup> and A. Miksons<sup>3</sup>

<sup>1</sup>Psychiatry And Narcology, Riga Stradins University, Riga, Latvia;

<sup>2</sup>Psychiatry, Riga Centre of Psychiatry and Narcology, Riga, Latvia and

<sup>3</sup>Psychosomatic Medicine And Psychotherapy, Riga Stradins University, Riga, Latvia

\*Corresponding author.

doi: 10.1192/j.eurpsy.2021.1319

**Introduction:** A physicians work is closely related to patients and the understanding of their problems. The use of psychotherapeutic methods is a factor for successful care (Swanson, 1994). At the same time burnout is a syndrome that can affect the health of doctors themselves thus reflecting on the quality of care they can provide (Lloyd et al, 2002).