

Aneurysm of the Posterior Inferior Cerebellar Artery Presenting as Intraventricular Hemorrhage in a Child: Report of a Case With Survival

RICHARD LEBLANC and JOHN E. BLUNDELL

SUMMARY: *A case of intraventricular hemorrhage secondary to a ruptured aneurysm of the posterior inferior cerebellar artery in a child is presented. Treatment is discussed and the literature is reviewed.*

RÉSUMÉ: *Nous présentons un cas d'hémorragie intraventriculaire secondaire à une rupture d'anéurysme de l'artère cérébelleuse postéro-inférieure chez un enfant. Nous discutons du traitement et présentons une revue de la littérature.*

INTRODUCTION

Posterior fossa aneurysms in children are uncommon lesions whose natural history is poorly defined (Gold et al., 1973). Aneurysms of the posterior inferior cerebellar artery (PICA) in children are even less common (Pickering et al., 1970). McDonald and Korb (1939) found only one in a child in a review of 1,125 post-mortem cases from the literature to 1938. With the advent of angiography, the ante-mortem diagnosis of cerebral aneurysms came to the fore. However, because of reticence on the part of neurosurgeons to operate on aneurysms in the posterior fossa, there was limited incentive for angiographic examination of this region (Laine, 1968). This situation has now been corrected, but the demonstration of a PICA aneurysm in a child remains an unusual occurrence. We report the case of a five year old boy with such a lesion presenting with an intraventricular hemorrhage whose aneurysm was successfully clipped and who survived without significant neurological sequelae.

CASE REPORT

A five year eleven month old white male with uncomplicated birth history was born with multiple small vascular lesions about the left breast that gradually disappeared. He was in good health until the morning of admission to hospital when he suddenly collapsed while playing. He was found unconscious and brought to a peripheral hospital where he was noted to be stuporous and he was transferred to The Montreal Children's Hospital under the care of Dr. John Blundell. On arrival the blood pressure was 120/70mm Hg, the pulse 70 with sinus arrhythmia, the temperature 35.4°C, and the respiratory rate 24 and regular. The head circumference was at the 45th percentile and the neck was markedly rigid. Kernig's and Brud-

zinski's signs were present. There was a one millimeter diameter telangiectasia on the left cheek. The patient was stuporous but rousable, and was disoriented to time and place. He obeyed first order commands and complained of headache and neck pain. The disc margins were indistinct and there were retinal hemorrhages bilaterally. The general and detailed neurological examinations were otherwise unremarkable.

The peripheral blood count revealed 15 800 white blood cells per mm³, a hemoglobin of 12.5, and hematocrit of 31.1. The prothrombin time was 12 with a control of 11, the partial thromboplastin time was 39 with a control of 30. There were 500 000 platelets per mm³. Lumbar puncture yielded bloody CSF with a xanthochromic supernatant. The CSF protein and glucose were 38 mg% and 48 mg% respectively. Serum biochemistry and osmolality were normal.

A computerized tomographic (CT) scan demonstrated blood in the IVth, IIIrd, and both lateral ventricles and mild diffuse dilatation of the ventricular system. There was no associated intracerebral hematoma. No further information was gained by an infused study. (Fig. 1 and 2). The patient was initially treated by rest in a quiet room, and with barbiturates for sedation. His level of consciousness gradually improved and he did not develop signs of delayed focal ischemia. A four vessel cerebral angiogram performed via the transfemoral route on the eighth day of admission revealed an aneurysm of the left posterior inferior cerebellar artery (PICA). The left vertebral artery was of smaller caliber than the right which appeared to be the dominant vessel (Fig. 3a & b).

OPERATIVE PROCEDURE

The patient was brought to the operating room on the 10th hospital day. With the patient in the prone position, a suboccipital craniectomy was performed and the aneurysm was approached using the operative microscope as described by Hammon and Kempe (1972). A temporary Mayfield clip (1971) was placed on the left

From the Department of Neurosurgery, the Montreal Children's Hospital and McGill University, Montreal, Quebec, Canada.

Reprint requests to Richard Leblanc, M.D., the Montreal Neurological Hospital, 3801 University Street, Montreal, Quebec, Canada, H3A 2B4.

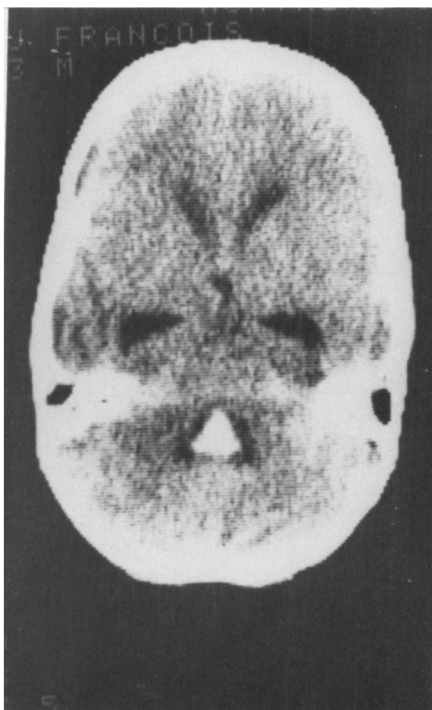


Figure 1 — Non-infused CT scan showing mild diffuse hydrocephalus and a hematoma occupying the IVth ventricle. Note the area of lower density, compatible with that of CSF, about the hematoma.

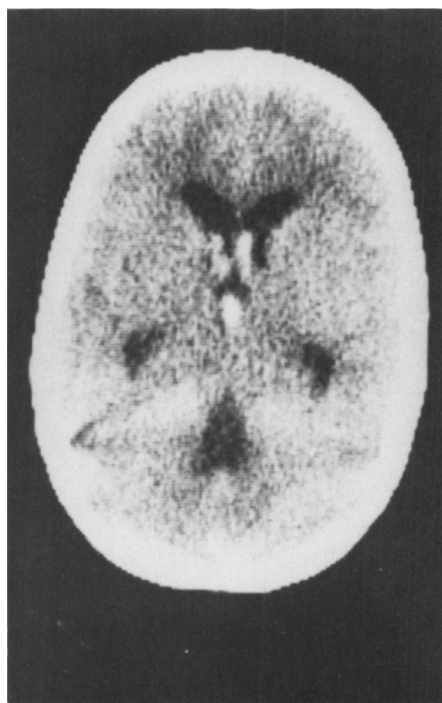


Figure 2 — CT scan showing mild diffuse hydrocephalus and hematoma of the IIIrd and both lateral ventricles.

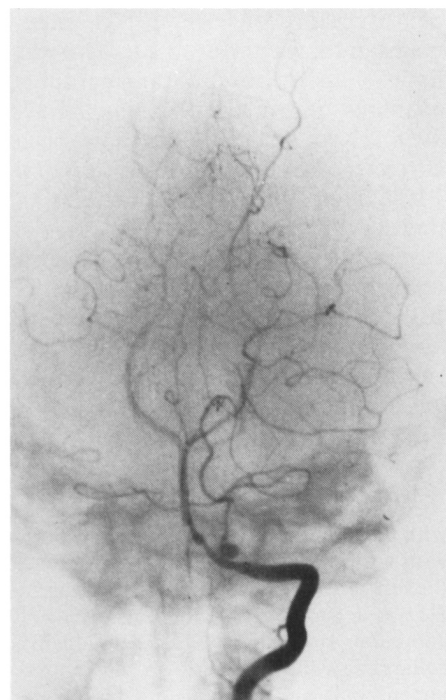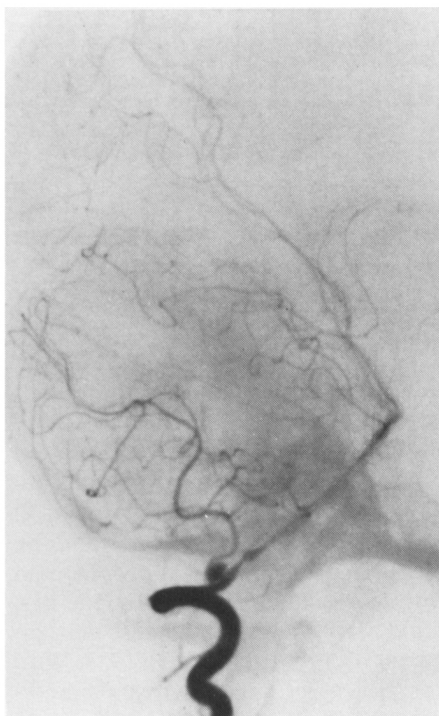


Figure 3 a & b — Lateral (a) and PA (b) views: Selective left vertebral arteriograms — subtraction films — showing an aneurysm of the posterior circulation that proved at operation to originate from the left posterior inferior cerebellar artery (PICA). Note narrowing of the basilar artery distal to the origin of PICA.

vertebral artery at its entrance into the posterior fossa without ill effect. Controlled hypotension was induced and the aneurysm was found without difficulty pointing into the subarachnoid space lateral to the brainstem anterior to the XIIth cranial nerve on the anterior medullary portion of the PICA. The dome and the neck of the aneurysm were clipped without incident. Upon removal of the Mayfield clip profuse bleeding was incurred from what proved to be a clean rent in the vertebral artery at the site of the Mayfield clip. This was easily controlled by the application of Weck clips immediately proximal and distal to the rent. The blood pressure was allowed to rise to a normal level without incident and the operation terminated. The patient awoke smoothly from anaesthesia and was neurologically intact.

POST-OPERATIVE COURSE

The patient did well post-operatively, gradually returning to normal activity. One week post-operatively, a detailed neurological examination revealed only prominent grooving of the left side of the tongue and a questionable slight decrease of the right abdominal reflexes. The disc margins were sharper and the retinal hemorrhages were resolving. An angiogram was performed on the 21st post-operative day and failed to demonstrate the aneurysm. (Fig. 4)

DISCUSSION

The occurrence of saccular aneurysms has been recognized as a significant cause of strokes in children

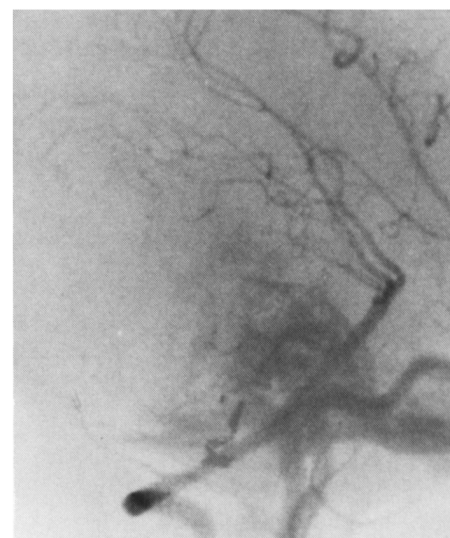


Figure 4 — Post-operative lateral vertebral angiogram demonstrating nonfilling of the aneurysm.

(Matson, 1965; Thompson and Pribram, 1969; Humphreys et al., 1972; Sedzimir and Robinson, 1973; Shucart and Wolpert, 1974; Shillito, 1976; Almeida et al., 1977; Becker et al., 1979; Amacher and Drake, 1979; Normes and Wikeby, 1979). The proportion of these lesions occurring on the posterior circulation is, however, not well defined (Table I). An aneurysm of the PICA in a child is considered a rarity (Pickering et al., 1970). We have found six cases in the

literature and added a case of our own (Table II). Only four of these were diagnosed ante-mortem. The case reported by Thompson et al. (1973) was initially mis-diagnosed because of an incomplete angiographic examination. Jane's case (1961), without the benefit of angiography, was misdiagnosed as a tumor of the posterior fossa. That patient expired four days after a twist-drill biopsy. The patient reported by Pickering and associates (1970) presented, as did our patient,

with intraventricular hemorrhage, and expired on the third hospital day.

The demonstration by Drake (1965; 1979) and others that posterior fossa aneurysms are amenable to surgery and the propensity of these lesions to rebleed (Humphreys et al., 1972) provided an incentive for the angiographic examination of the posterior circulation (Laine, 1973). Harwood-Nash and Fitz (1973) and Thompson et al. (1973) have advocated the use of this procedure in suspected cases of

TABLE II
PICA Aneurysms In Children*

Age, sex, side	Presentation	Treatment	Course	Reference
6 yrs, male right	Rupture	Not Specified	Died	McDonald & Korb 1939
1 year, male left	"Tumor"	Biopsy	Died	Jane 1961
23 mths, male left	Subarachnoid Hemorrhage	Excision of Aneurysm	Well	Matson 1965
1 mth, male right	Intraventricular Hemorrhage	Decrease of Intracranial Pressure	Died	Pickering et al. 1970
20 years, male	Not Specified	Methyl metacrylate reinforcement	Well	Hammon & Kempe 1972
9 yrs, female	Hydrocephalus "Tumor"	Not Specified	Not Specified	Thompson et al. 1973
5 11/12 yrs, male, left	Intraventricular Hemorrhage	Clipping	Well	This report

*PICA: Posterior Inferior Cerebellar Artery.

TABLE I
Posterior Circulation Aneurysms In Children

Total number of aneurysms	Number of aneurysms in children	% of aneurysms in children	Number of posterior circulation aneurysms in children	% of posterior circulation aneurysms in children	Reference
2672	41	1.6	5	12	Locksley 1966
3000	58	1.1	3	5	Patel & Richardson 1971
	14		1	7	Carrea et al. 1973
	50		2	4	Sedzimir & Robinson 1973
	15*		4	27	Thompson et al. 1973
	20		3	15	Shillito 1976
	11		1	9	Almeida et al. 1977
	31**		16	52	Amacher & Drake 1979

*Excludes 9 traumatic, mycotic, and miscellaneous cases.

**Excludes 2 mycotic aneurysms.

subarachnoid hemorrhage in children. They have pointed out that without the benefit of angiography, a misdiagnosis of a posterior fossa tumor is ever present, leaving the aneurysm both undiagnosed and untreated, while the true incidence of these lesions is underestimated. An intraventricular hematoma resulting from a ruptured cerebral aneurysm is almost universally fatal (Pia, 1973), but spontaneous resolution has been reported (Ojemann and New, 1963). Our patient improved and stabilized after an initial collapse. This favorable course likely resulted from an incomplete obstruction of the outflow of the CSF pathway in the fourth ventricle. This is demonstrated in the initial CT scan (Fig. 1), where the fourth ventricle hematoma is seen to be surrounded by an area of diminished density compatible with that of CSF. The fact that the aneurysm bled laterally into the subarachnoid space rather than medially into the substance of the brainstem, as is sometimes the case (Hammon and Kempe, 1972), undoubtedly contributed to the successful outcome of this case.

The aneurysm was successfully treated by clipping of its neck and fundus. However, damage incurred to the vertebral artery from temporary clamping with a Mayfield clip made occlusion of this vessel mandatory. Drake (1975) has demonstrated that a vertebral artery can be ligated without ill effect if it is the non-dominant vessel as long as temporary clamping does not produce a change in the patient's condition. This was the case in our patient who tolerated this procedure well.

Alexander (1963) has reported that the cross-legs of a Mayfield clip can act as scissors and sever a vessel, the damage becoming obvious only when the clip is removed. We believe that this is what happened in our patient, and caution neurosurgeons to bear this in mind when using this device.

We think that aneurysms of the posterior fossa in children are amenable to surgery and that clipping of the aneurysm is the treatment of choice when a suitable neck is present. When this is not the case, other techniques

are available (Hammon and Kempe, 1973), of which ligation or clipping of the vertebral artery is one.

ACKNOWLEDGEMENT

We are grateful to Dr. Augustin M. O'Gorman — Department of Radiology, The Montreal Children's Hospital for performing and interpreting the angiograms.

REFERENCES

- ALEXANDER, E. JR., ADAMS, J.E., DAVIS, C.H. JR. (1963). Complications in the use of temporary intracranial arterial clip. *Journal of Neurosurgery*, 20: 810-811.
- ALMEIDA, G.M., PINDARE, J., PLESE, P., BIANCO, E., and SHIBATA, M.K. (1977). Intracranial arterial aneurysms in infancy and childhood. *Child's Brain*, 3: 193-199.
- AMACHER, A.L., and DRAKE, C.G. (1979). The results of operating upon cerebral aneurysms and angiomas in children and adolescents — I. Cerebral aneurysms. *Child's Brain*, 5: 151-165.
- BECKER, D.H., SILVERBERG, G.D., NELSON, D.H. and HANBERY, J.W. (1979). Saccular aneurysm of infancy and early childhood. *Neurosurgery*, 2: 1-7.
- CARREA, R., SCHUSTER, G., GUEVARA, J.A., GIRARDO, J.M., TARATUTO, A.L. (1974). Classification and specific clinical signs of cerebrovascular disease in children. *Recent Progress in Neurological Surgery. Proceedings of the Symposium of the Fifth International Congress of Neurological Surgery, Tokyo, October 7-13, 1973. Pages 23-26.*
- DRAKE, C.G. (1965). Surgical treatment of ruptured aneurysms of the basilar artery. Experience with 14 cases. *Journal of Neurosurgery*, 23: 457-473.
- DRAKE, C.G. (1979). The treatment of aneurysms of the posterior circulation. *Clinical Neurosurgery*, 22: 96-144.
- DRAKE, C.G. (1975). Ligation of the vertebral (unilateral or bilateral) or basilar artery in the treatment of large intracranial aneurysms. *Journal of Neurosurgery*, 43: 255-274.
- GOLD, A.P., CHALLENGER, Y.B., GILLES, F.H., HILAL, S.P., LIVITON, A., ROLLINS, E.I., SOLOMON, G.E., and STEIN, B.M. (1973). X. Strokes in Children (Part 1). *Stroke*, 4: 835.
- HAMMON, W.M., KEMPE, L.G. (1972). The posterior fossa approach to aneurysms of the vertebral and basilar arteries. *Journal of Neurosurgery*, 37: 339-347.
- HARWOOD-NASH, D.C.F., and FITZ, C.R. (1974). The angiography of vascular anomalies in the newborn and infant. *Recent Progress in Neurological Surgery. Proceedings of the Symposium of the Fifth International Congress of Neurological Surgery, Tokyo, October 7-13, 1973. Pages 37-44.*
- HUMPHREYS, R.P., HENDRICKS, E.B., and HOFFMAN, H.J. (1972). Cerebrovascular disease in children. *Canadian Medical Association Journal*, 107: 774-779.
- JANE, J.A. (1961). A large aneurysm of the posterior inferior cerebellar artery in a 1-year-old child. *Journal of Neurosurgery*, 18: 245-247.
- LAINE, E. (1968). Arterial Vertebral-Basilar Aneurysms. *Progress in Brain Research*, 30: 323-347.
- LOCKSLEY, H.B. (1966). Report on the Cooperative Study of intracranial aneurysms and subarachnoid hemorrhage. Section V, Part I. Natural history of subarachnoid hemorrhage, intracranial aneurysms and arteriovenous malformations. *Journal of Neurosurgery*, 25: 219-239.
- MATSON, D.D. (1965). Intracranial arterial aneurysms in childhood. *Journal of Neurosurgery*, 23: 578-583.
- MAYFIELD, F.H. KEES, G. JR. (1971). A brief history of the development of the Mayfield clip. *Journal of Neurosurgery*, 35: 97-100.
- MCDONALD, C.A., and KORB, M. (1939). Intracranial aneurysms. Special article — *Archives of Neurology and Psychiatry*, (Chicago), 42: 298-328.
- NORNES, H., and WIKEBY P. (1979). Result of microsurgical management of intracranial aneurysms. *Journal of Neurosurgery*, 51: 608-614.
- OJEMANN, R.G., and NEW, P.F.J. (1963). Spontaneous resolution of an intraventricular hematoma. Report of a case with recovery. *Journal of Neurosurgery*, 20: 889-902.
- PATEL, A.N., RICHARDSON, A.E. (1971). Ruptured intracranial aneurysms in the first two decades of life. A study of 58 patients. *Journal of Neurosurgery*, 35: 571-576.
- PIA, H.W. (1972). The surgical treatment of intracerebral and intraventricular haematomas. *Acta Neurochirurgica*, 27: 149-164.
- PICKERING, L.K., HOGAN, G.R., and GILBERT, E.F. (1970). Aneurysm of the posterior inferior cerebellar artery. *American Journal of Diseases of Childhood*, 119: 155-158.
- SEDZIMIR, C.B., and ROBINSON, J. (1973). Intracranial hemorrhage in children and adolescents. *Journal of Neurosurgery*, 38: 261-280.
- SHILLITO, J. (1976). Strokes in children. *Clinical Neurosurgery*, 23: 185-219.
- SHUCART, W.A., and WOLPERT, S.M. (1974). Intracranial arterial aneurysms in childhood. *American Journal of Disease of Childhood*, 127: 288-293.
- THOMPSON, R.A., and PRIBRAM, H.F.W. (1969). Infantile cerebral aneurysm associated with ophthalmoplegia and quadriplegia. *Neurology*, 19: 785-791.
- THOMPSON, J.R., HARWOOD-NASH, D. C., and FITZ, C.R. (1973). Cerebral aneurysms in children. *American Journal of roentgenology*, 118: 163-175.