

## Clinical Record

Dr V Delibas takes responsibility for the integrity of the content of the paper

**Cite this article:** Delibas V, Ocar G, Ugurlugulbukan G, Guney Z, Alagoz S, Ozdas T, Kuran G. How dangerous can a small fish be? A greater weever attack. *J Laryngol Otol* 2022; **137**:350–353. <https://doi.org/10.1017/S0022215121004163>

Accepted: 9 December 2021  
First published online: 10 January 2022


### Key words:

Fish Venoms; Emergencies; Throat

### Author for correspondence:

Dr Vedat Delibas,  
Otorhinolaryngology Department,  
University of Health Sciences,  
Adana City Training and Research  
Hospital, Kislak Neighborhood,  
Dr. Mithat Ozsan Avenue, 4522 Street,  
No: 1, Yuregir, Adana 01000, Turkey  
E-mail: [delibasvedat.vd@gmail.com](mailto:delibasvedat.vd@gmail.com)

# How dangerous can a small fish be? A greater weever attack

V Delibas , G Ocar, G Ugurlugulbukan, Z Guney, S Alagoz, T Ozdas and G Kuran

Otorhinolaryngology Department, University of Health Sciences, Adana City Training and Research Hospital, Adana, Turkey

## Abstract

**Background.** Thraconian fish (weever fish) are poisonous fish found mostly in the eastern Mediterranean region, but also in the eastern Atlantic Ocean, the North Sea and European coastal areas. Greater weever fish belong to the *Trachinus draco* family; these fish have spines on their dorsal fins and gill covers that secrete a high dose of dracotoxin venom.

**Methods.** This paper reports a 35-year-old female who presented with widespread body aches, respiratory distress and hoarseness following a greater weever attack. It discusses respiratory distress and other findings that occur after a greater weever attack in rare otolaryngological emergency cases.

**Conclusion.** While greater weever fish are more likely to attack limbs such as arms and legs, patients stung on the neck who develop respiratory distress are considered an ENT emergency.

## Introduction

Thraconian fish (weever fish) are poisonous fish found mostly in the eastern Mediterranean, but also in the eastern Atlantic Ocean, the North Sea and European coastal areas.<sup>1</sup> Greater weever fish belong to the *Trachinus draco* family; these fish have spines on their dorsal fins and gill covers that secrete a high dose of dracotoxin venom (Figure 1).<sup>1,2</sup> Locally, a sting can cause erythema, temperature increase, pain and myonecrosis in the area where the venom penetrated; systemically, it can cause headache, chest pain, abdominal pain, widespread body aches, palpitations, hypotension, respiratory distress, convulsions and even death.<sup>2</sup>


This paper discusses the medical problems that developed in a patient who was attacked by a greater weever fish, and describes the treatment approach adopted in light of the literature.

## Case report

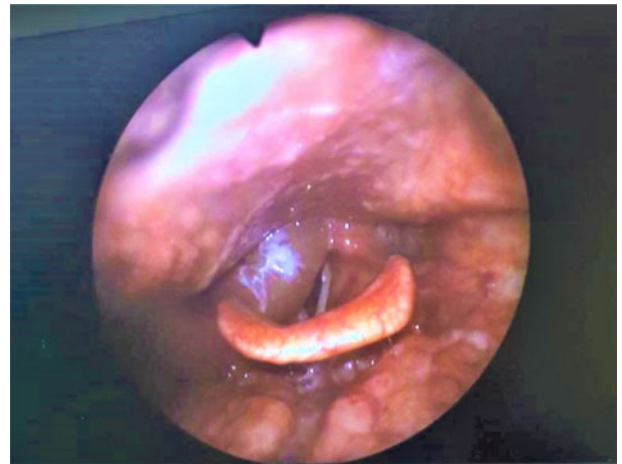
A 35-year-old female patient had pain, redness and swelling in the midline of the neck, the bilateral lower extremities, and the proximal phalanx of the second finger on the left hand after a greater weever attack that occurred whilst sea diving. She presented to our centre with complaints of widespread body aches, respiratory distress and hoarseness (Figure 2). The patient had no known previous history of allergic reactions.

The patient's oropharyngeal examination findings were normal. The flexible fibre-optic nasopharyngolaryngoscopy examination revealed that bilateral vocal folds were mobile, the rima glottidis opening was sufficient, and the right arytenoid and ventricular band were oedematous and medialised (Figure 3). Regarding the patient's vital signs, blood pressure was 130/85 mmHg, oxygen saturation was 99 per cent, temperature was 36.8°C and heart rate was 95 beats per minute. The white blood cell count of the patient was  $22 \times 10^3/\mu\text{l}$  in the complete blood count (normal range in adults is  $4\text{--}11 \times 10^3/\mu\text{l}$ ). The creatine kinase level was 2379 U/l (normal range in an adult female is 26–192 U/l). Other biochemistry, cardiac and coagulation parameters were within normal ranges. Computed tomography examination of the larynx revealed oedema narrowing the laryngeal airway at the supraglottic level on the right side, causing an asymmetrical appearance in the air passage. Intense oedema was observed between the paralaryngeal soft tissues on the right side of the neck (Figure 4).

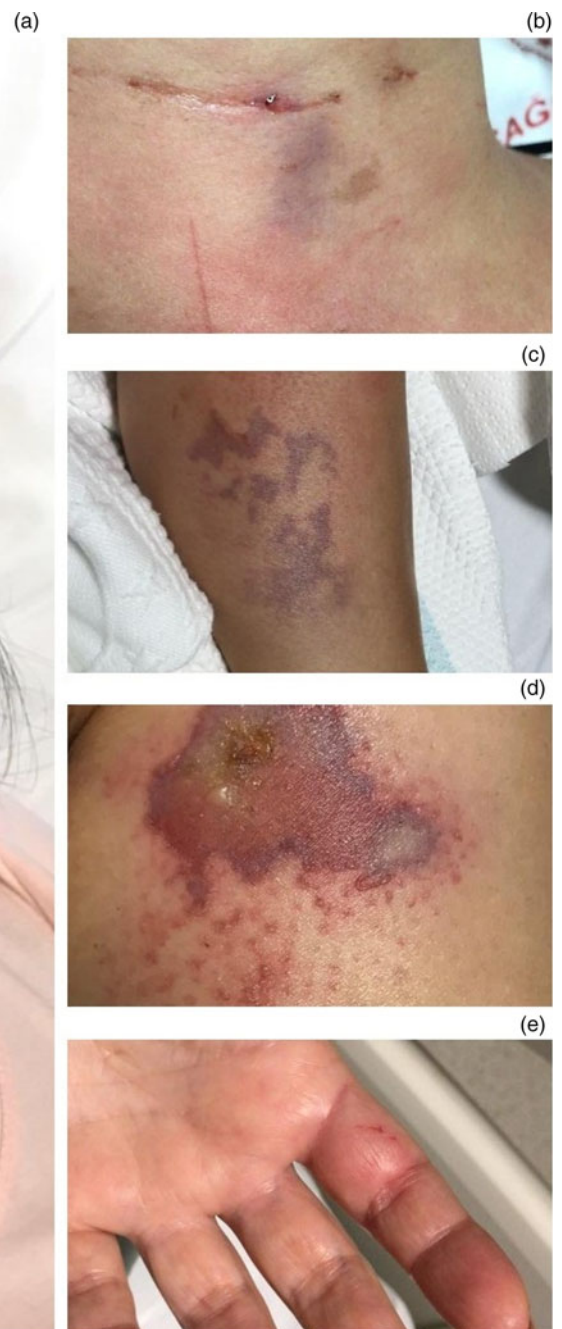
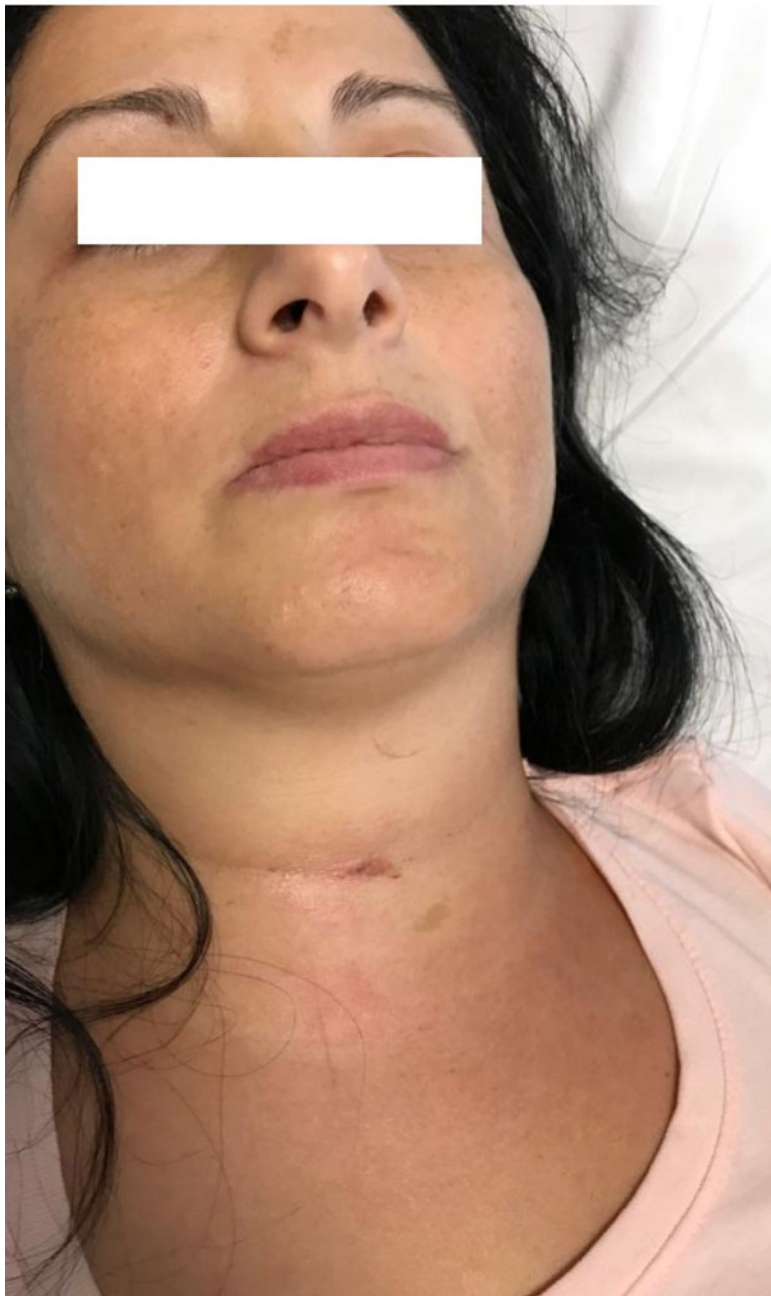The patient was admitted to our service for monitoring and treatment of arytenoid oedema and possible advanced respiratory distress. The areas of the patient that came into contact with the fish were cleaned by washing with warm saline. Foreign bodies in the areas affected were removed. Antibiotics were applied to the wound site (bacitracin (15 000 IU) and neomycin sulphate (150 mg) combination) along with antihistamine (12.5 mg pheniramine hydrogen maleate) ointments. A hot compress was applied. Tetanus prophylaxis was administered. Dexketoprofen trometamol (50 mg/2 ml) was given intravenously twice a day for the patient's pain in the first instance. When this was not sufficient, tramadol hydrochloride (opioid analgesic) (100 mg/2 ml) was administered intravenously once a day if needed. In order to prevent a secondary bacterial



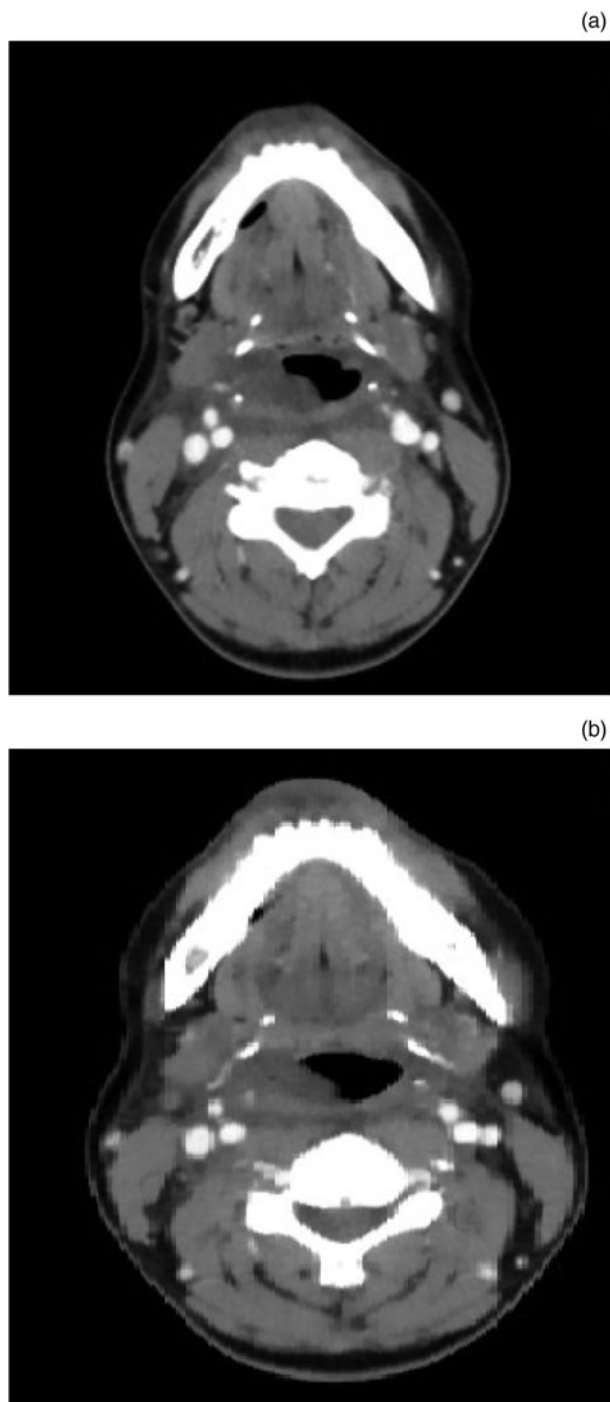
**Fig. 1.** Photograph of a greater weever fish, highlighting the areas (dorsal fin (arrow) and gill covers (circled)) that secrete a high dose of dracotoxin venom.<sup>2</sup>



**Fig. 3.** Right arytenoid and ventricular band oedematous and medialised appearance on flexible fibre-optic nasopharyngolaryngoscopic examination.



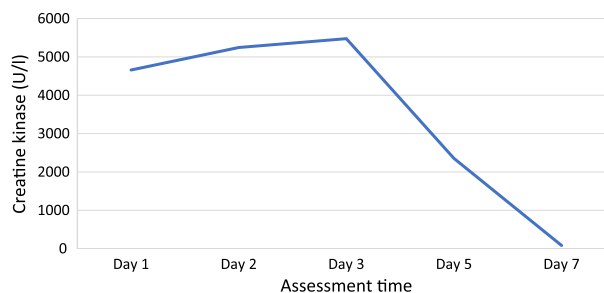
**Fig. 2.** The greater weever fish attack on our patient resulted in: a lesion in the midline of the neck (a & b), bilateral lesions on a lower extremity (c & d), and hyperaemia and oedema in the proximal phalanx of the second finger on the left hand (e).



**Fig. 4.** (a & b) Oedema narrowing the laryngeal airway from the right side at the supraglottic level, observed on axial computed tomography scans of the neck.

infection, prophylactic antibiotic therapy with cefazolin sodium (first generation cephalosporin) was prescribed, with 1 g administered intravenously twice a day. Pheniramine hydrogen maleate (45.5 mg/2 ml) and methylprednisolone (80 mg) were administered intravenously once a day for arytenoid oedema. Cold steam therapy was started.

An increase in creatine kinase levels, to 4658 U/l, was observed on the 1st day of hospitalization. The patient, who was thought to have developed myonecrosis, based on evaluations and clinical findings, was commenced on 1500 cc of 0.9 per cent isotonic sodium chloride and 1500 cc of Ringer's lactate, increasing hydration to a total of 3000 cc of fluid per 24 hours. The creatine kinase levels on the 2nd and 3rd day of



**Fig. 5.** Creatine kinase levels over 7 days in our patient with myonecrosis.

hospitalization were 5245 U/l and 5475 U/l, respectively. The creatine kinase level decreased to 2353 U/l on the 5th day and was 83 U/l on the 7th day, with no increase during follow up (Figure 5).

There was no deterioration in renal function test results during follow up. Creatine kinase elevation, arytenoid oedema, respiratory distress, hoarseness, diffuse body pains and lesions regressed. The patient was discharged at the end of the 10th day. In the first week after discharge, complete recovery was achieved in terms of both clinical and laboratory findings.

## Discussion

While the incidence of small fish attacks is unclear, the number who subsequently seek treatment is thought to be low, far lower than actual number who experience attacks. Because small fish are generally thought to be harmless, only when patients are symptomatic do they present to the hospital.

Clustered glands located on the dorsal fin and gill spines of the greater weever contain dracotoxin.<sup>3,4</sup> Dracotoxin increases vascular permeability and has pain-producing effects, especially membrane depolarisation and haemolytic activities.<sup>1,2</sup> Pores are formed in cell membranes, leading to apoptosis and other effects.<sup>5</sup>

Wild fish stings often affect the lower extremities of fishermen and tourists, causing common symptoms, with prominent erythema. Erythema spreads and oedema appears within a few hours, with an associated feeling of numbness. Inflammation may last for two weeks or more, and the mobility of the affected limb can be quite limited.<sup>4</sup> Following oedema, cellulitis and more advanced myonecrosis may develop in the affected area.<sup>2,4</sup> The patient may be agitated, pale or anxious, and may rarely experience headache, nausea, vomiting, sweating and syncope.<sup>1,4</sup> Deaths from Thraconian fish attacks are rare. Before the discovery of the antibiotic, three deaths from Thraconian fish in the Thrace region were reported.<sup>2</sup>

The first approach to treatment is to clean the affected area in order to remove any remaining venom. The affected area should be immersed in hot water (approximately 40°C) for around 60–90 minutes.<sup>1,2</sup> However, care should be taken to avoid scalding by not exceeding these temperature and time values.<sup>2</sup> It is not fully understood why immersion in hot water reduces the symptoms of fish stings.<sup>3</sup> Cold application makes the pain worse.<sup>1,2</sup> Given that the pain experienced is not likely to be at a tolerable level, firstly simple painkillers and then opioid painkillers should be administered, when necessary.<sup>1,2</sup>

Local wound cleaning, debridement and tetanus prophylaxis are provided when necessary. Infection is rare, but if a

local infection does develop, antibiotics will be necessary and may be considered for prophylaxis in the immunocompromised patient.<sup>1,2</sup>

- Small fish attacks are generally thought to be harmless, and the precise incidence is not known as patients attend hospital only when symptomatic
- While weever fish are often more likely to attack limbs such as arms and legs, stings on the neck can cause respiratory distress and become an ENT emergency
- Dracotoxin can cause oedema inflammation and necrosis or myonecrosis
- Although there is no standard treatment for this rare presentation, conservative therapy is recommended

In conclusion, our case is important in terms of the described neck with extremity involvement and the narrowing of the laryngeal air passage associated with local allergic reactions. No such case has previously been reported in the

literature. This paper contributes to the literature by sharing the treatment details and follow up of our case.

**Competing interests.** None declared

## References

- 1 Davies RS, Evans RJ. Weever fish stings: a report of two cases presenting to an accident and emergency department. *J Accid Emerg Med* 1996;**13**:139–41
- 2 Yıldız T, Karakulak FS. Toxic effects of weever fishes among poisonous fishes along the coast of Turkey [in Turkish]. *Aquatic Sci Eng* 2018;**33**:20–4
- 3 Emerson D. Treating envenomation caused by fish sting. *Emerg Nurse* 2012;**20**:28–9
- 4 Fezai M, Slaymi C, Ben-Attia M, Lang F, Jemaà M. Purified lesser weever fish venom (*Trachinus vipera*) induces eryptosis, apoptosis and cell cycle arrest. *Sci Rep* 2016;**6**:39288
- 5 Gorman LM, Judge SJ, Fezai M, Jemaà M, Harris JB, Caldwell GS. The venoms of the lesser (*Echiichthys vipera*) and greater (*Trachinus draco*) weever fish - a review. *Toxicon X* 2020;**6**:100025