

Concordant Symptomatic Intracranial Aneurysm in a Monozygotic Twin: A Case Report and Review of the Literature

Mark ter Laan,¹ Wilhelmina S. Kerstjens-Frederikse,² Jan D. M. Metzemaekers,¹ J. Marc C. van Dijk,¹ and Rob J. M. Groen¹

¹ Department of Neurosurgery, University Medical Center Groningen, University of Groningen, The Netherlands

² Department of Genetics, University Medical Center Groningen, University of Groningen, The Netherlands

The development of an intracranial aneurysm (IA) is a multifactorial process, involving genetic and environmental factors. The presence of IA or aneurysmal subarachnoid hemorrhage (aSAH) in twins is particularly interesting, since both genetic and environmental factors can be studied. It also raises the question of whether, when one twin is affected, the other asymptomatic twin should be examined for an IA. We report on a monozygotic (MZ) twin-pair with aSAH in both twins and we review all reported cases of IA in MZ twins. Including our case, we found only 14 MZ twin-pairs in which both twins harbored an IA, suggesting a heavy underreporting in the medical literature. In this small group, a high concordance was noted in the sites of IAs. In MZ twins, the preferred sites for IAs are the branching arteries, while aneurysms arising from fusion arteries are rare. These sites differ from the preferential sites seen in series of familial IAs and series of sporadic IAs. We therefore hypothesize that the twinning process might play a significant role in the development of IAs in MZ twins. To further explore and substantiate this, the large twin registries should be studied. Although IAs in MZ twins with a negative family history for IAs should not be regarded as *familial* IAs, screening of the asymptomatic twin should be seriously considered if one MZ twin presents with an aSAH or an IA, because of the high fatality rates reported in asymptomatic (and not screened) MZ twin-halves.

Keywords: aneurysmal subarachnoid hemorrhage, intracranial aneurysm, monozygotic twins, concordance, twinning process, mirroring, screening

Intracranial aneurysms (IAs) are acquired lesions. Both genetic and environmental factors play a role in the pathogenesis of IAs and they are therefore classified as a complex disease. The two main lines of evidence for a genetic predisposition are: (1) the association of IAs in several genetic disorders, such as Ehlers-Danlos syndrome (EDS) and autosomal dominant polycystic kidney disease (ADPKD); and (2) the

familial occurrence of IAs (Nahed, 2007; Schievink, 1997). Cigarette smoking is the only environmental factor that has consistently been identified as playing a role in the pathogenesis of IAs in all the populations studied (Schievink, 1997). Arterial hypertension and a moderate-to-high level of alcohol consumption also pose a risk of aneurysmal subarachnoid hemorrhage (aSAH) (Schievink, 1997). The diagnosis of aSAH or IA in twins is particularly interesting, since both genetic and environmental factors can be studied. The presence of an aSAH in one monozygotic twin also raises the question of whether the other, asymptomatic twin should also be examined for an IA. Only a limited number of twins with IAs have been reported, so here we report briefly on our MZ twin-pair with IA in both twins and we review all the cases reported in the literature.

Case Report

Patient A

A 49-year-old healthy male (patient A) presented at our emergency department. He had started to suffer from a sudden severe headache accompanied by nausea and neck pain three days earlier. He had experienced no loss of consciousness or other relevant complaints. This patient was a heavy smoker and suffered from arterial hypertension. A CT scan of the brain (3 days after the onset of symptoms) was normal. CSF examination confirmed the clinical suspicion of a subarachnoid hemorrhage and CT angiography revealed a multi-lobular aneurysm of the anterior communicating artery (Figure 1). This aneurysm was treated successfully the next day by endovascular coiling. The patient was discharged 8 days after admission in good medical condition. Angiographical follow-up was unremarkable.

Received 4 October, 2008; accepted 26 March, 2009.

Address for correspondence: Rob J. M. Groen, Department of Neurosurgery, University Medical Center Groningen, PO Box 30001, 9700 RB Groningen, The Netherlands. E-mail: r.j.m.groen@nchr.umcg.nl

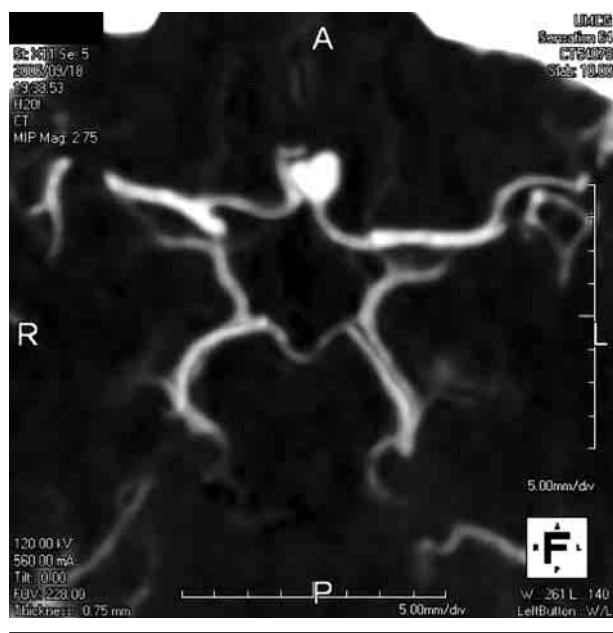


Figure 1
CT angiography of our patient A, showing a bilobular aneurysm of the anterior communicating artery.

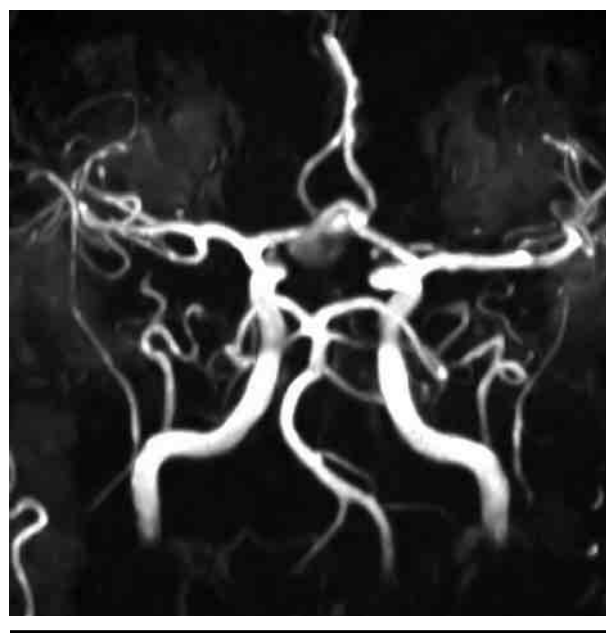


Figure 2
MR angiography of our patient B showing an aneurysm of the anterior communicating artery.

Patient B

The monozygotic twin brother (patient B) of our index case (patient A) had suffered an aSAH 4 years earlier, at the age of 45 years. He too was a heavy smoker and had arterial hypertension. He had presented 2 days after a sudden onset of severe headache with neck pain and nausea. A CT scan of the brain confirmed the clinical suspicion of a SAH. MR angiography showed a multi-lobular anterior communicating artery aneurysm (Figure 2) that was treated by surgical clipping. He was discharged in a good clinical condition. Follow-up was uneventful. There were no other siblings or family members with a history of IA and/or aSAH. Monozygosity of the twins was confirmed by DNA testing, using seven polymorphic markers on different chromosomes.

Literature Review

Methods

We searched our files for any other twins with IA over the past 20 years. In order to identify reports of twins with IA in the literature, we searched the databases of *Medline*, *PubMed*, *Embase* and *ISI Web of Science*, using the terms ‘monozygotic twins’, ‘dizygotic twins’, ‘subarachnoid hemorrhage’ and ‘intracranial aneurysm’, or combinations of these. In addition, reference lists in selected papers were checked for related articles. Articles in foreign languages were also translated and checked.

Results

The literature search led to 18 papers dealing with twins, subarachnoid hemorrhage and intracranial aneurysms: 16 reported on monozygotic twins and

one reported two dizygotic (DZ) twin-pairs in which only one of the twins had an aneurysm, but where two or more individuals with IAs were known in the respective families (Leblanc et al., 1995). One paper mentioned 101 cases of SAH in twins but gave no further details (Koskenvuo et al., 1992). One historical report mentioned a twin-pair with probable aneurysmal SAH in both, but gave very few details and was therefore excluded (O’Brien, 1942).

The details of 14 monozygotic twin-pairs, including our present twins, are listed in Table 1. In eight pairs (including our case), both twins had an aSAH (Brisman & Abbassioun, 1971; Fairburn, 1973; Hagen et al., 1997; Nakajima et al., 1998; Ohno et al., 2004; Schon & Marshall, 1984; Wilson & Cast, 1973), in six pairs the other (non-symptomatic) twin was found to have one or more aneurysms after screening (Hager & Steiger, 2004; Parekh et al., 1992; Porter, 2001; Sakovich et al., 1998; Sharma & Brown, 2001; Weil et al., 1988). All except one individual had their aSAH between age 30–50 years (mean age at time of rupture: 40.5 years). The average time between aSAH occurring in both twins was less than 4.5 years (range 2–10 years in 8 pairs). Six twin-pairs (including our own) were concordant (i.e., their IAs were at exactly the same site), four twin-pairs with multiple IAs had some at the same site, while in three twin-pairs the IAs were identical but on opposite sides (mirroring). Multiple aneurysms were present in 36% of these individuals (Table 1). Monozygosity of the twins was concluded in most cases based upon the identical phenotype of the twins. It was confirmed by DNA testing in only four pairs (including our present case). Two monozygotic twin-pairs were reported with

Table 1

Characteristics of 14 Reported Pairs of Identical Twins with Intracranial Aneurysms in Both Twins

Reference	Age (years)/ Gender	Signs and treatment	Site of aneurysm(s)	Monozygosity
(Brisman & Abbassioun, 1971)	30/F 35/F	SAH , clipping (2x) SAH , fatal	MCA L and R ICA R	Likely but not confirmed
(Fairburn, 1973)	44/F 46/F	SAH , ligation SAH , no treatment	<i>ICA R</i> <i>ICA L</i>	Confirmed
(Hagen et al., 1997)	39/F 41/F	SAH , clipping (3x) SAH , clipping (2x), fatal	ICA and MCA (2x) R ICA and MCA R , PCoM A R and L	Likely but not confirmed
(Hager & Steiger, 2004)	40/F 40/F	SAH, clipping Screening, clipping	MCA R MCA R	Likely but not confirmed
(Nakajima et al., 1998)	36/F 46/F	SAH , clipping SAH , clipping	<i>MCA R</i> <i>MCA L</i>	Likely but not confirmed
(Ohno et al., 2004)	39/M 42/M	SAH , clipping SAH , clipping, fatal	MCA L MCA L	Likely but not confirmed
(Parekh et al., 1992)	36/F 37/F	Epilepsy, clipping (2x) SAH, fatal	<i>MCA L</i> and <i>PICA L</i> <i>MCA R</i>	Likely but not confirmed
(Porter, 2001)	41/F 41/F	SAH, coiling (1x) Screening, clipping (2x)	BA , SupCerebA L BA , PCoM A R	Likely but not confirmed
(Sakovich et al., 1998)	45/F 46/F	SAH, clipping Screening, follow-up	ICA R ICA R and L	Confirmed
(Schon & Marshall, 1984)	39/M 43/M	SAH , clipping, fatal SAH , fatal	ACoM A ACoM A	Likely but not confirmed
(Sharma & Brown, 2001)	45/F 45/F	SAH, clipping (1x) Screening, follow-up	ICA R , MCA R and L ICA R	Likely but not confirmed
(Weil et al., 1988)	43/F 43/F	SAH, clipping (2x) Screening, clipping (1x)	ICA R and L , PCoM A L , BA ICA R and L , PCoM A L , BA	Confirmed
(Wilson & Cast, 1973)	42/F 45/F	SAH , no treatment SAH , fatal	MCA L MCA L	Likely but not confirmed
Present cases, 2009	45/M 49/M	SAH , clipping SAH , coiling	ACoM A ACoM A	Confirmed

Note: F, female; M, male; L, left; R, right; SAH, subarachnoid hemorrhage; MCA, middle cerebral artery; ICA, internal carotid artery; PCoM A, posterior communicating artery; PICA, posterior inferior cerebellar artery; BA, basilar artery; SupCerebA, superior cerebellar artery; ACoM A, anterior communicating artery.

Abbreviations in **bold** represent concordant clinical presentation and/or concordant aneurysm(s), abbreviations in *italic* represent mirroring aneurysms.

only one twin having an IA and the other a negative screening result (not shown in table) (Astradsson & Astrup, 2001; Puchner et al., 1994).

Discussion

To date, only 16 MZ twin-pairs and two DZ twin-pairs with IAs have been reported. This number is extremely low, and it is very likely due to underreporting. The prevalence of IAs in MZ twins (as a sporadic case in an unaffected family) should be the same as in the general population: at least 2.3% (Rinkel, 2005). A rough calculation for the situation in the Netherlands (with approximately 17 million inhabitants) leads to an estimate of 60 MZ twin-halves with aSAH that should have been treated in the past 20 years in Dutch neurosurgical centers. However, our present case is the only MZ twin-pair reported in our country. There are several possible explanations as to why so few cases have been reported in the international and national medical journals. First, the issue of twinning is not a routine

question when a patient is admitted, especially not in the emergency of an acute SAH. Second, if the aSAH is fatal, the patient is not followed-up, and questioning about familiarity and twinning can easily be omitted. Third, geographical factors (both members of a twin living in different countries or different areas) can interfere with the collection of the data required for proper analysis. Fourth, medico-legal issues (difficulties to get access to files, post-mortem destruction of patient data) may be responsible for frustrating research and result in failure to complete the report. Fifth, the issue of screening and the debate about the screening method, and the suitability of available treatment options may result in a decision not to proceed with testing of the other twin. The very low number of reported cases also implies there is a realistic risk of selection bias.

Genetic factors are obviously important in patients with familial IAs and in patients with specific, heritable, connective tissue disorders (EDS, ADPKD) (Hager & Steiger, 2004; Lozano & Leblanc, 1987; Schievink, 1997; Wardlaw & White, 2000). Several aspects

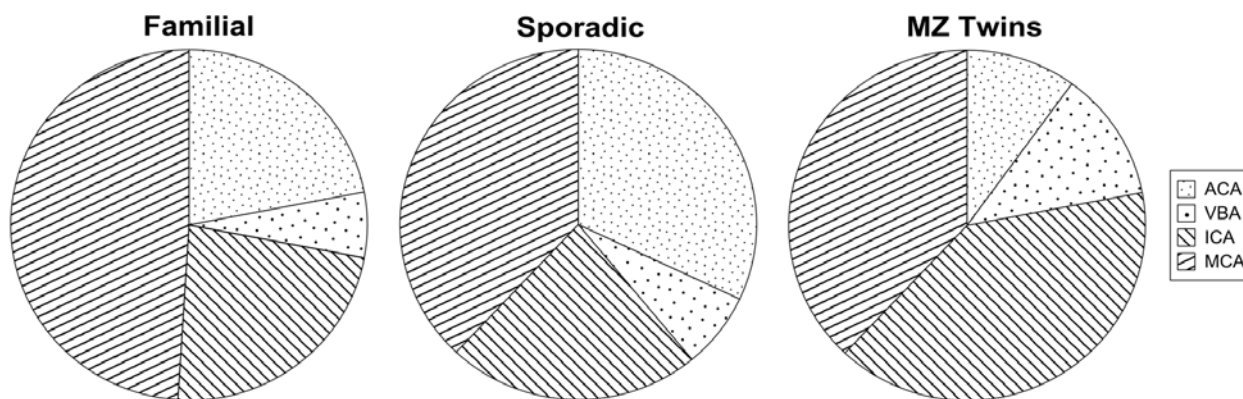


Figure 3

Aneurysm sites in familial, sporadic and monozygotic twin cases.

Note: ACA = anterior cerebral artery, VBA = vertebro-basilar artery, ICA = internal carotid artery, MCA = medial cerebra artery. ICA and MCA develop by branching (dots), ACA and VBA by fusion (stripes).

suggest that familial IAs are a separate disorder to sporadic IAs (Hagen et al., 1997; Hager et al., 2004; Lozano & Leblanc, 1987; Norrgard et al., 1987; Ruigrok et al., 2004). Although IAs may be complex diseases, several published pedigrees are compatible with an autosomal dominant mode of inheritance (with reduced penetrance) (Schievink et al., 1994; Verlaan et al., 2006; Wills et al., 2003), and based on this, screening of individuals with two or more affected first-degree relatives is generally advised (Rinkel, 2005). When confronted with one MZ twin with a cerebral aneurysm, it should be realized that MZ twins are genetically one individual. As such, a MZ twin-pair with IA(s) in both twins does not represent *familial* IAs but (provided their family history for IAs is negative) they are an example of *sporadic* IA(s). Consequently, one might expect the aneurysm characteristics of MZ twins with sporadic IAs to differ from those of familial IAs, and to resemble those of sporadic IAs. However, when we compared the characteristics of the present series of MZ twins with a series of familial IAs reported by Ronkainen (1995) and a series of sporadic IAs reported by Ellamushi (2001), we found the localization of the aneurysms in MZ twins differs from both familial IAs and sporadic IAs (see Figure 3). In MZ twins, aneurysms arising from the anterior communicating artery and basilar artery (both are fusion arteries) are rare, and the preferred sites for IAs are seen equally in the internal carotid artery (ICA) and middle cerebral artery (MCA) (both are branching arteries). In familial IAs, MCA aneurysms predominate (Ronkainen, 1995), while anterior communicating artery aneurysms are most frequently seen in sporadic cases (Ellamushi, 2001).

In 10 MZ twin-pairs (10/14 = 71%), IAs were located on the same vascular segment, and in three MZ twin-pairs (3/14 = 21%), IAs were mirroring (see Table 1). Mirroring of developmental anomalies is a phenomenon that occurs in 20 to 25% of MZ twin-pairs (Springer, 1978). The event leading to mirror-image

anomalies is thought to be directly related to the twinning process, and is explained by the incomplete redefinition of laterality after the MZ embryos separated (Sperber, 1994). From this perspective, mirroring in MZ twin-pairs also represents concordance. This means that 93% of MZ twin-pairs in the present review were concordant with respect to the site of their IA(s). Although very speculative, these peculiarities might suggest there is a correlation between aneurysm site and MZ twinning. The division of the blastocoel to form MZ twins occurs just before implantation. This is thought to disrupt the developmental clock, putting the two resulting embryos at a disadvantage, rendering them more susceptible to environmental agents, and leading to developmental arrest (Hall, 2003; Myriantopoulos, 1978). A zygote that is delayed at an early stage of its development (i.e. at the time of the monozygotic split) is more likely to be delayed later on and, consequently, is more likely to be affected by a malformation (Hall, 2003; Myriantopoulos, 1978). With respect to the classification of cerebrovascular malformations, a subdivision into fusion and branching anomalies is made. During embryogenesis at the level of the circle of Willis, both fusion and branching mechanisms play a role (Hager & Steiger, 2004). The basilar artery and anterior communicating artery result from fusion, while the bifurcation of the ICA is formed by branching of the primitive ICA. Development of aneurysms in the ICA as well as the MCA may be considered as branching errors (Hager & Steiger, 2004). Since the process of branching takes much more time than fusion (Padgett, 1948), it can be speculated that the chances of a branching error are higher in MZ twins, because of the developmental delay that results from the twinning process. This might be the explanation for the high percentage of MCA- and ICA-aneurysms detected in MZ twins in the present review group (see Figure 3). In order to further substantiate this, reliable data are needed on the incidence and characteristics of IAs in MZ and DZ twins.

Clearly, the above speculations and hypotheses need to be tested by comparing the details of large numbers of DZ and MZ twins. This could lead to new insights into the role of developmental, environmental and genetic factors in IA formation, and could eventually provide reasons for screening. The available large twin registries (e.g. the Finnish Twin Cohort (Koskenvuo et al., 1992)) should be studied for this purpose.

The fatality rate for aneurysm rupture in the second twin, if no screening was conducted after aSAH in the index twin, proved to be very high (6/9 [67%]). In contrast, if IAs were identified during screening of the second twin (five patients), there were no fatalities reported. Based on these findings, and until more evidence about IAs in relation to MZ-twinning is available, screening (and eventual treatment) of the asymptomatic MZ twin should be strongly considered if the other twin has presented with an aSAH (Porter, 2001; Rinkel, 2005).

Conclusions

The finding of IAs and/or aSAH in MZ twins is an intriguing phenomenon. Very likely, such cases are heavily underreported, because we found only 16 pairs of MZ twins with IAs in the international literature. This small number of cases means it is difficult to compare with familial and sporadic IAs. The characteristics of IAs in the present series of MZ twins seem to be different from those in reported series of familial and sporadic IAs, and suggests MZ twins have a prevalence of IAs in the branching arteries. There seems to be a high concordance in the sites for IAs in MZ twins, which might be related to the process of MZ-twinning (i.e., [dys]embryogenesis and (incomplete) redefinition of laterality resulting in mirroring). However, selection bias and the very small number of reported cases might also be responsible for this finding. To clarify this, and to test the hypotheses about the etiology of IAs in MZ twins, there should be studies started on the large twin registries — like the Finnish Twin Cohort (Koskenvuo et al., 1992).

Based on what is now known about the clinical course of IAs in MZ twins, we advise screening of the asymptomatic twin after an aSAH in an index twin. Future research will hopefully provide a well-founded guideline.

Acknowledgments

We thank Jackie Senior for editing the manuscript.

References

Astradsson, A., & Astrup, J. (2001). An intracranial aneurysm in one identical twin, but no aneurysm in the other. *British Journal of Neurosurgery*, *15*, 168–171.

Brisman, R., & Abbassioun, K. (1971). Familial intracranial aneurysms. *Journal of Neurosurgery*, *34*, 678–682.

Ellamushi, H. E. (2001). Risk factors for the formation of multiple intracranial aneurysms. *Journal of Neurosurgery*, *94*, 728–732.

Fairburn, B. (1973). ‘Twin’ intracranial aneurysms causing subarachnoid haemorrhage in identical twins. *British Medical Journal*, *1*, 210–211.

Hagen, T., Neidl, K., & Piepgras, U. (1997). Multiple cerebral aneurysms in identical twins. *American Journal of Neuroradiology*, *18*, 973–976.

Hager, P. & Steiger, H. J. (2004). Identical cerebral aneurysms in siblings: Report of two families. *Journal of Clinical Neuroscience*, *11*, 80–84.

Hall, J. G. (2003). Twinning. *Lancet*, *362*, 735–743.

Koskenvuo, M., Kaprio, J., & Romanov, K. (1992). Twin studies in metabolic diseases. *Annals of Medicine*, *24*, 379–381.

Leblanc, R., Melanson, D., Tampieri, D., & Guttmann, R. D. (1995). Familial cerebral aneurysms: A study of 13 families. *Neurosurgery*, *37*, 633–638.

Lozano, A. M. & Leblanc, R. (1987). Familial intracranial aneurysms. *Journal of Neurosurgery*, *66*, 522–528.

Myriantopoulos, N. C. (1978). Congenital malformations: The contribution of twin studies. *Birth Defects Original Article Series*, *14*, 151–165.

Nahed, B. V. (2007). Genetics of intracranial aneurysms. *Neurosurgery*, *60*, 213–225.

Nakajima, H., Kishi, H., Yasui, T., Komiyama, M., Iwai, Y., Yamanaka, K., & Nishikawa, M. (1998). Intracranial aneurysms in identical twins. *Surgical Neurology*, *49*, 306–308.

Norrsgard, O., Angquist, K. A., Fodstad, H., Forsell, A., & Lindberg, M. (1987). Intracranial aneurysms and heredity. *Neurosurgery*, *20*, 236–239.

O’Brien (1942). Subarachnoid hemorrhage in identical twins. *British Medical Journal*, *1*, 607–608.

Ohno, S., Ikeda, Y., Onitsuka, T., Nakajima, S., Uchino, H., Haraoka, J., & Yamagata, Z. (2004). [Cerebral aneurysms in identical twins]. *No Shinkei Geka*, *32*, 875–879.

Padget, D. H. (1948). Development of the cranial arteries in the human embryo. *Carnegie Contributions to Embryology*, *32*, 205–261.

Parekh, H. C., Gurusinghe, N. T., & Sharma, R. R. (1992). Cerebral berry aneurysms in identical twins: A case report. *Surgical Neurology*, *38*, 277–279.

Porter, P. J. (2001). What to do when the doctor sees double: Identical twins with nearly identical aneurysms. *Interventional Neuroradiology*, *7*, 153–160.

Puchner, M. J., Lohmann, F., Valdueza, J. M., Siepmann, G., & Freckmann, N. (1994). Monozygotic twins not identical with respect to the existence of intracranial aneurysms: A case report. *Surgical Neurology*, *41*, 284–289.

- Rinkel, G. J. (2005). Intracranial aneurysm screening: Indications and advice for practice. *Lancet Neurology*, 4, 122–128.
- Ronkainen, A. (1995). Special features of familial intracranial aneurysms: report of 215 familial aneurysms. *Neurosurgery*, 37, 43–46.
- Ruigrok, Y. M., Rinkel, G. J., Algra, A., Raaymakers, T. W., & van Gijn, J. (2004). Characteristics of intracranial aneurysms in patients with familial subarachnoid hemorrhage. *Neurology*, 62, 891–894.
- Sakovich, V. P., Lebedeva, E. R., & Nalesnik, M. V. (1998). [Heredity in intracranial aneurysms (a study of identical twins)]. *Zhurnal voprosy neirokhirurgii imeni N.N.Burdenko*, 33–35.
- Schievink, W. I. (1997). Intracranial aneurysms. *New England Journal of Medicine*, 336, 28–40.
- Schievink, W. I., Schaid, D. J., Rogers, H. M., Piepgras, D. G., & Michels, V. V. (1994). On the inheritance of intracranial aneurysms. *Stroke*, 25, 2028–2037.
- Schon, F. & Marshall, J. (1984). Subarachnoid haemorrhage in identical twins. *Journal of Neurology Neurosurgery and Psychiatry*, 47, 81–83.
- Sharma, P. & Brown, M. J. (2001). Neurovascular lessons from a pair of identical twins with cerebral aneurysms. *Postgraduate Medical Journal*, 77, 197–198.
- Sperber, G. H. (1994). Mirror-image dental fusion and discordance in monozygotic twins. *American Journal of Medical Genetics*, 51, 41–45.
- Springer, S. P. (1978). Laterality in twins: The relationship between handedness and hemispheric asymmetry for speech. *Behavior Genetics*, 8, 349–357.
- Verlaan, D. J., Dube, M. P., St-Onge, J., Noreau, A., Roussel, J., Satge, N., Wallace, M. C., & Rouleau, G. A. (2006). A new locus for autosomal dominant intracranial aneurysm, ANIB4, maps to chromosome 5p15.2–14.3. *Journal of Medical Genetics*, 43, e31.
- Wardlaw, J. M. & White, P. M. (2000). The detection and management of unruptured intracranial aneurysms. *Brain*, 123, 205–221.
- Weil, S. M., Olivi, A., Greiner, A. L., & Tobler, W. D. (1988). Multiple intracranial aneurysms in identical twins. *Acta Neurochirurgica (Vienna)*, 95, 121–125.
- Wills, S., Ronkainen, A., van, d., V, Kuivaniemi, H., Helin, K., Leinonen, E., Frosen, J., Niemela, M., Jaaskelainen, J., Hernesniemi, J., & Tromp, G. (2003). Familial intracranial aneurysms: An analysis of 346 multiplex Finnish families. *Stroke*, 34, 1370–1374.
- Wilson, P. J. & Cast, I. P. (1973). ‘Twin’ intracranial aneurysms. *British Medical Journal*, 1, 484.
-