

WOLF'S SYNDROME IN TWINS — TRANSLOCATION IN THE MOTHER

M. LEVY, B. NOEL, D. VIOLA

Department of Pediatrics (Péd. A), Centre Hospitalier de Metz, and Laboratory of Cytogenetics, Chambéry, France

A case of MZ twins, both affected by Wolf's syndrome, is described. Their mother, of subnormal look and low intellectual level is translocated. The children, born with a weight and size much below the average, show a very special morphotype: a hook-nose, an abnormal conformation of the back edge of the nostrils (a protrusion in the shape of a horn overhanging the filtrum), hypertelorism, microcephaly. Great asynchronism in the maturation of the bones and a somatoschisis of the body of the cervical vertebrae are noted. Deletion of the short arm chromosome 4 is juxtacentromeric. The study of blood and tissue groups corroborates monozygosity. Dermatoglyphs are little abnormal and identical in the two children. The mother's family is phenotypically normal. At 19 months of age, measuring is still below 4, psychomotor progress is extremely weak, and convulsions are frequent.

The twins we report were born after a normal gestation of 30 weeks or so; nevertheless the date of the last menses is firmly established. The mother was not submitted to either physical or chemical traumatic agents and no consanguinity can be found between the parents. The mother is 22; it is her first pregnancy. She is slightly deficient, but offers no somatic malformations. She has two sisters who are in good health, not abnormal, each with normal children. The father, aged 32, is of North African origin and doesn't present any malformation either.

The delivery of the twins is fast, Apgar's score at 1 minute is respectively 6 and 9; the twins are slightly cyanotic but reanimation has immediate effects. Immediately after they are admitted in the Department of Prematures, one is struck by three facts in particular: (1) their features are exactly alike; (2) their faces are most abnormal and immediately call to mind the possibility of genotypic abnormality; (3) their measures establish an obvious hypotrophy that is still considerable now they are 19 months old.

The malformations shown by these twins are superposable, so we shall describe them without making any difference between the two children. The skull is small, the implantation of the hair is normal: temporal sinuses deeply marked, two points spreading down the nape of the neck. The eyebrows are curved, a little thicker on the outside than on the inside; the palpebral fissures are slightly antimongoloid and both children show epicanthus on the right. Besides, one notes hypertelorism and very thick eyelids coming down abnormally over the irises. The front view shows the nose is distinctly flattened, especially the tip; the middle partition is thick and the nostrils nearly look like transversal slits. The two ridges of filtrum are quite marked and up to the openings of the nostrils in which they end in a small protrusion. Side-face, the face shows a nose strongly beaked on the tip. The corners of the mouth are falling, the palate is very hollow. The ears are normally set but not curled at all. Besides, one notes a bilateral dimple on the root of the helix. The trunk is normal except for the presence of umbilical hernia and mongolian spots on the buttocks in the two children, on the ankle and one shoulder respectively in one and the other. The top of the intergluteal groove is marked by a deep paramedian dimple situated on the right in one child and on the left in the other. The nails of both hands and feet are marked with horizontal striations, those of the upper limbs disappearing towards 7 months of age.

The curves of weight, size and head circumference remain below the 4th standard deviation, corroborating the delay in intrauterine growth. Indeed, that delay is obvious even if one agrees with the date of gestation stated by the mother. Nevertheless, morphological and neurological criteria give the impression that the infants are much more mature than 30 weeks allow.

Psychomotor evolution is marked first by the quick appearance of important hypotonia and the abnormally long presence of archaic reflexes, then by severe psychomotor retardation at 19 months, these children can

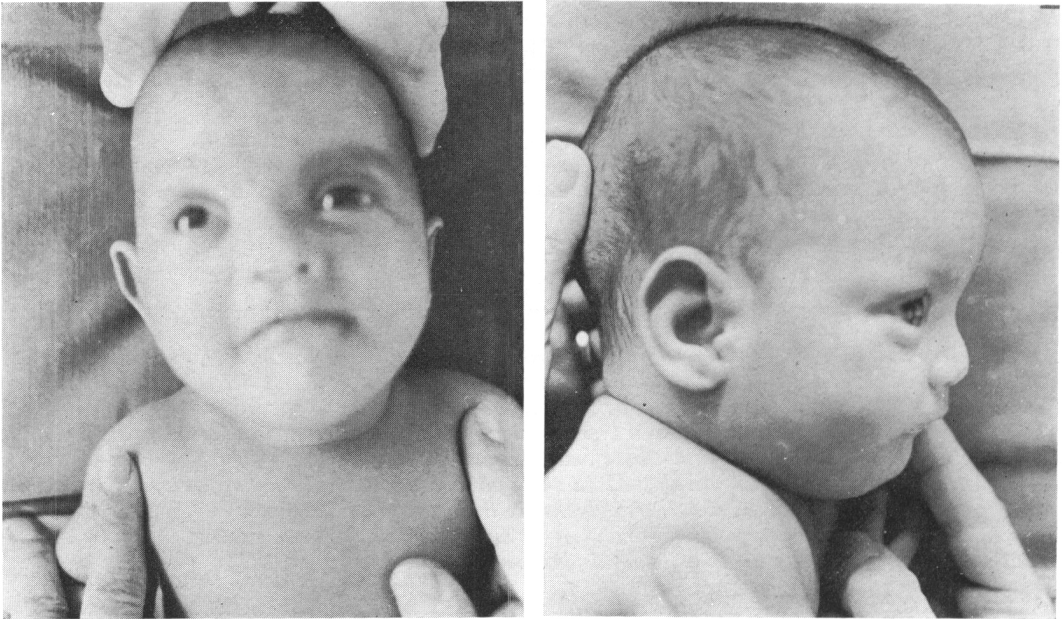

Fig. 1a,b. One of the twins aged 3 months.

neither smile nor hold their heads. Ultimately, from 9 months onward, appear many seizures controlled by barbituric treatment, this occurs again soon after the children are taken home, probably because treatment is interrupted.

X-ray studies show great asynchronism in maturation as far as bone age is concerned: a long delay for the upper limbs, the presence of normal centers of ossification in the lower limbs. Besides, one notes a dislocated left hip in one of the twins and, in both, no join in the nucleus of the vertebral bodies of the 3rd and 4th cervical vertebrae, an anomaly that still persists.

The cytogenetic study is carried out at the Laboratory of Cytogenetics of Chambéry. The various methods used are for R bands (Dutrillaux and Lejeune 1971), C bands (Arrighi and Tsu 1971), QA bands (Pearson modified by Noël et al. 1974), B OA bands (Dutrillaux et al. 1973). The karyotypes of the twins show a deletion of the short arms of chromosome 4. This deletion can be found in the mother who shows a balanced karyotype by reciprocal translocation at the end of the long arms of chromosome 12.

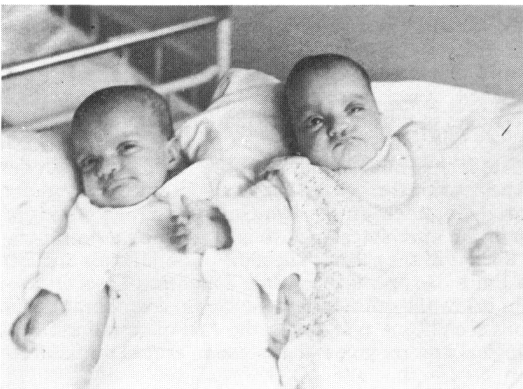


Fig. 2. The twins aged 3 months.



Fig. 3. The twins aged 16 months.

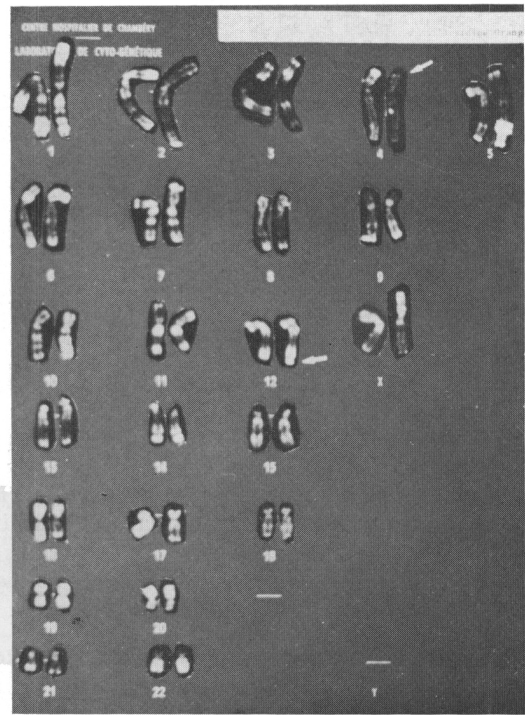
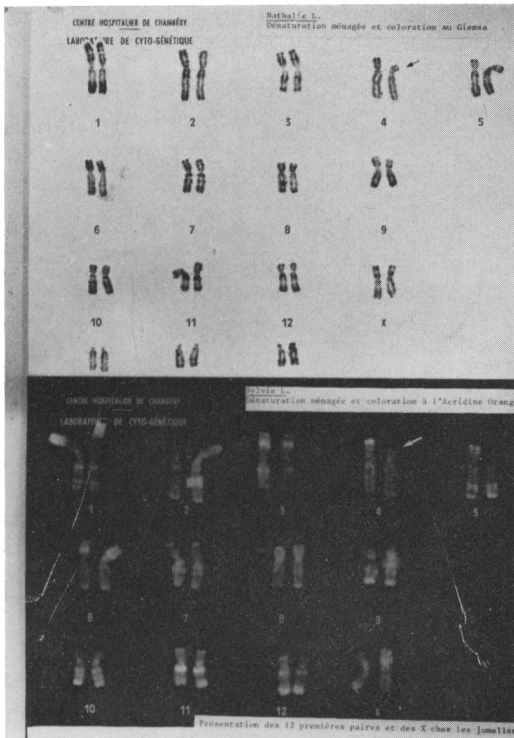


Fig. 4. Karyotype of Nathalie L., one of the twins: 1. Giemsa; 2. Acridine Orange. Fig. 5. Karyotype of the mother (Acridine Orange).

The two sisters of the mother and the father have normal karyotypes. The study of blood markers of the mother and the two daughters shows a probability of dizygosity of 0.000227 that is, 2/10,000. The dermatoglyphs show comparatively few anomalies, as usual in Wolf's syndrome, and are roughly superimposable.

The anomalies described here are common in Wolf's syndrome. Only microretrognathism is lacking here among the malformations comparatively frequent in such children. On the contrary, the vertebral anomalies in our twins do not appear in any observation previously published and still persist at present.

The syndrome of deletion of the short arm of the 4th chromosomal pair was identified in 1965 by Wolf et al. thanks to the technique of autoradiography. Before that date, a few cases had been reported as "cri du chat" disease caused by deletion in the arm of chromosome 5. In March 1974, 42 cases of 4 p — were mentioned in publications, but since we have heard of a certain number of cases, most of them still unpublished. Nevertheless, our observation shows some peculiarities: on the one hand, it is the first one that refers to twins; on the other hand, it is the first time that the anomaly is also found in the mother too, though with a translocation, which accounts for her normal somatic appearance.

The fact that the malformation affects twins did not lead us to special conclusions: the occurrence of the disease is of course far too unfrequent to allow numerical evaluation. We can just mention

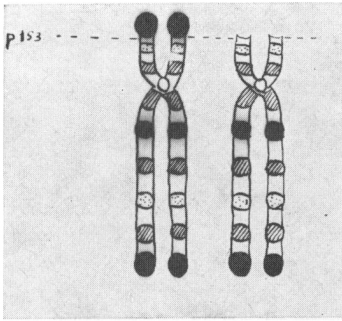


Fig. 6. Chromosome 4 in the children.

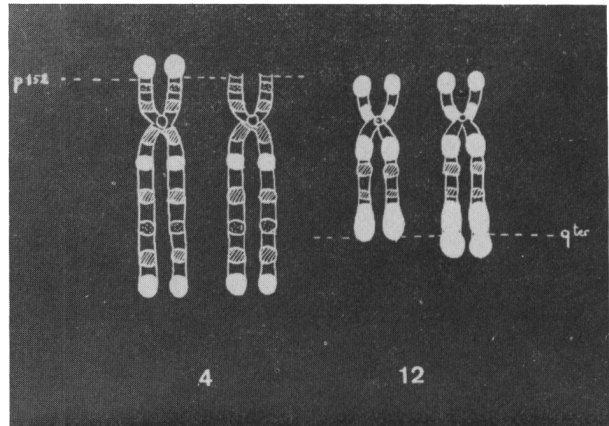


Fig. 7. Chromosomes 4 and 12 in the mother.

the conclusions of authors such as Stewart and Barber (1963), Nance and Uchida (1964), Nielsen (1969), according to whom the frequency of twins is higher in families where chromosomal anomalies can be found (Turner, Klinefelter, XYY), but this conclusion does not seem to apply to autosomes. Besides, one finds an increased frequency of normal twins in the families of these abnormal children, whereas here the twins themselves are abnormal.

Acknowledgment. The authors are grateful to Mrs. Rozot and Dr. B. Rucin for their competent and kind assistance.

REFERENCES

- Arrighi F.E., Tsu T.C. 1971. Localizations of heterochromatin in human chromosomes. *Cytogenetics*, 10: 81-86.
- Dutrillaux B., Lejeune J. 1971. Sur une nouvelle technique d'analyse du caryotype humain. *C.R. Acad. Sci. (Paris)*, 272: 2638.
- Dutrillaux B., Laurent C., Couturier J., Lejeune J. 1973. Coloration des chromosomes humains par l'acridine orange après traitement par le 5 bromodeoxyuridine. *C.R. Acad. Sdi. (Paris)*, 276: 3179.
- Nance W.E., Uchida I. 1964. Turner's syndrome, twinning and unusual variant of glucose-6-phosphate dehydrogenase. *Am. J. Hum. Genet.*, 16: 380-392.
- Nielsen J. 1969. *Klinefelter Syndrome and the XYY Syndrome*. København: Munksgaard.
- Noel B., Mottet J., Quack B. 1974. Identification des hommes 47,XYY dans la population générale par la coloration en fluorescence de l'hétérochromatine. *J. Genet. Hum.*, 22: 31-43.
- Stewart A., Barber R. 1963. Data on parental age, sibship size and twins. *Ann. Hum. Genet.*, 27: 1-9.
- Wolf U., Reinwein H., Porsch R. et al. 1965. Defizienz an den kurzen Armen eines chromosoms Nr 4. *Humangenetik*, 1: 397-413.

Dr. M. Lévy, Service de Pédiatrie A, Centre Hospitalier, 57000 Metz, France.