

Letters to the Editor

Septal deformity in neonates

Dear Sir,

In a recently published study Kent *et al.* (1991) analyse the possible connection between septal deformity in the newborn and a maxillary deformity by moulding forces on the maxilla during pregnancy and delivery, the Gray-theory (Gray, 1974). Suspicion of a deviation was obtained by mist testing and rhinoscopy by an auriscope but the diagnose was settled by passing a 6 × 2 mm silicone strut through the nasal cavities. If a columella dislocation was seen a base view photo was taken and the areas of the nostrils calculated. Matched normal controls were included and compared.

If a deviation was diagnosed alginate palatinal impressions were made and studied for incongruence, but none were found. Fourteen cases were found in 500 consecutive neonates, 12 deviated to the left against two to the right. Incidence was 2.8 per cent. Birth order among the cases with deviation was 1.8 (range 1-4) against 2.5 (range 1-10) in the total material. All deliveries were in the occipitoanterior presentation but the distribution between the left and right occipitoanterior presentation was not brought.

In an earlier study by one of the authors (Brain, 1990) the same diagnostic technique was used. The incidence of septal deviation in a population of 1,000 consecutive newborn was found to be 2.9 per cent. Reduction was done in some by a Walsham's forceps, but among the controls 43 per cent became straight spontaneously. However, no dislocations of the anterior part were found in this material either.

So, the group of authors do not seem to believe, that dislocation of the septal cartilage exists, although described since Metzenbaum (1936) by several (Briant, 1959; Klaff, 1963; Jeppesen and Windfeld, 1972; Jazbi, 1974; Pirsig, 1974) and several others.

It is therefore of great interest to analyse the diagnostic technique and the results for an explanation.

1. In the above mentioned paper Kent *et al.* (1991) bring a photograph in Figure 1 (left side) of a newborn's nose demonstrating a deflection of the apex nasi to the right. It could very well be a case of a dislocation of the septal cartilage to the left.

Briant (1963) stated that the direction of the dislocation of the inferior edge of the cartilage can be explained by the specific direction in which the nose is pressed during the internal rotation. He claimed that the pressure to the right during the LOA (left occiput anterior presentation) would cause dislocation of the inferior border to the *left*, correspondingly to the right in ROA (right occiput anterior presentation). Later it was demonstrated that 2/3 of the cases were equally distributed to the left and right, only 1/3 had the direction which could be expected from the internal rotation and that this direction was opposite, to the *right* in LOA and vice versa (Jeppesen and Windfeld, 1972).

As LOA is nearly twice as common as ROA, dislocations to the right should then be expected more often than to the left. However, the higher frequency of deviation to the left found by Kent *et al.* (1991) corresponds good to that, as a deviation to the *opposite* side as that of the dislocation is seen more posteriorly just like the deviation of the outer nose which mostly will take place to the left following LOA. The distribution between LOA and ROA is not shown, but if this is as usual, the dominance of deviation to the left is not a contradiction to the assumption, that at least some of the cases really is undiagnosed dislocations.

2. The dominance of low parity (more primiparae) is just similar to our findings of significantly higher frequency of primiparae and makes this conclusion possible, too. The duration of second stage is not shown, and we are therefore unable to compare to our results, that second stage of labour exceeding 15 minutes was seen significantly more often in multiparae in the material. (Jeppesen and Windfeld, 1972).

3. The incidence of 2.8 per cent is remarkably low com-

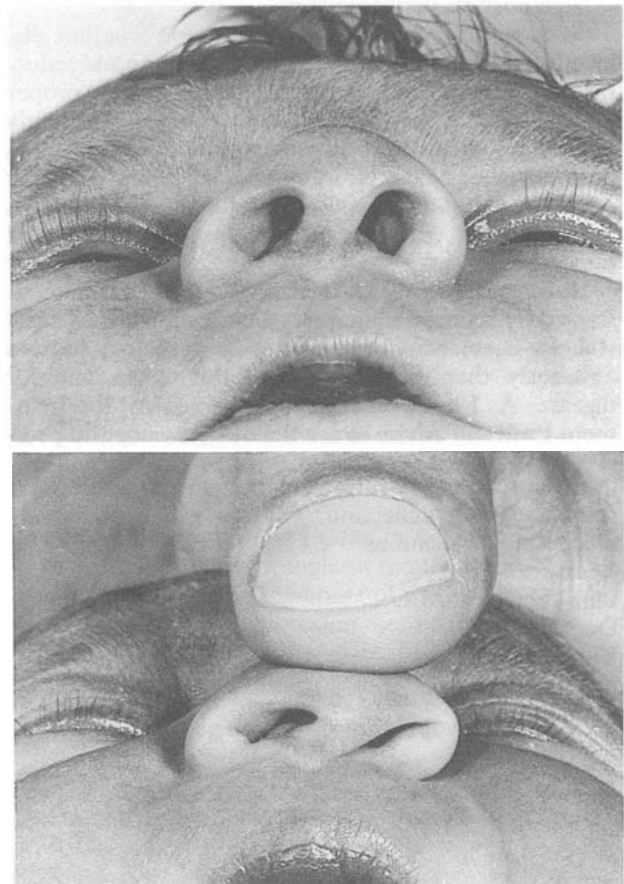


FIG.1

Top: Deflection following dislocation of the septal cartilage to the right.

Bottom: Aggravation by the compression test.

pared to our 3.2 per cent as we concentrated upon dislocations only. However, septal deviations can be seen not only accompanying dislocation but alone also. This could lead to suspicion of some underdiagnosing as well.

The same impression was the result of the discussion following the presentation (Brain, 1990) as it became clear, that no decongestant was used prior to inspection of the nasal cavity. These tiny changes will be hidden completely by even a slight mucosal swelling.

So I can advise you to supplement your great effort with the following better technique:

1. Before inspection swab the nasal mucosa with a cotton applicator soaked in solution of lidocaine 5 per cent with metaoxedrine chloride 0.1 per cent and wait some minutes.
2. Meanwhile try to apply a vertical pressure on the apex, the compression test. If support is low and the deflection become worse, it will add to the suspicion of a dislocation (Fig. 1).
3. Finally use preferably a children's nasal speculum and try to detect a difference between the two sides, a sloping against the floor of the nose on one side, and a tiny horizontal crest (the prominence of the premaxilla) on the other. Then palpate within a thin cotton applicator from the floor and medially and dorsally. After some practice you will find this method very usable in diagnosing the free lower border of the dislocated cartilage on one side and nothing at the other as described by Klaff (1963).

In easy cases you can only expect to find this Klaff-sign positive very anteriorly.

So in my opinion it is not a question whether dislocation exists or not, but whether diagnosing and reduction is of importance to the patients or not. A proper analysis of this question not only demands sufficiently big groups of treated and controls in order to get factors of importance to the indication for septoplasty equally distributed, but also a follow-up of 30 years and a high percentage of participation and must be considered impossible to carry out.

However, recently Grymer *et al.* (1989) has demonstrated by acoustic rhinometry that complaints of nasal stenosis is correlated more often to pathology located anteriorly than posteriorly and this is an anterior disease. As I have seen no complications of the treatment I will still advise to ask the obstetricians and pediatricians to keep an eye on the newborns noses, apply the compression test during the routine examination and refer any with deflection, and we will continuously reduce the dislocations.

Yours faithfully,
Finn Jeppesen, M.D.,
Dept. of ORL,
Viborg Sygehus,
DK-8800 Viborg,
Denmark

References

Brain, D. (1990) Neonatal septal deviations. 13th Congress European Rhinologic Society, London, June.

- Briant, T. E. (1959) A surgical technique for correction of combined septal and external deformities in children. *Transactions American Otorhinological Society of Plastic Surgery*, **2**: 53–61.
- Gray, L. P. (1974) Deviated nasal septum—incidence and etiology. *Medical Journal of Australia*, **1**: 557–563.
- Grymer, L. F., Hilberg, O., Elbrønd, O., Pedersen, O. F. (1989) Acoustic rhinometry: Evaluation of the nasal cavity with septal deviations, before and after septoplasty. *Laryngoscope*, **99**: 1180–1187.
- Jeppesen, F., Windfeld, I. (1972) Dislocation of the nasal septal cartilage in the newborn. *Acta Obstetrica Gynecologica Scandinavica*, **51**: 5–15.
- Kent, S. E., Rock, W. P., Nahl, S. S., Brain, D. J. (1991) The relationship of nasal septal deformity and palatal symmetry in neonates. *Journal of Laryngology and Otology*, **105**: 424–427.
- Klaff, D. D. (1963) Septal dislocations in the newborn infant. *International Rhinology*, **1**: 111–113.
- Pirsig, W. (1974) Die deformierte Neugeborennase. *Hals Nasen Ohrenheilkunde*, **22**: 1–5.

Reply:

Dear Sir,

We certainly mainly relied on the diagnostic and therapeutic techniques which had been previously developed by Lynsey Gray. They proved to be quite effective and reliable.

We did initially use a nasal speculum but found that it distorted the anatomy of the nasal vestibule and we therefore discarded this method of examination for this reason.

Of the patients with an obstructive airway, the examination was carried out by, in many instances, three different observers, none of whom were aware of the findings of their colleagues. When we compared the results later we found there was universal agreement and we are therefore confident that the examinations which were performed from which the data has been prepared were accurate.

We found the compression test to be valueless.

The question of the obstetrical data has been dealt with in previous reports.

The surgical anatomy of these septal deviations has also been dealt with at length in the previous paper. Certainly in our material, the deviations were a generalized bulge of the septum and not caused by a dislocation. In addition to the observations made in our patients, we also had a post-mortem specimen. In follow-up it was evident that the patients frequently underwent a spontaneous correction of their deformity. This again would be anticipated if the deviation was a bulge but would not occur if it was a dislocation.

Yours faithfully,
S E Kent
Consultant ENT Surgeon,
District General Hospital,
Lovely Lane,
Warrington,
WA5 1QG