

Conjunctivitis and subclinical infection in smallpox

BY C. H. KEMPE, F. DEKKING, L. ST VINCENT, A. R. RAO
AND A. W. DOWNIE

*Department of Pediatrics, University of Colorado Medical Center,
and the Infectious Disease Hospital, Tondiarpet, Madras*

(Received 12 April 1969)

Of the milder manifestations of smallpox infection, variola sine eruptione has long been recognized. This is seen in vaccinated contacts and serological evidence of the variolous nature of these cases has been obtained (Downie & McCarthy, 1958). Occasionally virus has been recovered from throat swabs or throat washings from such cases (Verlinde & Van Tongeren, 1952; Bingel & Kruse, 1959; Marennikova, Gurvich & Yamasheva, 1963). Conjunctivitis occurs in a proportion of cases of ordinary smallpox and has recently been recognized by us as the only clinical manifestation of smallpox infection (Dekking, Rao, St Vincent & Kempe, 1967). A peculiar form of pneumonitis without any skin eruption, probably allergic in nature, has been described in well vaccinated contacts (Evans & Foreman, 1963), and serological evidence of subclinical infection in contacts of variola minor patients has recently been obtained by Salles-Gomes, Angulo, Menezes & Zamith, (1965).

The present paper is concerned with the study of conjunctivitis in smallpox patients and conjunctivitis in contacts without other clinical evidence of smallpox. In addition, antibody studies have been made in close family contacts who had no evident clinical illness. The significance of antibody titres as evidence of subclinical infection in these contacts has been assessed in the light of our findings in vaccinated or revaccinated persons and in cases of smallpox.

MATERIAL AND METHODS

Most smallpox patients admitted to the Infectious Disease Hospital in Madras were accompanied by a member of the family or a relative who remained with them during their hospital stay. These family members were obviously in close contact with the patient they were attending and in a heavily infected environment, often for many days. They were revaccinated on the day of admission or next day, and were under close surveillance during their hospital stay.

Of these contacts 21 developed conjunctivitis but no rash or other signs of smallpox infection. From these 21, swabs of conjunctival exudate were examined for the presence of smallpox virus and the sera from 12 were examined for antibody. All these patients bore scars of previous vaccination with the exception of patient no. 3 in Table 1.

Requests for reprints should be addressed to Dr C. H. Kempe, 4200 East Ninth Avenue, Denver, Colorado 80220.

From 30 further contacts, who had no signs or symptoms of illness during their hospital stay and had been vaccinated earlier in life, blood was collected usually on the 1st or 2nd day after admission; a later sample was collected for serological examination from only four of these.

Four additional contacts developed typical smallpox, 3, 5, 10 and 10 days after admission to hospital. These were all adult females; three had been vaccinated earlier in life but had not been revaccinated before admission to hospital. The fourth had not been vaccinated before admission. Antibody titrations were made on the sera of these contact cases; the results are included in the second paper of this series (Downie *et al.* 1969) and are not further considered here.

In addition to the observations on the hospital contacts the results of virological examination of conjunctivitis seen in 84 cases of smallpox are recorded in this paper.

From patients showing conjunctivitis material was collected on cotton-wool swabs which were rubbed gently over the inner surface of the eyelids and the conjunctival sac. Each swab was then extracted in 1 ml. of Hanks's solution to which broth had been added to make 10%. This extract was used to inoculate the chorioallantois of 11- to 13-day chick embryos. Negative and doubtful membranes were subcultured to further chick embryos. Examination for antibodies was made as described.

RESULTS

Conjunctivitis in smallpox patients

The results of examination for virus in relation to the stage of disease are shown in Fig. 1. Of those patients from whose conjunctivas virus was recovered late in the disease, the conjunctivitis had been present not later than 15 days from the onset of illness. In a few cases the conjunctivitis occurred at the onset of fever and before the appearance of the focal eruption. In some patients from whom virus was not recovered, conjunctivitis occurred late in the course of the disease, although in others conjunctivitis, apparently not variolous in nature, was seen early in the illness.

Conjunctivitis in contacts who did not develop smallpox

Variola virus was recovered in culture of the conjunctival exudate from 12 of the 21 cases, but in only five of these was serum examined for antibody. The results of these tests for antibody are shown in Table 1. In case no. 3 serum was collected 9 days before the onset of conjunctivitis and antibody had not developed at this time. In the other four the antibody tests, made 6-14 days after the onset of conjunctivitis, showed the kind of antibody titres obtained in typical cases of smallpox, and in the three patients from whom a second sample of serum was taken there was an obvious rise in antibody following the conjunctivitis.

Smallpox virus was not recovered from the conjunctival exudate of nine contacts who developed conjunctivitis after admission. Antibody findings in seven of these are shown in Table 2. In the first patient there was no significant rise in antibody following the conjunctivitis but the results of precipitation, complement-

fixation and neutralization tests indicate that this contact had suffered either clinical or subclinical infection with smallpox virus before admission to hospital. Contact no. 4 showed a marked rise in antibody to levels typical of those seen in response to smallpox infection. Examination of conjunctival exudate on three

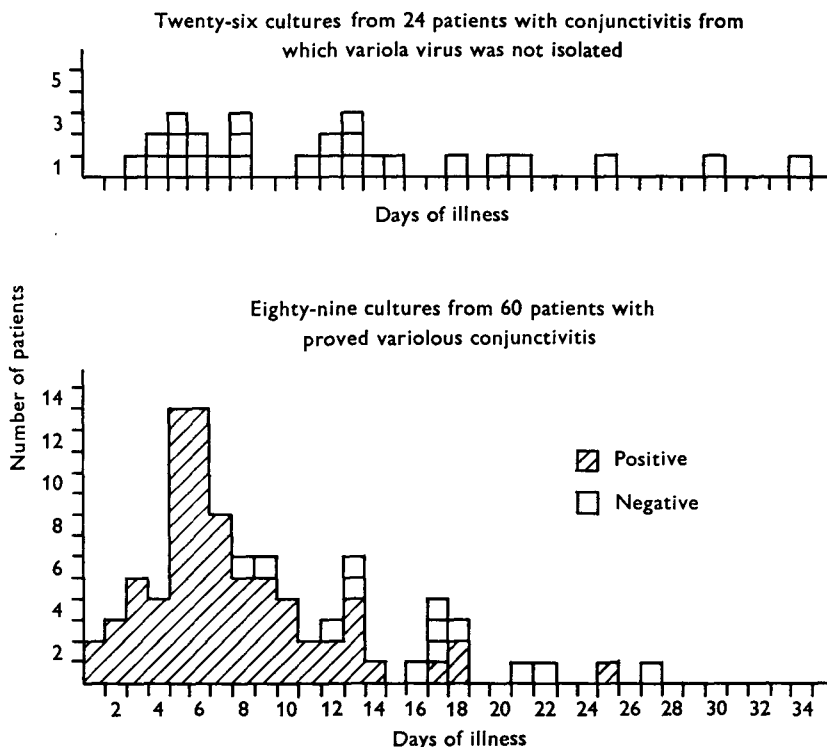


Fig. 1. Tests for virus in the conjunctival exudate of 84 smallpox patients showing clinical evidence of conjunctivitis. ▨, Positive; □, negative.

Table 1. *Antibody titres in five of twelve contacts who developed variolous conjunctivitis, but no other clinical evidence of smallpox*

Contact no.	Precipitation	CF titre	HI titre	Neutralization titre	Date of serum sample in relation to date of	
					Conjunctivitis (days)	Revaccination (days)
1	—	—	10	80	— 5	— 1
	+	—	80	500	13	17S*
2	+	20	40	300	14	20F*
3	—	—	20	9	— 9	2S
4	—	—	20	30	4	7S
	+	160	80	5000	8	11S
5	—	—	40	20	3	7F
	+	320	80	1000	6	10F

* S = vaccination on admission to hospital successful; F = vaccination on admission to hospital, no major reaction.

separate occasions failed to recover variola virus and it seems likely that this contact suffered subclinical infection with smallpox virus after admission to hospital. The remaining contacts in this group showed no significant increase in antibody after their conjunctivitis nor were their antibody levels suggestive of recent smallpox infection.

Table 2. *Antibody titres in seven of nine contacts who developed conjunctivitis from which virus was not isolated*

Contact no.	Precipitation	CF titre	HI titre	Neutralization titre	Date of serum sample in relation to date of	
					Conjunctivitis (days)	Revaccination (days)
1	+	640	40	700	-11	0F
	+	320	20	600	10	21F
2	-	-	10	60	-10	0F
	-	10	20	140	3	13F
3	-	-	10	100	-3	0S
4	-	-	10	100	-10	0F
	+	160	80	2000	16	26F
5	-	-	10	120	-4	-1F
	-	-	10	160	20	23F
6	-	-	10	95	-9	-8F
	-	-	<10	95	6	7F
7	-	-	<10	100	-21	-20*
	-	-	20	100	7	8*

In the last column, F and S have the same significance as in Table 1.

* Result of revaccination not recorded.

Antibody studies in contacts who suffered no illness while in hospital

Of thirty contacts in this category, tests were made on sera collected on the 2nd day after admission and, in four of them, 16-31 days later. None of these four sera showed a rise in titre; precipitation and CF tests were negative and neutralizing titres were relatively low. From the remaining 26 contacts serum was collected only on the 1st to 3rd day after admission except in one contact bled on the 29th day. Antibody levels in 18 were such as might be expected in persons with a previous history of vaccination—all gave negative precipitation tests, all except one were negative for CF antibody and all had neutralizing titres less than 1/350. In eight the findings were suggestive of recent smallpox infection (Table 3). The sera showed precipitation in agar gel with a vaccinia or variola antigen and other antibody titres consistent with smallpox infection. None of these patients gave a history of smallpox nor did any exhibit evidence of scarring. The serological findings, however, suggest that these patients had recently suffered from smallpox infection, either minimal or subclinical through contact with the disease before admission to hospital, or in no. 8, Table 3, possibly after admission to hospital.

Table 3. *Antibody titres in eight of thirty contacts who developed no illness*

Contact no.	Precipitation	CF titre	HI titre	Neutralization titre	Days after revaccination
1	+	20	40	200	4S
2	+	80	80	500	1F
3	+	80	40	500	1F
4	+	40	10	< 100	0F
5	+	160	80	700	1F
6	+	160	80	2000	1F
7	+	160	20	4000	1S
8	+	< 10	40	200	29F

In the last column, F and S have the same significance as in Table 1.

DISCUSSION

The results of virological examination of conjunctival exudate from smallpox patients showing conjunctivitis indicate that, while conjunctivitis developing in smallpox convalescents is not usually caused by variola virus, this may also apply to a small proportion of patients in whom conjunctivitis occurs in the first 8 days of illness (12 of 63 in Fig. 1). The occasional appearance of variolous conjunctivitis at or before the onset of fever suggests that the conjunctiva may have been the portal of entry of the virus in these patients. As noted by us earlier (Dekking *et al.* 1967) conjunctivitis occurring in immunized individuals may be the only clinical manifestation of smallpox infection.

Evidence of latent infection in contacts of variola minor in a hospital ward outbreak was obtained by Salles-Gomes *et al.* (1965) by serum antibody studies. Most of these latent infections occurred in vaccinated contacts, although occasionally they were seen in individuals who had not been vaccinated nor had suffered previously from variola. In variola major, because of the greater virulence of the virus, subclinical infection would seem unlikely to occur in persons not previously immunized by vaccination or smallpox infection. One possible instance of such an occurrence has been recorded by Verlinde & Van Tongeren (1952). In the present work evidence of latent infection was obtained only in previously vaccinated persons. Although there was no history of recent smallpox in those studied, it is impossible on the information at our disposal to rule out recent occurrence of minimal clinical infection such as variola sine eruptione. More extensive studies are required in this field.

SUMMARY

Attempts were made to demonstrate variola virus in the conjunctival exudate of 84 smallpox patients who developed conjunctivitis in the acute stage of the illness or during convalescence. Variola virus was isolated from 60 but not from the remaining 24. Of the 64 from whom virus was isolated the conjunctivitis developed from the onset up to the 15th day of illness. From conjunctivitis developing later virus was not recovered. In some patients who developed conjunctivitis early in the disease we failed to recover virus from the conjunctival exudate.

Of 55 close family contacts who stayed in hospital with smallpox patients four developed smallpox. In 21, conjunctivitis but no other illness developed. From 12 of these, variola virus was recovered from the conjunctival exudate and four of these 12, who were further investigated, showed after the appearance of conjunctivitis antibody titres similar to those seen in typical smallpox cases. From nine of the contacts who developed conjunctivitis virus was not recovered. One of these had antibody titres in serum collected before the onset of conjunctivitis which indicated recent smallpox infection. In another there was a marked antibody rise during her hospital stay although examination of conjunctival exudate on three separate occasions failed to yield variola virus. Twenty-six family contacts who developed no illness in hospital had antibody determinations made on sera collected soon after admission to hospital. In eight of these antibody titres were such as to indicate recent smallpox infection although there were no signs, in the form of scarring, or history of recent smallpox infection. These findings have been discussed in relation to the occurrence of minimal and subclinical infection in close family contacts of smallpox patients.

This investigation was supported in part by Public Health Service Grant AI-1632-16 VR from the National Institute of Allergy and Infectious Diseases, by the World Health Organization and by the Marcus T. Reynolds III Fund.

REFERENCES

- BINGEL, K. F. & KRUSE, L. (1959). Methoden und Ergebnisse der virologischen und serologischen Untersuchungen bei der Pockenerkrankungen in Heidelberg (Dezember 1958/Januar 1959). *Medizinische, Stuttgart*. no. 20, 961-9.
- DEKKING, F., RAO, A. R., ST VINCENT, L. & KEMPE, C. H. (1967). The weeping mother, an unusual source of variola virus. *Arch. ges. Virusforsch.* **22**, 215-18.
- DOWNIE, A. W. & MCCARTHY, K. (1958). The antibody response in man following infection with viruses of the pox group. III. Antibody response in smallpox. *J. Hyg., Camb.* **56**, 479-87.
- DOWNIE, A. W., ST VINCENT, L., GOLDSTEIN, L., RAO, A. R. & KEMPE, C. H. (1969). Antibody response in non-haemorrhagic smallpox patients. *J. Hyg., Camb.* **67**, 609-18.
- EVANS, W. H. M. & FOREMAN, H. M. (1963). Smallpox handler's lung. *Proc. R. Soc. Med.* **56**, 274-5.
- MARENNIKOVA, S. S., GURVICH, E. B. & YAMASHEVA, M. A. (1963). Laboratory diagnosis of smallpox and similar viral diseases by means of tissue culture methods; sensitivity of tissue culture methods in the detection of variola virus. *Acta virol., Prague* **7**, 126-9.
- SALLES-GOMES, L. F. de, ANGULO, J. J., MENEZES, E. & ZAMITH, V. A. (1965). Clinical and subclinical variola minor in a ward outbreak. *J. Hyg., Camb.* **63**, 49-58.
- VERLINDE, J. D. & VAN TONGEREN, H. A. E. (1952). Isolation of smallpox virus from the nasopharynx of patients with *variola sine eruptione*. *Antonie van Leeuwenhoek* **18**, 109-12.