

Aetiology and pathology of otitis media with effusion in adult life

R MILLS, I HATHORN

Otolaryngology Unit, University of Edinburgh, Scotland, UK

Abstract

Objectives: To gather and analyse information concerning the aetiology and pathology of otitis media with effusion in adults.

Method: A review of the English language literature from 1970 to the present was conducted.

Results: The available evidence suggests that otitis media with effusion in adult life is best viewed as a syndrome with a number of causes, including: infiltration of the eustachian tube by nasopharyngeal carcinoma and other local malignancies; changes in the middle ear and eustachian tube induced by radiotherapy; and systemic disease.

Conclusion: There is now a body of evidence specifically related to the aetiology and pathology of otitis media with effusion in adult life. However, further research is required to fill in the gaps in our knowledge and understanding of this condition.

Key words: Adults; Otitis Media With Effusion; Etiology; Pathology

Introduction

Otitis media with effusion (OME) is a common condition in the paediatric population. It is associated with many factors, including adenoidal hypertrophy, upper respiratory tract infection, cleft palate and exposure to cigarette smoke. In adults, OME is less prevalent, but still causes considerable morbidity. Cases of OME occur in all decades of adult life (Figure 1; RP Mills, unpublished data). While adult OME was once a neglected subject in terms of research effort, this is no longer the case. Over the last 20 years, a great deal of new information has become available that sheds some light on the pathogenesis of this enigmatic condition.

Materials and methods

A review of the English language literature from 1970 to the present was carried out. The PubMed database was searched using the term 'otitis media with effusion in adults'. Additional bibliographic referencing was undertaken. Only papers dealing with aspects of otitis media with effusion (OME) in adults were included. Papers concerning OME in children are only cited in order to highlight differences between the findings in adults and children. In the absence of histopathological studies of material from adult patients, data from studies involving animals and children have been quoted.

The first author's (RPM) career-long interest in adult OME led him to record data from patients with idiopathic OME arising in adult life throughout his time as a consultant otolaryngologist. This includes patients whose disease resolved without surgery. Data were collected prospectively between 1987 and 2009 using a computer database (Lotus Approach®). All patients were under the care of one otolaryngologist (RPM) and so the series does not include all patients treated in the relevant departments.

The management strategy for patients with idiopathic adult OME (no evidence of underlying systemic disease or nasopharyngeal tumour) remained the same throughout the study period. Unless there was prior documentation of chronicity, patients were reviewed two months after their initial consultation to confirm persistence of the effusion(s). At initial surgery, they underwent examination of the nasopharynx, and random biopsies were taken to exclude nasopharyngeal carcinoma. Assuming that effusion(s) were present, a ventilation tube was placed. Recurrent effusions were treated either by further tube placement or hearing aid provision.

The study group comprised patients with idiopathic OME aged over 15 years who were seen at Ninewells Hospital in Dundee (between 1987 and 1998) and at Edinburgh Royal Infirmary (between 1998 and 2009). In all cases, age at presentation, gender and

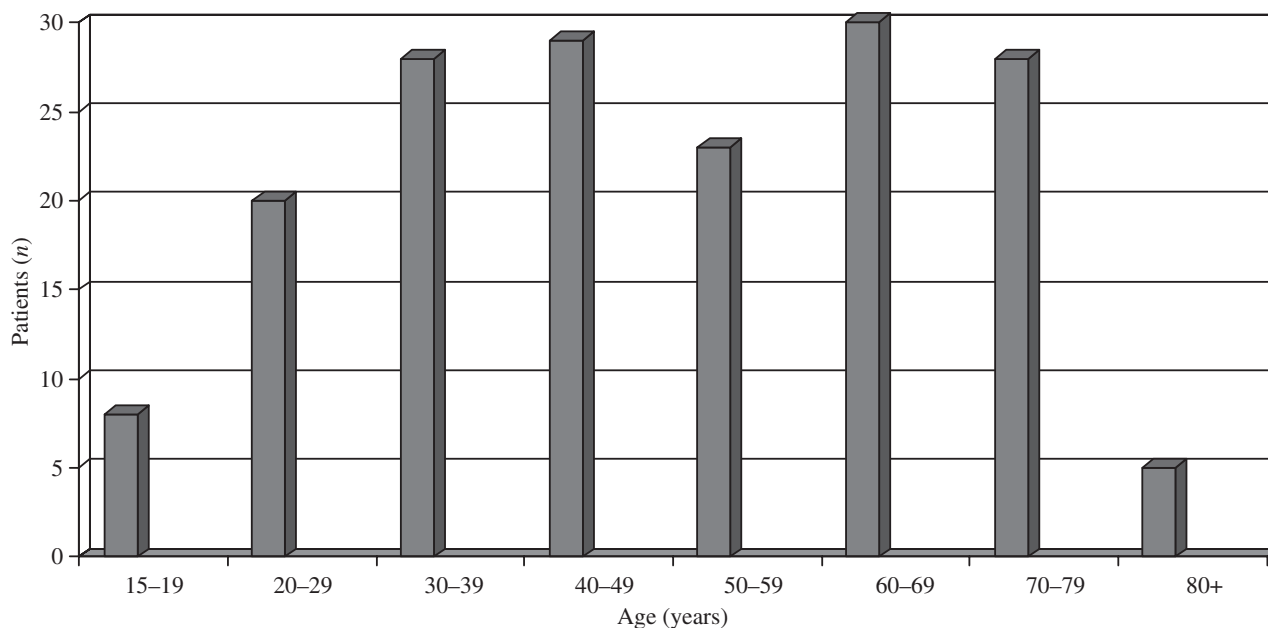


FIG. 1

Age of patients with otitis media with effusion at presentation ($n = 168$) (RP Mills, unpublished data).

findings at initial surgery were recorded. In the first 106 consecutive cases in the series, the findings at subsequent surgery were also recorded. In 32 consecutive patients (67 ears), the appearance of the middle-ear mucosa, as observed through the myringotomy incision, was recorded by one observer (RPM) and correlated with the effusion type found in the middle ear (serous or mucoid).

Aetiology

Local malignancy

The association between otitis media with effusion (OME) in adults and nasopharyngeal carcinoma (NPC) is well established.¹⁻³ Low *et al.* studied magnetic resonance imaging scans from 35 patients with NPC (59 affected ears).³ Of these, 18 had OME and 12 had evidence of eustachian tube cartilage erosion. Some of the patients also had destruction of the veli palatini muscle. This indicates two potential mechanisms for effusion formation: tubal dysfunction due to muscle involvement and direct infiltration of the eustachian tube, with the latter being the more important. Glynn *et al.* reviewed cases of adult OME over a 10-year period.⁴ They identified 59 patients with unilateral OME and 26 with bilateral OME. A nasopharyngeal mass was documented in 69 per cent of cases. All patients underwent examination under anaesthesia with nasopharyngeal biopsy, and four of the masses were found to be malignant (4.7 per cent). The authors advocate a high index of suspicion of nasopharyngeal tumour in adults with OME, and state that if a mass is identified it must be biopsied. In a series of 167 patients with adult-onset OME, Finkelstein *et al.* found that head and neck tumours, mainly NPCs, were present in 4.8 per cent of cases.⁵

Adult OME may also be associated with sinonasal malignancy and occult skull base lesions (benign and malignant).⁵⁻⁷ It may also follow radiotherapy for head and neck malignancy.⁸⁻¹⁰ There is a correlation between the morbidity of radiation-induced OME and the radiation dose received by the middle-ear cavities and eustachian tube.¹¹

Sinonasal disease

In a prospective series of 167 patients with adult-onset OME, Finkelstein *et al.* found evidence of paranasal sinus disease, particularly in the ethmoids, in 66 per cent of cases.⁵ They also found that nasopharyngeal lymphoid hyperplasia and adult-onset adenoidal hypertrophy was present in 19 per cent of patients. The same authors had earlier reported that OME was present in 23 per cent of patients presenting with chronic sinusitis.¹² Parietti-Winkler *et al.* studied patients with nasal polyps, with and without OME.¹³ Otitis media with effusion was five times more likely to be present in patients with Samter's triad than in other patients with nasal polyps. Yung and Arasaratnam found that, in their series of 53 adult patients requiring ventilation tube insertion, 26.4 per cent had inflammation of the lateral nasal wall and 51 per cent had inflammation at the eustachian tube orifice.¹⁴ Skin prick tests for allergy were positive in 57 per cent of the patients.

In the first author's series, only 22 per cent of the patients had a history of asthma, eczema or hay fever (RP Mills, unpublished data). The frequencies of nasal symptoms in the group were: nasal obstruction, 41 per cent; rhinorrhoea, 24 per cent; and sneezing, 24 per cent. Of note, these symptoms became apparent as a result of direct questioning and were not the patient's presenting complaints. This suggests case

selection bias, with an otologist (such as the first author) seeing patients who present with ear symptoms, and those with a more rhinological-orientated practice, such as Finkelstein *et al.*, identifying OME in patients presenting with nasal symptoms. At the very least, it undermines the contention by Finkelstein and colleagues that 'otitis media with effusion is not a separate entity but a presentation of sinus disease'.¹²

Acid reflux disease

It has been suggested that gastroesophageal reflux may have a role in the aetiology of adult OME.^{15–19} Sone *et al.* studied 186 adults with idiopathic OME and 156 control subjects.¹⁷ Gastroesophageal reflux symptoms were reported more frequently in the OME group. The same authors used the reflux symptom index to study 410 individuals undergoing health check-ups and 62 patients with OME who had high levels of pepsinogen in their middle-ear effusions.¹⁸ A greater number of OME patients had positive reflux symptom index scores (scores over 13) compared with non-OME patients, but high scores also appeared to correlate with increased body mass index.

Eustachian tube dysfunction

Eustachian tube dysfunction has long been considered an important factor in the pathogenesis of OME in adults and children. Eustachian tube function has been studied in adults with OME, using tubotympano-aerodynamic-graphy, the patency and pressure equilibration test, and the inflation-deflation test.²⁰ Impairment of active opening function was observed in adult OME patients; 46 per cent had an organic obstruction of the eustachian tube, as assessed by these methods.²⁰ Sade and Fuchs studied mastoid pneumatisation in adult OME patients and found a relationship with the chronicity of the disease process.²¹ They argued that poor mastoid pneumatisation predisposes to the development of negative pressure in the middle ear.

However, Cohen *et al.* have postulated that middle-ear gas is derived from the mucosa, and that the function of the eustachian tube is to drain mucus and allow gas to escape from the middle ear, but not to ventilate it.²² They propose that the occurrence of negative pressure in the middle ear is the result of gas production failure by the middle-ear mucosa and that middle-ear effusions occur when the eustachian tube fails to clear middle-ear secretions.

It may be that middle-ear mucosal metaplasia results in impaired gas production and that the eustachian tube is overwhelmed by the increase in secretion production. In addition, the drainage function of the eustachian tube may be deficient in individuals predisposed to OME. This could, for example, be due to impaired ciliary function. There is, however, still a need to identify the factor, or factors, which trigger the metaplastic process within middle-ear mucosa. In adults, OME often develops following an upper respiratory tract

infection, but in these cases early spontaneous resolution of the effusion(s) is common.²³

Cohen's model for the pathogenesis of OME fits most of the known facts concerning chronic OME. However, in cases where middle-ear effusions develop following air travel, it is difficult not to accept the notion that a failure of the eustachian tube to equalise the pressure inside and outside the middle ear during descent is the cause of the problem. The ears of as many as 15 per cent of airline passengers may show evidence of barotrauma following a flight, without development of an effusion.²⁴ However, this is an extreme set of circumstances in which the middle ear and eustachian tube of an animal not evolved for flight try to cope with rapid changes in static pressure. It seems unlikely that middle-ear gas production could be 'up-rated' quickly enough to compensate in these circumstances, and so we are forced to fall back on the eustachian tube, a structure designed to let gas out of the middle ear, not to facilitate its entry. As with most biological systems, there is a degree of tolerance allowing the ill-equipped eustachian tube to do the job against the odds in most people. It is therefore only individuals with relatively dysfunctional eustachian tubes who suffer. It should also be pointed out that effusions resulting from this type of barotrauma are usually transient.

Cohen and colleagues' theory is supported by the results of a study by Hergils and Magnuson.²⁵ These authors investigated middle-ear pressure in subjects in a pressure chamber. They found that middle-ear pressure could be maintained within the normal range when the eustachian tube was closed. This implies a mechanism involving a balance between removal of gas from the middle ear and its replacement, and does not support the classic 'hydrops ex vacuo' theory.

Data have been presented above indicating that middle-ear effusions in NPC are associated with infiltration of the eustachian tube by tumour. Sumi *et al.* studied 11 patients with benign parapharyngeal space tumours, 9 of whom had apparent obstruction of the eustachian orifice. All of the patients had normal ears and hearing.²⁶ This suggests that while infiltration of the eustachian tube leads to effusion formation, external compression does not.

Smoking

Smoking has been shown to be associated with reduced ciliary beat frequency in samples of middle-ear mucosa taken from adults with OME.²⁷

Intensive care patients

Otitis media with effusion is surprisingly prevalent in patients undergoing treatment in an intensive care unit.^{28–30} Two studies identified evidence of middle-ear effusion in around 50 per cent of the patients studied.^{28,30} Gonzalez Pena *et al.* reported an association between the use of large-bore nasogastric tubes (18 French gauge) and the presence of middle-ear

effusion in 100 patients.²⁹ The results of the other two studies did not confirm this finding.^{28,30}

Human immunodeficiency virus

Otitis media with effusion has been reported in association with human immunodeficiency virus infection.³¹

Sarcoidosis

There is one report in the literature concerning OME in a patient with sarcoidosis.³²

Pathology

Effusion type

The type of effusion (serous or mucoid) found at first surgery for otitis media with effusion (OME) in adult patients was recorded in 183 ears by RP Mills (unpublished data). Of these, 123 (67 per cent) were serous and 63 (33 per cent) were mucoid. Mucoid effusions occurred with equal frequency in males and females. Mucoid effusions were significantly more likely to be bilateral than serous effusions (chi-square = 16.5, $p < 0.0001$). Eight patients had a mucoid effusion in one ear and a serous effusion in the other.

Of the 106 patients for whom data concerning subsequent surgery were recorded, 23 underwent a second operation (no data for 6 patients). In 19 of these, the same effusion type was found in the same ear as at first surgery. However, in four ears which had had a mucoid effusion at first surgery, a serous effusion was found, and in one ear with a serous effusion at first surgery a mucoid effusion was found. In children, different effusion types may also occur in the same ear at subsequent surgery,³³ and it appears that this phenomenon occurs in a minority of adults as well. However, as mucoid effusions were more likely to be bilateral, patients with serous effusions form a larger proportion of this cohort than the data presented above would suggest. In fact, 69 per cent of the patient group had unilateral or bilateral serous effusions. The above findings confirm a long-standing clinical impression that the majority of effusions found in adult life are serous in type, which is the opposite of the situation in children.

More recently, a new entity called eosinophilic otitis media has been described.^{34–36} The effusions in this condition are reported as being highly viscous, yellow in colour and containing eosinophils.³⁴ Eosinophilic otitis media typically occurs in females in their fifties, and may be associated with eosinophilic sinusitis and nasal polyposis.^{34,35}

Middle-ear mucosa histopathology

Histological examination of middle-ear mucosa in OME indicates that a thick mucosa with numerous secretory columnar cells is associated with mucoid effusions, and a thin mucosa with few secretory cells and evidence of separation of epithelial junctions and widened intercellular spaces are associated with

serous effusions.^{37–40} However, these studies have been carried out in children or animals. The only report of findings in adults was a study of three patients who died of head and neck malignancy.⁴¹ Mucoid effusions (two cases) were associated with goblet cell proliferation and enhanced secretory activity. There was no evidence of secretory activity in the one case with a serous effusion.

The appearances of the middle-ear mucosa, as seen through the myringotomy incision, were recorded in 32 patients (67 ears) by the first author. The appearance of the middle-ear mucosa was correlated with the effusion type found in the middle ear (serous or mucoid) (RP Mills, unpublished data). Thick mucosa was found in 80 per cent of ears with mucoid effusions, while thin mucosa was observed in 80 per cent of ears with serous effusions. This difference is statistically significant (chi-square = 28.2, $p < 0.0001$). Thick mucosa was usually dull grey in colour, with a boggy appearance. Thin mucosa was pale, with dilated blood vessels coursing across its surface.

Sade has pointed out that mucus production is the normal reaction of mucosal surfaces to inflammation.⁴² It may be that the type of effusion present in an ear at a particular point in time is determined by the intensity of the inflammatory process and therefore the degree of metaplasia to a mucus-secreting epithelium at that point in time. This would explain how different effusion types can be found in a patient's ear at the same operation and why a different effusion may be identified at subsequent surgery.

Bacteriology

A large number of studies have identified pathogenic bacteria in the middle-ear effusions from children, but few have examined middle-ear fluid from adults. A study conducted by Heaton and Mills included 14 adult patients, none of whom had positive cultures from their effusions.⁴³ In the same study, pathogenic bacteria were identified in 21 per cent of effusions from children. Evidence of bacteria in middle-ear fluid from adults has been found using the polymerase reaction technique, in a study of 19 effusions.⁴⁴ This indicates that culture-negative middle-ear effusions may contain genomic sequences from bacterial pathogens. *Helicobacter pylori* has been found in the middle-ear effusions of some adult patients.⁴⁵ However, despite its presence in the middle ear, there is limited evidence supporting the role of *H pylori* in the pathogenesis of OME.⁴⁶

Cytokines

A number of studies that have included adults have shown the presence of immunoregulatory cytokines in middle-ear effusions.^{47–50} Takeuchi *et al.* compared interleukin (IL)-8 gene expression in effusions from children and adults.⁴⁷ Interleukin-8 transcripts were found in 75 per cent of effusions from both groups. Interleukin-8 is a monocyte- and macrophage-derived

cytokine that displays potent chemotactic-activating properties towards neutrophils. Ondrey *et al.* studied the early-response cytokines, IL-1 beta and tumour necrosis factor alpha, in effusions from adults, most of whom had a history of head and neck malignancy and radiation of the temporal bone.⁴⁸ Interleukin-1 beta was expressed in 85 per cent of effusions from children, but in only 12 per cent of those from adults.

Kariya *et al.* studied effusions from 80 adults with OME using an enzyme-linked immunosorbent assay.⁴⁹ They detected IL-2 in 75 per cent of effusions, IL-4 in 41 per cent, IL-5 in 52 per cent, IL-10 in 17 per cent, IL-12 in 100 per cent and interferon-gamma in 82 per cent. Levels of IL-4 in samples from patients with allergic rhinitis were significantly higher than in those with no such history. Interestingly, the incidence rate and concentration of IL-10 was found by Kariya *et al.* to be significantly higher in mucoid type effusions compared to serous type effusions.⁴⁹ These authors suggest that IL-12 may play a role in the pathogenesis of OME by affecting the production of IL-2 and interferon-gamma.

Zhao *et al.* studied the concentrations of IL-10 and transforming growth factor beta in 45 samples of middle-ear fluid and blood samples from 36 patients with OME, and compared this with blood samples from 30 control subjects,⁵⁰ using the same method as Kariya *et al.*⁴⁹ Interleukin-10 concentrations were significantly higher in middle-ear effusion than in the corresponding blood samples, but the levels of transforming growth factor beta were similar in both. As in the earlier study, by Kariya *et al.*,⁴⁹ IL-10 levels were significantly higher in serous effusions as compared to mucoid effusions. The precise relevance of these findings will become clearer when the roles of different cytokines in diseases have been better defined.

Nitric oxide

Hisamatsu *et al.* studied the levels of nitrotyrosine and nitric oxide, and the activity of superoxide dismutase and lactate dehydrogenase, in 90 samples of middle-ear fluid.⁵¹ These substances are part of the so-called nitric oxide/superoxide system. Nitrotyrosine levels were lower in the samples from adults than in samples from patients younger than 16 years. The significance of these finds is not entirely clear.

Discussion

There is now a large body of evidence concerning various aspects of adult otitis media with effusion (OME), but at present it is difficult to synthesise this into a unified model of pathogenesis. However, this may be because adult OME is in fact a syndrome, rather than a disease. There is good reason to view OME as secondary to nasopharyngeal carcinoma (NPC), and other head and neck malignancy as distinct from other forms of OME. Adult OME is associated with systemic disease in a minority of cases and is often not a presenting feature, but NPC must be excluded in all cases.

Eosinophilic otitis media appears to be a separate entity, distinct from other forms of OME, with well-defined diagnostic criteria (e.g. presence of eosinophils in viscous effusions, and association with asthma, chronic rhinosinusitis and nasal polyposis). Nevertheless, further data from other centres are required to confirm this. The distinction between non-eosinophilic mucoid OME and serous OME is less clear-cut. Further immunological studies appear to offer the best route to a greater understanding of OME.

The distinctions between different forms of OME are not only of academic interest. There is evidence that eosinophilic OME is best treated with systemic or topical steroid therapy.³⁴ A clinically meaningful classification of OME variants may lead to more effective targeting of therapeutic interventions. More data concerning the long-term effectiveness of steroid therapy (particularly systemic treatment) for eosinophilic OME are required, but it does seem worthwhile to try to identify cases that fall into this category. The majority of adult patients with OME have serous effusions, so this would involve collecting a minority of effusions to look for eosinophils.

It is interesting to ask the question: are adult and paediatric OME the same disease? While there are differences between idiopathic OME in adults and children, the similarities are considerable. A study of 168 adult patients with idiopathic OME indicated a small male predominance (93 males (55 per cent) vs 75 females (45 per cent); RP Mills, unpublished data). These rates are similar to that found in most series of childhood OME cases. In both children and adults, the reason for this is not clear. Both forms of the disease have a similar spontaneous resolution rate during the first two months after presentation.²³ However, in some individuals, adult OME is a more chronic condition than its childhood counterpart. On the other hand, serous effusions are more common in adults and mucoid effusions are more common in children. There are also immunological differences between effusion in adults and children.⁴⁸

The adults in the first author's cohort first noted symptoms attributable to OME as adults. This does not exclude the possibility that the adult disease represented a recurrence of a problem which had affected the individual in early childhood. The sequelae of this childhood disease could predispose the middle ear to problems in later life. This possibility is not excluded by the different patterns of effusion types in these two groups. This hypothesis could only be tested by following a cohort of children with OME into adult life.

Further research is needed to clarify the aetiology and pathology of OME, and to determine the optimal treatment for individual cases.

Conclusion

There is now a body of evidence specifically related to the aetiology and pathology of otitis media with

effusion in adult life. However, further research is required to fill in the gaps in our knowledge and understanding of this condition. At present, immunological studies offer the most promise in this regard.

References

- Young YH, Hsieh T. Eustachian tube dysfunction in patients with nasopharyngeal carcinoma, pre- and post-irradiation. *Eur Arch Otorhinolaryngol* 1992;**249**:206–8
- Hsu MM, Young YH, Lin KL. Eustachian tube function of patients with nasopharyngeal carcinoma. *Ann Otol Rhinol Laryngol* 1995;**104**:453–5
- Low WK, Lim TA, Fan YE, Balakrishnan A. Pathogenesis of middle-ear effusion in nasopharyngeal carcinoma: a new perspective. *J Laryngol Otol* 1997;**111**:431–4
- Glynn F, Keogh JJ, Ali TA, Timon CI, Donnelly M. Routine nasopharyngeal biopsy in adults presenting with isolated serous otitis media: is it justified? *J Laryngol Otol* 2006;**120**:439–41
- Finkelstein Y, Ophir D, Talmi YP, Shabtai A, Strauss M, Zohar Y. Adult-onset otitis media with effusion. *Arch Otolaryngol Head Neck Surg* 1994;**120**:517–27
- Talmi YP, Mardinger O, Horowitz Z, Yahalom R, Wolf M, Peleg M *et al.* Incidence of secretory otitis media following maxillectomy. *Oral Surg Oral Med Oral Pathol Radiol Endod* 1998;**86**:524–8
- Radaelli de Zinis LO, Parinello G, Nicholai P. Middle ear effusion in patients with sinonasal cancer treated by surgery, with or without radiotherapy. *Otolaryngol Head Neck Surg* 2013;**148**:619–24
- Wang SZ, Wang WE, Zhang HY, Guo M, Hoffman MR, Jiang JJ. Analysis of anatomical factors controlling the morbidity of radiation-induced otitis media with effusion. *Radiother Oncol* 2007;**85**:463–8
- Liang KL, Su MC, Twu CW, Jiang RS, Lin JC, Shiao JY. Long-term result of management of otitis media with effusion in patients with post-irradiated nasopharyngeal carcinoma. *Eur Arch Otolaryngol* 2011;**268**:213–17
- Hsin CH, Chen TH, Liang KL, Tseng HC, Liu WS. Postirradiation otitis media with effusion in nasopharyngeal carcinoma patients treated by intensity-modulated radiotherapy. *Laryngoscope* 2013;**123**:2148–53
- Leonetti JP. A study of unilateral middle ear effusion caused by occult skull base lesions. *Ear Nose Throat J* 2013;**92**:195–200
- Finkelstein Y, Talmi YP, Rubel Y, Bar-Ziv J, Zohar Y. Otitis media with effusion as a presenting symptom of chronic sinusitis. *J Laryngol Otol* 1989;**103**:827–32
- Parietti-Winkler C, Baumann C, Gellet P, Gauchard G, Jankowski R. Otitis media with effusion as a marker of the inflammatory process associated to nasal polyposis. *Rhinology* 2009;**47**:396–9
- Yung MW, Arasaratnam R. Adult-onset otitis media with effusion: results following ventilation tube insertion. *J Laryngol Otol* 2001;**115**:874–8
- Sone M, Yamamuro Y, Hayashi H, Yanagi E, Niwa Y, Nakashima T. Prediction of gastroesophageal reflux in otitis media with effusion in adults. *Acta Otolaryngol* 2007;**127**:470–3
- Al-Saab F, Manoukian JJ, Al-Sabah B, Almot S, Nguyen LH, Tewfik TL *et al.* Linking laryngopharyngeal reflux to otitis media with effusion: pepsinogen study of adenoid tissue and middle ear fluid. *J Otolaryngol Head Neck Surg* 2008;**37**:565–71
- Sone M, Kato T, Suzuki Y, Arai H, Sugiyama K, Ishida K *et al.* Relevance and characteristics of gastroesophageal reflux in adult patients with otitis media with effusion. *Auris Nasus Larynx* 2011;**38**:203–7
- Sone M, Katayama N, Kato T, Izawa K, Wada M, Hamajima N *et al.* Prevalence of laryngopharyngeal reflux symptoms: comparison between health checkup examinees and patients with otitis media. *Otolaryngol Head Neck Surg* 2012;**146**:562–6
- Sone M, Kato T, Arai H, Izawa K, Suzuki Y, Ishida K *et al.* Exploratory findings of audiometry in adult patients with otitis media with high pepsinogen concentrations: a preliminary study. *Acta Otolaryngol* 2013;**133**:35–41
- Iwano T, Kinoshita T, Hamada E, Doi T, Ushiro K, Kumazawa T. Otitis media with effusion and eustachian tube dysfunction in adults and children. *Acta Otolaryngol Suppl* 1993;**500**:66–9
- Sade J, Fuchs C. Secretory otitis media in adults: II. The role of mastoid pneumatization as a prognostic factor. *Ann Otol Rhinol Laryngol* 1997;**106**:37–40
- Cohen D, Raveh D, Peleg U, Nazarian Y, Perez R. Ventilation and clearance of the middle ear. *J Laryngol Otol* 2009;**123**:1314–20
- Mills R, Vaughan-Jones R. A prospective study of otitis media with effusion in adults and children. *Clin Otolaryngol* 1992;**17**:271–4
- Stangerup SE, Klokke M, Vesterhauge S, Jayaraj S, Rea P, Harcourt J. Point prevalence of barotitis and its prevention and treatment with nasal balloon inflation: a prospective, controlled study. *Otol Neurotol* 2004;**2**:89–94
- Hergils L, Magnuson B. Regulation of negative middle ear pressure without tubal opening. *Arch Otolaryngol Head Neck Surg* 1988;**114**:1442–4
- Sumi T, Tsunoda A, Shirakura S, Kishimoto S. Mechanical obstruction of the eustachian tube by the benign tumor of the parapharyngeal space does not cause otitis media with effusion. *Otol Neurotol* 2007;**28**:1072–5
- Agius AM, Wake M, Pahor AL, Smallman LA. Smoking and middle ear ciliary beat frequency in otitis media with effusion. *Acta Otolaryngol* 1995;**115**:44–9
- Lin CC, Lin CD, Cheng YK, Tsai MH, Chang CS. Middle ear effusion in intensive care unit patients with prolonged endotracheal ventilation. *Am J Otolaryngol* 2006;**27**:109–11
- Gonzalez Pena M, Figuerola Massana E, Hernandez Gutierrez P, Rello Condomines J. Middle ear effusion in mechanically ventilated patients: effects of the nasogastric tube. *Respir Care* 2013;**58**:273–8
- Kesser BW, Woodard CR, Stowell NG, Becker SS. Middle ear effusion in adult ICU patients: a cohort study. *Ear Nose Throat J* 2013;**92**:340–6
- Tshifularo M, Govender L, Monama G. Otolaryngological, head and neck manifestations in HIV-infected patients seen at the Steve Biko Academic Hospital in Pretoria, South Africa. *S Afr Med J* 2013;**103**:464–6
- Mills RP, Tay HL. Findings at initial surgery for childhood otitis media with effusion and subsequent outcome. *Clin Otolaryngol* 1995;**20**:461–4
- Osinubi OA, Lauder I, Thomas RS. A rare cause of unilateral hearing loss. *Postgrad Med J* 2000;**76**:584–5
- Lino Y. Eosinophilic otitis media: a new middle ear disease entity. *Curr Allergy Asthma Rep* 2008;**8**:525–30
- Lino Y, Tomioka-Matsutani S, Matsubara A, Nakagawa T, Ninaka M. Diagnostic criteria for eosinophilic otitis media: a newly recognized middle ear disease. *Auris Nasus Larynx* 2011;**38**:456–61
- Seo Y, Nonaka Y, Tagaya E, Tamaoki J, Yoshihara T. Eosinophilic otitis media is associated with asthma severity and smoking history. *ORL J Otorhinolaryngol Relat Spec* 2015;**77**:1–9
- Lim DJ. Normal and pathological mucosa of the middle ear and eustachian tube. *Clin Otolaryngol* 1979;**4**:213–23
- Senturia BH, Carr CD, Ahlvin RC. Middle ear effusions: pathologic changes of the mucoperiosteum in the experimental animal. *Trans Am Otol Soc* 1962;**50**:33–49
- Lim DJ, Birk H. Ultrastructural pathology of the middle ear mucosa in serous otitis media. *Ann Otol Rhinol Laryngol* 1971;**80**:838–53
- Paparella MM, Hirade F, Juhn SK, Kaneko Y. Cellular events involved in middle ear fluid production. *Ann Otol Rhinol Laryngol* 1970;**76**:776–7
- Tanaka K, Saito J, Ohashi M, Terayama Y. Histopathology of otitis media with effusion. An electron microscopic study of human temporal bones. *Arch Otorhinolaryngol* 1986;**243**:269–73
- Sade J. Pathology and pathogenesis of serous otitis media. *Arch Otolaryngol* 1966;**84**:297–305
- Heaton JM, Mills RP. Factors associated with positive bacteriological cultures of chronic middle ear effusions. *Clin Otolaryngol Allied Sci* 1995;**20**:262–5
- Liederman EM, Post JC, Aul JJ, Sirko DA, White GJ, Buchman CA *et al.* Analysis of adult otitis media: polymerase chain

- reaction versus culture for bacteria and viruses. *Ann Otol Rhinol Laryngol* 1998;**107**:10–16
- 45 Morinaka S, Tominaga M, Nakamura H. Detection of *Helicobacter pylori* in the middle ear fluid of patients with otitis media with effusion. *Otolaryngol Head Neck Surg* 2005;**133**:791–4
- 46 Sudhoff H, Rajagopal S, Baguley DM, Ebmeyer J, Schmelzer A, Schreiber S *et al.* A critical evaluation of the evidence on a causal relationship between *Helicobacter pylori* and otitis media with effusion. *J Laryngol Otol* 2008;**122**:905–11
- 47 Takeuchi K, Maesako K, Yuta A, Sakakura Y. Interleukin-8 expression in middle ear effusions. *Ann Otol Rhinol Laryngol* 1994;**103**:404–7
- 48 Ondrey FG, Juhn SK, Adams GL. Early-response cytokine expression in adult middle ear effusions. *Otolaryngol Head Neck Surg* 1998;**119**:342–5
- 49 Kariya S, Okano M, Hattori H, Sugata Y, Matsumoto R, Fukushima K *et al.* TH1/TH2 and regulatory cytokines in adults with otitis media with effusion. *Otol Neurotol* 2006;**27**:1089–93
- 50 Zhao SQ, Li J, Liu H, Zhang GQ, Wang Y, Han DM. Role of interleukin-10 and transforming growth factor beta 1 in otitis media with effusion. *Chin Med J (Engl)* 2009;**122**:2149–54
- 51 Hisamatsu K, Inoue H, Makiyama K, Homma M. Nitrotyrosine in otitis media with effusion. *Ann Otol Rhinol Laryngol* 2005;**114**:804–8

Address for correspondence:
Prof R P Mills,
Department of Otolaryngology,
University of Khon Kaen,
123, Mitrapap Highway, Khon Kaen 40002, Thailand

E-mail: profprpmills@yahoo.co.uk

Prof R P Mills takes responsibility for the integrity of the content of the paper
Competing interests: None declared
