

# The Journal of Laryngology and Otology

(Founded in 1887 by MORELL MACKENZIE and NORRIS WOLFENDEN)

February 1959

## THE VASOMOTOR ACTIVITIES OF THE NASAL MUCOUS MEMBRANE\*

By K. GREER MALCOMSON (Bristol)

SINCE the time of Harvey knowledge of the circulation of the blood has increased to such an extent that the literature on the subject is now vast. From this knowledge has been derived the underlying principles governing the medical and surgical management of functional and organic disorders of the heart and of the blood vessels in most parts of the body. The nose, despite its anatomical prominence, has been very much neglected in this quest because fatal or disabling diseases were naturally given priority of attention.

From earliest times, no special knowledge was required to observe that olfaction is the prime function of the nose, but Galen recognized that it was also an important organ of respiration, heating the inspired air, and preventing cooling of the lungs. Little was added to this until the end of the 19th century when interest in nasal physiology was aroused by Zwaardemaker (1889 *a, b*), who described his olfactometer and an hygrometric method of measuring the nasal airway. At this time the general pattern of the peripheral autonomic ganglia had been substantially elucidated by Langley and others, and although the anatomical disposition of the nerves to the nose was well established, it was not until 1913 that Tschalussow published the results of four years' experiments (Tschalussow 1913; Fofanow and Tshalussow 1913) in which he demonstrated for the first time the existence of vasomotor fibres going to the nose. To do this,

---

\* Paper read at the Section of Laryngology, Royal Society of Medicine, May, 1958.

## K. Greer Malcomson

he converted the nose into a closed chamber and recorded changes in the nasal volume with a tambour and smoked drum. By electrical stimulation he showed that vasoconstrictor fibres travelled in the cervical sympathetic chain and vasodilator fibres in the vidian nerve; when he applied nicotine to the sphenopalatine ganglion, the vasodilator response was replaced by vasoconstriction. Following superior cervical sympathetic ganglionectomy and allowing time for degeneration of the postganglionic fibres, Tschalussow found that vasoconstriction was unaffected when he stimulated the postganglionic component, from which he concluded that the postganglionic fibres destined for the nose had their cell stations in the sphenopalatine ganglion, an inference which we now know to be incorrect.

Tschalussow's paper excited little interest in the neurovascular physiology of the nose, and only five workers in the past 50 years have confirmed or extended his observations in animals. Of these Mendenhall (1915; Martin and Mendenhall, 1915) commented upon the pre-eminent vasomotor sensitivity of the nose. Tatum (1923) observed that asphyxia caused reflex vasoconstriction mediated on the efferent side by the cervical sympathetic chain. Sternberg (1925*a, b*) stressed the bias of the nasal mucous membrane to reflex vasoconstriction with different physical stimuli. Blier (1930) reaffirmed Tschalussow's finding that vasoconstrictor fibres were present not only in the posterior nasal nerve of the dog\* but also in the vidian nerve, and he demonstrated that vasoconstriction was abolished after superior cervical ganglionectomy and degeneration of the postganglionic fibres.

### Neurovascular Anatomy of the Nose

This is too well known to elaborate here, but a number of points should be mentioned. The autonomic innervation of about three-quarters of the nasal mucous membrane reaches the nose *via* the vidian nerve and follows the distribution of the second division of the trigeminal nerve to the nose. The destination is the same but the terms vegetative and somatosensory qualify their separate destinies. The ophthalmic branch of the trigeminal supplies sensory fibres to the cartilaginous septum and the anterior part of the lateral wall of the nose through its medial and lateral internal nasal branches, but there are no clearly defined parasympathetic fibres accompanying these. Sympathetic fibres are said to reach this area from the superior cervical ganglion *via* the internal carotid plexus and the ophthalmic nerve. It would indeed be exceptional if the mucous glands, goblet cells and the supporting vascular structures in these areas lacked secretomotor and vasomotor control (Fig. 1).

The vascular supply from the maxillary and ethmoidal arteries follows a similar pattern to that of the nerves. The arteries are in the depths of

---

\* Supplies approximately the posterior two-thirds of the maxilloturbinal.

## Vasomotor Activities of Nasal Mucous Membrane

the mucous membrane, arranged in parallel longitudinal rows, from which arterioles pass towards the surface and supply subepithelial and periglandular capillary networks. These drain into the erectile venous sinuoids, the efferent vessels of which are provided with well-defined sphincters (Lucas, 1952). Arteriovenous anastomoses have been demonstrated short-circuiting the superficial system in animals (Dawes and Prichard, 1953) and it is believed that a similar mechanism exists in man.

### Experimental Study of Nasal Vessels

Tschalussow studied the vasomotor aspects of the nose from a neurological standpoint. His method has also been applied to the effects of drugs

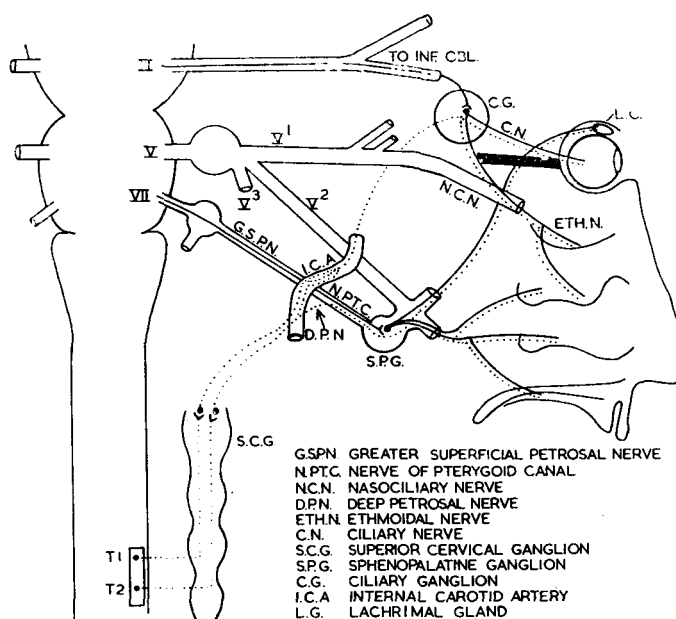


FIG. 1.

on the mucous membrane, but it is not easily applicable to the investigation of the human nasal airway. Table I enumerates the principal experimental techniques, and of these, rhinometry has received most attention.

Direct rhinometry involves three factors—the volume of air passed, its pressure (resistance) and time. Thus, if air is passed through the nose at a given pressure in a given time, the volume is measured; or if a known volume is passed at a given air pressure, the time taken for its passage represents the relative efficiency of the nasal airway. The third method—when a known volume passes in a given time, the nasal resistance or pressure is measured by manometry (rhinomanometry).

## K. Greer Malcomson

In studying the vasomotor activity of the nasal mucous membrane in animals, the most satisfactory method is direct rhinomanometry. Hitherto the plethysmographic method of Tschalussow has been used by workers in this field. The technique in the present study consists of pumping the same volume of air a given number of times per minute (i.e. at the normal respiratory rate) through a cannula inserted into the nose of an animal (in this study principally the cat) whose lower respiratory tract has been excluded by tracheotomy, and recording the resistance in the nose with a water manometer on a smoked drum (Fig. 2). Although the results can be

TABLE I.  
METHODS USED IN INVESTIGATING NASAL BLOOD FLOW CHANGES  
(after Slome 1955).

---

COLOUR of nasal mucosa	Inspection (Hill, 1913). Photo-electric plethysmography (Hertzman and Dillon, 1939).
TEMPERATURE of mucosa	recorded by thermocouples (Mudd, Goldman and Grant, 1921 a, b) (Ralston and Kerr, 1945)
VOLUME changes	Closed chamber technique (Tschalussow, 1913) Intranasal balloon (Ralston and Kerr, 1945)
RHINOMETRY	(a) INDIRECT
	(i) Hygrometric methods Mirrors (Zwaardemaker, 1889b; Glatzel, 1901) Rotating cylinder (Hellman, 1926)
	(ii) Sound during forced expiration (Bruck, 1901)
	(iii) Humming by each side of the nose in turn (Spiess, 1902)
	(iv) Rosenthal's Nasal Tolerance Test (1904)
	(b) DIRECT
	(i) Volume (fixed pressure and time) (Mendel, 1897; Jacobson, 1897)
	(ii) Time (known volume and pressure) (Kayser, 1895; Gärtner, 1911)
	(iii) Pressure or resistance (measured volume and time) = Rhinomanometry
RHINOMANOMETRY	(a) RELATIVE changes in resistance (Bloch, 1888; Zwaardemaker, 1895)
	(b) ABSOLUTE measurements of resistance (and volume and time)
	(i) Resistance, and rate of air flow (= volume in a given time) Aerodromometer (Zwaardemaker, 1909) Rhino-anemomanometer (Undritz, 1930)
	(ii) Respiratory volume, time and resistance (Worms and Bolotte, 1928; Uddströmer, 1940)
	(iii) Known volume, given time, measuring resistance Insufflation (van Dishoeck, 1935) Aspiration (Sternstein and Schur, 1936)

---

reduced to absolute figures in accordance with aerodynamic laws, the tracings adequately convey the activity of the mucous membrane in terms of nasal resistance or passability. Vasodilatation increases the obstruction or resistance with a greater excursion of the manometer, while vasoconstriction diminishes the resistance with narrowing of the record. Drugs may be insufflated into the nose by a small atomizer attached to a side limb of the cannula.

### Stimulation of the Cervical Sympathetic Chain

Stimulation of the cervical sympathetic chain produces an immediate vasoconstriction the intensity of which is directly related to the strength

## Vasomotor Activities of Nasal Mucous Membrane

of stimulation, up to a maximum when as one might expect, no further vasoconstriction is possible. So sensitive is the sympathetic chain to stimulation that slight manipulation causes vasoconstriction.

Application of nicotine to the superior cervical ganglion causes a considerable but transient vasoconstriction after which stimulation of the chain fails to produce a response (depolarization). Failure of conduction also ensues if the chain is infiltrated with 2 per cent. procaine.

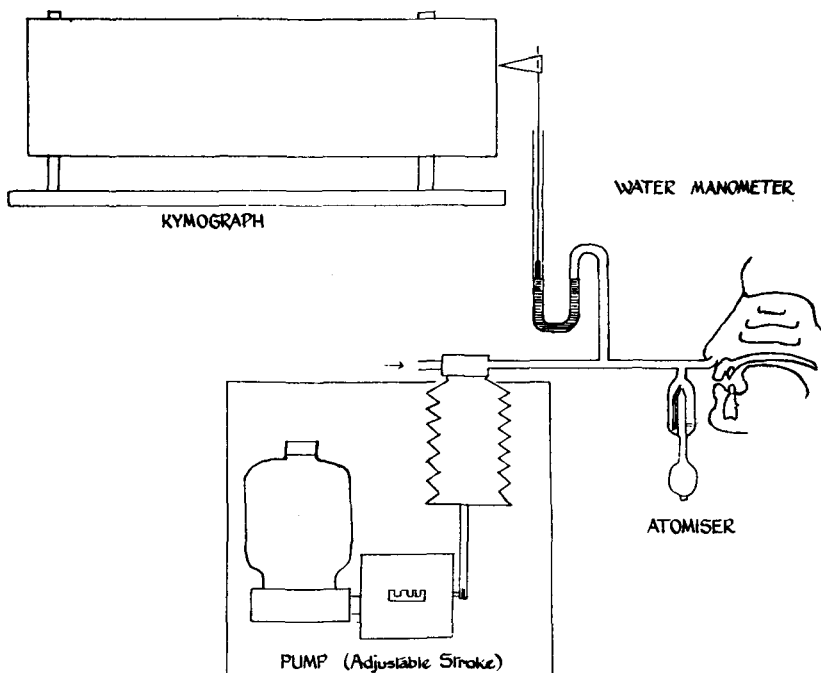


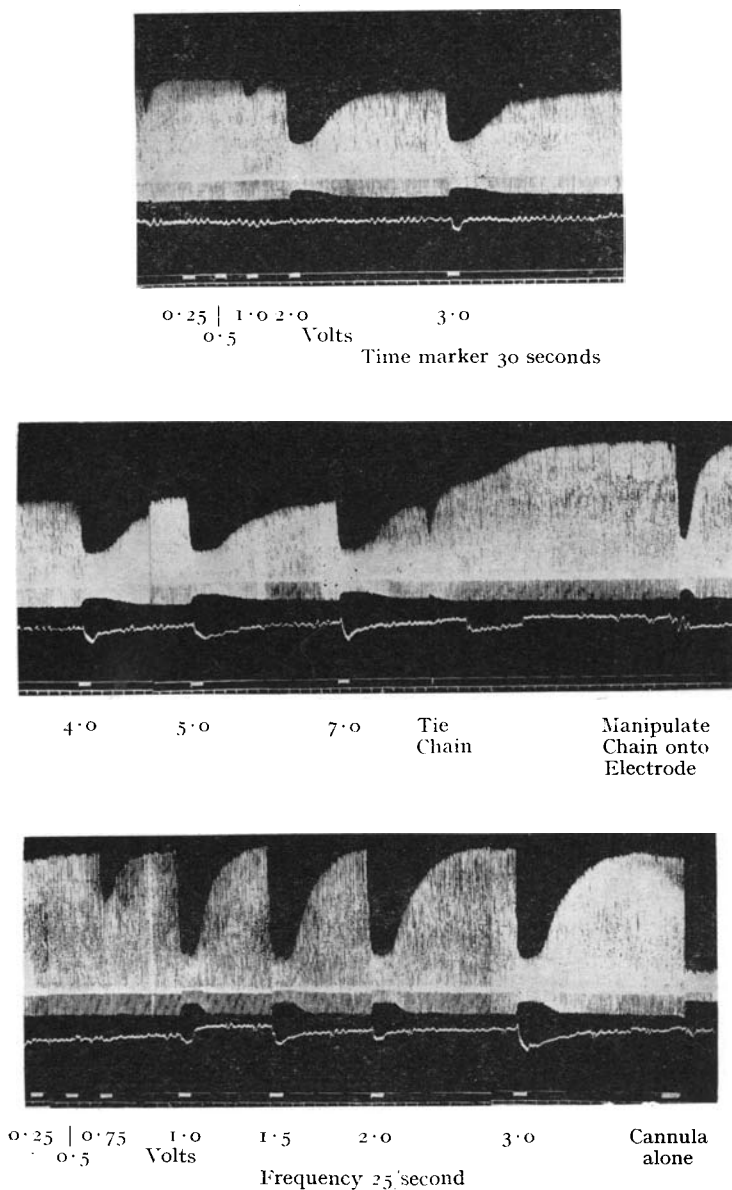
FIG. 2.

Diagram of apparatus for recording nasal vasomotor changes.

When the sympathetic chain is stimulated in continuity a number of times in succession one finds superimposed on the basic pattern of "vasoconstriction-recovery-vasoconstriction etc." that the resistance fails to return exactly to the resting level (Fig. 3). In other words, the plateau (on the record) of the resting resistance gradually falls to form a step pattern. If after maximal vasoconstriction has been reached the chain is divided, there is an immediate restoration to the original resting resistance, and in fact the record may continue to rise far beyond this, producing a considerable degree of nasal obstruction.

This finding implies the presence of afferent fibres in the cervical sympathetic chain mediating a reflex increase in the vasoconstrictor tone

K. Greer Malcomson



STIMULATION OF THE CERVICAL SYMPATHETIC CHAIN

FIG. 3.

Stimulation of the cervical sympathetic chain. The first half of the record shows a series of stimulations in continuity; note the fall in the level of the resting resistance. The chain is then tied, and the peripheral cut end is manipulated on to the electrode; note the vasoconstrictor response with mechanical stimulation. The second half of the record shows an increased sensitivity to stimulation and a higher level of resting resistance.

## Vasomotor Activities of Nasal Mucous Membrane

in the nose. There are no significant effects exerted on the systemic blood pressure, indicating that this is largely a local reflex. When the peripheral cut end of the cervical sympathetic chain is now stimulated there is always a full restoration to the resting resistance after successive stimulations. If the central cut end of the chain is stimulated, and sometimes even during stimulation in continuity, observable effects on the systemic blood pressure occur, further evidence of the existence of afferent fibres in the

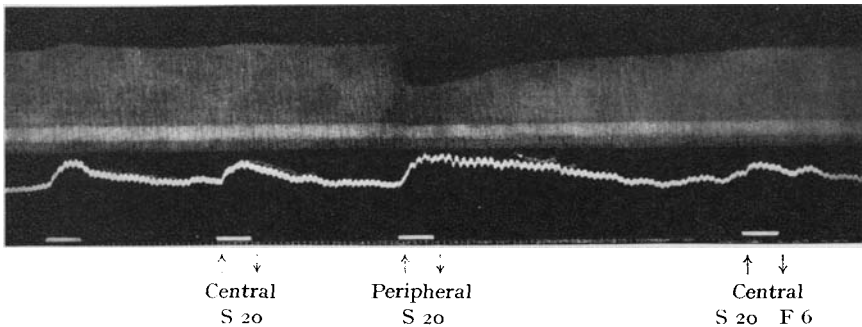


FIG. 4.

Stimulation of the central and peripheral cut ends of the cervical sympathetic chain. There is a rise in blood pressure with both stimulations, but passive dilation of the nose occurs with the one and active vasoconstriction with the other.




FIG. 5.

Stimulation of cervical sympathetic.

cervical sympathetic chain (Fig. 4). These afferents do not participate in the sneezing reflex, for no sneezing efforts occur during stimulation either in continuity or of the central cut end of the chain.

When the vidian nerve is divided or the sphenopalatine ganglion is excised, the response of the nasal mucous membrane to stimulation of the chain is almost completely abolished (Fig. 5). An insignificant number of vasoconstrictor fibres reach the nose by the ethmoidal nerve (*q.v.*) and probably also a minute proportion by branches of the maxillary artery.

K. Greer Malcomson

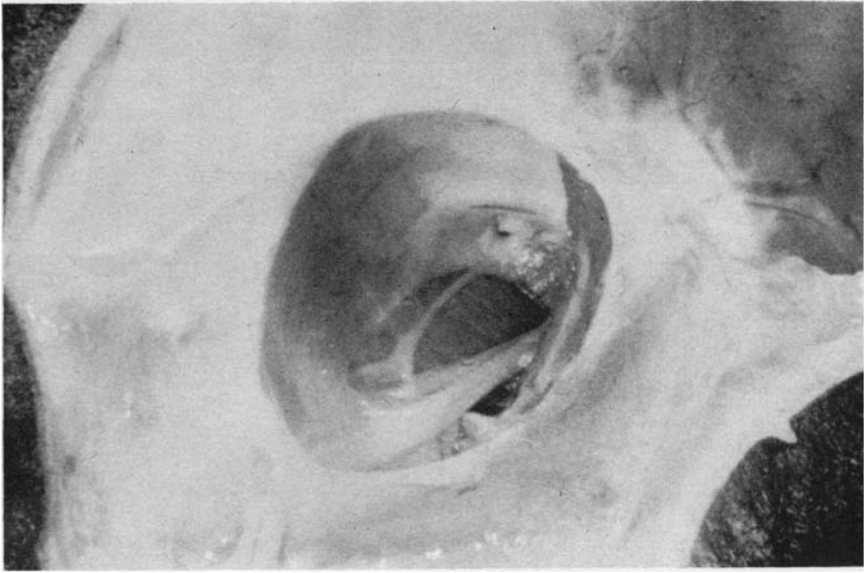


FIG. 6.

Transorbital approach to the vidian nerve. The nerve lies on the pterygoid muscle on the medial side, and the infra-orbital nerve lies more laterally. The sphenopalatine ganglion is easily seen.

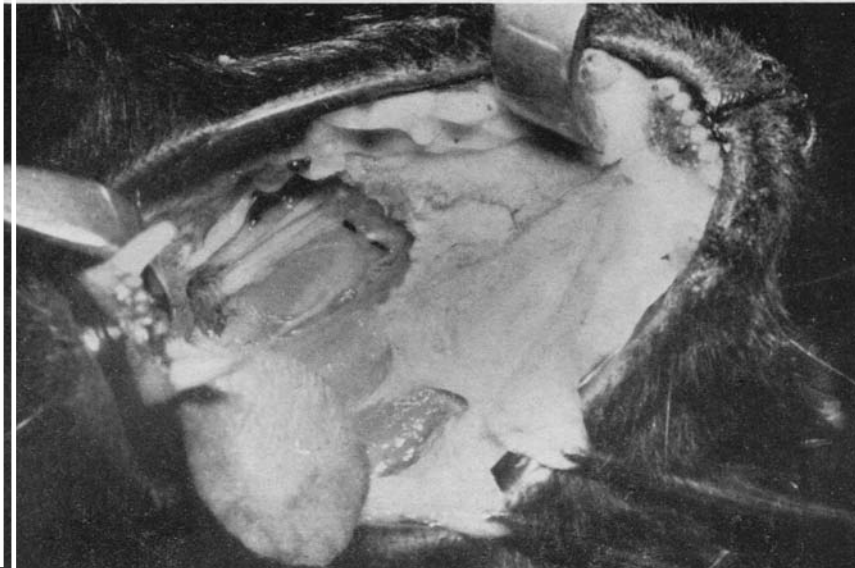


FIG. 7.

Transpterygoid approach to the vidian nerve. The mouth is widely opened for access. The pterygoid muscle is removed and some of the hard palate is excised. A glass rod has been placed below the sphenopalatine ganglion.



## Vasomotor Activities of Nasal Mucous Membrane

When the sympathetic and parasympathetic supplies are stimulated simultaneously, vasoconstrictor effects overshadow and dominate all vasodilatory effects.

### Stimulation of the Parasympathetic Supply

The nerve of the pterygoid canal, commonly known as the vidian nerve, is constituted in the cat in the same manner as in man. The parasympathetic sensory and motor components leave the facial nerve at the geniculate ganglion as the greater superficial petrosal nerve, which joins the deep petrosal nerve to form the vidian nerve. The motor components synapse in the sphenopalatine ganglion, and the nerve is ultimately distributed with the branches of the maxillary nerve to the nose. In the cat the preganglionic section of the nerve may be approached from above *viâ* the orbit (Fig. 6), or from below through the external pterygoid muscle (Fig. 7).

At lower strengths of stimulation (up to 5.0-10.0 volts) of the vidian nerve, vasodilatation occurs, accompanied by sneezing efforts. As the strength of stimulation is increased a neutral state develops with the mucous membrane wavering uncertainly between vasodilatation and vasoconstriction. Beyond this, vasoconstriction is usually the only response, but sneezing still occurs (Fig. 8).

This biphasic response forms a constant pattern; it is probably related to the constitution of the vidian nerve which is composed of thicker, rapidly conducting medullated preganglionic fibres on the parasympathetic side which are more sensitive than the slowly conducting non-medullated postganglionic fibres on the sympathetic side.

When eserine 1:100,000 is applied to the sphenopalatine ganglion, the parasympathetic effects of vidian nerve stimulation are potentiated (Fig. 9). Nicotine depolarizes the ganglion with a transient burst of impulses causing a vasodilatation, after which stimulation of the preganglionic section only produces a vasoconstrictor response at the same levels as before, *viz.*, about 7.0-10.0 volts. There is thus a lower threshold for stimulation of the medullated preganglionic fibres in the sympathetic chain than there is for the non-medullated postganglionic sympathetic fibres in the vidian nerve.

No sneezing efforts are made when nasal branches of the maxillary nerve are stimulated; instead complex facial twitching, jaw clenching and withdrawing movements appear.

After superior cervical ganglionectomy and allowing time for degeneration of the postganglionic fibres, stimulation of the vidian nerve always produces a vasodilatation irrespective of the strength of stimulation and this can be potentiated by applying eserine to the ganglion (Fig. 10). Sneezing is present on stimulation of the nerve in continuity or of its

K. Greer Malcomson

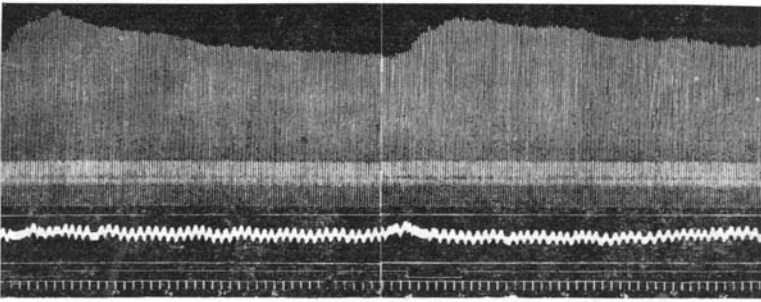
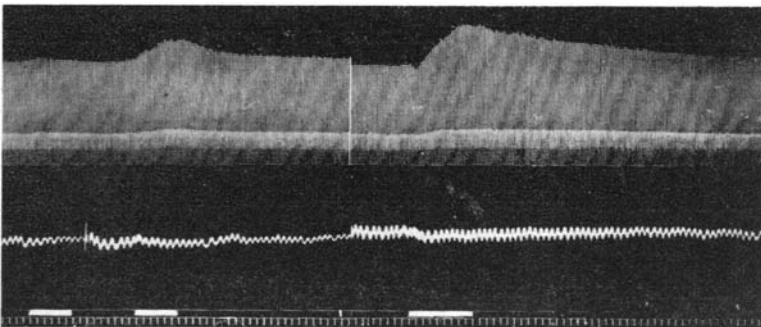


FIG. 8.

Stimulation of the vidian nerve showing the biphasic response. Each stimulation is for 60 seconds. The stimulations shown are at 5.0, 10.0, 12.5 and 15.0 volts respectively.



Volts 2.0

5.0

5.0

ESERINE 1:100,000 FOR 10 MINUTES

FIG. 9.

Stimulation of the vidian nerve. Following the application of eserine 1:100,000 to the sphenopalatine ganglion for 10 minutes, the vasodilator response is potentiated.

## Vasomotor Activities of Nasal Mucous Membrane

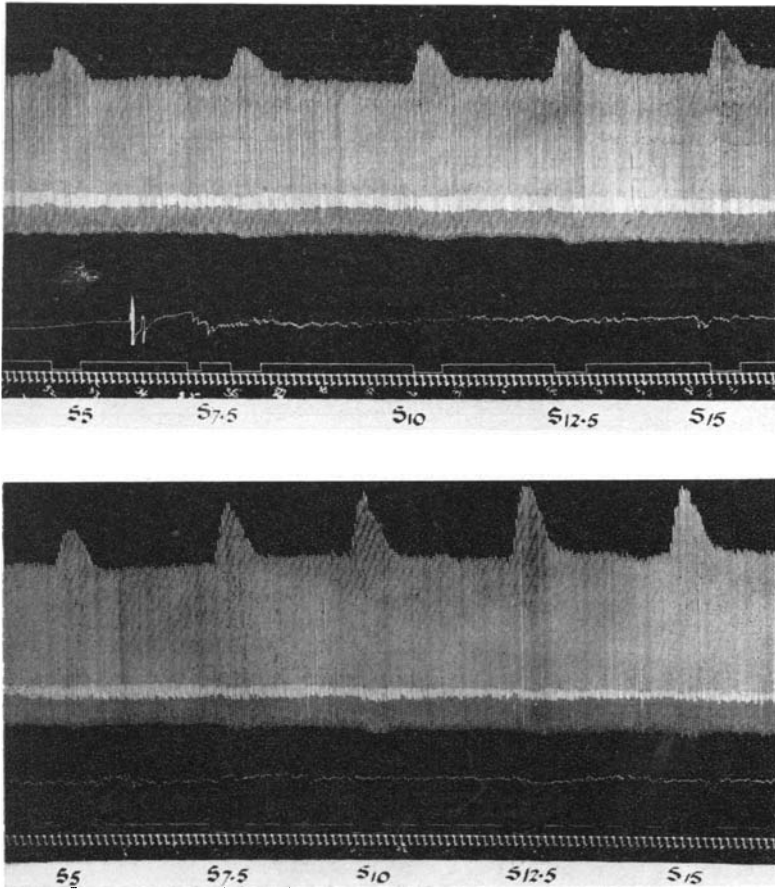


FIG. 10.

Stimulation of the vidian nerve after elimination of the sympathetic component by superior cervical ganglionectomy one month previously. After a series of stimulations, eserine 1:100,000 is applied to the sphenopalatine ganglion; when the stimulations are repeated, there is an increase in the vasodilator response.


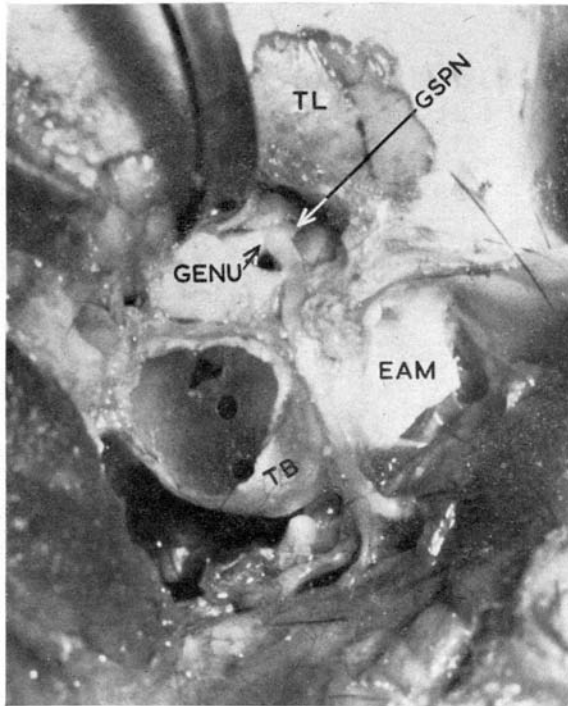


FIG. 11.

Stimulation of cervical sympathetic during stimulation of vidian nerve.

## K. Greer Malcomson

central cut end, but not on stimulation of the peripheral cut end. In a ganglionectomized preparation, vasoconstriction is completely eliminated whereas in the intact animal, vasoconstrictor effects prevail at comparatively low levels of stimulation notwithstanding the simultaneous stimulation of the vasodilator fibres in the parasympathetic component of the vidian nerve. This can be further demonstrated by weak stimulation



THE FACIAL NERVE

FIG. 12.

The facial canal is opened between the external auditory meatus (E.A.M.) and the tympanic bulla (T.B.), and followed medially across the internal ear to expose the genu of the facial nerve. The greater superficial petrosal nerve can be seen passing forwards from this point.

of the vidian nerve (at vasodilatory levels) and the sympathetic chain simultaneously, separately, or in either order, when sympathetic dominance is invariable (Fig. 11).

### Stimulation of the Greater Superficial Petrosal and Facial Nerves

Access to the greater superficial petrosal nerve, and to the facial nerve central to the geniculate ganglion is not easy. Both these nerves are difficult to expose in the cat (Fig. 12). When either is stimulated the

## Vasomotor Activities of Nasal Mucous Membrane

response is always vasodilatation, similar in pattern to that produced by vidian nerve stimulation in the ganglionectomized animal (Figs. 13, 14 and 15). Sneezing and lacrimation are both present.

### The Ethmoidal Nerve and the Ciliary Ganglion

In the cat the ciliary ganglion is a spherical structure about 2.0 mm. in diameter directly below the optic nerve about 10.0 mm. proximal to the globe (Fig. 16). Centrally it receives parasympathetic preganglionic fibres from the oculomotor nerve, and sympathetic fibres from the carotid plexus. Its branches pass mainly to the globe but filaments connect it to the nasociliary nerve, which continues as the ethmoidal nerve.

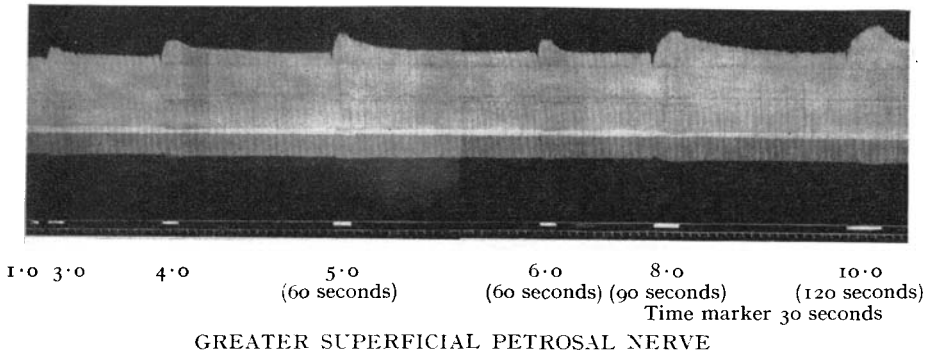


FIG. 13.

Stimulation of the preganglionic and postganglionic connections of the ganglion produces vasoconstriction as the principal response, but vasodilatation has been demonstrated, and feeble sneezing efforts also occur (Figs. 17, 18, 19). The ethmoturbinal area is not important for air-conditioning, so these responses represent the insignificant vasomotor and secretomotor activity of this part of the nose. So far as I am aware an autonomic innervation of this area of the nose has not previously been demonstrated physiologically.

### Hypothalamus

The practical implications of a study of the hypothalamus in relation to the nose are not very great so little time was devoted to it in the present series.

Stimulation of the hypothalamus produces local changes in the nasal airway; those shown are due to vasoconstriction (Fig. 20). Homolateral activity of the pupils and nictitating membrane occur but general

# K. Greer Malcomson

## GREATER SUPERFICIAL PETROSAL NERVE AND THE CERVICAL SYMPATHETIC CHAIN

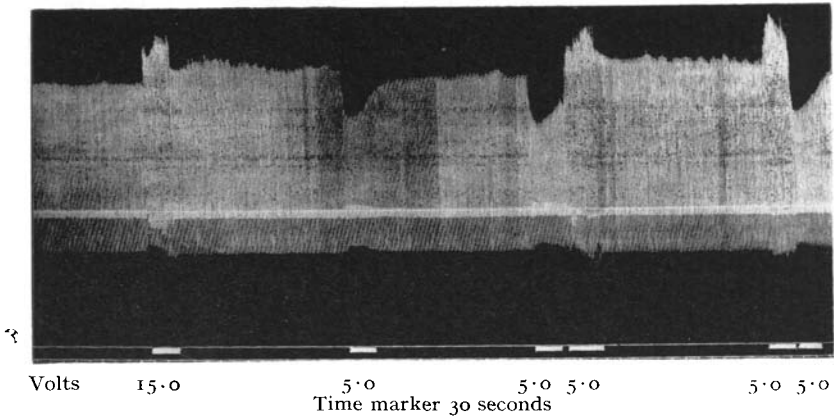


FIG. 14.

Stimulation of the greater superficial petrosal nerve and the cervical sympathetic chain.

1st marker: Petrosal nerve, 15.0 volts.

2nd marker: Sympathetic chain, 5.0 volts.

3rd marker: Consecutive stimulation of the chain and the nerve at 5.0 volts.

4th marker: Consecutive stimulation of the petrosal nerve and the chain at 5.0 volts.

Volts 5.0 0.0 10.0 12.5  
Time marker 10 sec.

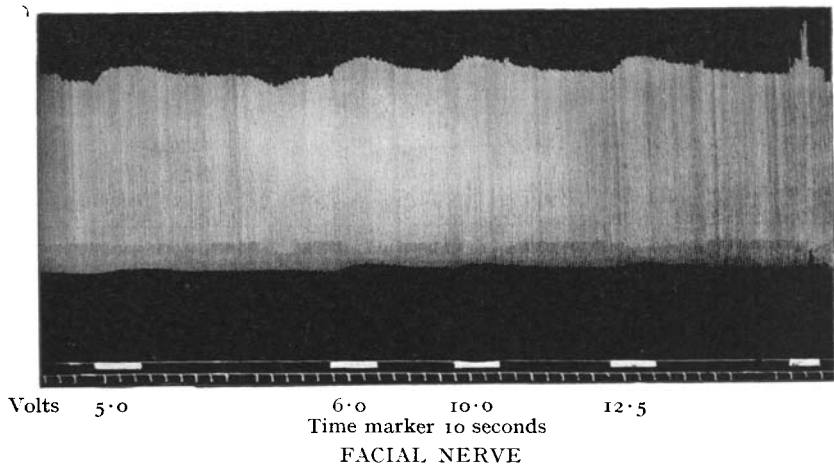


FIG. 15.

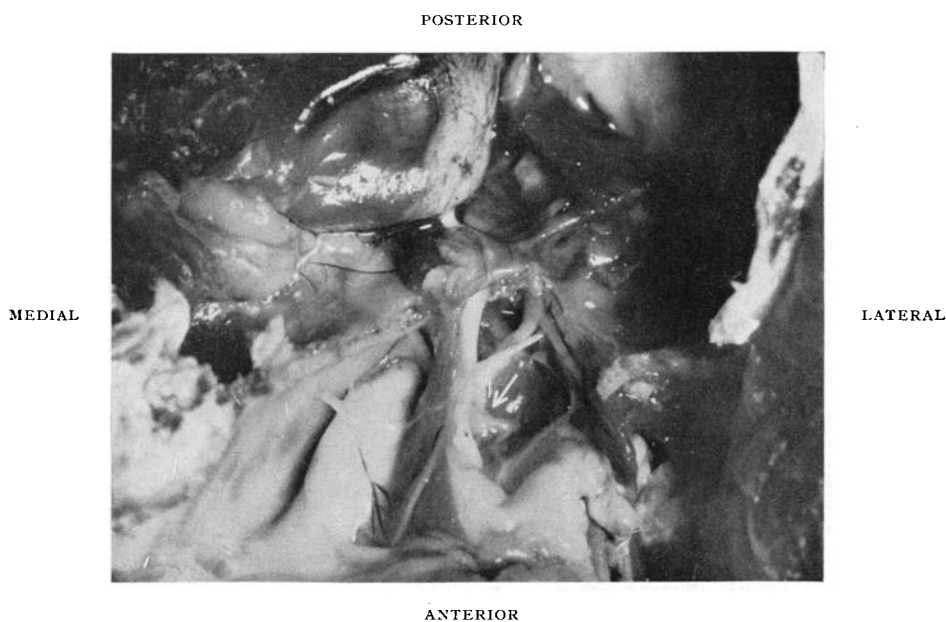
## Vasomotor Activities of Nasal Mucous Membrane

sympathetic effects may also be produced as shown by the simultaneous blood pressure tracing.

### Secretomotor Activities of the Nasal Mucous Membrane

Nasal mucus is composed of 96 per cent. water and about 3 per cent. mucin. The mucin confers viscosity and a stickiness so that the secretions are lightly adherent to the cilia, and at the same time are coalesced into a continuous transparent film which covers the entire mucous membrane.

In investigating the parotid or submaxillary glands, the rate, quantity



CILIARY GANGLION AND ETHMOIDAL NERVE (arrow shows the ciliary ganglion)

FIG. 16.

The ciliary ganglion and ethmoidal nerve. The collapsed eyeball has been displaced upwards. The ganglion lies below the optic nerve which is lying in its normal position. The ethmoidal nerve crosses the oculomotor and optic nerves, the medial rectus muscle and orbital fat to reach the ethmoidal foramen.

and viscosity of the secretions are easily determined by cannulation of their respective ducts. If the same principle is applied to the nose by regarding the postnasal space as a duct and cannulating it for the collection of mucus, it is found that the method is unsatisfactory owing to the viscosity (variously quoted as 8-14 times that of gastric mucus) and to the slow rate of flow. Unlike the discrete drops of salivary secretion, nasal mucus is produced as a thin continuous elastic stream.

K. Greer Malcomson

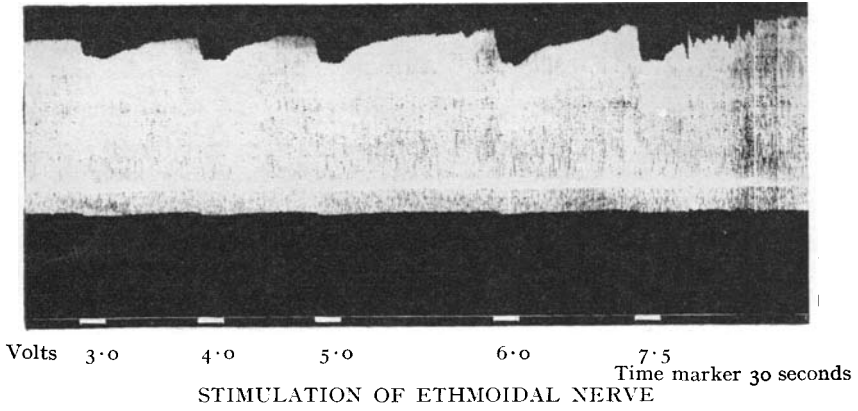


FIG. 17.

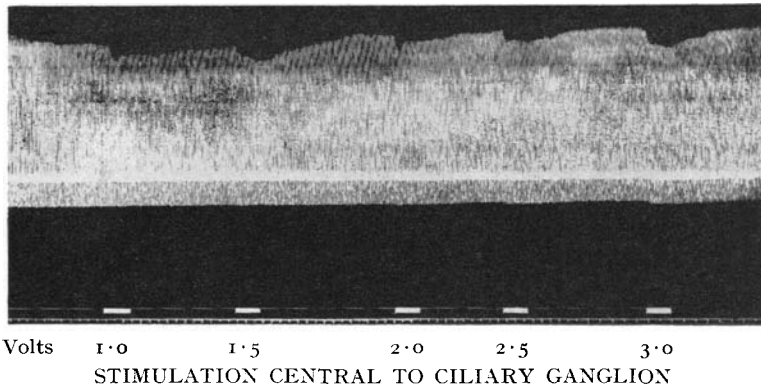


FIG. 18.

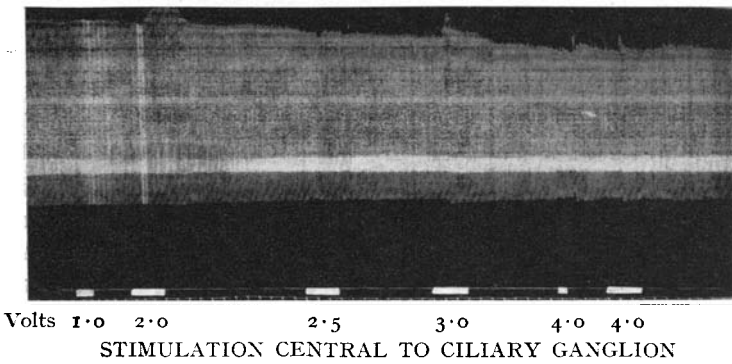


FIG. 19.



## Vasomotor Activities of Nasal Mucous Membrane

Direct observation of the mucous membrane gives a visual estimation of its secretomotor and vasomotor activities. The hard palate is removed to expose the maxilloturbinal system (Fig. 21). The contraction and pallor of the turbinates and the swell body of the septum on sympathetic stimulation is striking, and as the moist surfaces separate, little strands of mucus are drawn out and snap when the tension exceeds the viscosity. Parasympathetic stimulation produces sneezing, and in some preparations increased secretions are visible.

### Pharmacological Aspects

Preparations such as vasoconstrictors, inhalations, antihistamines and now cortisone derivatives are frequently prescribed for nasal conditions. New preparations are constantly being produced, some of which are

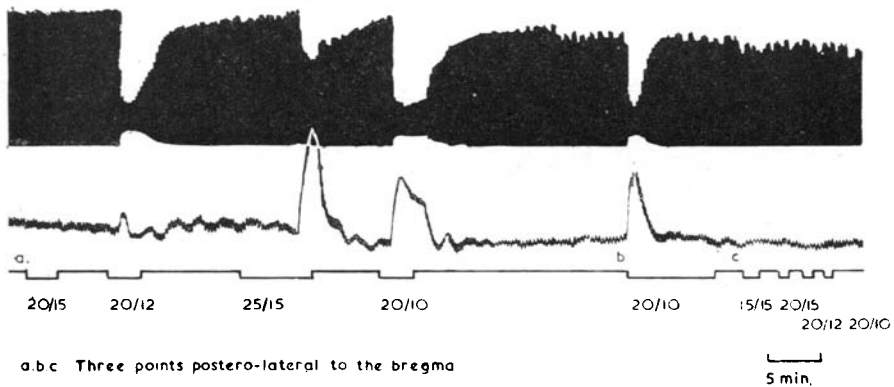


FIG. 20.  
Stimulation of higher centres of the hypothalamus.

sufficiently effective to become generally acceptable and widely prescribed for use by the nasally afflicted public, while those which fail to displace the well-tried (and often less expensive) preparations are soon forgotten.

The guinea-pig ileum is one of the most sensitive biological indicators for determining the protective value of the antihistamines against histamine, and *in vivo* the bronchial tree of the guinea-pig is used for the same purpose. The nasal mucous membrane would appear to be the ideal tissue for a laboratory study of the antihistamines in relation to rhinology, but in the tracheotomized guinea-pig the absorption of histamine aerosol from the nose is so rapid that bronchospasm dominates the result, a fact which may have an analogy in human asthma. In the cat, histamine aerosol produces a vasodilatation (Fig. 22) which is only moderately influenced by the administration of antihistamines. Diphenhydramine (Benadryl) for example, is a weak vasoconstrictor in the nose (Fig. 23), and indeed a slight increase in the vasoconstrictor tone in the human nose

## K. Greer Malcomson

would explain the effectiveness of these drugs in specific and nonspecific vasomotor rhinitis.

Other vasodilators such as amyl nitrite, priscol and dilatal produce insignificant changes in the nose; their effects are mainly on the systemic blood pressure.

In contrast, the nose is extremely sensitive to vasoconstrictors, and dilutions of adrenaline 1:200,000,000 intravenously frequently register a reaction; on several occasions adrenaline 1:1,000,000,000 has produced a

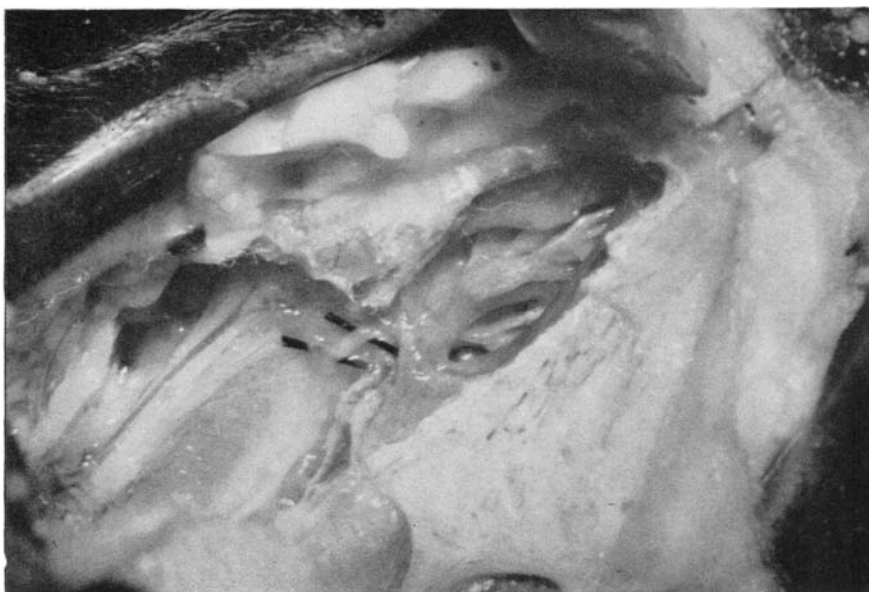

FIG. 21.

The hard palate has been excised to expose the nasal mucous membrane from below. The pterygoid muscle has been removed for access to the vidian nerve. Rods have been placed under the sphenopalatine ganglion and the postganglionic section of the nerve.

perceptible response. The nose is thus the most sensitive organ in the body to adrenaline—five times more sensitive than the heart or the nictitating membrane. In the sympathectomized nose, the reaction to minute traces of adrenaline intravenously appears earlier than on the intact side (Figs. 24 and 25) in accordance with the generally accepted fact that when an area has been sympathetically denervated by ganglionectomy or postganglionic sympathectomy, the local response to injected or circulating adrenaline is exaggerated.

The nose preparation is excellent for comparing the properties of different vasoconstrictors and for correlating these with levels of sympathetic stimulation (Fig. 26).

# Vasomotor Activities of Nasal Mucous Membrane

## Applied Physiology

A detailed knowledge of the activities of the nasal mucous membrane is valuable for a proper understanding of nasal disturbances and for their intelligent management.

### *Interruption of the parasympathetic nerve supply*

The greater superficial petrosal nerve has been sectioned in migrainous neuralgia with complete relief (Gardner and Stowell, 1947); the nasal features noted were unilateral dryness, crusting and smaller turbinates. The petrosal nerve may be damaged during section of the sensory roots

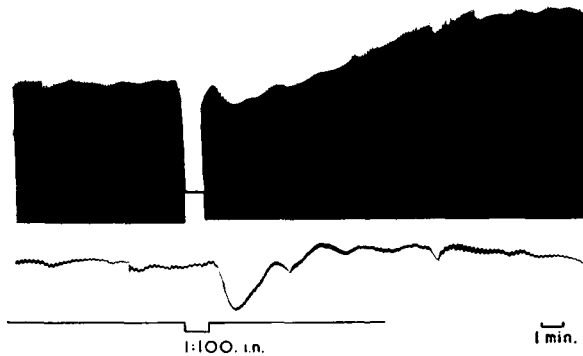


FIG. 22.  
Effect of intranasal histamine.

of the trigeminal for neuralgia, or the facial nerve may be sacrificed during excision of an acoustic neuroma. I have examined a few patients in these categories, and there was no evidence of gross nasal disturbance.

In 1953, I saw a patient at Guy's Hospital with a Bell's palsy within a few days of the onset; he complained of nasal obstruction on the same side, which was due to massive unilateral crusting, and the mucous membrane was dry and glazed. This state of affairs recovered within two weeks, although impaired lacrimation and the palsy persisted.

In view of the insignificant disturbance in nasal physiology following parasympathetic section, it was decided to try the effect of petrosal section in severe nonspecific paroxysmal vasomotor rhinitis which had resisted all standard conservative treatments. In a series of 400 cases of vasomotor disturbances of the nose studied at Guy's between 1950 and 1953, only one patient was considered suitable for this form of treatment. Sneezing persisted after division of one nerve but the rhinorrhœa was now unilateral, and apart from some widening of the airway, there was no undue dryness or crusting. After a period of about a year, petrosal section was carried out on the other side with complete cessation of all paroxysmal symptoms.

## K. Greer Malcomson

No nasal disability ensued (the absence of lacrimation had no adverse effect on the conjunctiva) and head colds pursued a normal course; in fact, a small polyp appeared for a time during a cold (Reading and Malcomson, 1954).

The anterior opening of the pterygoid canal in man is 4-5 mm. lateral to the sphenopalatine foramen so that the vidian nerve is often the first distinctive structure to be involved in the lateral spread of nasopharyngeal growths. Although lacrimation may be impaired, this is not usually

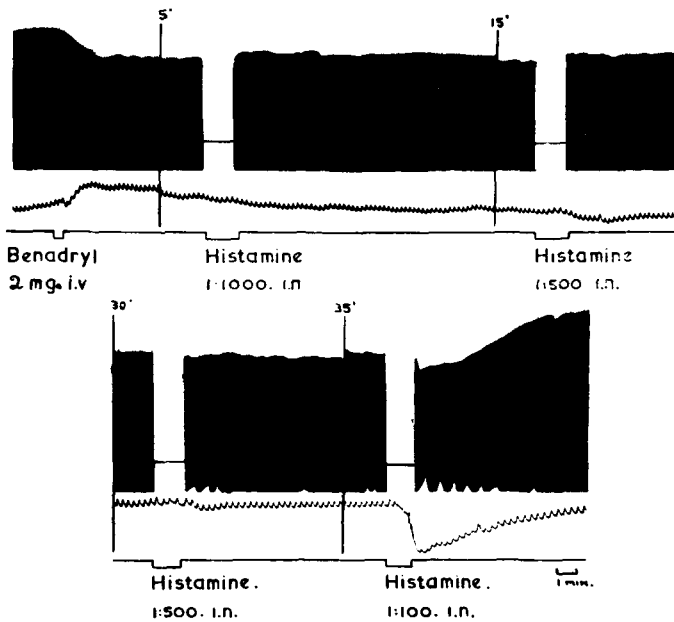


FIG. 23.

noticed by the patient, and apart from the local effects of the disease, the nasal mucous membrane remains normal. Theoretically palatal taste should be dulled or lost but this is not recorded as a clinical feature.

In view of the ease with which the vidian nerve may be divided, it is a logical step to consider this in the treatment of nonspecific paroxysmal vasomotor rhinitis if all other treatments have failed and if the symptoms are sufficiently severe to justify it.

A submucous resection of the septum is carried back to the sphenoid. The mucous membrane of the nasopharynx is now mobilized, first off the junction of the anterior wall and the floor of the sinus, and then laterally until the upper part of the medial surface of the medial pterygoid plate is defined. Further lateral mobilization of the mucous membrane in front of the anterosuperior angle of the medial pterygoid plate leads into the small

## Vasomotor Activities of Nasal Mucous Membrane

funnel-shaped opening of the pterygoid canal, and the vidian nerve is avulsed with elevators. The foramen rotundum is 12·0 mm. lateral to the sphenopalatine foramen, and is separated from the pterygoid canal by a tongue of bone so that inadvertent injury of the maxillary nerve is unlikely (Figs. 27, 28 and 29).

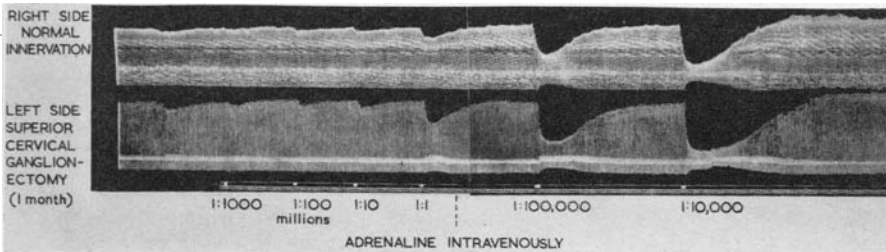


FIG. 24.

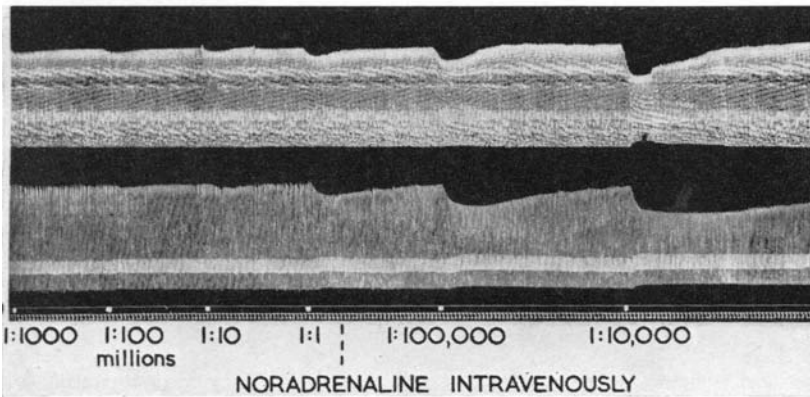


FIG. 25.

Sensitivity of the nasal mucosa to noradrenaline following sympathectomy.  
 Upper tracing—right side with intact innervation.  
 Lower tracing—left side denervated by superior cervical ganglionectomy one month previously.

As against petrosal section, this procedure has the merit of simplicity, and both nerves may be sectioned at the same time. Other approaches to the nerve, e.g. transantral, involve more trauma and give access to only one nerve.

Vidian neurectomy produces an autonomic denervation of the air-conditioning part of the nose. To the effects of pure parasympathectomy are added those of a postganglionic sympathectomy, which produces an increased sensitivity of the mucosa to circulating adrenaline. The immediate effects of this procedure are satisfactory but unfortunately no long-

## K. Greer Malcomson

term results are available. Moreover, such a study would provide the material for a separate communication.

The treatment of nonspecific paroxysmal vasomotor rhinitis is as unsatisfactory as that of psychosomatic disorders in general, a field in which wishful-thinking and misinterpretations may cloud critical clinical observation. Vidian nerve section should be regarded as a last expedient in this condition, in spite of the physiological basis presented here, until experience defines its precise indications and limitations.

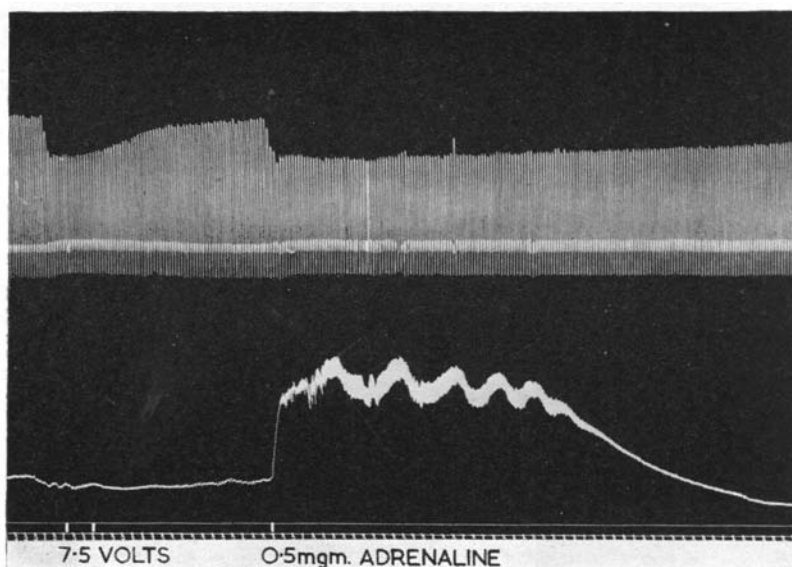


FIG. 26.

The cervical sympathetic chain is stimulated at 7.5 volts. On return to resting levels, adrenaline 0.5 mg. is given intravenously.

When emotional factors are a feature in nonspecific paroxysmal vasomotor rhinitis (O'Neill and Malcomson, 1954), the psychosomatic mechanism involved may be a resurrection of the emotional reaction of the child to such disturbing feelings as frustration, anger, insecurity, and so on. The child frequently responds to these emotions by crying, and this is usually accompanied by watery rhinorrhœa. In the adult the efferent pathway for the emotional expression is the same but the lacrimation is largely suppressed and the rhinorrhœa persists, while the underlying psychological mechanism remains unsuspected by the patient.

### *Interruption of the sympathetic supply*

Cervical sympathectomy was observed to produce a unilateral nonspecific vasomotor rhinitis by Fowler (1943). It was characterized by

## Vasomotor Activities of Nasal Mucous Membrane

hyperæmia, hypersecretion and swelling of the mucosa, features which have been repeatedly confirmed by most rhinologists since. Curiously Fowler detected a large number of eosinophils in the secretions on the sympathectomized side.

The present study has revealed the existence of a local sympathetic tone which is mediated by afferent fibres in the cervical chain, and which is increased by sympathetic stimulation or irritation.

In atrophic rhinitis, the mucous membrane is shrunken due to a reduction in its vascular bed and there are profoundly secondary epithelial changes. This disorganization of the fundamental functions of the nose

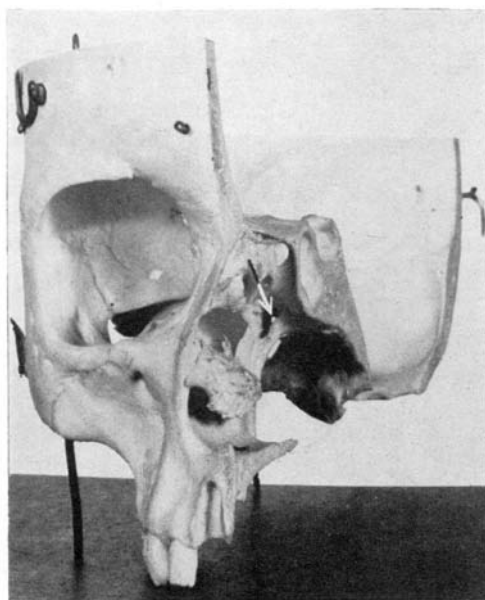


FIG. 27.

Hemisection of the skull viewed obliquely from the front. Arrow points to pterygoid (vidian) canal.

resembles Raynaud's Disease in a number of ways—it occurs in the adolescent or young woman and it affects very active vasomotor areas, both of which have a rich sympathetic innervation. A preganglionic superior cervical sympathectomy will augment the blood supply to the nose and at the same time avoids the increased sensitivity to adrenaline which occurs with ganglionic or postganglionic section. On this basis I have carried out this procedure seven times in atrophic rhinitis, and there is no doubt that provided permanent organic vascular changes have not occurred, excellent immediate results ensue. I have had the opportunity of observing one patient for 2½ years after the right chain had been divided.

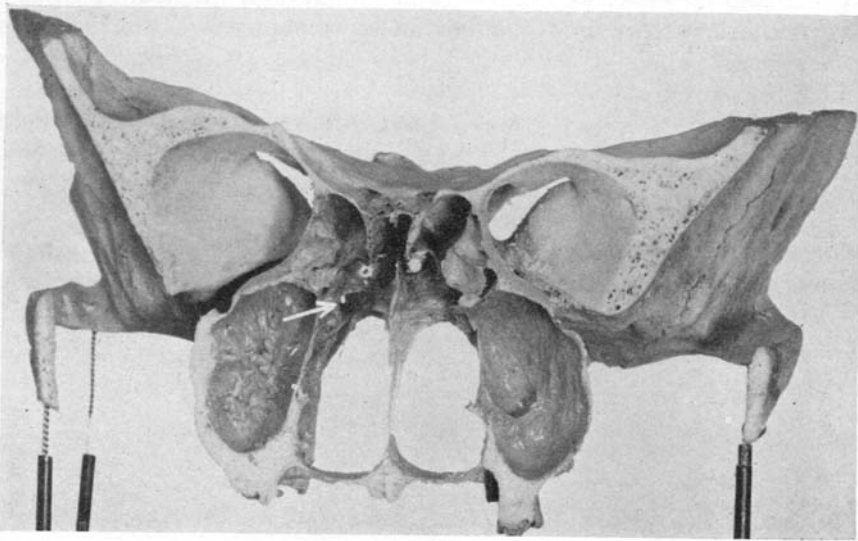


FIG. 28.

Coronal section through the posterior half of the nasal chambers to show the relationship of the vidian canal to the antrum, ethmoid labyrinth and the sphenoid sinus. Arrow points to pterygoid (vidian) canal.

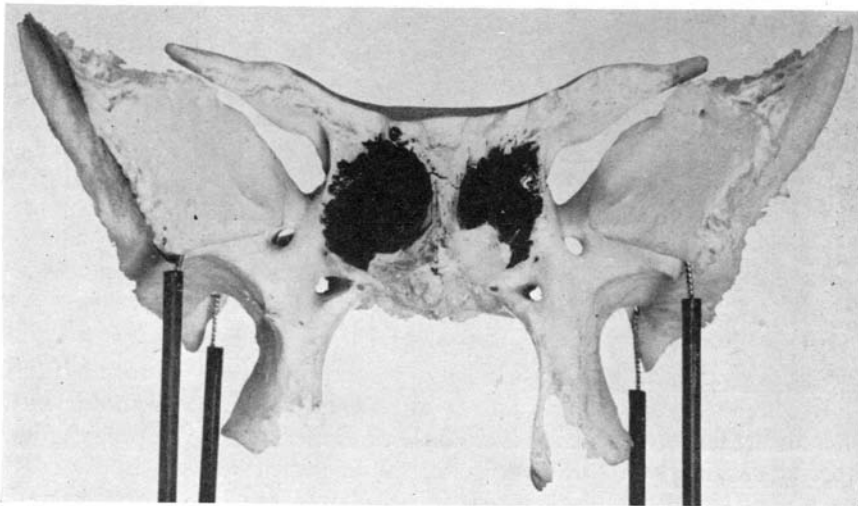


FIG. 29.

The sphenoid. The vidian canals lie at the infero-lateral angles of the sphenoidal sinuses, the walls of which have been darkened. A well-defined ridge separates the vidian canal from the foramen rotundum.



## Vasomotor Activities of Nasal Mucous Membrane

and for a year after the left side had been cut. It was most gratifying to see her nose change from the distressing state of the fully established disorder with its penetrating sickly offensive odour to a perfectly functioning mucous membrane with restoration of normal olfaction. The symmetry of the bilateral Horner's syndrome was virtually unnoticeable and caused no disability.

The prolonged after-dilatation caused by adrenaline 1:1,000 intranasally may be turned to advantage in older patients with atrophic rhinitis in whom operation is unlikely to help.

In conclusion, I hope that this brief talk on the physiology of the nose will give a new freshness to the word "vasomotor" and that the fragments here presented of some of the mechanisms underlying the vasomotor activities of the nasal mucous membrane may contribute to a better understanding of this fascinating, frequent, yet frustrating malady, vasomotor rhinitis.

### Acknowledgments

I would like to take this opportunity of expressing my warm thanks to Professor David Slome in whose department at the Royal College of Surgeons the physiological studies were made, and who showed the greatest enthusiasm and interest in this forgotten facet of physiology.

To my old chiefs at Guy's, Mr. Cann our present president of this section, Mr. Philip Reading and Mr. L. F. W. Salmon, my heartfelt appreciation and thanks for allowing me to study and to operate on their patients when I was their registrar.

These studies were undertaken partly during the tenure of a Leverhulme Research Scholarship at the Royal College of Surgeons of England, and partly during the tenure of a Research Fellowship in the Throat and Ear Department at Guy's Hospital.

### REFERENCES

- BLIER, Z. (1930) *Amer. J. Physiol.*, **93**, 398.  
BLOCH, E. (1888) *Z. Ohrenheilk.*, **18**, 215.  
BRUCK, F. (1901) *Ther. d. Gegenw.*, **42**, 407.  
DAWES, J. D. K., and PRICHARD, M. M. L. (1953) *J. Anat. (Lond.)*, **87**, 311.  
VAN DISHOECK, H. A. E. (1935) *J. Hyg. (Camb.)*, **35**, 185.  
FOFANOW, L. L., and TSCHALUSSOW, M. A. (1913) *Pflüg. Arch. ges. Physiol.*, **151**, 543.  
FOWLER, E. P., JR. (1943) *Arch. Otolaryng. (Chicago)*, **37**, 710.  
GARDNER, W. J., STOWELL, A., and DUTLINGER, R. (1947) *J. Neurosurg.*, **4**, 105.  
GÄRTNER, G. (1911) *Wien. klin. Wschr.*, **24**, 279.  
GLATZEL, F. (1901) *Ther. d. Gegenw.*, **42**, 348 and 501.  
HELLMANN, K. (1926) *Z. Laryng. Rhinol.*, **15**, 1.  
HERTZMAN, A. B., and DILLON, J. B. (1939) *Amer. J. Physiol.*, **127**, 671.  
HILL, L. (1913) *Lancet*, **1**, 1285.  
——— and MUECKE, F. F. (1913), *Lancet*, **1**, 1291.

## K. Greer Malcomson

- JACOBSON, A. W. (1897) *C.R. XII Congr. Méd., Moscou*, **6**, Sect. XII B, 176.
- KAYSER, R. (1895) *Arch. Laryng. Rhin. (Berl.)*, **3**, 101.
- LUCAS, H. A. (1952) *J. Laryng.*, **66**, 480.
- MARTIN, E. G., and MENDENHALL, W. L. (1915), *Amer. J. Physiol.*, **38**, 98.
- MENDEL, H. (1897) *Physiologie et pathologie de la respiration nasale*. Paris.
- MENDENHALL, W. L. (1915) *Amer. J. Physiol.*, **36**, 57.
- MUDD, S., GOLDMAN, A., and GRANT, S. B. (1921) *J. exp. Med.*, **34**, 11.
- , GRANT, S. B., and GOLDMAN, A. (1921) *J. Lab. clin. Med.*, **6**, 175, 253 and 322.
- O'NEILL, D., and MALCOMSON, K. (1954) *Brit. med. J.*, **1**, 554.
- RALSTON, H. J., and KERR, W. J. (1945) *Amer. J. Physiol.*, **144**, 305.
- READING, P., and MALCOMSON, K. (1954) *Brit. med. J.*, **1**, 552.
- ROSENTHAL, G. (1904) *Pr. méd.*, **12**, 129 and 177.
- SLOME D. (1955) *Lectures on the Scientific Basis of Medicine*, **5**, XXVI, 451.
- SPIESS, G. (1902) *Int. Zbl. Laryng.*, **18**, 110.
- STERNBERG, H. (1925a) *Z. Hals-, Nas. -u. Ohrenheilk.*, **12**, 340.
- (1925b) *Zbl. Hals-, Nas. -u. Ohrenheilk.*, **7**, 675.
- STERNSTEIN, H. J., and SCHUR, M. O. (1936) *Arch. Otolaryng. (Chicago)*, **23**, 475.
- TATUM, A. L. (1923) *Amer. J. Physiol.*, **65**, 229.
- TSCHALUSSOW, M. A. (1913) *Pflüg. Arch. ges. Physiol.*, **151**, 523.
- UDDSTRÖMER, M. (1940) *Acta oto-laryng. (Stockh.)*, Suppl. 42.
- UNDRITZ, W. (1930) *Acta oto-laryng. (Stockh.)*, **14**, 513.
- WORMS, G., and BOLOTTE, M. (1928) *L'insuffisance respiratoire nasale*. Paris.
- ZWAARDEMAKER, H. (1889a) [Anosmie] *Ned. T. Geneesk.*, **25** (ii), 2.
- (1889b) *Ned. T. Geneesk.*, **25** (ii), 297. [Ademaanslag als diagnosticum der nasale stenore.]
- (1895) *Die Physiologie des Geruchs*. Leipsig.
- (1909) *Z. Laryng. Rhinol.*, **1**, 625.

2 Rodney Cottages,  
Clifton, Bristol