

Diagnostic Challenge

An unusual cerebral computed tomography image

Pierre-Nicolas Carron, MD;* Mathias Cavassini, MD;† Philippe Maeder, MD;‡ Olivier William Hugli, MD*

CASE PRESENTATION

A 28-year-old prison inmate presented to the emergency department because of a transient loss of consciousness and a fever as high as 40°C. He was a migrant from Equatorial Guinea living in Switzerland for the past 2 years and had been in jail for the previous 2 months. During this period, he became progressively more aggressive and complained of recurrent frontal headaches. The patient denied any significant medical history, took no medications and stated that he had had a negative HIV test a few months prior. On admission, although there were no focal neurologic signs, papillary edema was present along with global psychomotor impairment (disinhibition, perseveration and grasping). Minor dentoalveolar and maxillofacial injuries were noticed. The blood tests revealed leukopenia (white blood cell count $3.4 \times 10^9/L$), mainly concerning lymphocytes, and elevation of the C-reactive protein

(552.4 nmol/L, normal < 95.2 nmol/L). Computed tomography of the head revealed a large nonenhancing frontal “bat-like” hypodensity (Fig. 1). Mild ventricular dilatation (not shown) and compression of the sulci and gyri suggested intracranial hypertension. Lumbar puncture was not performed given the risk of intracranial hypertension.

QUESTION

What is the most likely diagnosis?

- a) glioblastoma
- b) cerebral lymphoma
- c) cerebral toxoplasmosis
- d) neurosyphilis

For the answer to this challenge see page 227.

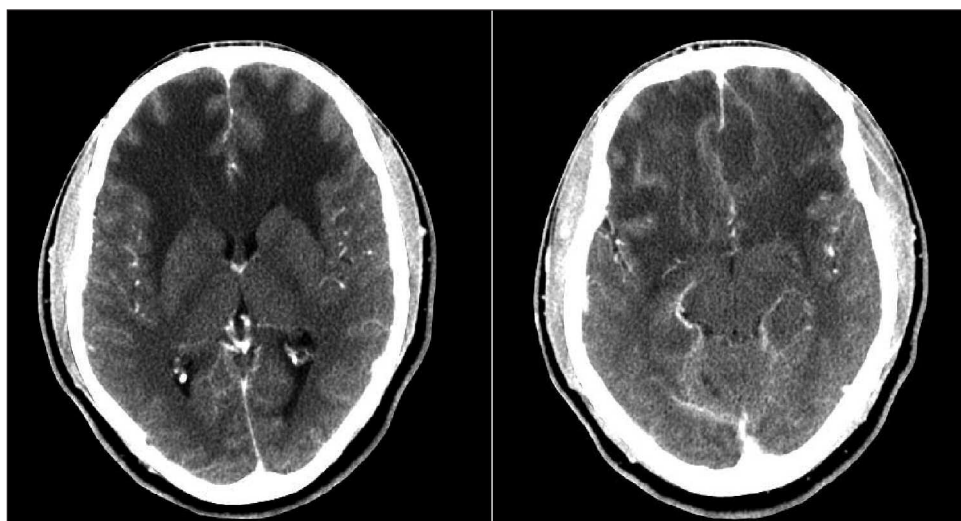


Fig. 1. Two transverse computed tomography slices on the frontal lobe and near the anterior skull base, after contrast injection, showing bilateral extensive hypodensity of the frontal white matter with mass effect.

From the *Emergency Department, the †Service of Infectious Diseases and the ‡Department of Radiology, University Hospital of Lausanne University, Lausanne, Switzerland

Submitted Jun. 8, 2009; Accepted Sep. 26, 2009

This article has not been peer reviewed.

CJEM 2010;12(3):223