



# Fusion computed tomography–magnetic resonance imaging scans for pre-operative staging of congenital middle-ear cholesteatoma

Francesco Maccarrone<sup>1</sup> , Carla Cantaffa<sup>1,2,3</sup> , Maurilio Genovese<sup>4</sup>, Sauro Tassi<sup>1</sup> and Maurizio Negri<sup>1</sup>

## Main Article

Carla Cantaffa takes responsibility for the integrity of the content of the paper

**Cite this article:** Maccarrone F, Cantaffa C, Genovese M, Tassi S, Negri M. Fusion computed tomography–magnetic resonance imaging scans for pre-operative staging of congenital middle-ear cholesteatoma. *J Laryngol Otol* 2024;**138**:507–511. <https://doi.org/10.1017/S0022215123002001>

Received: 12 September 2023

Revised: 4 November 2023

Accepted: 13 November 2023

First published online: 17 November 2023

### Keywords:

Middle ear cholesteatoma;  
diffusion magnetic resonance imaging;  
X-ray computed tomography

### Corresponding author:

Carla Cantaffa;  
Email: [carla.cantaffa@outlook.com](mailto:carla.cantaffa@outlook.com)

<sup>1</sup>Department of Otolaryngology, Ospedale B Ramazzini di Carpi, AUSL Modena, Carpi, Italy, <sup>2</sup>Department of Otolaryngology – Head and Neck Surgery, Azienda Ospedaliero Universitaria di Modena, Modena, Italy, <sup>3</sup>University of Modena and Reggio Emilia / Università degli Studi di Modena e Reggio Emilia, Modena, Italy and <sup>4</sup>Department of Neuroradiology, Azienda Ospedaliero Universitaria di Modena, Modena, Italy

## Abstract

**Objective.** To evaluate if fusion computed tomography–diffusion-weighted magnetic resonance imaging may have a role in the pre-operative assessment of congenital middle-ear cholesteatoma.

**Methods.** A retrospective chart review of surgically treated congenital middle-ear cholesteatoma patients over a 2-year timespan was conducted. Pre-operative staging was performed on computed tomography and fusion computed tomography–diffusion-weighted magnetic resonance imaging based on extension of the disease according to the ChOLE classification system and the Potsic classification system. Intra-operative staging was compared to imaging findings to evaluate accuracy of the two imaging modalities in predicting congenital middle-ear cholesteatoma extent.

**Results.** Computed tomography was able to correctly predict congenital middle-ear cholesteatoma extent in three out of six cases according to the ChOLE classification system, all of which were staged as Ch1a and Ch1b on pre-operative computed tomography. Cases in which computed tomography was not able correctly to determine congenital middle-ear cholesteatoma extent were staged as Ch3 on pre-operative computed tomography. Fusion scans correctly determined congenital middle-ear cholesteatoma extent in all cases according to the ChOLE classification.

**Conclusions.** Fusion computed tomography–diffusion-weighted magnetic resonance imaging may be helpful in cases of congenital middle-ear cholesteatoma where pre-operative computed tomography shows mastoid and antrum opacification, in which computed tomography alone may overestimate cholesteatoma extension beyond the level of the lateral semi-circular canal.

## Introduction

Congenital middle-ear cholesteatoma represents approximately 2–5 per cent of all cholesteatoma cases, although this percentage is likely underestimated. Congenital middle-ear cholesteatoma is defined as a keratinous cyst located behind an intact tympanic membrane. The aetiopathogenesis of this disease is still unclear despite several theories having been proposed. Maccarrone *et al.* showed a histological relationship between congenital middle-ear cholesteatoma and the tensor tympani tendon.<sup>1</sup>

The diagnostic work-up of cholesteatoma includes clinical examination, audiometric tests and imaging studies. For the imaging studies, computed tomography (CT) scan is still considered the gold standard technique because it has excellent spatial resolution and allows delineation of anatomical structures. Magnetic resonance imaging (MRI), on the other hand, is associated with poorer spatial and anatomical discrimination. However, as opposed to CT scans, MRI allows differentiation of the cholesteatoma from other soft tissues by means of diffusion-weighted sequences. To date, the role of MRI in cholesteatoma patients has been reserved almost exclusively to post-operative settings with the aim of investigating suspected recurrent or residual disease, especially when the neo-tympanic membrane is intact and not transparent.

Given these premises, this study sought to investigate whether the fusion of CT and diffusion-weighted MRI images could have a role in improving pre-operative localisation of congenital middle-ear cholesteatoma.

## Materials and Methods

### Patients

A retrospective review of patients surgically treated for congenital middle-ear cholesteatoma at Ospedale Ramazzini in Carpi (Emilia Romagna, Italy) between 2020 and 2022

was performed. No patients with previous ear surgery were included. No age limit was applied to participants as evidence exists that congenital middle-ear cholesteatoma can be diagnosed in adults as well.<sup>2</sup> Congenital middle-ear cholesteatoma was diagnosed on the basis of otoscopic examination and medical history according to Levenson's criteria, which include the presence of a white mass in the middle-ear cavity, normal pars flaccida and pars tensa of the tympanic membrane, no past history of otorrhea and perforation, and no previous otological surgery. Past history of otitis media or effusion was not included as an exclusion criterion. Pre-operative CT and MRI scans were available for all included patients. Surgery was recorded in all cases. This study was approved by the institutional review board of our hospital. Informed consent for study participation was waived due to the retrospective nature of this study.

### Imaging protocols

#### Computed tomography scan

All patients were studied with non-contrast, high-resolution CT performed on multidetector scanners from different vendors. Temporal bone axial slices were obtained with the head in neutral position, thickness of 0.4–0.6 mm and bone algorithm. Images were then reformatted on anatomical axial and coronal planes. On the CT scan, findings suggestive of mastoid involvement included opacification of mastoid air cells in continuity with middle-ear opacification and erosive characteristics, such as widening of the aditus ad antrum and mastoid destruction.

#### Fusion computed tomography–diffusion-weighted magnetic resonance imaging

Pre-operative MRIs were performed in a 1.5T scanner (GE Signa HDXT 1.5 T) with high-resolution sequences for temporal bone study, which included axial and coronal T1w and T2w turbo spin echo sequences, a three-dimensional fast imaging employing steady-state acquisition, axial non-echo planar imaging, diffusion-weighted imaging sequence (periodically rotated overlapping parallel lines with enhanced reconstruction–diffusion-weighted imaging, thickness 3 mm, b-value 800) with apparent diffusion co-efficient map and post-contrast three-dimensional T1w sequence. Findings suggestive of cholesteatoma were a non-enhancing lesion hypointense in pre-contrast T1w images, hyperintense in diffusion-weighted images and characterised by reduced apparent diffusion co-efficient.

Computed tomography–diffusion-weighted MRI fusion was performed on a GE Advantage Workstation (Advantage Work Station 4.7 Volume Share 7). First, CT and fast imaging employing steady-state acquisition images were registered using vestibulocochlear labyrinth as reference structures, then periodically rotated overlapping parallel lines with enhanced reconstruction–diffusion-weighted imaging sequence was fused on CT images using grayscale for CT and a colour map (red–yellow) for diffusion-weighted imaging.<sup>3</sup> Axial and coronal scans were reviewed to assess cholesteatoma extent. All imaging was pre-operatively interpreted by the same neuroradiologist (MG) and surgeons (MN and FM).

Pre-operative staging of cholesteatomas was achieved using two classification systems: (1) Potsic and (2) the extension parameter of the ChOLE classification system. Stage was determined first based on CT images alone, and then based on fusion CT–MRI images. Finally, radiologic staging was

compared with intra-operative staging according to the same classification systems.

The ChOLE classification system, introduced by Linder *et al.* in 2019<sup>4</sup>, is based on the following parameters: extension, status of the ossicular chain at the end of surgery, complications and degree of pneumatisation and ventilation. It may be applied to all cholesteatoma cases, including congenital cholesteatoma. It has the advantage of being able to stratify precisely cholesteatoma cases according to their extent across various anatomical subsites. In detail, extension is defined as class Ch1 when cholesteatoma is limited to the middle-ear space. Class Ch1 extension is further subdivided into Ch1a and Ch1b, with the latter including extension into the sinus tympani. Class 2 extensions involve the middle ear, with further extensions into the attic and antrum (Ch2a) up to the level of the lateral canal within the mastoid. The Ch2b subdivision incorporates anterior extension into the anterior epitympanum (supratubal recess) with optional additional extension into the protympanum and/or extension into the sinus tympani. Class 3 extension encompasses extensive bone erosion, either of the external ear canal and/or the tegmen tympani (with or without necessity of reconstruction of the defect). These cholesteatomas also expand beyond the lateral semicircular canal into the mastoid and may reach the sigmoid sinus and lateral surface of the mastoid bone. Class 4 cholesteatomas are defined as congenital or acquired cholesteatomas with infralabyrinthine, supralabyrinthine or transcochlear extensions (Ch4a) or as apical petrous bone cholesteatomas (Ch4b).

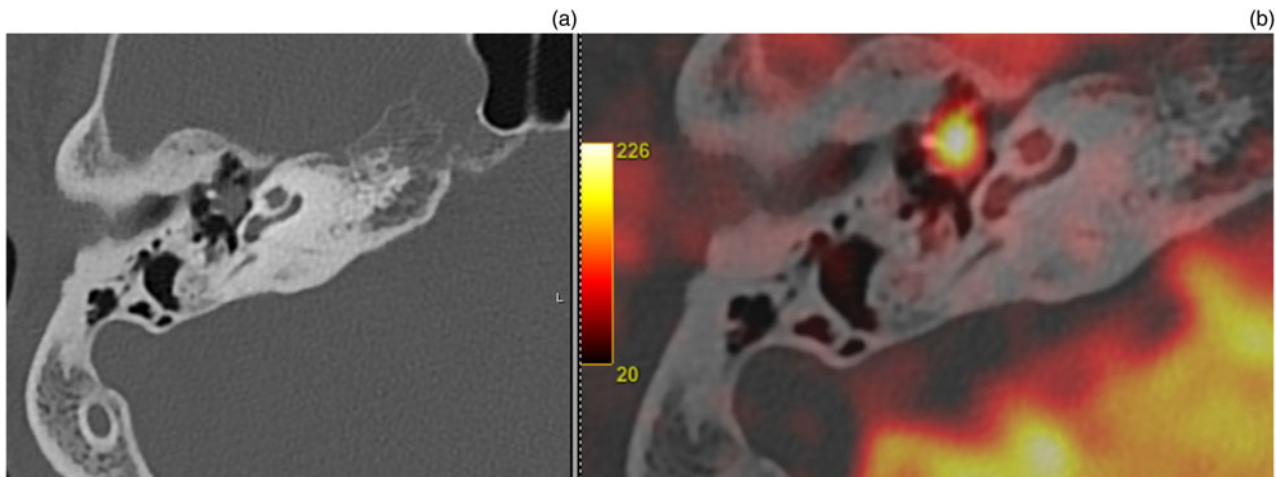
Other parameters of this classification system were not considered in this study as their assessment does not necessitate fusion CT–MRI imaging. In fact, CT scan is the gold standard for ossicular chain status evaluation and mastoid pneumatisation. Magnetic resonance imaging, on the other hand, is performed when intracranial complications are suspected.

The Potsic classification is specific for congenital cholesteatoma but, as opposed to the ChOLE classification, it does not allow a detailed description of cholesteatoma extent. According to the Potsic classification, stage I congenital cholesteatoma is limited to a single quadrant with no ossicular involvement or mastoid extension; stage II extends to multiple quadrants with no ossicular involvement or mastoid extension; stage III is characterised by ossicular involvement but no mastoid extension; and stage IV congenital cholesteatoma is characterised by mastoid extension<sup>5</sup>.

### Results

Six patients (three females and three males), aged 3–36 years old (mean 18.3 years old), were included in this study. All patients had unilateral cholesteatoma. Hence, a total of six ears were analysed. Pre-operative staging was consensual among the three observers in all cases. The mean time interval between imaging and surgery was 50.7 days (range 10–127 days).

Using the ChOLE classification, CT scan correctly staged cholesteatoma in three patients (50 per cent), while up-staging was observed in the remaining three. Fusion CT–MRI images allowed correct staging of cholesteatoma in all six patients (100 per cent). The three patients who were correctly staged with CT scan alone had stage Ch1a or Ch1b according to the ChOLE classification (Figure 1). Patients whose CT scans were not able correctly to estimate cholesteatoma extent were all staged as Ch3 on the pre-operative CT scan, while



**Figure 1.** Computed tomography (CT) scan (a) showing a Ch1a congenital cholesteatoma according to the ChOLE classification. Staging was confirmed with a fusion CT diffusion-weighted Magnetic resonance imaging scan (b).

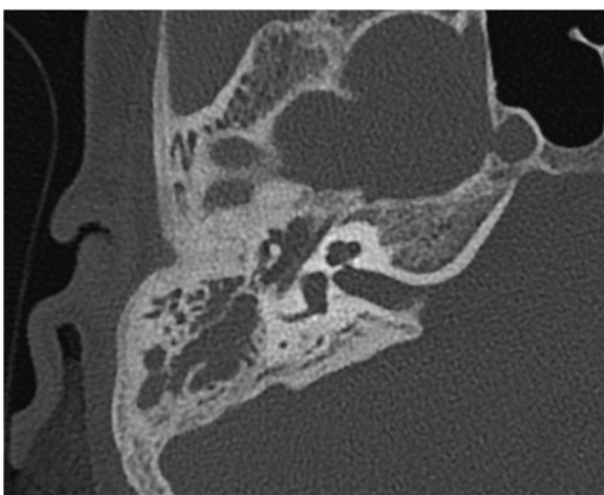
intra-operative staging was Ch2b, which indicates that there was no extension of the disease beyond the level of the lateral semi-circular canal.

However, using the Potsic classification, CT scan correctly predicted intra-operative stage in 100 per cent of the cases, while fusion CT-MRI images correctly predicted intra-operative stage in all patients except patient 3 (five of six cases; 83 per cent), where fusion scan failed to predict antrum involvement. The CT scan of patient 3 showed complete opacification of the middle ear and mastoid (Figure 2), suggesting mastoid involvement by cholesteatoma, and was therefore staged as Ch3-Potsic IV. On fusion imaging, however, high levels of water restriction were observed only at the level of the tympanic cavity, including the protympanum, up to the aditus, while non-significant diffusion values were seen in the antrum and mastoid, suggesting mucous retention (Figure 3). The CT-MRI stage was thus Ch2b-Potsic III. Intra-operatively, cholesteatoma reached the antrum but did not extend beyond the lateral semi-circular canal and was therefore classified as Ch2b-Potsic IV. Data are summarised in Table 1.

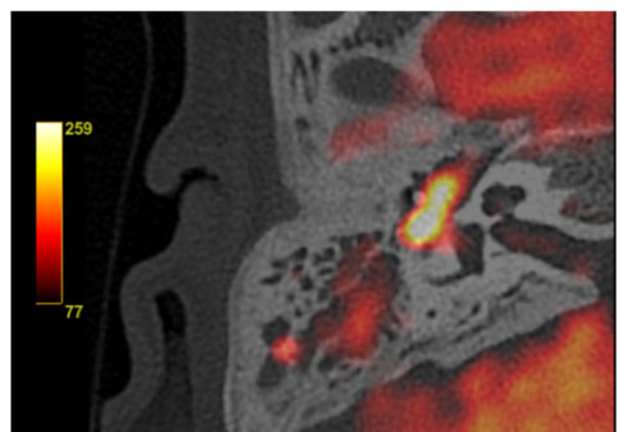
**Discussion**

Since the pivotal study by Maheshwari *et al.* in 2002, diffusion-weighted MRI has been used as a complementary imaging technique to CT scan in the management of cholesteatoma patients.<sup>6</sup> However, until recently it has been traditionally reserved for post-operative settings as a tool to identify recurrent and/or residual disease, especially when the tympanic membrane is intact and non-transparent. Some researchers have recently been exploring its potential usefulness in pre-operative patient evaluation with the aim of ameliorating surgical planning. In particular, combined CT and diffusion-weighted MRI images have been suggested to be superior to either imaging modality alone in showing precise primary cholesteatoma localisation. Pre-operative combined CT-MRI images have been described to have an accurate predictive value of 84–87 per cent in determining the extent of cholesteatoma.<sup>7–9</sup> We considered using the advantages of fusion CT-MRI images in patients with congenital cholesteatoma because, by definition, such patients have an intact tympanic membrane, which deprives the ear surgeon of important information on disease extent derived from otoscopic examination.

A few reports have questioned the ability of CT scan to precisely estimate cholesteatoma extent. For instance, in a study



**Figure 2.** Pre-operative Computed tomography (CT) scan of a patient with congenital cholesteatoma, showing opacification of the mastoid in continuity with the tympanic cavity. Pre-operative staging based on CT scan was therefore Ch3 according to the ChOLE classification, and was stage IV according to the Potsic classification.



**Figure 3.** Fusion Computed tomography (CT) diffusion-weighted MRI of patient 3 showing high diffusion values in the tympanic cavity up to the level of the aditus ad antrum, but not in the mastoid. Pre-operative staging according to fusion images was therefore Ch2b according to the ChOLE classification, and was stage III according to the Potsic classification.

**Table 1.** Summary of results

Patient ID	Gender	Age	CT stage		Fusion CT–MRI stage		Intra-operative stage	
			ChOLE	Potsic	ChOLE	Potsic	ChOLE	Potsic
1	F	12	Ch1b	III	Ch1b	III	Ch1b	III
2	M	3	Ch1a	I	Ch1a	I	Ch1a	I
3	F	13	Ch3	IV	Ch2b	III	Ch2b	IV
4	F	11	Ch3	IV	Ch2b	IV	Ch2b	IV
5	M	36	Ch1a	III	Ch1a	III	Ch1a	III
6	M	35	Ch3	IV	Ch2b	IV	Ch2b	IV

Ch = cholesteatoma extent according to the ChOLE4 classification; CT = computed tomography; MRI = magnetic resonance imaging; ChOLE = extension (Ch), status of the ossicular chain at the end of surgery (O), complications (L), and degree of pneumatization and ventilation (E) classification system

by Aoki, out of 24 patients with predicted mastoid involvement on CT scan, only six cases had intra-operative confirmation of mastoid extension of the disease.<sup>10</sup> CT scan specificity in determining primary paediatric cholesteatoma extent was calculated as 46 per cent in a study by Sharma *et al.* considering all subsites combined (64 per cent for aditus involvement and 67 per cent for mastoid involvement).<sup>7</sup> However, in the same study, an overall specificity of 97 per cent (100 per cent for aditus involvement and 92 per cent for mastoid involvement) for CT–MRI fusion images was observed.<sup>7</sup> Similarly, an accuracy of 62.5 per cent was described for CT scan alone in determining cholesteatoma extent in a retrospective series of 12 patients, including eight primary cholesteatoma cases.<sup>11</sup> Yamashita *et al.* observed an even lower accuracy rate (29.2 per cent) for CT scans in estimating cholesteatoma extent in their series, which also included eight primary cholesteatoma cases.<sup>9</sup> They also observed that the number of involved middle-ear subsites detected with CT scan was significantly higher than the number of subsites actually involved by the disease at intra-operative evaluation.<sup>9,11</sup>

In our small series, we observed that CT scan may overestimate congenital middle-ear cholesteatoma extent, in particular mastoid involvement beyond the level of the lateral semi-circular canal. Of the three patients with predicted mastoid involvement beyond the level of the lateral semi-circular canal on CT scan, according to the ChOLE classification Ch3 at pre-operative CT scan, no patients were found to have mastoid involvement beyond this level intra-operatively. On the other hand, by combining CT with diffusion-weighted MRI imaging we were able to correctly distinguish mastoid involvement beyond the lateral semi-circular canal by the disease from opacification due to inflammatory tissue, as confirmed by intra-operative findings.

- Unenhanced computed tomography (CT) is the gold standard for pre-operative staging of cholesteatoma, however it is unable to differentiate cholesteatoma from inflammatory tissue. On the other hand, magnetic resonance imaging (MRI) is currently confined to the post-operative setting to detect residual and/or recurrent disease
- The role of MRI, in combination with CT (fusion CT–diffusion-weighted MRI), in the pre-operative setting has been scarcely investigated
- A correct pre-operative staging of cholesteatoma extent is of the utmost importance in surgical planning, as it determines the choice between endoscopic versus microscopic approach
- In the authors' opinion, congenital middle-ear cholesteatoma may benefit from fusion images more than other forms of cholesteatoma since, being characterised by an intact tympanic membrane, little information about its extent can be gathered from otomicroscopy and/or otoendoscopy
- Analysing outcomes from a preliminary series of patients with congenital middle-ear cholesteatoma, we observed that fusion imaging may be especially helpful in patients whose pre-operative CT scan shows mastoid cell opacification, as in these cases CT overestimates cholesteatoma extent

- As a secondary endpoint of the study, we observed that the ChOLE classification may be preferable to the Potsic classification for pre-operative staging of congenital cholesteatoma

In contrast to the ChOLE classification, the Potsic classification does not distinguish antrum involvement up to the level of the lateral semi-circular canal from mastoid involvement beyond this level because both cases are classified as Potsic stage IV cholesteatomas. This distinction, however, is pivotal in pre-operative evaluation of congenital middle-ear cholesteatoma patients because it may influence surgical management. In fact, cholesteatomas that do not extend beyond the dome of the lateral semi-circular canal may be treated with an endoscopic transcanal approach, while mastoid extension beyond this level is a contraindication to this technique.<sup>12</sup> For instance, in one patient (patient 3) fusion scan underestimated cholesteatoma extent according to the Potsic classification: disease extended into the antrum, therefore was intraoperatively classified as Potsic IV, while fusion scan showed restriction of water diffusion only up to the level of the aditus, and was therefore classified pre-operatively as Potsic III. However, pre-operative ChOLE classification stage on fusion CT–MRI was confirmed intra-operatively (Ch2b), as there was no involvement of the mastoid beyond the lateral semi-circular canal. For this reason, the ChOLE classification should be preferred for evaluating cholesteatoma extent pre-operatively. Given these premises, we find that fusion CT–MRI images would be especially useful to evaluate cholesteatoma extent when pre-operative CT scan shows opacification of the antrum and mastoid.

Others have observed that the accuracy of CT scan in determining disease extent is significantly lower in patients without aeration around the cholesteatoma (0 per cent *vs* 88 per cent),<sup>13</sup> supporting our hypothesis. A review by James suggested a tympanic tube placement to drain an effusion prior to obtaining a CT scan as the effusion may obscure the limits of the cholesteatoma.<sup>14</sup>

Of course, bone erosion, which is typical of cholesteatoma and can be seen on CT scan, facilitates the diagnosis. For this reason, in our opinion, the mastoid antrum is the anatomical subsite where the differentiation between cholesteatoma and inflammatory tissue is most challenging. The mastoid antrum is almost always present and is already a large cavity, especially in cases of congenital cholesteatoma where ear ventilation is initially preserved, thus no middle-ear inflammation is present which may alter mastoid anatomy, therefore bone erosive activity typical of cholesteatoma is not clearly visible as in other subsites.

Our study has several limitations, the main ones being its retrospective nature and the small sample size. Further studies will be required to confirm our preliminary observations.

## Conclusions

This study reports preliminary results regarding the role of fusion CT–MRI scan in the pre-operative evaluation of primary congenital cholesteatoma. To our knowledge, this is the first study to evaluate the role of fusion CT–MRI scans in this specific setting. Based on our observations, CT scan tends to overestimate cholesteatoma extent beyond the level of the lateral semi-circular canal in cases where mastoid and antrum opacification is present. Therefore, if a pre-operative CT scan shows mastoid and antrum opacification, fusion of CT and diffusion-weighted MRI images may be indicated to obtain a correct pre-operative staging of congenital cholesteatoma extent, and consequently facilitate and improve surgical planning.

**Conflicts of interest and source of funding.** None

## References

- Maccarrone F, Molinari G, Alberici MP, Cesinaro AM, Villari D, Alicardi-Ciuffelli M *et al.* The tensor tympani tendon: a hypothetical site of origin of congenital cholesteatoma. *Head Neck Pathol* 2022;**16**:224–8
- Lou Z. Clinical findings of cholesteatoma behind an intact tympanic membrane in adults. *J Craniofac Surg* 2021;**32**:e332–4
- Balik AO, Seneldir L, Verim A, Zer Toros S. The role of fusion technique of computed tomography and non-echo-planar diffusion-weighted imaging in the evaluation of surgical cholesteatoma localization. *Medeni Med J* 2022;**37**:13–20
- Linder TE, Shah S, Martha AS, Rööslü C, Emmett SD. Introducing the “ChOLE” classification and its comparison to the EAONO/JOS consensus classification for cholesteatoma staging. *Otol Neurotol* 2019;**40**:63–72
- Kazahaya K, Potsic WP. Congenital cholesteatoma. *Curr Opin Otolaryngol Head Neck Surg* 2004;**12**:398–403
- Maheshwari S, Mukherji SK. Diffusion-weighted imaging for differentiating recurrent cholesteatoma from granulation tissue after mastoidectomy: case report. *AJNR Am J Neuroradiol* 2002;**23**:847–9
- Sharma SD, Hall A, Bartley AC, Bassett P, Singh A, Lingam RK. Surgical mapping of middle ear cholesteatoma with fusion of computed tomography and diffusion-weighted magnetic resonance images: diagnostic performance and interobserver agreement. *Int J Pediatr Otorhinolaryngol* 2020;**129**:109788
- Sun WH, Fan JK, Huang TC. The efficacy of DW and T1-W MRI combined with CT in the preoperative evaluation of cholesteatoma. *J Pers Med* 2022;**12**:1349
- Yamashita K, Hiwatashi A, Togao O, Kikuchi K, Matsumoto N, Obara M *et al.* High-resolution three-dimensional diffusion-weighted MRI/CT image data fusion for cholesteatoma surgical planning: a feasibility study. *Eur Arch Otorhinolaryngol* 2015;**272**:3821–4
- Aoki K. Advantages of endoscopically assisted surgery for attic cholesteatoma. *Diagn Ther Endosc* 2001;**7**:99–107
- Locketz GD, Li PMMC, Fischbein NJ, Holdsworth SJ, Blevins NH. Fusion of computed tomography and PROPELLER diffusion-weighted magnetic resonance imaging for the detection and localization of middle ear cholesteatoma. *JAMA Otolaryngol Head Neck Surg* 2016;**142**:947–53
- Chiao W, Chieffe D, Fina M. Endoscopic management of primary acquired cholesteatoma. *Otolaryngol Clin North Am* 2021;**54**:129–45
- Ide S, Ganaha A, Tono T, Goto T, Nagai N, Matsuda K *et al.* Value of DW-MRI in the preoperative evaluation of congenital cholesteatoma. *Int J Pediatr Otorhinolaryngol* 2019;**124**:34–8
- James AL. Endoscopic middle ear surgery in children. *Otolaryngol Clin North Am* 2013;**46**:233–44