

LETTER TO THE EDITOR**To THE EDITOR****Freezing of Gait after Hypoxic Pallidal Damage and Nigrostriatal Denervation**

Keywords: Basal ganglia, Positron emission tomography, Magnetic resonance imaging, Movement disorders

Freezing of gait (FOG) is a paroxysmal failure of locomotion occurring in specific phases of gait, such as initiation. FOG may develop as an isolated syndrome or a symptom of complex disorders such as Parkinson's disease (PD).

The globus pallidus (GP) has been implicated in various pathological mechanisms of FOG because secondary FOG arises from regional damage to the GP.^{1,2} Although gait problems including FOG after deep brain stimulation (DBS) of the subthalamic nucleus were more common and associated with certain stimulation frequencies, gait problems after DBS of the internal GP (GPi) were associated with stimulation of anatomical subregions of the GPi.³⁻⁵

Herein, we report two patients with delayed FOG after hypoxic GP damage.

The first case is a 48-year-old man who visited our clinic due to gait disturbance. He lost consciousness because of asphyxia during a fire at age 28. His gait disturbance began insidiously at age 46. Gait initiation was poor with frequent falls. Neurological examination showed normal cognition (Mini-Mental Status Examination, MMSE = 28/30), mild bradykinesia in both limbs, and FOG (Supplemental video 1).

Brain magnetic resonance imaging (MRI) showed no lesions in the substantia nigra and bilateral symmetrical cystic necrosis of GPi and part of the external GP (GPe, Figure 1A and 1B). Single-photon emission computed tomography (SPECT) using ¹²³I-N-omega-fluoropropyl-2beta-carbomethoxy-3beta-(4-iodophenyl) tropine (¹²³I-FP-CIT) showed asymmetric low ¹²³I-FP-CIT uptake in the bilateral striata (Figure 1C). Medications, including levodopa, were ineffective.

The second case is a 77-year-old woman who visited the outpatient clinic due to gait disturbance. She had a history of carbon monoxide poisoning at age 52. Her gait problems had

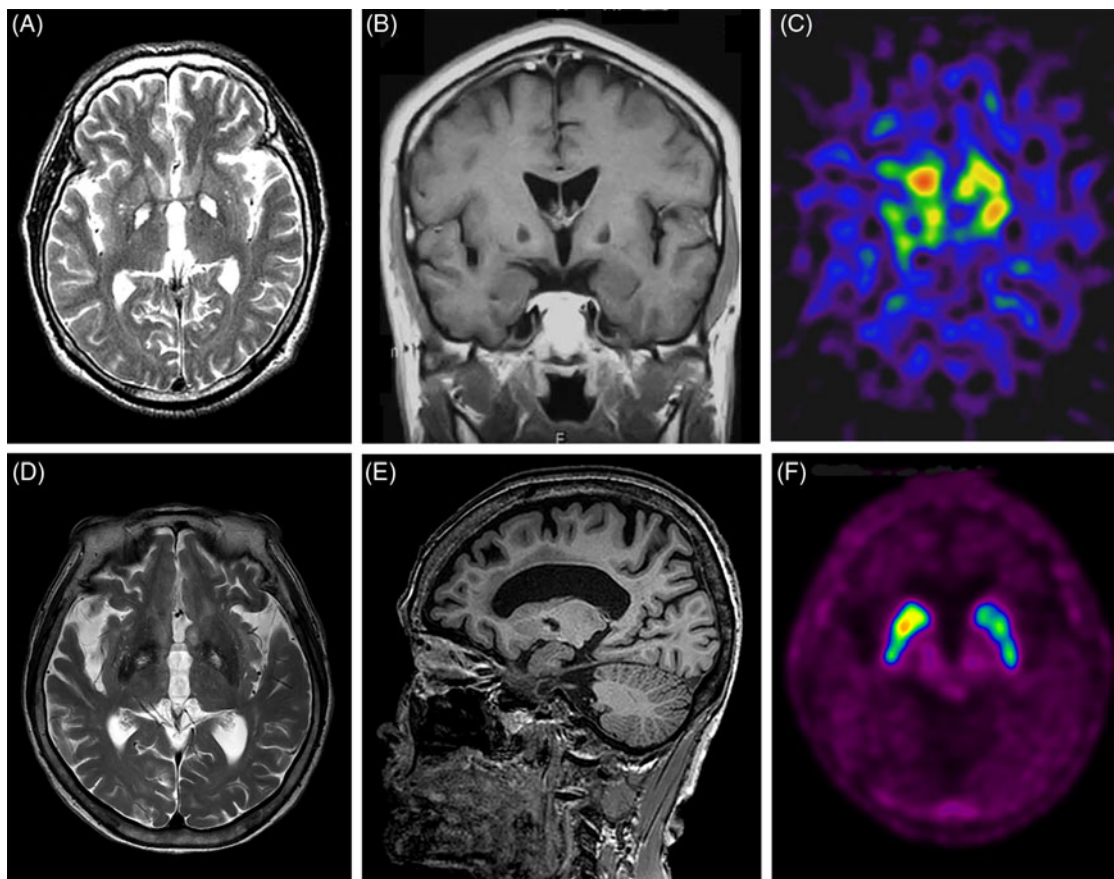


Figure 1: Brain MRI and dopamine transporter imaging of case 1 (A–C) and case 2 (D–F). Brain MRI shows cystic necrosis of the GPi and GPe in both patients. Dopamine transporter imaging (¹²³I-FP-CIT SPECT in case 1 and 18 F-FP-CIT PET in case 2) shows decreased FP-CIT uptake in the bilateral striata, which is more severe on the left side in case 1 and on the right side in case 2. (A) Case 1 T2. (B) Case 1 T1. (C) Case 1 FP-CIT SPECT. (D) Case 2 T2. (E) Case 2 T1. (F) Case 2 FP-CIT PET

started at age 70. She had been treated with levodopa, which increased her gait problems. Neurologic examination showed cognitive impairment (MMSE = 10/28), mild bradykinesia, postural instability, and FOG (Supplemental video 2).

Brain MRI showed mild changes in the periventricular white matter and bilateral cystic changes affecting the GPi and GPe (minor, Figure 1D and 1E). Positron emission tomography using ^{18}F -FP-CIT showed asymmetric decreased ^{18}F -FP-CIT uptake in the bilateral striata (Figure 1F).

Her FOG improved after discontinuing levodopa treatment. Additional medications (methylphenidate 20 mg/day and bupropion 150 mg/day) were partially effective.

The patients provided informed consent for publication of the report and supplemental videos.

The GP cysts in our patients were related to history of hypoxic damage and remained asymptomatic for 18 years. Striatal dopamine deficiency (SDD), revealed using dopamine transporter (DaT) imaging, may combine with GP damage to produce FOG.

The role of the GP in FOG was emphasized in patients with dystonia.⁴ Since FOG is not expected in dystonia, and SDD is not a feature of dystonia, FOG after GP DBS for dystonia indicates that GP dysfunction alone may be sufficient to cause FOG. However, a dystonic patient with GP DBS developed ensuing FOG that was ameliorated by levodopa, indicating that dopaminergic dysfunction contributes to FOG after DBS, although SDD was not evaluated.⁴ Later studies demonstrated functional division of the GP, explaining how the GP DBS can have dual effects on gait; DBS of the dorsal portion of the GPi (d-GPi) can relieve parkinsonian symptoms including gait symptoms, while DBS of the ventral portion of the GPi (v-GPi) can aggravate gait disturbance, resulting in symptoms including FOG.⁴ Thus, GP lesions secondary to hypoxic injury may contribute to development of FOG, although an 18-year gap raises a question regarding a self-sufficient role of GP in FOG.

In the majority of GP lesions with secondary FOG, DaT imaging is not performed, resulting in lack of information on SDD. In a recent study, FOG was a complication of venous congestion in the GP caused by an arteriovenous fistula (AVF), and SDD was confirmed using DaT imaging.⁶ FOG was ameliorated after resolution of GP congestion by AVF embolization. Furthermore, DBS of d-GPi was effective in a few PD patients with FOG.⁷ These studies demonstrated the roles of GP and SDD in FOG. In the two patients reported in our study, the GP lesions crossed the boundary between the d-GPi and v-GPi and remained asymptomatic for many years; FOG eventually developed with emergence of SDD. Thus, both GP dysfunction and SDD are important in development of FOG.

The cause of SDD remains speculative. Concomitant presynaptic involvement from onset of carbon monoxide poisoning has been described but is not applicable to delayed FOG.⁸ Retrograde degeneration of the putamen secondary to GP damage is possible but has been only observed in animal experiments.⁹ Because SDD was asymmetric, and pallidal lesions were fairly symmetric, an additional disease process causing SDD can be assumed. Neurodegenerative disorders affecting the pre- and/or postsynaptic nigrostriatal pathways, such as progressive supranuclear palsy, could be the cause based on poor levodopa responsiveness, progressive clinical evolution, and additional neurologic features such as cognitive decline.¹⁰ Although pathologic confirmation is

needed to determine the cause of SDD, it is difficult to exclude the contribution of preexisting GP necrosis to later pathologic processes, resulting in FOG.


In summary, a protracted clinical course over 18 years consisting of pallidal damage (the first “hit”) and a second “hit” of SDD likely resulted in FOG. Since previous cases also involved two “hits” similar to our cases, essential features of the cases could be formulated into a hypothesis that a dual “hit” is necessary for development of FOG related to GP. Although the pathologic cause of SDD requires further study, this unusual combination is informative regarding the pathogenesis of FOG and warrants further investigation.

DISCLOSURES

The authors have no conflicts of interest to declare.

SUPPLEMENTARY MATERIAL

To view supplementary material for this article, please visit <https://doi.org/10.1017/cjn.2020.16>.

Chaewon Shin 

Department of Neurology, Chungnam National University
College of Medicine, Chungnam National University Hospital,
Daejeon, South Korea

Tae-Beom Ahn

Department of Neurology, Kyung Hee University College of
Medicine, Seoul, South Korea

Sang-Eun Kim

Department of Nuclear Medicine, Seoul National University
College of Medicine, Seoul, South Korea

Correspondence to: Tae-Beom Ahn, MD, PhD, Department of Neurology, Kyung Hee University Hospital, 23 Kyungheedaero, Dongdaemun-gu, Seoul 02447, South Korea. Email: taeboom.ahn@khu.ac.kr

REFERENCES

- Shahar T, Gadoth A, Nossek E, Giladi N, Ram Z, Maimon S. Reversible freezing of gait caused by dural arteriovenous fistula and congestion of the globus pallidus. *Mov Disord.* 2012;27(13):1690–3.
- Kim JS, Lee KJ, Guak TH, Kim BS, Yang DW. Gait ignition failure after unilateral anteromedial pallidotomy. *Eur Neurol.* 2001;46(1):56–7.
- Wolf ME, Capelle HH, Bänzner H, Hennerici MG, Krauss JK, Blahak C. Hypokinetic gait changes induced by bilateral pallidal deep brain stimulation for segmental dystonia. *Gait & Posture.* 2016;49:358–63.
- Baizabal-Carvallo JF, Jankovic J. Movement disorders induced by deep brain stimulation. *Parkinsonism Relat Disord.* 2016;25:1–9.
- Collomb-Clerc A, Welter ML. Effects of deep brain stimulation on balance and gait in patients with Parkinson’s disease: A systematic neurophysiological review. *Neurophysiol Clin/Clinical Neurophysiology.* 2015;45(4–5):371–88.

6. Shahar T, Gadoth A, Nossek E, Giladi N, Ram Z, Maimon S. Reversible freezing of gait caused by dural arteriovenous fistula and congestion of the globus pallidus. *Mov Disord.* 2012;27(13):1690–3.
7. Katayama Y, Kasai M, Oshima H, Fukaya C, Yamamoto T. Effects of anterodorsal pallidal stimulation on gait freezing (Kinesia paradoxa) in Parkinson's disease. *Stereotact Funct Neurosurg.* 2000;74(3–4):99–105.
8. Rissanen E, Paavilainen T, Virta J, Marttila RJ, Rinne JO, Airas L. Carbon monoxide poisoning-induced nigrostriatal dopaminergic dysfunction detected using positron emission tomography (PET). *Neurotoxicology.* 2010;31(4):403–7.
9. Chung YW, Hassler R. Anterograde and retrograde degenerative reactions in caudate nucleus and putamen after experimental lesion of the pallidum in squirrel monkey (*Saimiri sciureus*). *Acta anatomica.* 1982;113(3):246–63.
10. Fasano A, Baldari S, Di Giuda D, et al. Nigro-striatal involvement in primary progressive freezing gait: insights into a heterogeneous pathogenesis. *Parkinsonism Relat Disord.* 2012;18(5):578–84.