

Orthostatic Symptoms of Transient Ischemic Attack – Revised

Ariel Hendin, MD*; Lisa M Fischer, MD, FRCPC*; Jeffrey J Perry, MD, MSc, CCFP-EM*

ABSTRACT

Transient ischemic attacks (TIA) are a common presentation to the emergency department (ED) and are associated with an estimated 9% risk of stroke within 90 days.¹ We report the case of a 72-year-old female who presented with orthostatic symptoms of facial weakness and dysarthria; that is, the patient's symptoms were present when she was standing and resolved when supine. Neurological deficits present only when standing should alert the clinician to the importance of advanced neuroimaging to evaluate for acute arterial occlusion.

RÉSUMÉ

Les accidents ischémiques transitoires sont des troubles fréquents au service des urgences et ils sont associés à un risque estimé d'accident vasculaire cérébral de 9 % dans les 90 jours suivants.¹ Sera décrit ici le cas d'une femme de 72 ans qui présentait des symptômes orthostatiques sous forme de faiblesse faciale et de dysarthrie; plus précisément, la patiente avait des symptômes en position debout mais pas en position couchée. La présence de déficits neurologiques en position debout seulement devrait éveiller les cliniciens à l'importance de la neuro-imagerie évoluée afin que soit évalué le risque d'une oblitération artérielle aiguë.

Keywords: TIA, Stroke, Atrial fibrillation

CASE DESCRIPTION

A 72-year-old right-hand dominant female was seen in an urban, academic tertiary care emergency department (ED). Emergency Medical Services had been activated by her coworker, who noted onset of symptoms of left-sided facial droop and dysarthria at 6:15 AM when the patient walked into work. Upon her arrival to the ED at 7:05 AM, the patient's symptoms were resolving.

She had no prior history of the same symptoms, and her only pre-existing conditions were pulmonary sarcoidosis and depression. She was not on any medications, was an ex-smoker and reported consuming four alcoholic drinks per day. Her vital signs at triage were as follows: blood pressure 103/85 mm Hg, heart rate 120 beats per minute, respiratory rate 14 breaths per minute, oxygen saturation 97% on room air, temperature 36.3°C, and glucose 5.7 mmol/L.

On initial physician examination, she was found to be in rapid atrial fibrillation at 130 beats per minute and her repeat blood pressure was 152/127 mm Hg. She had no murmurs or carotid bruits on cardiorespiratory examination, but she did have a rapid and irregularly irregular pulse. Careful neurological examination demonstrated a normal level of consciousness and the patient was alert and oriented. Cranial nerves II–XII were normal, including no evidence of the facial droop reported at triage. She had full motor, sensory, and cerebellar function, and both reflexes and gait were grossly normal. She received 20 mg of diltiazem intravenously for rate control of her atrial fibrillation, as per Advanced Cardiovascular Life Support (ACLS) guidelines.² Following the diltiazem, her heart rate decreased to 80 beats per minute and blood pressure was 184/109 mm Hg. Initial laboratory investigations were normal, with the exception of a troponin I level of 0.151 (reference range <0.045 mcg/L). An unenhanced CT as well as a CT angiogram of the head and neck demonstrated no area of ischemic infarct; however, the neuroradiologist reported a hyperdense right middle cerebral artery with a cutoff at the proximal M1 segment and some collateral compromise (Figure 1A). This was felt to be in keeping with an acute clot without evidence of brain ischemia at the time of imaging.

From the Department of Emergency Medicine, Ottawa Hospital Research Institute (JJP), University of Ottawa, Ottawa, ON.

Correspondence to: Ariel Hendin, 1053 Carling Avenue, E-Main, Room EM-206, Box 227, Ottawa, ON K1Y 4E9; Email: ahendin@toh.on.ca

© Canadian Association of Emergency Physicians

CJEM 2017;19(2):163-165

DOI 10.1017/cem.2016.353

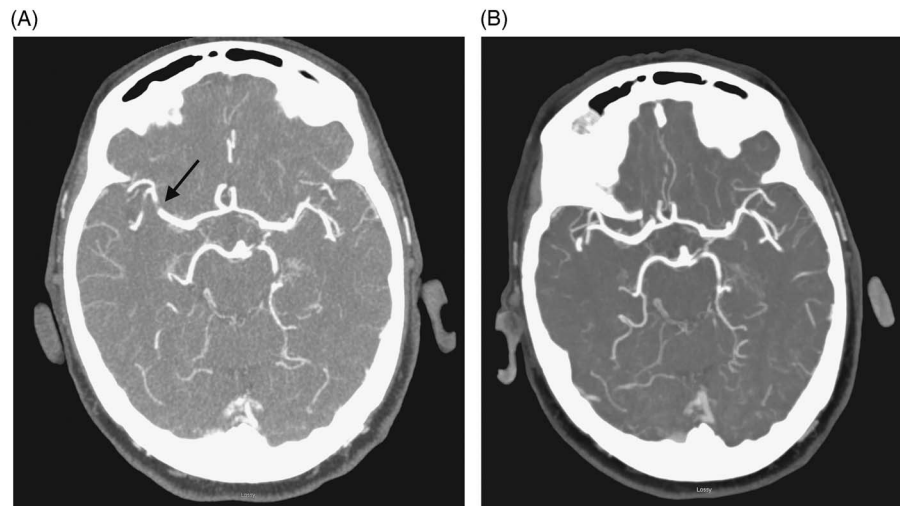


Figure 1. (A) CT angiogram demonstrating hyperdense MCA with acute clot visualized at M1. (B) Repeat CTA 24 hours following initiation of heparin demonstrates resolution of M1 clot.

The Neurology Service was consulted for further evaluation based on the radiological findings combined with the patient's moderate stroke risk, as quantified by an ABCD2 score of 5 points.³ Upon neurology initial assessment, the patient's neurological examination was found to be in keeping with her initially described examination, apart from very mild flattening of the left nasolabial fold. The patient had been resting on a stretcher for most of her ED visit. She walked over for a chest x-ray and upon her return developed acute left-sided face and arm weakness as well as dysarthria. These symptoms resolved within minutes of lying supine. Unfortunately, repeat vitals were not performed at this time. Based on these symptoms of orthostatic transient neurological deficits as well as imaging demonstrating an acute arterial clot, the patient was admitted to hospital under the Neurology Service for further observation and treatment. She was started on intravenous heparin, given a 1L bolus of crystalloid, and kept on strict bed rest. A deliberate decision was made to withhold anti-hypertensives during the first 24 hours of her hospital admission, despite her hypertension, in an effort to theoretically maintain perfusion to her collateral circulation. The patient's systolic blood pressure ranged from 135-193 mm Hg over this time. A repeat head CT performed the day after admission demonstrated resolution of the right middle cerebral artery clot (Figure 1B), at which point the heparin was discontinued and apixaban was started. An echocardiogram ruled out the presence of intra-cardiac thrombus and the patient was started on a daily oral dose of

metoprolol for rate control. The patient was discharged from hospital without any neurological deficits three days post admission.

DISCUSSION

This case of a 72-year-old female patient who had symptoms of TIA only upon standing reinforces several aspects of TIA and stroke care. There are only a few reported cases of TIAs precipitated by standing, and in the majority of these cases, the cause of patient symptoms was a major vessel occlusion or critical stenosis (i.e., internal carotid, basilar, or vertebral arteries). A reasonable explanation for this phenomenon is that with large vessel occlusion and marginal collateral blood supply, collateral vessels that are maximally dilated when the patient is supine cannot maintain adequate perfusion to the ischemic segment when the patient stands and the blood pressure decreases.⁴⁻⁶ Our patient became symptomatic upon prolonged standing and was without symptoms when supine; her presentation was due to an acute clot in the right middle cerebral artery (MCA) in combination with collateral circulation which was mildly compromised and perfusion-dependent. Her acute MCA clot was thought to be embolic in nature; she had a CHADS2 score of 3 and was discharged on apixaban; as per the current Canadian Cardiovascular Society guidelines that recommend an oral anticoagulant for patients with atrial fibrillation who are 65 years of age or older.⁷

Orthostatic vital signs were not performed on our patient because of her TIA symptoms when standing. One case report details a patient with neurologic deficits due to orthostatic hypotension that resolved only with aggressive volume resuscitation,⁸ but few of the patients in the other reported cases had postural changes in their blood pressure. Both the Canadian and American stroke societies recommend avoiding blood pressure-lowering agents in most cases of acute ischemic stroke, although long-term blood pressure management is recommended with TIA for stroke prevention.^{9,10}

Even before brain imaging demonstrated acute pathology, our patient was at moderate risk, based on a score of 5 points based on the ABCD2 scoring system, and at higher risk for impending stroke based on the factors outlined in the Canadian TIA Score.¹¹ Imaging that demonstrated acute ischemia confirmed that she was at elevated risk of stroke following her symptoms of TIA.¹² This case highlights the value of vascular imaging of the brain and neck arteries within 24 hours of TIA presentation, which should be based on clinical risk factors,¹³ and in our patient's case highlights the value of such evaluations.

In conclusion, while the vast majority of TIAs in Canada are safely managed with expedited outpatient referral to a stroke specialist, the emergency physician must carefully consider each patient's risk factor profile and clinical presentation and select appropriate investigations to be performed during the initial visit. This case sheds light on an underreported entity in the emergency medicine literature, that of orthostatic TIA symptoms. It is our opinion that patients with orthostatic TIA symptoms should be assessed by neurology services and likely admitted to hospital for further monitoring.

Acknowledgements: The authors would like to acknowledge Dr. Santanu Chakraborty from the Department of Radiology at the University of Ottawa for his assistance in reviewing imaging for this report.

REFERENCES

1. Perry JJ, Kerr J, Symington C, et al. How do we manage emergency department patients diagnosed with transient ischemic attack? *CJEM* 2012;14(1):20-4.
2. Neumar RW, Otto CW, Link MS, et al. 2010. American Heart Association Guidelines for Cardiopulmonary Resuscitation and Emergency Cardiovascular Care. *Circulation* 2010;122(18 Suppl 3):S729-67.
3. Johnston SC, Rothwell PM, Nguyen-Huynh MN, et al. Validation and refinement of scores to predict very early stroke risk after transient ischemic attack. *Lancet* 2007;369(9558):283-92.
4. Somerville ER. Orthostatic transient ischemic attacks: a symptom of large vessel occlusion. *Stroke* 1984;15(6):1066-7.
5. Aladdin Y, Hussain MS, Saqqur M. Real-time hemodynamic assessment of intracranial stenosis in a patient with orthostatic aphasia: potential applications of transcranial Doppler. *J Neuroimaging* 2009;19(1):86-8.
6. Saqqur M, Sharma VK, Tsivgoulis G, et al. Real-time hemodynamic assessment of downstream effects of intracranial stenoses in patients with orthostatic hypoperfusion syndrome. *Cerebrovasc Disease* 2010;30(4):355-61.
7. Verma A, Cairns J, Mitchell LB, et al. 2014 focused update of the Canadian Cardiovascular Society guidelines for the management of atrial fibrillation. *Can J Card* 2014;30(10):1114-30.
8. Pascual-Leone A, Anderson DC, Larson DA. Volume therapy in orthostatic transient ischemic attacks. *Stroke* 1989;20(9):1267-70.
9. Adams HP, Adams RJ, Brott T, et al. Guidelines for the early management of patients with ischemic stroke: a scientific statement from the stroke council of the American Stroke Association. *Stroke* 2003;34(4):1056-83.
10. Coutts SB, Wein TH, Lindsay MP, et al. Canadian Stroke Best Practice Recommendations: secondary prevention of stroke guidelines, Update 2014. *Int J Stroke* 2015;10(3):282-91.
11. Perry JJ, Sharma MS, Sivilotti MLA, et al. A prospective cohort study of patients with transient ischemic attack to identify high-risk clinical characteristics. *Stroke* 2014;45(1):92-100.
12. Wasserman JK, Perry JJ, Sivilotti ML, et al. Computed tomography identifies patients at high risk for stroke after transient ischemic attack/nondisabling stroke: prospective, multicenter cohort study. *Stroke* 2014;45(1):114-9.
13. Heart and Stroke Foundation of Canada. Canadian Stroke Best Practice Recommendations: Emergency Department Evaluation and Management; 2013. Available at: <http://www.strokebestpractices.ca/index.php/hyperacute-stroke-management/emergency-department-evaluation-and-management/> (accessed March 6, 2015).