

PROGRESS IN CLINICAL NEUROSCIENCES: Advances in the Management of Low-Grade Gliomas

Warren P. Mason

ABSTRACT: The management of low-grade gliomas represents one of the most challenging and controversial areas in neuro-oncology. Many aspects of the treatment of low-grade gliomas are debated, including the optimal timing of surgery and radiotherapy, the benefit of extensive surgery, and the impact of these variables on the natural history of these indolent and generally incurable tumours. The recently published results of several large multicentre trials addressing the timing and dose of radiotherapy have provided solid evidence for delayed and reduced dose irradiation. These studies have also confirmed prognostic variables that can be used to guide management of individual patients. Among these variables is the observation that tumours with oligodendroglial features have a better natural history and response profile. The recognition that as many as two thirds of low-grade gliomas have oligodendroglial features, advances in molecular diagnostics making accurate pathologic diagnosis of oligodendroglial tumours possible, and the established chemosensitivity of malignant oligodendrogliomas, have raised new issues surrounding the potential value of chemotherapy for low-grade gliomas. This review will be restricted to low-grade diffuse astrocytomas, oligodendrogliomas, and low-grade mixed oligoastrocytomas in adults, and provide evidence-based guidelines for the management of these tumours, including the emerging role of chemotherapy as initial treatment.

RÉSUMÉ: Progrès dans le traitement des gliomes à faible degré de malignité. Le traitement des gliomes à faible malignité demeure un des domaines les plus controversés en neuro-oncologie. Plusieurs aspects de leur traitement, soit le meilleur moment pour la chirurgie et la radiothérapie, les bénéfices d'une chirurgie extensive et l'impact de ces variables sur l'histoire naturelle de ces tumeurs indolentes et généralement incurables, font l'objet de controverses. Les résultats de plusieurs grandes études multicentriques publiées récemment sur le moment de l'administration et la dose de radiothérapie ont fourni des données solides favorisant une irradiation tardive, à faible dose. Ces études ont également confirmé que certaines variables sont utiles pour établir un pronostic et peuvent être utilisées pour guider la prise en charge individuelle des patients. Il est bien établi que les tumeurs qui ont des caractéristiques oligodendrogliales ont une histoire naturelle plus favorable et une meilleure réponse au traitement. On sait maintenant que les deux-tiers des gliomes à faible malignité ont des caractéristiques oligodendrogliales. Les progrès effectués dans le diagnostic moléculaire, qui rendent possible un diagnostic anatomopathologique précis dans les cas de tumeurs oligodendrogliales, et la chimiosensibilité des oligodendrogliomes malins ont suscité des discussions sur la valeur potentielle de la chimiothérapie dans les gliomes à faible malignité. Cette revue se limite aux astrocytomes diffus à faible malignité, aux oligodendrogliomes et aux oligoastrocytomes mixtes à faible malignité chez les adultes et fournit des lignes directrices basées sur des données probantes pour le traitement de ces tumeurs, particulièrement quant au rôle émergeant de la chimiothérapie comme traitement initial.

Can. J. Neurol. Sci. 2005; 32: 18-26

Low-grade gliomas represent approximately 11% of the primary central nervous system (CNS) tumours diagnosed each year in the United States and Canada.¹ Although these neoplasms are classified pathologically as low-grade, they are not benign, and are capable of malignant dedifferentiation. As a consequence, they produce significant morbidity and ultimately high mortality for most afflicted patients, who have median

From the Department of Medical Oncology & Hematology, Princess Margaret Hospital, Toronto, Ontario, Canada.

RECEIVED DECEMBER 16, 2002. ACCEPTED IN FINAL FORM JULY 27, 2004.
Reprint requests to: Warren P. Mason, Department of Medical Oncology & Hematology, Princess Margaret Hospital, 610 University Avenue, Suite 18-717, Toronto, Ontario, M5G 2M9 Canada.

survivals in the range of five to seven years.² The optimal management of patients with low-grade gliomas has been controversial, with some physicians recommending early and extensive surgery followed by radiotherapy, and others advocating a conservative approach where treatment is postponed until patients become symptomatic or have radiographic tumour progression.³ Patients with low-grade gliomas are clinically more heterogeneous than those with malignant gliomas, and many patients can have event-free survivals lasting a decade or more. Moreover, the widespread availability of magnetic resonance imaging has produced a trend towards earlier diagnosis for many patients who have few symptoms and normal neurologic examinations, and do not appear to require immediate intervention. Consequently, the toxicities of radiotherapy and chemotherapy, and the potential morbidity of surgery are very real concerns for this patient population whose anticipated survival is measured in years. Thus, for physicians caring for patients with low-grade gliomas, the challenge lies between providing too much therapy too early, or too little too late.

EPIDEMIOLOGY

Low-grade gliomas cluster in younger age groups. Low-grade fibrillary and protoplasmic astrocytomas, oligoastrocytomas and oligodendrogliomas are similar in their epidemiologic features, presenting in patients whose median age at the time of diagnosis is approximately 35 years.⁴⁻⁹ Males appear at increased risk for this disease, reportedly constituting 55 to 65% of all patients with low-grade glial tumours.^{5,6}

Low-grade fibrillary astrocytomas tend to arise in the cerebral hemispheres of young adults, and within the brainstem of young children. Rarely they can arise in the spinal cord or cerebellum. When arising within the cerebral hemispheres, low-grade gliomas are distributed in a manner relative to proportions of the cerebral mass, and are consequently most likely to develop within the frontal and temporal lobes.¹⁰

CLASSIFICATION

Glial neoplasms can be indolent (pilocytic astrocytoma) or highly aggressive (glioblastoma multiforme). A variety of grading systems, all based on classic morphologic criteria, are used to segregate gliomas into discrete groups with distinct prognoses and treatment recommendations. The most common classification systems currently in use by neuropathologists are the World Health Organization and the St. Anne-Mayo systems.^{11,12} Low-grade gliomas recognized by these systems are listed in the Table.

The most common of the astrocytic low-grade gliomas is the fibrillary astrocytoma, a well-differentiated infiltrative neoplasm of fibrillary astrocytes.¹³ Microscopically, these tumours are characterized by mild to moderate nuclear pleomorphism, but features of aggressive behaviour, such as mitotic activity, vascular hyperplasia, and necrosis are absent. The gemistocytic variant of diffuse fibrillary astrocytoma is notable for the presence of abundant plump gemistocytes, resembling reactive astrocytes, scattered diffusely through the tumour. Gemistocytic features have traditionally been considered a histopathologic marker for aggressive tumour biology, but recent reports have documented survival figures and prognostic determinants similar to fibrillary astrocytomas in general.¹⁴ Protoplasmic astrocytomas are uncommon, and usually present as cortically based cystic masses.¹³

Oligodendrogliomas have a characteristic “fried-egg” histologic appearance most evident in paraffin sections. The perinuclear halo that gives rise to this characteristic appearance is an artefact of slow tissue fixation, and is usually absent in frozen sections.¹³ There are several validated grading systems for oligodendrogliomas in use. The most common and simple system is one where anaplastic features (high cellularity, nuclear pleomorphism, frequent mitoses, endothelial proliferation and necrosis) distinguish the malignant anaplastic oligodendroglioma from an oligodendroglioma. Mixed oligoastrocytomas contain histologically distinct but clonal populations of neoplastic astrocytes and oligodendrocytes.¹⁵ The diagnosis of a mixed glioma requires a substantial astrocytic component, because many oligodendrogliomas contain isolated or reactive non-neoplastic astrocytic cells.¹³ The diagnosis of an oligodendroglial tumour histologically is difficult because there are no specific immunohistochemical markers that identify these tumours.

Recent advances in the molecular classification of brain tumours have identified genetically distinct subsets of glioma. The most common chromosomal abnormality seen in low-grade astrocytoma is the deletion of chromosome band 17p13.1 and mutations of the tumour suppressor gene p53 (TP53), which is found in this region.¹⁶⁻¹⁹ Approximately 65% of low-grade astrocytomas harbour p53 mutations.¹⁹ Moreover, advances in our understanding of the molecular biology of oligodendrogliomas have identified allelic loss of chromosomes 1p and 19q as early events in the formation of these tumours.²⁰ Recent studies have demonstrated that as many as 80% of low-grade oligodendroglial tumours and 15% of low-grade astrocytomas also have allelic loss of chromosomes 1p and 19q.^{21,22} Furthermore, this observation has the potential to change the management of these neoplasms because preliminary evidence

Table: World Health Organization classification of low-grade gliomas

Astrocytic gliomas
Astrocytoma
-fibrillary
-protoplasmic
-gemistocytic
Pilocytic astrocytoma
Pleomorphic xanthoastrocytoma
Subependymal giant-cell astrocytoma
Subependymoma
Mixed glioma (oligoastrocytomas)
Oligodendroglioma

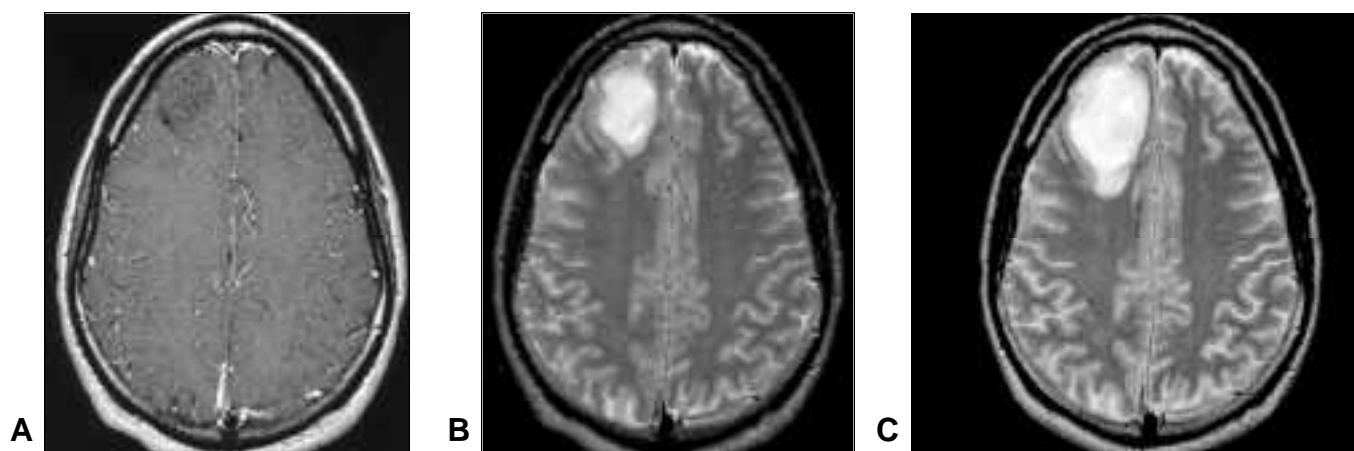


Figure 1: Low-grade oligodendroglioma. Twenty-eight-year-old man presenting with generalized seizures. MRI showed well-demarcated right frontal lobe mass with low-signal intensity and no enhancement with gadolinium-DTPA contrast on T1-weighted scan (A), and high signal intensity and little surrounding edema on T2-weighted scan (B). These radiographic features are characteristic for a low-grade glioma. Following radiographic progression (C), he underwent gross total resection of tumour. Radiotherapy and chemotherapy have been deferred without tumour progression over a follow-up period of over three years.

suggests that 1p and 19q loss of heterozygosity in low-grade gliomas is also a marker of response to chemotherapy and radiotherapy, and improved outcome.²³ Consequently, following resection or biopsy, all low-grade tumours should have their molecular genetic profile determined for the identification of “susceptibility gene mutations” that may define a cohort of patients that benefit from specific therapies.

CLINICAL PRESENTATION

Intrinsic tumours of the CNS produce symptoms and signs on the basis of two mechanisms: 1) increased intracranial pressure due to the expanding lesion, or to obstruction of cerebrospinal fluid flow; and, 2) infiltration and compression of adjacent neural structures. Increased intracranial pressure accounts for symptoms such as headache, nausea and vomiting, confusion, and personality changes. Focal neurologic deficits can be episodic such as seizures, or progressive, such as weakness, sensory changes, ataxia and aphasia.

The most common presenting symptom is seizures, which are reported by 50% to 90% of all patients with low-grade gliomas before diagnosis.^{9,10,24,25} The advent of readily available CT and MR imaging has shortened the duration and reduced the severity of symptoms in patients with low-grade gliomas. Leighton et al²⁶ reported presenting symptoms in 167 adults with supratentorial low-grade gliomas (89 astrocytoma, 78 oligodendroglioma/mixed glioma) diagnosed between 1979 and 1995. In this series, 78% had seizures at presentation, 31% focal neurologic deficits, 29% headache, 11% cognitive or behavioural change, and 9% papilloedema. The median interval duration between symptom onset and first imaging was two months. The ready availability of imaging has also extended the apparent natural history of this disease. For example, in 1984, Laws et al¹⁰ reported a median survival of four years in an historical study. In contrast, more recent studies conducted by Vertosick et al,²⁴ and McCormack et al⁹ reported median survivals of 8.2 years and 7.2 years, respectively. These discrepancies likely represent a lead-time

bias made possible by modern imaging techniques, and not improvement in the outcome of this disease by therapeutic intervention.

RADIOLOGIC FEATURES

Low-grade gliomas have characteristic radiographic features that make possible the presurgical diagnosis of these neoplasms with great accuracy.²⁷ However, the considerable variation in the radiographic appearance of low-grade gliomas, in part due to differing histology, makes pathologic confirmation of all suspicious lesions mandatory before treatment is administered.

Low-grade fibrillary astrocytomas usually present as ill-defined, nonenhancing, and hypodense lesions on CT scans. Magnetic resonance scans are more sensitive at detecting small tumours, and may disclose a lesion when a CT scan is apparently normal.²⁸ Low-grade gliomas usually appear as discrete areas of hypo- or isointensity on unenhanced T1-weighted images, and usually more circumscribed hyperintense lesions on T2-weighted images (Figure 1).^{29,30} Contrast enhancement is usually absent, but when present, does not reliably denote a more malignant neoplasm.^{30,31} Tumours that enhance on CTscans also enhance on MR images, as tumour enhancement represents disruption of the blood-brain barrier. Imaging features alone cannot predict the grade of a presumed glial neoplasm.³² For instance, as many as 50% of nonenhancing tumours on CT scans will prove to be anaplastic rather than low-grade gliomas at the time of pathologic grading.³³ For definitive diagnosis before therapy, biopsy must be performed to establish an accurate diagnosis.³⁴

Positron emission tomography (PET) can be helpful in the evaluation of patients with low-grade gliomas prior to biopsy.^{35,36} Most low-grade gliomas appear hypometabolic on [¹⁸F]fluorodeoxyglucose PET images. The appearance of a hypermetabolic region within an otherwise hypometabolic tumour can signify the malignant transformation of a low-grade astrocytoma, even in the absence of change or enlargement on CT or MR scans.³⁷ Moreover, a fluorodeoxyglucose PET scan can, by

identifying hypermetabolic regions within a low-grade tumour, select regions within a tumour that can be biopsied stereotactically, thereby leading to an accurate histologic grading of the neoplasm.

Magnetic resonance spectroscopy is an emerging technique that may help distinguish astrocytomas from other brain lesions, and play a role in the noninvasive determination of tumour grade.^{38,39} This technique remains experimental, and conclusions surrounding the clinical usefulness of this technology remain preliminary.

NATURAL HISTORY

The natural history of low-grade gliomas remains unclear because of the impact of CT and MR scans on establishing an early diagnosis, histologic and behavioural heterogeneity of low-grade gliomas, and the unknown impact of therapeutic interventions either at the time of diagnosis or at tumour progression. Nonetheless, the natural history of low-grade gliomas is one of progressive growth and eventual malignant degeneration. When patients with initially low-grade gliomas expire from tumour progression, the tumour at the time of death is usually an anaplastic astrocytoma or glioblastoma multiforme. Patients with an initial diagnosis of a low-grade glioma seldom die of progressive low-grade disease. A number of recent studies have shed light on the natural history of these neoplasms. Leighton and associates reported tumour recurrence or progression in 90 of 167 patients with supratentorial low-grade glioma.²⁶ In this series, the median time to progression was 50 months. Of the 71 (79%) patients with recurrence, 36 (51%) had a pathologically confirmed malignant glioma. Given the high incidence of cryptic anaplastic foci in tumours classified as low-grade, this study suggests that most low-grade gliomas degenerate into malignant neoplasms.

Estimates of overall and progression-free survival for untreated patients with low-grade gliomas can be inferred from modern series where patients received deferred radiotherapy or minimal intervention following diagnostic biopsies. Munding and Weigel⁴⁰ have reported five- and ten-year survival rates of 17% and 6% for patients with low-grade gliomas following limited biopsies, and Soffietti and colleagues²⁵ have published five- and ten-year survivals of 21% and 0% for 13 patients who had partial resections of low-grade astrocytomas. A recently published European trial, where 311 patients with low-grade gliomas were randomized to early versus deferred radiotherapy, reported 66% overall survival and 37% time to progression estimates at five years for the arm that had irradiation delayed, and 63% overall survival and 44% time to progression estimates at five years for the arm that received early radiotherapy.⁴¹

PROGNOSTIC FEATURES

A number of retrospective and a few prospective series have evaluated variables of potential prognostic significance in patients with low-grade gliomas. These studies suffer from a number of limitations, including investigator bias, patient heterogeneity, and variability of treatment offered. Nevertheless, a number of features relating to patient characteristics, tumour morphology and treatment have consistently been identified as prognostic indicators for patients with low-grade gliomas.

Tumour histology is of considerable prognostic significance. For instance, patients with low-grade oligodendrogliomas appear to have a particularly good prognosis with expected median survival in the range of 9.8 to 13 years.^{26,42} Moreover, there is some evidence to suggest that patients with low-grade oligoastrocytomas have prognoses that are similar to those with low-grade oligodendrogliomas.^{26,42} The recent recognition that a significant proportion of patients with low-grade gliomas have tumours that harbour allelic losses on chromosomes 1p and 19q suggests that in addition to classical histologic features, molecular characteristics may be important as prognostic markers for patients with low-grade gliomas.^{21,43} Tumour size at diagnosis has been demonstrated in a number of recent publications as having prognostic significance, with diminishing progression-free and overall survival as tumour size increases.⁴⁴ These data also support the variable observation of midline shift on radiographic images as a poor prognostic feature, and improved survival with more aggressive surgical resection.^{45,46}

With the exception of histology, age is the most important and consistent prognostic factor for survival.^{26,44,47-49} It is difficult to separate the influence of histology on age, particularly when children and young adults are more likely to have indolent pilocytic tumours. Nonetheless, studies that have excluded patients with pilocytic astrocytomas have confirmed that age is the most significant predictor of outcome following surgery and radiotherapy.⁵⁰ Furthermore, although increasing age appears to act as a continuous variable exerting unfavourable impact on survival,⁴⁸ most studies have suggested that patients beyond 40 are those most likely to have tumours with particularly aggressive biology.^{26,47,49,51}

Pre-operative and, to a lesser extent, postoperative performance status have been shown to be positively correlated with prognosis in patients with low-grade gliomas.^{8-10,25,26,49,51} Laws and associates,¹⁰ who documented poor survival in patients with evidence of increased intracranial pressure, impaired consciousness and personality change, first noted this observation. The widespread availability of CT and MR imaging has probably contributed to the diminishing significance of performance status on outcome because few patients now present with severe neurologic deficits at the time of diagnosis.⁵²

Seizures are the most common presenting symptom in patients with low-grade gliomas.^{24,26,52} A history of seizures has been identified as a good prognostic factor for patients with low-grade gliomas in part because they are common in patients who are young, who have indolent tumours, and have good performance status. Despite these associations, however, multivariate analysis has demonstrated seizures to be an independent, if somewhat variable, prognostic factor for patients with low-grade glial tumours.⁴⁷

THERAPY

Surgery

Surgery is essential to the diagnosis and management of low-grade gliomas. The timing and extent of surgery remain some of the most controversial issues in clinical neuro-oncology. A randomised clinical trial would be required to attempt to answer these matters definitively. However, a number of retrospective studies have addressed these questions, with preliminary conclusions.

Surgery remains necessary for pathological diagnosis of a suspected low-grade glioma, and can effectively alleviate tumour-related symptoms. Stereotactic biopsy is usually adequate for pathological diagnosis, but craniotomy with maximal surgical resection can reduce tumour-related morbidity, and possibly extend survival.⁴⁵ Consequently, for patients with gliomas in locations that make them amenable to extensive surgical resection, maximal surgical debulking appears to be preferable to biopsies or subtotal resections. A number of retrospective reviews have examined the relationship between extent of resection, and surgical and medical morbidity, and have concluded that, whenever possible, maximal surgical resection had fewer neurological complications, and no greater risk of neurological compromise, than biopsy or less extensive resections.^{53,54} Advances in CT- or MR-guided stereotactic surgery have made the possibility of extensive surgery feasible for an increasing proportion of patients with gliomas.³¹

Patients with malignant gliomas benefit from radical surgery, where extent of surgical resection influences postoperative survival.⁵⁵⁻⁵⁷ The prognostic significance of extent of resection has been examined retrospectively in low-grade glioma as well, and with a few notable exceptions,^{6,52} aggressive surgery appears beneficial for patients with low-grade tumours.^{8,25,26,45} These studies may be biased, however, as tumours that are easily and extensively resected may differ in their biologic behaviour from inaccessible tumours, and patients with easily resected tumours may have other characteristics that favour prolonged survival. Recently, Karim et al,⁴⁹ in a prospective study designed to determine optimal radiation dose for 379 adults with low-grade gliomas, found a statistically significant ($p=0.006$) increase in survival with more aggressive surgical resections. This observation supports an earlier study conducted by Berger et al,⁵⁸ who noted that patients with large low-grade gliomas had reduced rates of malignant transformation and recurrence when maximal surgery was performed.

While it is clear that patients with low-grade gliomas should have maximal surgical resections when the decision to operate is made, the appropriate timing of cytoreductive surgery is largely unanswered.³ Surgery can reduce or eliminate neurologic morbidity from large tumours, and for patients with such tumours, early surgery seems appropriate for symptom alleviation. Moreover, large low-grade tumours are prone to malignant transformation, and for this reason, early resection may modify tumour behaviour, delay progression, and prolong survival.^{13,58} The optimal surgical management of patients with small low-grade gliomas that are asymptomatic, or have only seizures as their sole manifestation, remains controversial. There is no current evidence to suggest that early surgical intervention for patients with small tumours influences recurrence, malignant transformation or survival.⁵⁸ Based on studies that have suggested that surgery and pathologic confirmation can be delayed until clinically indicated without adversely affecting outcome for patients with small well-differentiated gliomas, a policy of observation until progression is supported by an increasing proportion of neuro-oncologists.

Radiotherapy

Radiotherapy has been a standard treatment for low-grade gliomas for decades where it has been administered to patients

postoperatively as a means of improving otherwise disappointing outcomes. Until recently, all recommendations for postoperative radiotherapy for low-grade glioma had been based on retrospective reviews of patients. These series had many flaws, including variable grading systems, the inclusion of patients with pilocytic astrocytomas with low-grade fibrillary astrocytomas, variable treatment fields, doses and schedules, and confounding patient-related factors that influenced outcome. Retrospective series demonstrated the value of postoperative radiotherapy for incompletely resected symptomatic supratentorial astrocytomas where five-year survival rates could be extended from 10% for patients receiving only surgery, to 32% for those receiving surgery and postoperative radiotherapy.⁵ Furthermore, these series demonstrated that the benefits of radiotherapy for low-grade gliomas increased with age. In fact, some of these series have demonstrated a survival advantage following radiotherapy only for patients 35 to 40 years, or older.^{6,8,59} Finally, these studies settled the question of appropriate treatment fields, with current recommendations for treatment being restricted to the CT or MR scan defined tumour volume and a 2 cm margin of normal tissue.^{6,60} Despite the value and importance of these retrospective studies, there were a number of unanswered fundamental questions surrounding radiotherapy, the most important of which being appropriate timing and radiation dose. Three recent large randomised studies that have addressed these very questions have done much to clarify the role of radiotherapy for low-grade glioma.

The optimal dose of radiotherapy has been controversial, with most authorities traditionally recommending doses between 50 and 55 Gy in daily fractions between 1.8 and 2.0 Gy at five fractions per week. There is evidence, however, to support lower doses, as some investigators have noted poor survival with higher doses of radiation. A significant study, conducted by the European Organization for the Research and Treatment of Cancer (EORTC Study 2284) reported the results of a prospective randomised trial to determine the existence of a dose-response curve of low-grade glioma.⁴⁹ Between 1985 and 1991, 379 patients with a variety of low-grade neoplasms were randomised to receive irradiation postoperatively with either 45 Gy in five weeks, or 59.4 Gy in 6.6 weeks. After a median follow-up of greater than six years, results that demonstrated no survival difference between the treatment arms were reported. The five-year survival rates were 59% and 58% for patients randomized to the high-dose arm and low-dose arm, respectively. An update from this study that examined quality of life issues has demonstrated that patients receiving the lower dose of radiotherapy had significantly higher quality-of-life indices than those receiving the higher dose of radiotherapy.⁵¹ A second large randomised intergroup study conducted by the North Central Cancer Treatment Group, Radiation Therapy Oncology Group, and Eastern Cooperative Oncology Group adds further support for lower doses of radiotherapy for low-grade glioma.¹ This study randomised 203 patients to either a high-dose radiotherapy arm where a total dose of 64.8 Gy in 36 fractions, or to a low-dose arm where 50.4 Gy in 28 fractions was administered. Data from this study were recently analysed, and after a median follow-up of 6.43 years, survival at two and five years is nonsignificantly better with the low-dose radiotherapy arm. Specifically, survival at two and five years was 94% and

72%, respectively, with low-dose radiotherapy, and 85% and 64%, respectively, with high-dose radiotherapy. Moreover, toxicity was greater for patients receiving high-dose radiotherapy: the two-year actuarial incidence of grade 3 to 5 radiation necrosis was 2.5% with low-dose radiotherapy, and 5% with high-dose radiotherapy. Thus from the cumulative data from these two large, multi-institutional, randomised trials from the modern era, it appears that lower-doses of radiotherapy are as efficacious as, and less toxic than, higher doses.

More recently, the question of timing of radiotherapy has been addressed by a second European Organization for the Research and Treatment of Cancer study conducted between 1986 and 1997 that randomised 311 adult patients with low-grade gliomas after surgery to radiotherapy or observation until tumour progression.⁴¹ The dose of irradiation chosen for this study was 54 Gy over a period of six weeks. After a median follow-up of five years, the five-year estimates for time to progression were 44% and 37% for the treated and control arms, respectively. Five-year overall survival estimates were 63% and 66% for the treated and control arms, respectively. The differences were statistically significant only for the time to progression estimates. Thus, early radiotherapy appeared to improve time to progression, but not overall survival, for patients with low-grade gliomas. While this study could be interpreted to support early radiotherapy for this patient population, detailed quality of life assessments were not performed, and the delayed toxicities of radiotherapy were not documented. Consequently, an equally compelling interpretation of this study, given no difference in survival between the treated and control arms, would be to recommend withholding radiotherapy for patients with low-grade gliomas until there is evidence of radiographic or clinical progression. This approach seems particularly appropriate for young patients with favourable prognostic factors.

The toxicities of radiotherapy are not completely documented. The possibility of cognitive decline or dementia following radiotherapy is a very real concern for patients with low-grade gliomas, where median survival is often in excess of five years.⁶¹ However, recent studies of patients with low-grade gliomas treated with partial brain radiotherapy have not demonstrated a clinically meaningful effect on neurocognitive function for most patients, at least for relatively short follow-up intervals in the range of two to four years after the completion of radiotherapy.^{62,63} Despite these reassuring clinical observations, PET imaging suggests that radiotherapy is damaging to normal brain. Although methionine or glucose uptake as measured by PET imaging is not affected in low-grade astrocytomas by radiotherapy, normal brain does demonstrate reduction of glucose and methionine uptake following radiation exposure, suggesting damage that may be subclinical, or perhaps not detectable by neuropsychological tools in current use.^{64,65} Radiation necrosis appears to be infrequent when standard dosing and fields are applied. For instance, Shaw et al⁶ reported an incidence of radionecrosis of 2% following external beam radiotherapy for low-grade gliomas.

CHEMOTHERAPY

Although the role of chemotherapy in the management of low-grade gliomas is poorly defined, there is increasing interest

in using chemotherapy as initial treatment for low-grade tumours.⁶⁶ For patients with low-grade neoplasms, there are several advantages to an approach that avoids or delays cranial irradiation: chemotherapy may be more effective when administered as initial therapy; the CNS toxicities of radiotherapy, namely dementia or radiation necrosis, can be avoided or postponed; and chemotherapy may result in substantial reduction in tumour volume, thereby possibly reducing the size of radiotherapy treatment field when irradiation is required.

Reports of successful chemotherapy for low-grade oligodendrogliomas have stimulated this new approach to the management of low-grade tumours.^{23,67,68} Macdonald et al,⁶⁹ who reported responses to procarbazine, lomustine, and vincristine (PCV) chemotherapy in a series of aggressive oligodendrogliomas, were the first to suggest a role for chemotherapy in the management of nonanaplastic oligodendrogliomas. Following a number of anecdotal reports suggesting that objective responses to chemotherapy were possible in low-grade oligodendrogliomas, Mason et al⁶⁷ reported their experience using PCV chemotherapy in nine patients with symptomatic, enlarging, nonenhancing low-grade oligodendrogliomas. In their series, eight patients were treated with chemotherapy at presentation, and one was treated for a recurrence after radiotherapy had failed. All patients improved by clinical and radiographic criteria, or both. This experience has been confirmed and extended by Soffietti et al,⁷⁰ who treated 13 patients with newly diagnosed low-grade nonenhancing oligodendrogliomas and oligoastrocytomas with PCV chemotherapy, and observed partial responses in three patients, and stabilization of disease in ten. Recently, Buckner et al²³ reported a 28% response rate in 29 patients with newly diagnosed low-grade oligodendroglial tumours to PCV chemotherapy. Interestingly, in this series 1p and 19q allelic alterations were observed in nine of 13 patients with low-grade pure oligodendrogliomas, and these deletions were observed predominantly in patients with stable disease as opposed to those with tumour regression.

Unlike low-grade oligodendroglioma and oligoastrocytoma, where chemotherapy is becoming an increasingly acceptable initial treatment, chemotherapy has no established role in the management of low-grade fibrillary astrocytoma in adults.⁶⁶ In children, however, chemotherapy has been used as initial therapy in an effort to eliminate or delay the need for cranial irradiation because the delayed effects of radiotherapy on the developing brain would be substantial. The results from pediatric trials are difficult to interpret because many patients with low-grade tumours had pilocytic astrocytomas.⁷¹ However, Brada et al⁷² have recently administered temozolomide chemotherapy as initial treatment to a series of patients with symptomatic, enlarging low-grade tumours. Objective radiographic responses and stabilization of tumour growth was seen in patients with oligodendroglial and astrocytic pathology (Figure 2). Patients experienced modest improvement in quality of life, and those with epilepsy experienced improved seizure control. Furthermore, Quinn et al⁷³ have recently reported their results of a multicentre trial where temozolomide chemotherapy was administered to 46 patients with progressive low-grade gliomas that were predominantly of astrocytic histology. Although 14

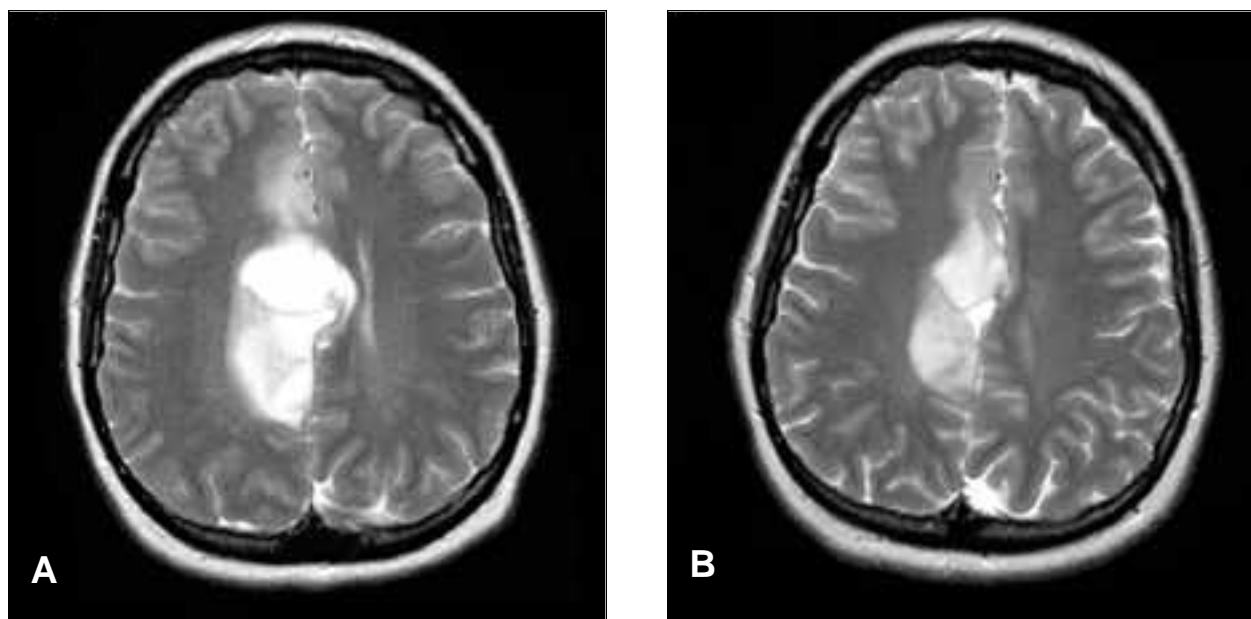


Figure 2: T2-weighted MRI of a 31-year-old woman with a low-grade astrocytoma that progressed radiographically following stereotactic biopsy. Irradiation was deferred because the patient was autistic and would require daily general anaesthesia for radiotherapy. Images before (A) and after 15 cycles of monthly temozolomide chemotherapy (B) demonstrate a partial radiographic response to therapy.

patients had received prior radiotherapy and chemotherapy, complete and partial radiographic responses were seen in 61%. For the entire cohort, a median progression-free survival of 22 months and a 12-month progression-free survival of 76% were reported. These interesting data, in light of recent observations that as many as two-thirds of patients with low-grade gliomas have oligodendroglial features, and as many as 15% of low-grade astrocytomas have a molecular genetic profile akin to that of classical oligodendrogliomas, has rekindled interest in the early use of chemotherapy for low-grade astrocytic neoplasms.

FUTURE TRENDS

A number of important conclusions regarding the management of low-grade gliomas can be drawn from the preliminary results of recent randomised studies exploring the role of radiotherapy for this disease. Significantly, it would appear that a lower dose, perhaps no greater than 50 Gy, should be administered to patients with this disease. Moreover, it appears to be safe to withhold radiotherapy until there is evidence of tumour progression. Both of these treatment strategies would reduce the toxicity and delayed neurocognitive sequelae associated with cranial irradiation.

The increasing use of chemotherapy for low-grade gliomas, and the possible association of chemosensitivity in low-grade glioma with oligodendroglial molecular markers represents an opportunity to incorporate chemotherapy in the initial management of this disease and thereby further delay irradiation. Currently, at least two randomised intergroup studies incorporating chemotherapy for low-grade glioma are being planned. The Radiation Therapy Oncology Group is conducting a trial with the

North Central Cancer Treatment Group, the Eastern Cooperative Oncology Group, and the Southwest Oncology Group for high-risk patients with supratentorial low-grade glioma.¹ Patients will be randomised to receive radiation alone at a dosage of 54 Gy in 30 fractions or radiotherapy followed by six courses of PCV chemotherapy. This protocol is aggressive because high-risk patients are being selected for treatment; consequently, a dose higher than recent studies would support, and a chemotherapy regimen conventional for anaplastic gliomas are being administered. Presently, the European Organization for the Research and Treatment of Cancer with the National Cancer Institute of Canada are planning a trial where patients with symptomatic and progressive low-grade gliomas will be randomised to receive radiation at a dosage of 50 Gy or temozolomide chemotherapy.⁷⁴ This study will address directly the role of chemotherapy for this disease, and temozolomide has been selected because it can be administered chronically with minimal cumulative toxicity.

The current management of low-grade gliomas is being refined by large clinical trials designed to address important therapeutic controversies. Nonetheless, the approach to a patient with a low-grade glioma is complex and must be individualized, and must take into account a number of important variables including tumour histology and genetics, tumour location, patient prognostic features and symptoms, and toxicities of available treatment modalities. These complexities mandate frank discussions with patients before embarking on a treatment plan because available treatments are not curative, and are associated with toxicities and sequelae that may impact unfavourably on quality of life.

Fortunately, the medical community has recognized the limitations of current therapies, and efforts are presently directed at maximizing benefits while minimizing toxicities of available treatments for this intractable disease.

REFERENCES

- Shaw E, Arusell R, Scheithauer B, et al. Prospective randomized trial of low- versus high-dose radiation therapy in adults with supratentorial low-grade glioma: initial report of a North Central Cancer Group/Radiation therapy Oncology Group/Eastern Cooperative Oncology Group study. *J Clin Oncol* 2002; 20: 2267-2276.
- Buatti J, Meeks S, Ryken T, Carlisle T. Low-grade gliomas: answering one question in a myriad of new questions. *J Clin Oncol* 2002; 20: 2223-2224.
- Cairncross JG, Laperriere NJ. Low-grade gliomas: to treat or not to treat? *Arch Neurol* 1990; 47: 1139-1140.
- Hart M, Petito C, Earle K. Mixed gliomas. *Cancer* 1974; 1: 134-140.
- Leibel S, Sheline G, Wara W, Boldrey E, Neilson S. The role of radiation therapy in the treatment of astrocytomas. *Cancer* 1975; 35: 1551-1557.
- Shaw E, Dumas-Duport C, Scheithauer B, et al. Radiation therapy in the management of low-grade supratentorial astrocytomas. *J Neurosurg* 1989; 70: 853-861.
- Shaw E, Scheithauer B, O'Fallon J, Davis D. Mixed oligoastrocytomas: a survival and prognostic factor analysis. *Neurosurgery* 1994; 34: 577-582.
- Philippon J, Clemenceau S, Fauchon F, Foncin J. Supratentorial low-grade astrocytomas in adults. *Neurosurgery* 1993; 32: 554-559.
- McCormack B, Miller D, Budzilovich G, Voorhees G, Ransohoff J. Treatment and survival of low-grade astrocytoma in adults-1977-1988. *Neurosurgery* 1992; 31: 636-642.
- Laws E, Taylor W, Clifton M, Okazaki H. Neurosurgical management of low-grade astrocytoma of the cerebral hemispheres. *J Neurosurg* 1984; 61: 665-673.
- Burger P, Scheithauer B. Tumours of the Central Nervous System. Washington, DC. Armed Forces Institute of Pathology, 1994.
- Dumas-Duport C, Scheithauer B, O'Fallon J, Kelly P. Grading of astrocytomas. A simple and reproducible method. *Cancer* 1988; 62: 2152-2165.
- Russel D, Rubinstein L. Pathology of tumours of the central nervous system. Baltimore: Williams and Wilkins, 1989.
- Whitton A, Bloom H. Low grade glioma of the cerebral hemispheres in adults: a retrospective analysis of 88 cases. *Int J Radiat Oncol Biol Phys* 1990; 18: 783-786.
- Kraus J, Koopmann J, Kaskel P, et al. Shared allelic losses on chromosomes 1p and 19q suggest a common origin of oligodendroglioma and oligoastrocytoma. *J Neuropathol Exp Neurol* 1995; 54: 91-95.
- Louis D. A molecular genetic model of astrocytoma histopathology. *Brain Pathol* 1997; 7: 755-764.
- Louis DN. The p53 gene and protein in human brain tumours. *J Neuropathol Exp Neurol* 1994; 53: 11-21.
- Louis D, von Deimling A, Chung R, et al. Comparative study of p53 gene and protein alterations in human astrocytomas. *J Neuropathol Exp Neurol* 1993; 52: 31-38.
- Kitange G, Templeton K, Jenkins R. Recent advances in the molecular genetics of primary gliomas. *Curr Opin Oncol* 2003; 15: 197-203.
- Cairncross JG, Ueki K, Zlatescu MC, et al. Specific genetic predictors of chemotherapeutic response and survival in patients with anaplastic oligodendrogliomas. *J Natl Cancer Inst* 1998; 90: 1473-1479.
- Reifenberger J, Reifenberger G, Liu L, et al. Molecular genetic analysis of oligodendroglial tumours shows preferential allelic deletions on 19q and 1p. *Am J Pathol* 1994; 145: 1175-1190.
- von Deimling A, Louis D, von Ammon K, et al. Evidence for a tumour suppressor gene on chromosome 19q with human astrocytomas, oligodendrogliomas and mixed gliomas. *Cancer Res* 1992; 52: 4277-4279.
- Buckner J, Gesme D Jr., O'Fallon JR, et al. Phase II trial of procarbazine, lomustine, and vincristine as initial therapy for patients with low-grade oligodendroglioma or oligoastrocytoma: efficacy and associations with chromosomal abnormalities. *J Clin Oncol* 2003; 21: 251-255.
- Vertosick F, Selker R, Arena V. Survival of patients with well-differentiated astrocytomas diagnosed in the era of computed tomography. *Neurosurgery* 1991; 28: 496-501.
- Soffietti R, Chio A, Giordana M, Vasario E. Prognostic factors in well-differentiated cerebral astrocytoma in the adult. *Neurosurgery* 1989; 24: 686-692.
- Leighton C, Fisher B, Bauman G, et al. Supratentorial low-grade glioma in adults: an analysis of prognostic factors and timing of radiation. *J Clin Oncol* 1997; 15: 1294-1301.
- Lee Y-Y, Tassel P, Bruner J, Moser R, Share J. Juvenile pilocytic astrocytomas: CT and MR characteristics. *Am J Radiol* 1989; 152: 1263-1270.
- Brothi J, Baleriaux D, Delecluse F. MRI and surgical treatment of low grade gliomas. *IMBO/IIOC* 1986; 211-215.
- Kelly P, Dumas-Duport C, Scheithauer B, Kall B, Kispert D. Stereotactic histologic correlations of computed tomography- and magnetic resonance imaging-defined abnormalities in patients with glial neoplasms. *Mayo Clin Proc* 1987; 62: 450-459.
- Stack J, Antoun N, Jenkins J, Metcalfe R, Isherwood I. Gadolinium-DTPA as a contrast agent in magnetic resonance imaging of the brain. *Neuroradiology* 1988; 30: 145-154.
- Kelly P. Volumetric stereotactic surgical resection of intra-axial brain mass lesions. *Mayo Clin Proc* 1988; 63: 1186-1198.
- Kilgore D, Breger R, Daniels D, et al. Cranial tissues: normal MR appearance after intravenous injection of Gd-DTPA. *Radiology* 1986; 160: 757-761.
- Chamberlain M, Murovic J, Levin V. Absence of contrast enhancement on CT brain scans of patients with supratentorial malignant gliomas. *Neurology* 1988; 38: 1371-1374.
- Kondziolka D, Lunsford L, Martinez A. Unreliability of contemporary neurodiagnostic imaging in evaluating suspected adult supratentorial (low-grade) astrocytoma. *J Neurosurg* 1993; 79: 533-536.
- Kaschten B, Stevenaert A, Sadzot B, et al. Preoperative evaluation of 54 gliomas by PET with fluorine-18-fluorodeoxyglucose and/or carbon-11-methionine. *J Nucl Med* 1998; 39: 778-785.
- Byrne T. Imaging of gliomas. *Semin Oncol* 1994; 21: 162-171.
- Francavilla T, Miletich R, Dichiro G, et al. Positron emission tomography in the detection of malignant degeneration of low-grade gliomas. *Neurosurgery* 1989; 24: 1-5.
- Hwang J, Egnaczyk G, Ballard E, et al. Proton MR spectroscopic characteristics of pediatric pilocytic astrocytomas. *AJNR Am J Neuroradiol* 1998; 19: 535-540.
- Vigneron D, Bollen A, McDermott M, et al. Three-dimensional magnetic resonance spectroscopic imaging of histologically confirmed brain tumours. *Magn Reson Imaging* 2001; 19: 89-101.
- Mundinger F, Weigel K. Considerations in the usage and results of curietherapy. In: Lunsford L, (Ed.) *Modern Stereotactic Neurosurgery*. Boston: Martinus Nijhoff, 1988: 245-258.
- Karim A, Afra D, Cornu P, et al. Randomized trial on the efficacy of radiotherapy for cerebral low-grade glioma in the adult: European Organization for Research and Treatment of Cancer study 22845 with the Medical Research Council study BR04: an interim analysis. *Int J Radiat Oncol Biol Phys* 2002; 52: 316-324.
- Shaw E, Scheithauer B, O'Fallon J. Supratentorial gliomas: a comparative study by grade and histologic type. *J Neurooncol* 1997; 31: 273-278.
- Smith JS, Perry A, Borell TJ, Lee HK, et al. Alterations of chromosome arms 1p and 19q as predictors of survival in oligodendrogliomas, astrocytomas, and mixed oligoastrocytomas. *J Clin Oncol* 2000; 18: 636-645.
- Kreth F, Faist M, Rossner R, Volk B, Ostertag C. Supratentorial World Health Organization Grade 2 astrocytomas and oligoastrocytomas. A new pattern of prognostic factors. *Cancer* 1997; 79: 370-379.

45. Scerrati M, Roselli R, Iacoangeli M, Pompucci A, Rossi G. Prognostic factors in low grade (WHO grade II) gliomas of the cerebral hemispheres: the role of surgery. *J Neurol Neurosurg Psychiatry* 1996; 61: 291-296.
46. Janny P, Cure H, Mohr M, et al. Low grade supratentorial astrocytomas. *Cancer* 1994; 73: 1937-1945.
47. van Veelen M, Avezaat C, Kros J, van Putten W, Vecht C. Supratentorial low grade astrocytoma: prognostic factors, dedifferentiation, and the issue of early versus late surgery. *J Neurol Neurosurg Psychiatry* 1998; 64: 581-587.
48. Lote K, Egeland T, Hager B, et al. Survival, prognostic factors, and therapeutic efficacy in low-grade glioma: a retrospective study in 379 patients. *J Clin Oncol* 1997; 15: 3129-3140.
49. Karim A, Matt B, Hatlevoli R, et al. A randomized trial no dose-response in radiation therapy of low-grade cerebral glioma: European Organization for Research and Treatment of Cancer (EORTC) study 22844. *Int J Radiat Oncol Biol Phys* 1996; 36: 549-556.
50. Medbery C, Strauss K, Steinberg S, Cotelingam J, Fisher W. Low-grade astrocytomas: treatment results and prognostic variables. *Int J Radiat Oncol Biol Phys* 1988; 15: 837-841.
51. Pignatti F, van den Bent M, Curran D, et al. Prognostic factors for survival in adult patients with cerebral low-grade glioma. *J Clin Oncol* 2002; 20: 2076-2084.
52. Piepmeier J. Observations on the current treatment of low-grade astrocytic tumours of the cerebral hemispheres. *J Neurosurg* 1987; 67: 177-181.
53. Fadul C, Wood J, Thaler H, et al. Morbidity and mortality of craniotomy for excision of supratentorial gliomas. *Neurology* 1988; 38: 1374-1379.
54. Ciric I, Ammirati M, Vick N, Mikhael M. Supratentorial gliomas: surgical considerations and immediate postoperative results. Gross total resection versus partial resection. *Neurosurgery* 1987; 21: 21-26.
55. Salzman M, Scholtz H, Kaplan RS, Kulik S. Long-term survival in patients with malignant astrocytoma. *Neurosurgery* 1985; 34: 213-220.
56. Ammirati M, Vick N, Liao Y, Ciric I, Mikhael M. Effect of extent of surgical resection on survival and quality of life in patients with supratentorial glioblastomas and anaplastic astrocytoma. *Neurosurgery* 1987; 21: 201-206.
57. Vecht C, Avezaat C, Putten W, Eijkenboom W, Stefanko S. The influence of the extent of surgery on the neurological function and survival in malignant glioma. A retrospective analysis of 243 patients. *J Neurol Neurosurg Psychiatry* 1990; 53: 466-471.
58. Berger M, Deliganis A, Dobbins J, Keles G. The effect of extent of resection on recurrence in patients with low grade cerebral hemisphere gliomas. *Cancer* 1994; 74: 1784-1791.
59. Laws E, Taylor W, Bergstralh E, Okazaki H, Clifton M. The neurosurgical management of low-grade astrocytoma. *Clin Neurosurg* 1986; 61: 665-673.
60. Wara W. Radiation therapy for brain tumours. *Cancer* 1985; 55: 2291-2295.
61. Surma-Aho O, Niemela M, Vilkkij J, et al. Adverse long-term effects of brain radiotherapy in adult low-grade glioma patients. *Neurology* 2001; 56: 1285-1290.
62. Taphoorn M, Schiphorst A, Snoek F, et al. Cognitive functions and quality of life in patients with low-grade gliomas: the impact of radiotherapy. *Ann Neurol* 1994; 36: 48-54.
63. Vigliani M-C, Sichez N, Poisson M, Delattre J-Y. A prospective study of cognitive functions following conventional radiotherapy for supratentorial gliomas in young adults: 4-year results. *Int J Radiat Oncol Biol Phys* 1996; 35: 527-533.
64. Roelcke U, von JA, Hausmann O, et al. Operated low grade astrocytomas: a long term PET study on the effect of radiotherapy. *J Neurol Neurosurg Psychiatry* 1999; 66: 644-647.
65. Bruehlmeier M, Roelcke U, Amsler B, et al. Effects of radiotherapy on brain glucose metabolism in patients operated on for low grade astrocytoma. *J Neurol Neurosurg Psychiatry* 1999; 66: 648-653.
66. Mason W. Chemotherapy for low-grade gliomas. *FORUM Trends in Experimental and Clinical Medicine* 2000; 10: 95-104.
67. Mason WP, Krol GS, DeAngelis LM. Low-grade oligodendroglioma responds to chemotherapy. *Neurology* 1996; 46: 203-207.
68. Soffietti R, Ruda R, Bradac GB, et al. PCV chemotherapy for recurrent oligodendrogliomas and oligoastrocytomas. *Neurosurgery* 1998; 43: 1066-1073.
69. Macdonald DR, Gaspar L, Cairncross J. Successful chemotherapy for newly diagnosed aggressive oligodendroglioma. *Ann Neurol* 1990; 27: 573-574.
70. Soffietti R. Chemotherapy with PCV for low grade nonenhancing oligodendrogliomas. *Neurology* 1999; 52 (Suppl. 2): A423.
71. Packer R, Lange B, Ater J, et al. Carboplatin and vincristine for recurrent and newly diagnosed low-grade gliomas of childhood. *J Clin Oncol* 1993; 11: 850-856.
72. Brada M, Viviers L, Abson C, et al. Phase II study of primary temozolomide chemotherapy in patients with WHO grade II gliomas. *Ann Oncol* 2003; 24: 1715-1721.
73. Quinn J, Reardon DA, Friedman AH, et al. Phase II trial of temozolomide in patients with progressive low-grade glioma. *J Clin Oncol* 2003; 21: 646-651.
74. Baumert B, Stupp R, van den Bent M, Mason W. Therapy with continuous temozolomide for low grade glioma, inclusion based on genetic classification: two study proposals of the EORTC (European Organization for Research and Treatment of Cancer). *Neurooncology* 2002; 4 (Suppl. 1): S7.