
Neuroimaging Highlight

Editors: Richard Farb, David Pelz

Sequestered Intradural Lumbar Disc

Submitted by: Alim P. Mitha, Forrest D. Hsu, James N. Scott, Bassam M. Addas, Yves Starreveld

Can. J. Neurol. Sci. 2009; 36: 776-778

A 42-year-old farmer was lifting a hay bale and experienced a sudden onset of sharp pain radiating down his left leg. Over the ensuing week, the pain became less pronounced, but was replaced with a progressive left greater than right leg numbness, foot weakness, and urinary hesitancy. He presented to his local hospital, where he was initially managed conservatively, and then transferred to our institution for consultation after an MR lumbar spine was completed. On physical exam, he had grade 1/5 weakness of left and right dorsi- and plantar flexion. Sensory testing showed a moderate decrease in pinprick sensation in his

left leg from L1 to S1 dermatomes. He was symmetrically hyporeflexic with grade 1 knee reflexes and absent ankle jerks. Peri-anal sensation was intact, but there was moderately reduced rectal tone. The remainder of his neurological exam was normal.

IMAGING

The MR examination showed an irregular, elongated soft tissue structure posterior to the L4 vertebral body that appeared contiguous at its cephalad margin with the L3/4 intervertebral disc (Figure 1). This lobulated mass was T1 isointense and

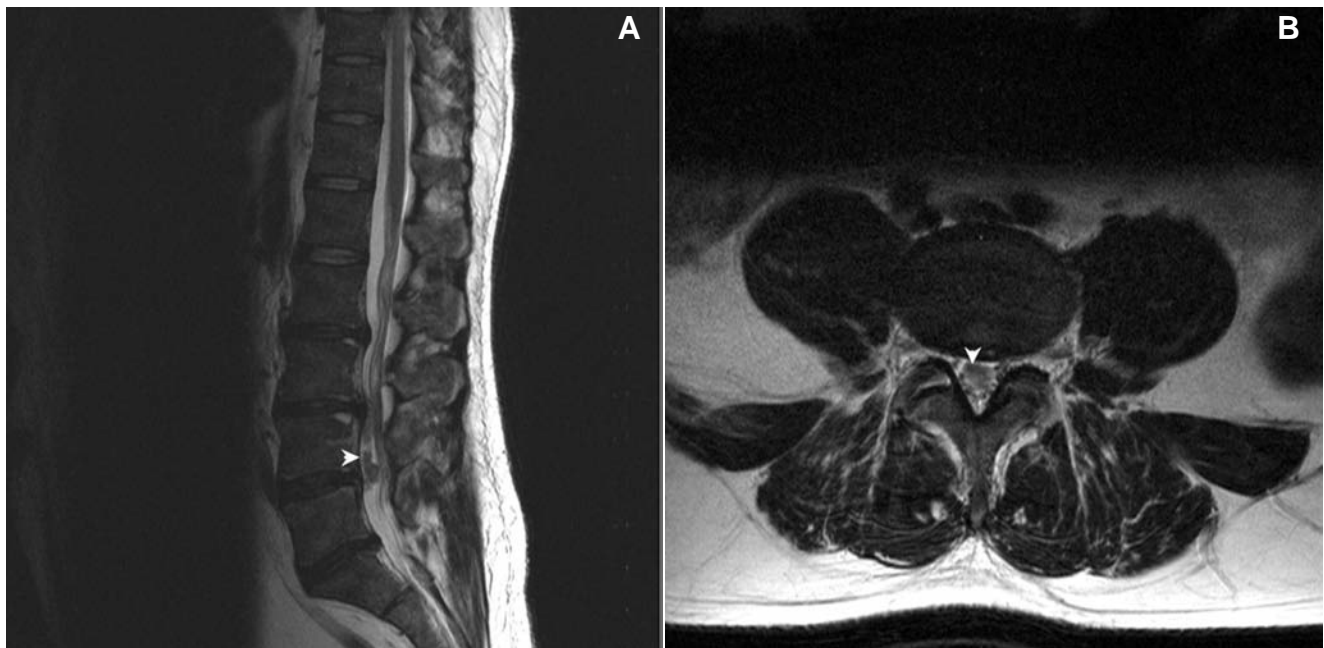


Figure 1: A) Sagittal T2-weighted image demonstrating the slightly hyperintense intradural lesion anterior to the nerve roots and extending inferiorly from the L3/4 level. B) Axial T2-weighted image again showing the anterior intradural lesion displacing the nerve roots posteriorly and laterally.

From the Department of Neurosurgery (APM, FDH, YS), Division of Neuroradiology (JNS), University of Calgary, Calgary, Alberta, Canada; Division of Neurosurgery (BMA), King Abdulaziz University, Jeddah, Saudi Arabia.

RECEIVED JULY 17, 2008. FINAL REVISIONS SUBMITTED JUNE 3, 2009.

Correspondence to: Yves Starreveld, Division of Neurosurgery, Rm C1243 -1403 29th St NW, Calgary, Alberta, T2N 2T9 Canada.

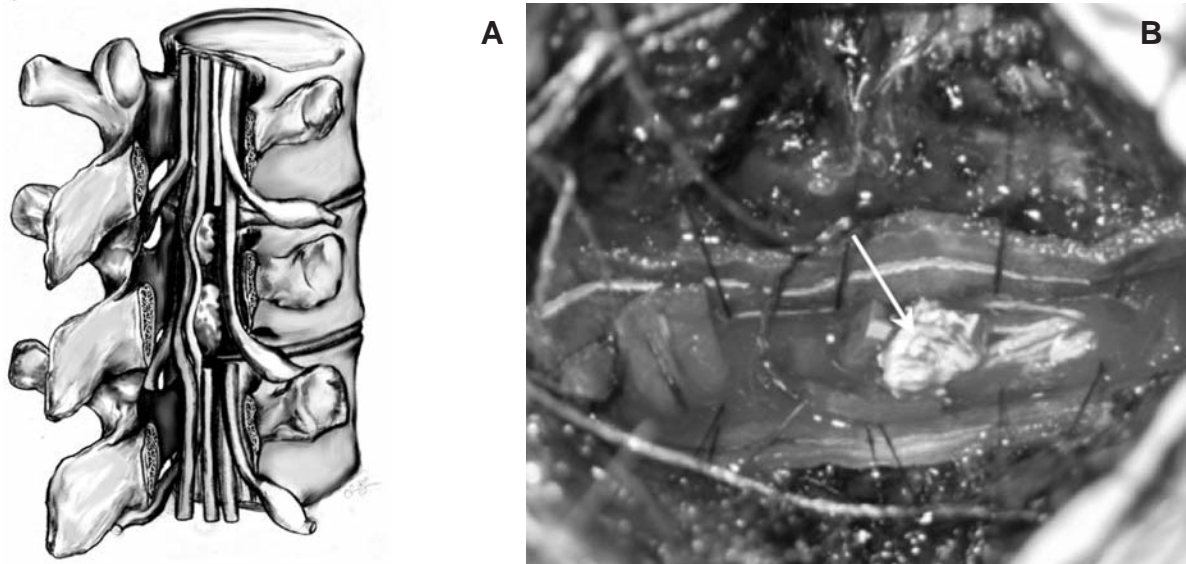


Figure 2: A) Drawing of the intradural disc material in relation to the nerve roots. The lamina to the right, the posterior dura, and an overlying nerve root have been cut away to expose the anteriorly located intradural disc material. B) Intraoperative photo of the intradural lumbar disc fragment, arrow shows extruded intradural disc fragment.

slightly T2 hyperintense to the L3/4 disc. Axial images through this level confirmed the mass was intradural in location, and was causing displacement of regional spinal nerve roots. This appearance was consistent with a sequestered intradural disc extrusion. Common intradural extramedullary mass lesions with unusual imaging features such as a schwannoma, neurofibroma and meningioma would be possible alternate diagnoses.

SURGICAL INTERVENTION

Given his symptoms, clinical and imaging findings, the patient was scheduled for an emergent intradural discectomy. Intraoperatively, laminectomies were completed at L3/5. The thecal sac was noted to be tense and non-pulsatile. Upon opening the significantly thinned dura, disc material was seen displacing the nerve roots dorsally and laterally within the intradural space (Figure 2). There were no intra- or post-operative complications. Permanent sections of the decompressed fragments were reactive cartilage consistent with lumbar disc.

DISCUSSION

Lumbar intradural disc herniations are a very rare pathological entity with an incidence ranging between 0.04-0.33% of all lumbar disc herniations¹. Several mechanisms for the pathogenesis of intradural disc herniation have been proposed. Dandy and others²⁻⁴ postulated that the acute pressure of the herniated fragments may erode and then penetrate the overlying dura that may be predisposed by adhesions, congenital lumbar stenosis, or congenital or iatrogenic chronically 'thinned' dura⁴. A few reports have documented intradural disc herniations occurring acutely coincident with the development of neurologic deficit⁵.

Interestingly, lumbar biomechanical studies suggest that L3/4 and L4/5 disc levels are believed to be centers of lumbar flexion and are exposed to greater loads as the back flexes⁶. Estimated forces exerted on the L3/4 lumbar disc ranges between 0.3-0.5kN at rest (axial support of the body), 2kN with light load exertions to 5 kN with heavy load exertions⁶⁻⁷. In our patient's case, the theoretical calculated pressure that the L3/4 disc/dura may have been exposed to as much as 1000 psi.

Intradural disc herniations have been reported in a variety of locations. In D'Andreas' review of nine lumbar intradural disc herniations, the most common locations were at the L4/5 followed by the L3/4 levels. It was postulated that at these levels the annulus, posterior longitudinal ligament and dura appear to be 'adhesed' or in close approximation⁴. Others have reported thoracic and cervical intradural disc herniations^{5,8}. Making the diagnoses pre-operatively is important and challenging. There are no specific radiologic features by plain film, CT, CT myelogram or MR that can make a definitive diagnoses. The best imaging modality is believed to be MR with gadolinium showing an intradural lesion with ring enhancement suggestive of a cuff of granulation tissue surrounding the herniated disc fragment^{4,9}. Alternative intradural extramedullary and intramedullary lesions with similar imaging features must also be included in the differential including schwannoma, meningioma, neurofibroma and ependymomas. The patient was referred to our service from a community hospital that had performed an urgent non-enhanced MR of the lumbar spine. Despite the absence of gadolinium studies, our patient's history, clinical and imaging findings were indicative of a sequestered intradural disc; alternate diagnoses of an intradural extramedullary tumor such as a schwannoma, or meningioma could not be excluded until surgical resection. It is interesting to note that histological

examination of the disc material showed signs of hyperchondrocytosis suggestive of reactive process that may correlate with the enhancement seen on MR gadolinium studies. Regardless, the patient's acute presentation of cauda equina syndrome secondary to a compressive intradural lesion necessitated an urgent decompression.

OUTCOME

Within a few days following decompression, our patient's left leg numbness resolved significantly and his left and right dorsiflexion and plantar flexion strength improved to a grade 3/5. On the day of discharge he was ambulating well with a walker and by his eight-week follow-up appointment the only residual deficit was mild bilateral numbness in the L5/S1 dermatomes. Although rare, intradural disc herniations must be kept in the differential diagnosis of a patient with a neurological deficit and MR findings suggesting an intradural extramedullary lesion.

ACKNOWLEDGEMENTS

We would like to acknowledge Summit Jhas for his detailed illustration of our case of a sequestered intradural disc.

REFERENCES

1. Kataoka O, Nishibayashi Y, Sho T. Intradural lumbar disc herniation. Report of three cases with a review of the literature. *Spine*. 1989;14:529-33.
2. Dandy W. Serious complications of ruptured intervertebral disks. *JAMA*. 1942;119:474-77.
3. Koc RK, Akdemir H, Oktem IS, Menku A. Intradural lumbar disc herniation: report of two cases. *Neurosurg Rev*. 2001;24:44-7.
4. D'Andrea G, Trillo RR, Celli P, Orlando ER, Ferrante L. Intradural lumbar disc herniations: the role of MRI in preoperative diagnosis and review of the literature. *Neurosurg Rev*. 2004;27:75-80.
5. Almond LM, Hamid NA, Wasserberg J. Thoracic intradural disc herniation. *Br J Neurosurg*. 2007;21(1):32-4.
6. Dolan P, Adams MA. Recent advances in lumbar spinal mechanics and their significance for modeling. *Clin Biomech*. 2001;16S: S8-16.
7. McGill SM, Norman RW. Partitioning of the L4-5 dynamic moment into disc ligamentous and muscular components during lifting. *Spine*. 1986;11:666-78.
8. Iwamura Y, Onari K, Kondo S, Inasaka R, Hidekazu H. Cervical Intradural disc herniation. *Spine*. 2001;26(6):698-702.
9. Wassertrom R, Mamourian AC, Black JF, Lehman RAW. Intradural lumbar disc fragment with ring enhancement on MR. *Am J Neuroradiol*. 1993;14:401-4.