

DIAGNOSTIC CHALLENGE

Answer

Jacquelyn Dirks, MD;\* Anthony Herd, MD\*†

The correct answer is “b” (a chest x-ray).

An anterior–posterior chest x-ray revealed a 4-cm round opacity in the right upper lobe, along with lower lobe atelectasis and a pleural effusion (Fig. 1). The patient’s white blood count was slightly elevated at  $13.5 \times 10^9/L$ , but the rest of the complete blood count (CBC), electrolytes and renal function indices were normal. An erythrocyte sedimentation rate (ESR) was not ordered.

A CT-scan of the chest was subsequently performed (Fig. 2) and revealed features consistent with an abscess in the right upper lobe, which extended from the pleural cavity into the chest wall, and the presence of a collection of pleural fluid.

An ultrasound-guided aspiration of the lesion yielded pus, which grew *Staphylococcus aureus* that was sensitive to methicillin. Sputum staining for acid fast bacilli and serum HIV antibody tests were negative.

Antibiotic therapy with intravenous cloxacillin was com-

menced and the patient underwent an open thoracotomy for drainage of the abscess and lung debridement. He was discharged from hospital 8 days later and made a full recovery.

Discussion

This patient presented with pain and reduced mobility in his right shoulder, associated with chills and sweats. The initial diagnosis was shoulder strain because of the temporal relation to his lifting heavy boxes. However, when his symptoms did not resolve, further investigation was undertaken.

A CBC might be considered as part of the work-up for an infectious etiology because of the history of chills and sweats, but this would not help to localize the focus. While the patient’s ESR might be elevated, like a CBC, it is non-specific. The patient had pectoral swelling, but no ery-

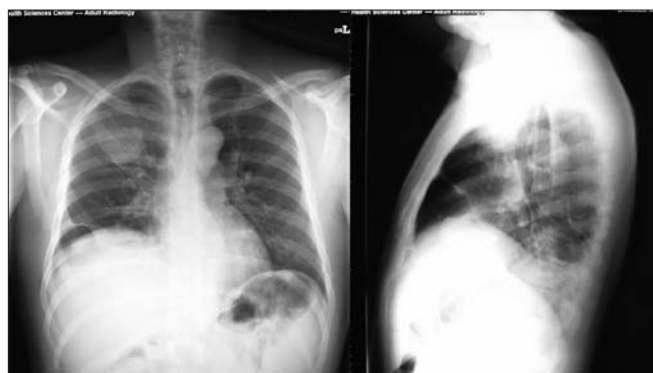

Fig. 1. Anterior–posterior (left) and lateral chest x-ray (right) demonstrating a round opacification in the right upper lobe.

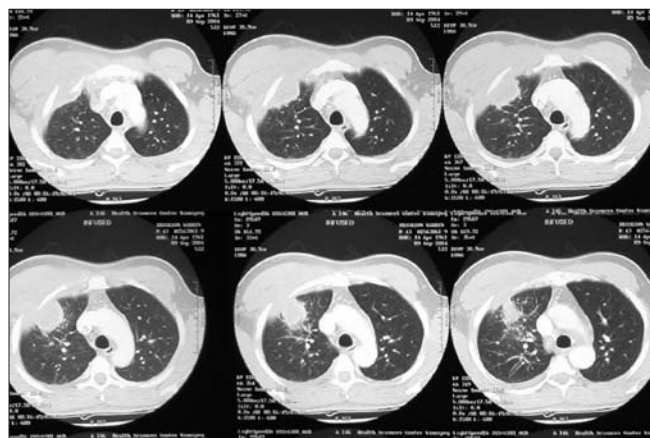


Fig. 2. CT-scan of the chest demonstrating a radiopaque lesion in the right upper lobe.

From the \*Faculty of Medicine, University of Manitoba and the †Adult Emergency Unit, Health Sciences Centre, Winnipeg, Man.

This article has not been peer reviewed.

Can J Emerg Med 2007;9(4):309-10

thema or induration of the skin and there were abnormal findings on auscultation of the chest. Under these circumstances, a chest x-ray is indicated. If the shoulder is not adequately included on the anterior–posterior view, specific shoulder x-rays may also be indicated. A CT-scan was necessary to clarify the abnormalities on the plain films. It is highly unlikely that magnetic resonance imaging of the shoulder would be deemed appropriate prior to preliminary diagnostic imaging.

Symptoms and signs of empyema vary depending on the severity of the infection, the amount of fluid that accumulates within the pleural space and the infectious agent.<sup>1</sup> The typical presentation is that of fever, chills, productive cough, dyspnea and chest pain. Physical findings can include fever, dullness to percussion of the chest, crackles on auscultation from an associated pneumonia and, rarely, a pleural friction rub. Usually, thoracic empyema develops as complication of pneumonia with a parapneumonic effusion.<sup>2</sup>

Abscess formation occurs when the condition is chronic. Occasionally, the abscess can erode through the chest wall and present as a spontaneously draining abscess. This condition is referred to as empyema necessitatis and it would have developed in our patient if the diagnosis and treatment had been further delayed.

Our patient had no respiratory symptoms on history, but did have respiratory findings on physical examination. Presumably, his shoulder pain and ulnar parasthesias were the result of irritation of the medial cord of the brachial plexus, which is in close proximity to the clavicle and first rib.

The radiologic findings in this case are typical of a thoracic empyema with pleural effusion and consolidation or both), and spherical opacification when an abscess is present.<sup>3</sup>

A presumptive diagnosis of a thoracic empyema is confirmed by aspiration of frank pus during thoracentesis.

Ultrasonography can provide guidance for thoracentesis, pleural catheter placement or aspiration of associated pulmonary abscesses.

In addition to parenteral antibiotics, treatment options for a thoracic empyema include percutaneous pleural drainage, tube thoracostomy drainage, intrapleural fibrinolysis and surgical drainage, either with video assisted thoracostomy or open thoracotomy.<sup>1</sup>

The clues to a non-musculoskeletal etiology of shoulder pain in this case were the history of chills and sweats, the chest wall swelling and the crackles on auscultation. These findings could have easily been missed if the emergency physician restricted the exam to the shoulder. This case serves as a reminder not to be anchored to the diagnosis of soft tissue injury when evaluating patients with extremity and joint symptoms, unless there is clear history or obvious signs of trauma.

**For the Challenge, see page 296.**

**Competing interests:** None declared.

**Key words:** empyema, abscess, staphylococcus

## References

1. de Hoyos A, Sundaresan S. Thoracic empyema. *Surg Clin North Am* 2002;82:643-71.
2. Ahmed RA, Marrie TJ, Huang JQ. Thoracic empyema in patients with community-acquired pneumonia. *Am J Med* 2006; 119:877-83.
3. King S, Thompson A. Radiological perspectives in empyema. *Br Med Bull* 2002;61:203-14.

**Correspondence to:** Dr. Anthony Herd, Adult Emergency Health Unit, Health Sciences Centre, 820 Sherbrook St., Winnipeg MB R3A 1R9; am.herd@shaw.ca