

NEW AUTOSOMAL SYNDROMES: TRISOMIES 4p AND 9p

B. DALLAPICCOLA (1), P. MASTROIACOVO (2), G. SEGNI (2)

(1) Department of Medical Genetics, University of Rome, Italy

(2) Department of Pediatrics, Catholic University; Program of Preventive Medicine (Perinatal Preventive Medicine — Subproject NPP/4), National Research Council, Rome, Italy

Six cases of trisomy 4p and three of trisomy 9p are reported. Growth retardation is an aspecific clinical sign, present in both of these "new autosomal" syndromes. Growth hormone determinations fit in the normal range. The attempts to subclassify these disorders correlating the severity of clinical manifestations and the size of the imbalanced chromosome segment, are considered unrealistic approaches.

INTRODUCTION

Several considerations allow a joint presentation of 4p and 9p trisomy syndromes, while discussing growth retardation due to autosomal imbalances. Mainly:

(1) 4p and 9p trisomies, as well as trisomy 8, are the best established new autosomal syndromes (Dallapiccola and Forabosco 1975). However, contrary to no. 8 chromosome trisomics, who are not necessarily growth retarded, the height invariably remains below normal in the patients carrying 4p and 9p duplications.

(2) Both disorders are relatively frequent, as estimated by numerous observations reported in the recent literature (more than 30 cases of 4p trisomy syndrome: Dallapiccola et al. 1977; more than 80 cases of 9p trisomy syndrome: Mastroiacovo et al. 1976).

(3) Conversely, the two syndromes closely overlap with other autosomal disorders, concerning some general aspects, as the aspecificity of the individual clinical dysmorphisms. However, individually nonpathognomonic features cluster in specific ways and characterize peculiar phenotypes, which can be correctly diagnosed on clinical grounds alone.

These imbalances usually result from a parental balanced translocation and, only in a minority of cases, from a *de novo* rearrangement. It is worth of note that trisomy 9p has been considered the most frequent chromosomal aberration associated with familial mental retardation (Blanck et al. 1975).

TRISOMY 4p

In the years 1973-1976 we have investigated 6 patients carrying duplications of the short arm of no. 4 chromosome. Our observations are summarized in Table 1, in which the karyotype of the patients and the parental chromosome imbalances are also reported (Fig. 1). Table 2 shows the main clinical features of the syndrome and their relative distribution in the examined individuals.

At birth, the average weight is 2667/g (mean value for 32 cases) and the average length about 48 cm. Available data suggest the existence of a severe growth retardation, mainly

Table 1. General features in the 6 cases of 4p trisomy

	Case I	Case II	Case III	Case IV ^a	Case V ^b	Case VI ^b
Sex	F	M	M	M	M	F
Age	2 years	newborn	21 months	newborn	3 months	4 years
Patients' karyotype	46,XX,rec(4) inv(4)(p17;q35)	47,XY,+der(4p)mat		47,XY,+der(4) t(3;4)(p26;q13)mat	46,XY,-22,+der(22),t(4;22)(p11;p12)mat	47,XX,+der(4p;22p)mat
Parental karyotype	46,XY,-4,inv.(4)(p13;q35)	47,XX,-4,+der(4p),+der(4q)-cen.fission		46,XX,t(3;4)(p26;q13)	46,XX,t(4;22)(p11;p12)	46,XX,t(4;22)(p11;p12)(q25;q11)
Birth weight (g)	2600	2450	3000	2000	3020	2200

^a Contributed by Dr. E. Montali

^b Contributed by Dr. A.M. Sommer

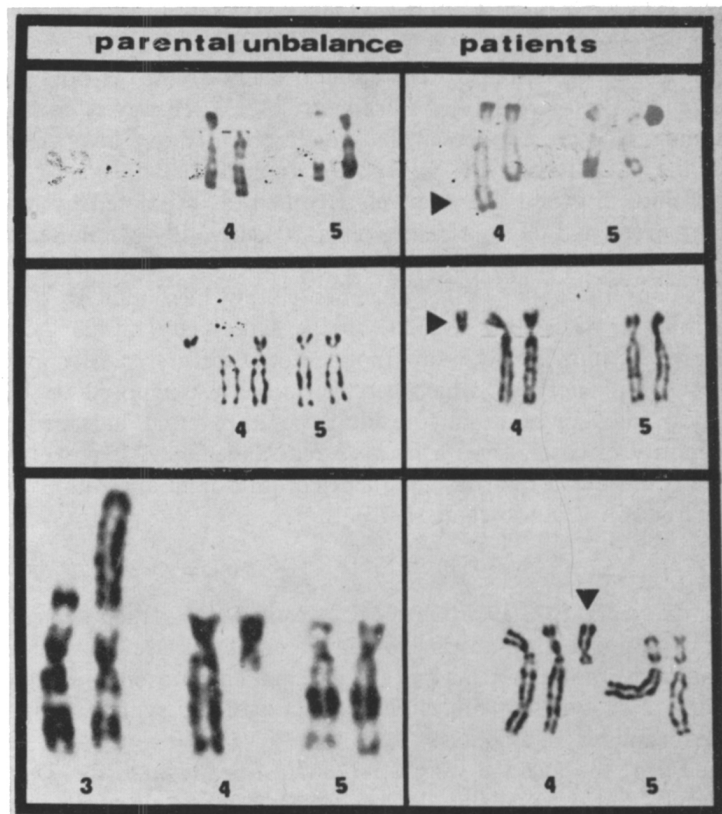


Fig. 1. Partial karyotypes showing parental aberration and patients' imbalance in a series of 4p trisomies.

Table 2. Main clinical features, with relative frequency, in the 6 cases of 4p trisomy

Growth retardation	6/6	Prominent glabella	4/6
Mental retardation (severe)	6/6	"Boxer" nose	4/6
Flexion contractures of fingers and toes	4/6	Malformed ears	5/6
Microcephaly	5/6	Long philtrum	4/6
External genitalia malformations in males	4/4		

affecting height during childhood. Stature is invariably below the 3rd percentile, while an overweight may be present in older individuals. At puberty, a dysharmonic growth, with a prevalence of lower limbs over the trunk, has been reported. Hormonal assays, and mainly growth hormone evaluations, fit in the normal range (Dallapiccola 1974).

The skeletal anomalies detected in the patients have been included in the list of the main features of the syndrome (Dallapiccola et al. 1975, 1977; Table 3, Fig. 2). Some of these

Table 3. Main radiological findings in 4p trisomy patients

<i>Skull</i>		<i>Pelvis</i>	
Microcephaly	19/23	Hypoplastic iliac wings	10/15
Convolutional markings	9/14	Increased acetabular angle	8/15
Small-closed sella	8/14	Hip malformations	8/23
Hypertelorism	12/23	Coxa valga	10/17
Malocclusion	11/15		
<i>Spine-Thorax</i>		<i>Hands-Feet</i>	
Scoliosis	15/24	Pseudoepiphyses	7/13
"Square" vertebral bodies	8/24	Hallux valgus	7/14
Aplastic-hypoplastic ribs	10/15	<i>Delayed bone age</i>	10/17

findings, such as "pseudoepiphyses", may be seen slightly more often than normal variants. Other changes — for example, faulty long bone development, "square" vertebral bodies and coxa valga — are undoubtedly secondary to more basic disorders. In fact, they are not unusual in mentally retarded children, because of reduced physical activity. A third group of signs, notably the abnormalities of the pelvis, are not significantly different from those observed in other chromosomal imbalances. Therefore, while the peculiar clustering of some clinical features can *per se* suggest 4p syndrome, the skeletal abnormalities, which are consistent with the presence of a chromosomal disorder, appear to be inadequate to classify the chromosome imbalance properly.

TRISOMY 9p

We have investigated 3 patients with 9p trisomy syndrome. In 2 cases the imbalance resulted from a parental translocation, in the third case it originated *de novo* (Fig. 3, Table 4). On the whole, the clinical features are strictly comparable to those originally reported by Rethoré and Lafourcade (1974) (Table 5). In this context, the craniofacial and hands dysmorphisms appear of specific diagnostic value (Fig. 4).

The average weight at birth is normal in pure 9p trisomy patients (3106 g for 13 cases); however, for associated 9p trisomies, the birth weight is low (2716 g for 16 cases). At

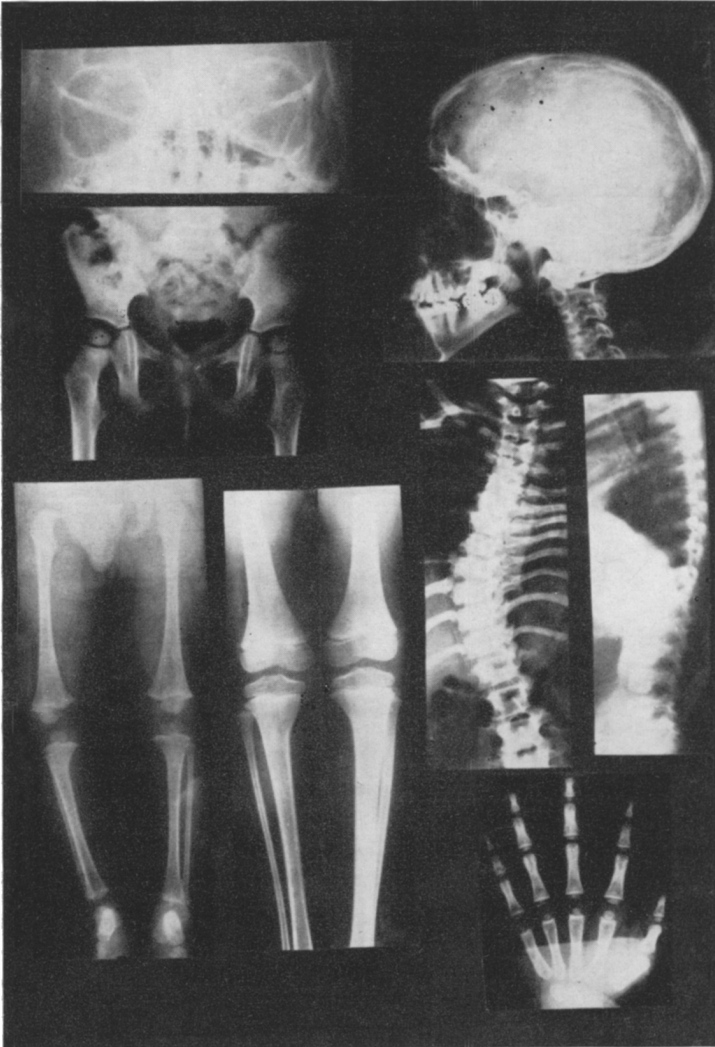


Fig. 2. Some of the most consistent skeletal anomalies in 4p trisomics.

maturity, height ranges from 160 to 175 cm for males and from 149 to 159 cm for females; the weight is normal or above normal.

In 1976 Fujita et al. have investigated growth hormone values in three patients. Concentrations less than 5 ng/ml following hypoglycemia induced by arginine and insulin have been observed, while the values were significantly increased following glucagone and propranolol administration. These findings have been interpreted as a secretion defect and not as a defect of hormonal production. Similar data have not been confirmed in our three cases, showing normal basal values and reactions. However, it is worth of note that the patients studied by Fujita et al. (1976) were carriers of larger chromosome 9 duplications, which also involved part of the long arm.

A classification of 9p trisomics has been proposed according to the size of the chromosomal

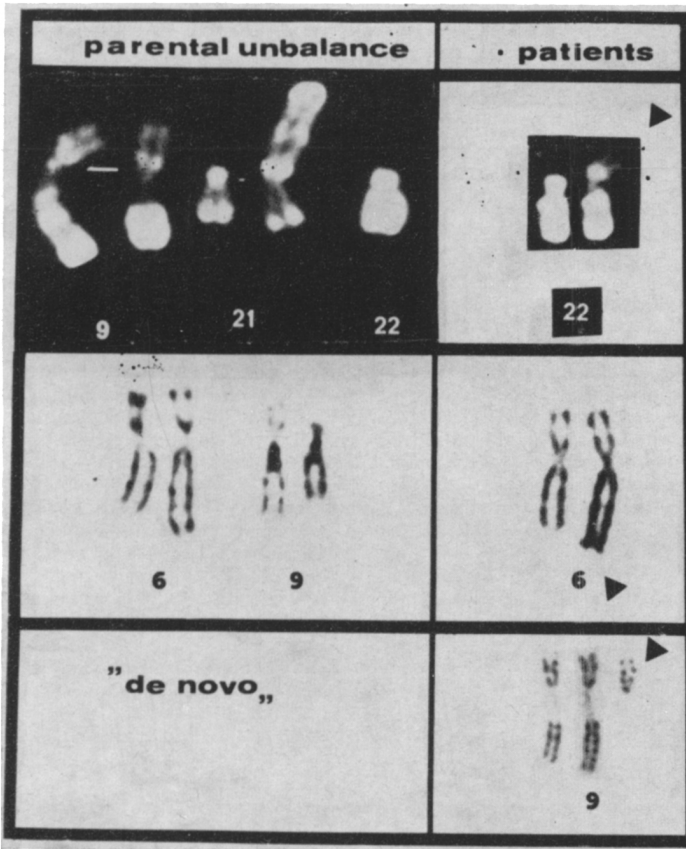


Fig. 3. Partial karyotypes showing parental aberration and patients' imbalance in three 9p trisomics.

Table 4. General features in the 3 cases of 9p trisomy

	Case I	Case II	Case III ^a
Sex	M	F	M
Age (years)	8	11	12
Patients' karyotype	47,XY,-22,+der(22)t(9;22)(q12;q11)mat	45,XX,-6,+der(6)t(6;9)(q27;q13)pat	47,XY,+9p(q12-pter)
Parental karyotype	45,XX,-9,-21,-22,t(9;21)(9;22)(q12;q13)(q12;q11)	46,XY,t(6;9)(q27;p13)	46,XX 46,XY
Birth weight (g)	2050	2800	2750

^a Contributed by Drs. P. Vignetti and L. Chessa

Table 5. Main clinical features, with relative frequency, in the 3 cases of 9p trisomy

Growth retardation	3/3	Large, prominent nose	3/3
Mental retardation (severe)	3/3	Full, outward turned lips	2/3
Microcephaly	3/3	Downward slanting mouth corners	3/3
Deep set eyes	3/3	Protruding ears	2/3

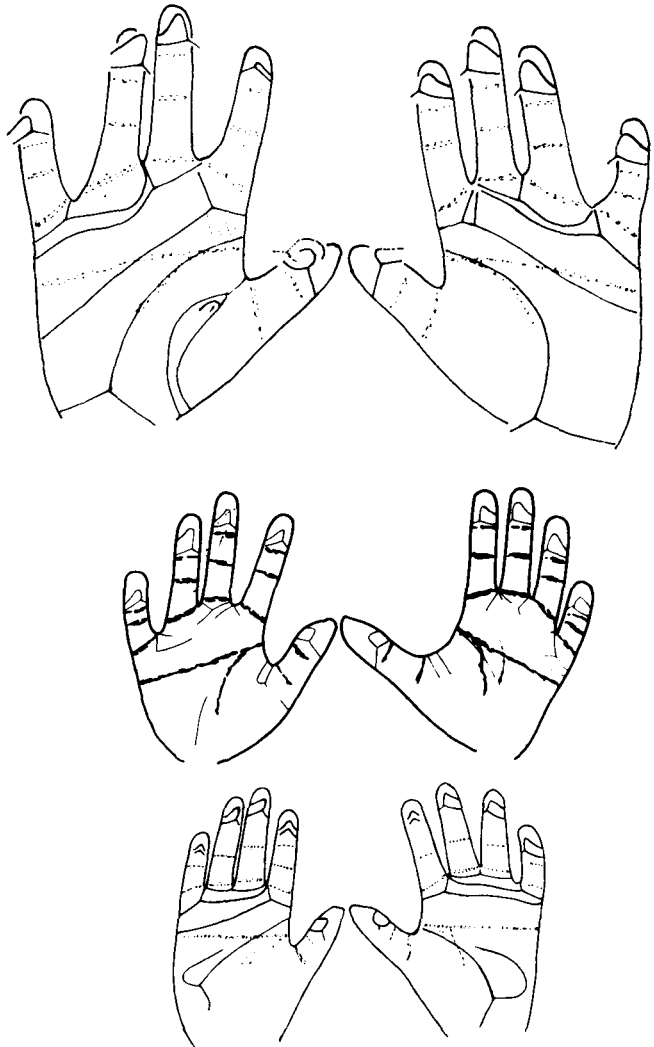


Fig. 4. Diagram of dermatoglyphics in 9p trisomy patients: Note the transverse palmar crease and the absence of the triradii under the bases of the fourth fingers.

imbalance, and the existence of different phenotypical patterns has been derived (Centerwall et al. 1976). Personal data are not in contrast with the idea to subclassify some of the new autosomal syndrome. However, in the present series of patients, a possible positive correlation between the severity of clinical manifestations and the size of imbalanced chromosome can be established only in 4p trisomics. In fact, in the group of 9p trisomy patients,

the more severely affected individual was the one carrying the smaller short-arm imbalanced segment.

In conclusion, available evidence suggests that both 4p and 9p trisomy syndromes could result from the imbalance of the two distal short arm bands, and possibly from the imbalance of the short arm telomeric region (Dallapiccola et al. 1977): therefore, we consider the attempts to subclassify these syndromes by means of "phenotypical maps" rather unrealistic approaches.

REFERENCES

- Blanck C.E., Colver C.B., Potter A.M., McHugh J., Lorber J. 1975. Physical and mental defect of chromosomal origin in four individuals of same family. Trisomy for the short arm of 9. *Clin. Genet.*, 7: 261-271.
- Centerwall W.R., Miller K.S., Reeves L.M. 1976. Familial "partial 9p" trisomy: Six cases and four carriers in three generations. *J. Med. Genet.*, 13: 57-64.
- Dallapiccola B. 1974. Ritardi staturali da aberrazioni autosomiche. Proc. Int. Symp. "Management of Height Retardation", Fiuggi 1974. *Acta Med. Auxol.*, 6: 251-282.
- Dallapiccola B., Forabosco A. 1975. Le nuove sindromi autosomiche. *Folia Hered. Pathol.*, 24: 32-67.
- Dallapiccola B., Giovannelli G., Forabosco A. 1975. The radiological pattern associated with the trisomy of the short arm of chromosome No. 4. *Pediatr. Radiol.*, 3: 34-40.
- Dallapiccola B., Mastroiacovo P., Montali E., Sommer E. 1977. Trisomy 4p: 5 new cases and overview. *Clin. Genet.* (in press).
- Fujita H., Shimazaki M., Takeuchi T., Hayakawa Y., Oura T. 1976. 47,+ (9q-) in unrelated three children with plasma growth hormone deficiency. *Hum. Genet.*, 31: 271-282.
- Mastroiacovo P., Dallapiccola B., Gugliantini F., Segni G. 1976. Trisomia 9p da traslocazione paterna t(6;9) (q27;p13). *Riv. Ital. Pediatr.*, 2: 115-123.
- Rethoré M.O., Lafourcade J. 1974. Trisomie du bras court du chromosome 9: Syndrome +9p. *Journées Parisiennes de Pédiatrie* [pp. 379-390]. Paris: Flammarion.

RIASSUNTO

Nuove Sindromi Autosomiche: Trisomie 4p e 9p

Vengono descritti 6 casi di trisomia 4p e 3 casi di trisomia 9p. Il ritardo della crescita è un segno clinico aspecifico presente in ambedue queste nuove sindromi autosomiche. Le determinazioni dell'ormone della crescita danno valori normali. I tentativi di sottoclassificare queste anomalie in rapporto alla gravità delle manifestazioni cliniche e alle dimensioni del segmento cromosomico sbilanciato non appaiono realistici.

RÉSUMÉ

Nouveaux Syndromes Autosomiques: Trisomies 4p et 9p

Six cas de trisomie 4p et trois cas de trisomie 9p sont décrits. Le retard de la croissance est un signe clinique aspécifique présent dans les deux syndromes. Les valeurs de l'hormone de la croissance sont normales. Les tentatives de classer ces anomalies par rapport aux manifestations cliniques et aux dimensions du segment chromosomique non-balancé ne semblent pas réalistiques.

ZUSAMMENFASSUNG

Neue autosome Syndrome: 4p- und 9p-Trisomie

Verf. beschreiben 6 Fälle von 4p-Trisomie und 3 Fälle von 9p-Trisomie. Bei beiden dieser neuen autosomen Syndrome stellt die Wachstumsverzögerung ein spezifisches klinisches Symptom dar. Eine Bestimmung der Wachstumshormone ergab normale Werte. Versuche, diese Anomalien je nach Schwere der klinischen Erscheinungen oder nach den Dimensionen der nicht ausbalancierten Chromosomensegmente in Untergruppen einzuteilen, erscheinen nicht realistisch.

Prof. Bruno Dallapiccola, Cattedra di Genetica Medica, Ospedale Spallanzani, Via Portuense 292, 00149 Rome, Italy.