

# Neuropathology of 3-Hydroxyisobutyric Aciduria, an Autopsy Case Report

Xianyuan Song, Virginia Anderson, Miguel Guzman, Chandrakant Rao

Can. J. Neurol. Sci. 2009; 36: 483-486

3-hydroxyisobutyric aciduria (3-HiB-uria), a rare disorder of valine metabolism, results from tissue accumulation and significant elevation of urinary excretion of 3-hydroxyisobutyric acid. To date, 14 cases of 3-HiB-uria have been reported, the majority of which were male patients, including two sets of male twins, two brothers, and a brother-and-sister pair.<sup>1-7</sup> The clinical course varies, from mild attacks of vomiting with normal brain and cognitive development,<sup>3,5</sup> to failure to thrive with profound mental impairment and early death.<sup>2,4</sup> Dysmorphic facial features and brain malformation have been described in patients with 3-HiB-uria.<sup>1-4,6,8</sup> Of the 14 reported cases, there were only two autopsies from four deaths. No gross or microscopic images exist. In this report, we document the post-mortem neuropathological findings in a 3-HiB-uria case with photographs for the first time.

## CASE REPORT

This four-year-old Trinidadian boy was the first baby born to healthy unrelated parents. At birth, the infant weighed 5lbs with lethargy, feeding difficulties and poor cry. Family history was not contributory. The patient's developmental and mental retardation and dysmorphic facial features initially lead to misdiagnoses of cerebral palsy and Cornelia de Lange syndrome. When he presented to our institution at the age of three years, he was found to have organic acidemia, recurrent episodes of ketoacidosis and lactic acidemia, and severe failure to thrive. Repeated urine organic acid tests revealed persistent high 3-hydroxyisobutyrate levels, and diagnosis of 3-HiB-uria was made. Other acids were elevated including: 3-hydroxybutyrate and acetoacetate (consistent with ketosis); lactate, 4-hydroxyphenyl lactate, 2-hydroxybutyrate, and pyruvate (consistent with lactic acidosis); and 2-hydroxyisovalerate and 3-hydroxy-2-ethylpropionate (products secondary to ketosis or lactic acidosis). The levels of 3-hydroxypropionate, methylcitrate, and methylmalonate were all within normal range. Patient was placed on carnitine supplement with high-calorie-low-protein diet without success and died seven months after the diagnosis.

At autopsy, severe growth retardation and wasting was noted. The body weighed 8.95kg, and measured 67cm. Dysmorphic facial features included: microcephaly, persistent anterior fontanel, prominent occiput, bushy eyebrows, flat nasal bridge, epicanthal folds, discolored hypoplastic teeth, and micrognathia (Figure 1). Additional autopsy findings included: severe thyroid and adrenal atrophy, marantic degeneration of mitral valve, testicular atrophy, cryptorchism, neurogenic muscular atrophy, and bronchopneumonia in the left lung.

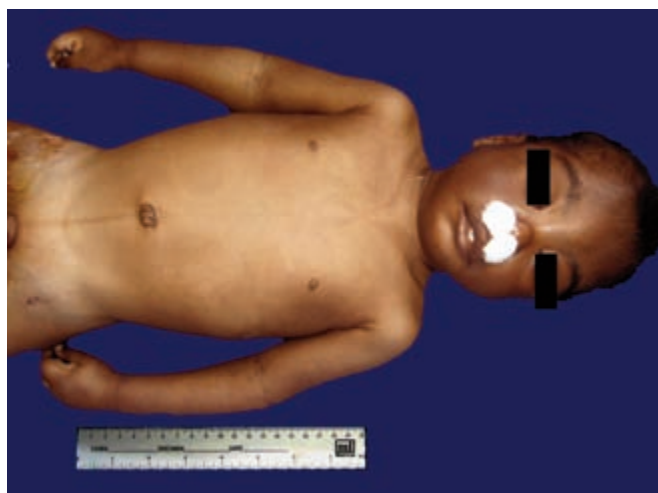


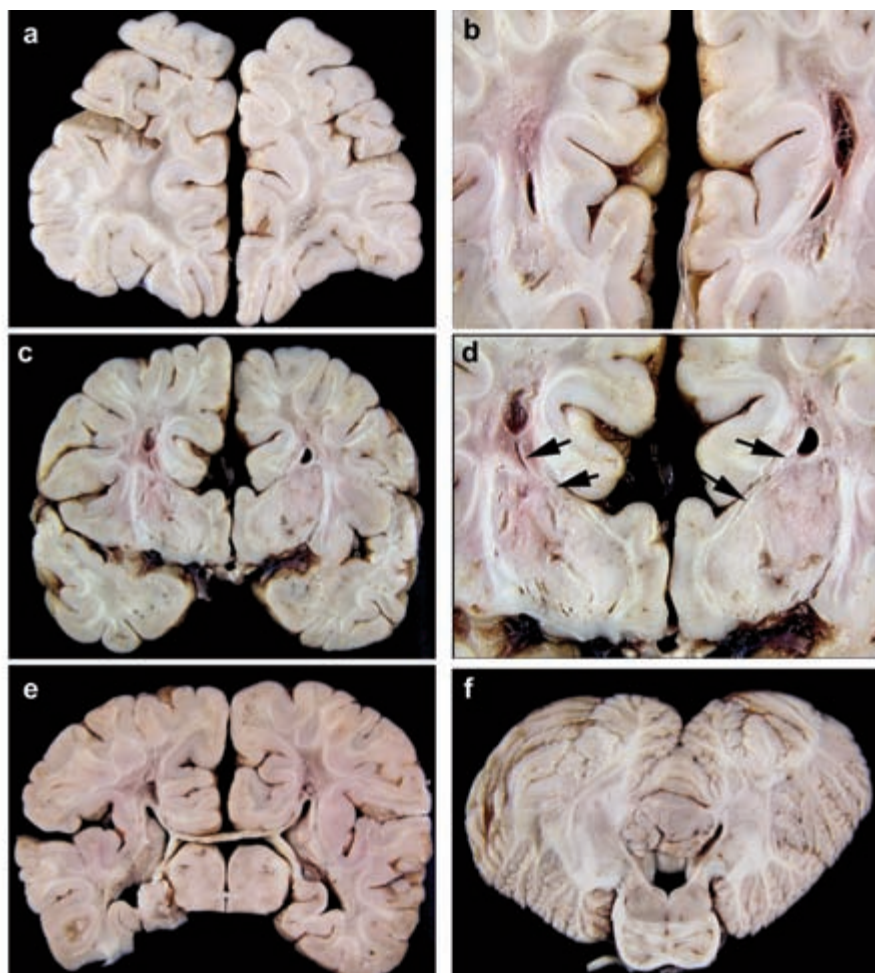
Figure 1: Facial features of the patient.

The brain was small, weighing 587 grams (expected weight for the age: 1191 grams), with no obvious atrophy or malformations externally. On cross sections, the brain revealed diffuse white matter abnormalities involving all lobes of the cerebrum, with varying degrees from discoloration to granular softening to focal cavitory changes (Figure 2A-F). Notably, U fibers and the subcortical white matter were spared. There was near total agenesis of corpus callosum (Figure 2C and D), with a thinned out portion at the level of the caudal thalamus (Figure 2E). Bilateral aberrant bands of cortex were present in the midline, compressing the lateral ventricles against the misshapen basal ganglia, where multiple cystic areas were present (Figure 2C and D). An area of discoloration in the cerebellar white matter adjacent to the dentate nucleus was also noted (Figure 2F).

Microscopically, the damage to deep white matter myelin was widespread, with preservation of U fibers and subcortical white

From the Department of Pathology, SUNY Downstate Medical Center, Brooklyn, New York, USA.

RECEIVED SEPTEMBER 11, 2008. FINAL REVISIONS SUBMITTED FEBRUARY 27, 2009.  
Correspondence to: Xianyuan Song, Department of Pathology, SUNY Downstate Medical Center, 450 Clarkson Ave, Box 25, Brooklyn, New York, 11203, USA



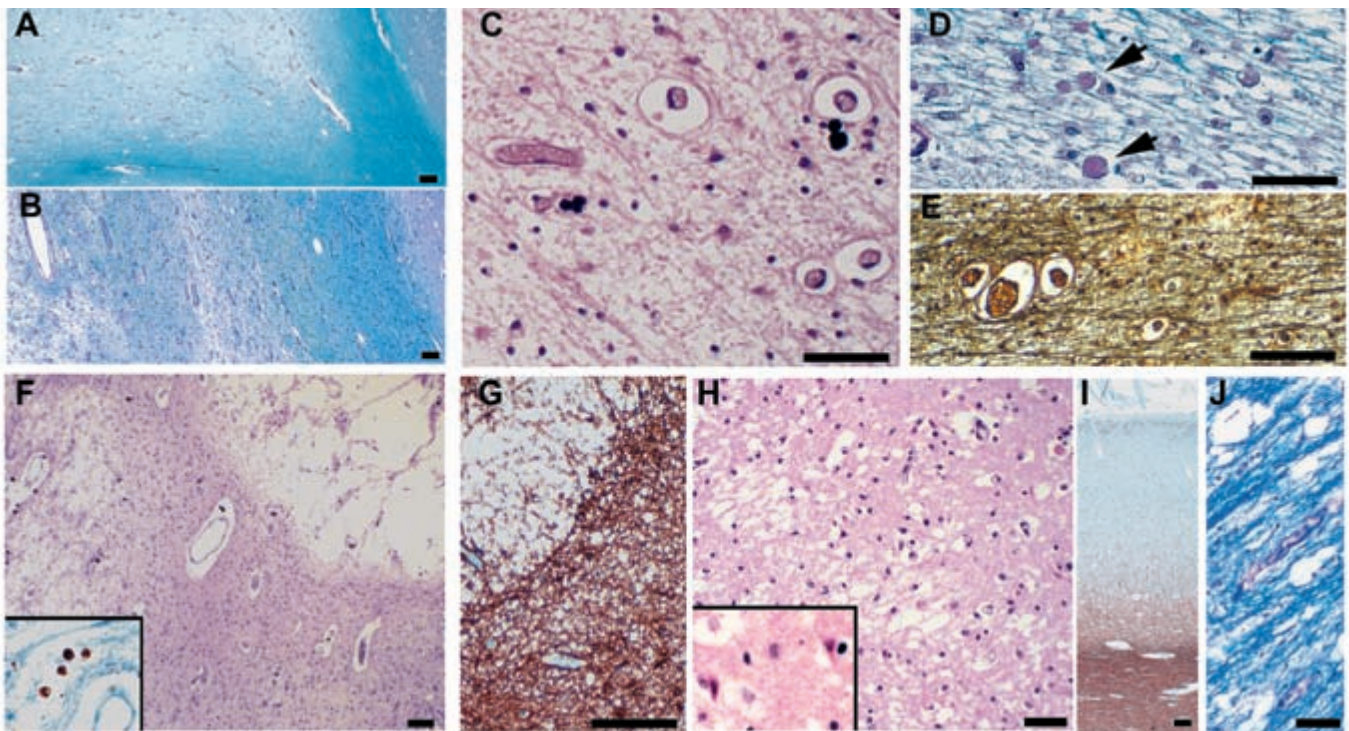
**Figure 2:** Gross appearance of the brain at the levels of frontal lobe (A, B), amygdala (C, D), caudal thalamus (E), pons and cerebellum (F). Note diffuse white matter damage sparing subcortical and U fibers; partial agenesis of corpus callosum (C, D) preserving the posterior aspect (E); and bilateral aberrant midline cortex, compressing the lateral ventricles against basal ganglia (arrows). The deep white matter of cerebellum showed discoloration (F).

matter (Figure 3A and B). The extent of the white matter changes varied. Some areas were close to normal except for pallor (Figure 3A). In other areas, myelinated fibers were sparse with gliosis, few PAS-positive macrophages, and relatively preserved axons (Figure 3B-E). Cystic areas containing gliovascular strands were also present in multiple areas including basal ganglia, with putamen more heavily involved than globus pallidus. Transitions from pallor, to sparse fibers to frank cystic lesions were noted in these areas (Figure 3F and G). A few small areas in putamen and globus pallidus showed different pattern of pathology with either acute (mostly in putamen) or subacute (in globus pallidus) neuronal damage (Figure 3H) or mummified neurons with mineralization. Myelin pallor was also seen in the cerebellar white matter next to dentate nucleus (figure not shown). Throughout these white matter changes, vascularity and perivascular mineralization was prominent (Figure 3C, E-F); however, macrophages were either absent or minimal (Figure 3D and F), except in the few lacunar infarcts in globus pallidus,

where moderate numbers were observed. Similarly, perivascular lymphocytic infiltrates, though seen, were minimal. The ependymal lining of the lateral ventricles between the midline cortex and basal ganglia showed multiple foci of denudation with granular ependymitis. Besides the few foci of neuronal damage in basal ganglia, no obvious neuronal loss was noted in the cortex or hippocampus. The cortex, including the one abnormally positioned in the midline, exhibited normal lamination, (Figure 3I). The optic nerves showed vacuolization within myelinated fibers (Figure 3J). Interestingly, no evidence of long tract degeneration was found in either brain stem or spinal cord (figure not shown). No evidence of neurodegenerative diseases, such as neurofibrillary tangles was present (Bielschowsky silver stain, figure not shown).

#### DISCUSSION

The signature pathology of disorders of aminoacidopathies is “spongy myelinopathy”,<sup>9</sup> the prototypes of which are phenylketonuria



**Figure 3:** Microphotographs of the brain. Representative sections from frontal lobe (A-E) showed deep white matter pallor (A) and sparse myelination (B) with preservation of subcortical fibers. Note the gliosis, prominent vascularity with perivascular mineralization (C), occasional macrophages (arrows in D), and relatively preserved axons (E). A section from putamen (F-G) showed white matter damage with transitions from pallor (lower right), to sparse fibers (left), to cystic cavitations containing gliovascular strands (upper right), and few macrophages (F inset). Gliosis was highlighted in (G) with GFAP stain. (H and inset): acute neuronal damage in putamen. (I): normal lamination of the cortex. (J): spongy myelinopathy of the optic nerves. (A, B, D, and J): LFB/PAS; C, F and H: H&E; E: Bielschowsky silver; F inset: CD68 [R&D Systems, 1:100]; G: GFAP [Dako, 1:1000]; I: Neurofilament protein [Sternberger Monoclonals, 1:1000]. Bar = 100 $\mu$ M).

and maple syrup urine disease. Several terms, which are often non-committal due to the difficulty in defining the entities, have been used to describe the myelin changes in these disorders, including myelin pallor, demyelination, dysmyelination, delayed myelination, defective myelination, myelinopathy, leukodystrophy, cystic demyelination, cavitation of white matter, and infarcts.<sup>9-12</sup> Products of myelin degradation have been infrequently described in the lesions.<sup>11</sup> As an inborn error of valine metabolism, 3-HiB-uria shares features with other aminoacidopathies. In the case described herein, “spongy myelinopathy” was seen, especially in the optic nerves; however, the majority of the case was different from this pattern. There was evidence of both damage to formed myelin and poor formation of myelin in this case. Areas displaying transitions from pallor to cystic formation might resemble a demyelinating process, while the lack of myelin degradation products and macrophages in most of the areas favored dysmyelination. Considering the diffuse and symmetric white matter changes with sparing of subcortical and U fibers, we believe this case qualified as dysmyelination/leukodystrophy.

Central nervous system malformations have been well documented in aminoacidopathies. In 3-HiB-uria, microcephaly, migrational disorders, lissencephaly, pachygyria, polymicrogyria, laminar heterotopia, agenesis of corpus callosum, hypoplasia of cerebellum, and congenital intracerebral

calcifications have been described. In this case, microencephaly, basal ganglia involvement, abnormal midline cortex, and perivascular mineralization were present. Interestingly, this case demonstrated partial agenesis of corpus callosum (ACC), with the posterior portion preserved, which was different from “classical” partial ACC where the posterior aspect is usually lost. The corpus callosum develops rostrocaudally between the 11th and 20th weeks of gestation; thus, the abnormality seen here may represent a destructive process after the corpus callosum was formed.

Besides 3-HiB-uria, basal ganglia involvement has been reported in several organic acidemias, including glutaric aciduria type I; mitochondrial enzyme deficiency diseases, such as Leigh’s disease; hypoxia-ischemic encephalopathy, and trauma. Basal ganglia are regions with a high metabolic demand, and are thus vulnerable to hypoxia and mitochondrial disorders. Recent *in vitro* studies on rat cerebral cortex showed evidence suggesting impairment of mitochondrial function in 3-HiB-uria.<sup>13</sup> This could potentially lead to selective regional vulnerability, in regions such as the basal ganglia. In addition, the acute neuronal damage in basal ganglia seen in this case is also frequently observed in glutaric aciduria type I, which resembles a “metabolic stroke”, i.e. acute neuronal damage

induced by toxic agents, and is believed to be the result of a rapid selective loss of vulnerable neurons rather than an infarct.<sup>14</sup> The mechanisms underlying this particular vulnerability have been well investigated in models for adult neurodegenerative disorders and for a few pediatric neurological disorders which may well share final overlapping pathways.<sup>14</sup>

The speculated mechanisms of brain dysfunction in Phenylketonuria and Maple syrup urine disease, are very likely operative in 3-HiB-uria, include impairment of amino acid transport across the blood-brain barrier, interference in normal protein synthesis, and consequent defective proteolipid protein synthesis which impairs myelination.

Definitive diagnosis of 3-HiB-uria is made by identification of high levels of 3-hydroxyisobutyrate on gas chromatography-mass spectrometry studies. However, due to its rarity, this entity is not easily recognized initially. Severe ketoacidotic attacks cause encephalopathy with grave impact on mental development, and patients are sometimes misdiagnosed as cerebral palsy as was in this case. Cornelia de Lange syndrome (CDLS) is a multiple congenital anomaly syndrome marked by a distinctive facial dysmorphism, variable degree of intellectual deficit, severe growth retardation beginning before birth, and various other malformations. ACC has also been reported in CDLS.<sup>15</sup> Most of the CDLS cases are sporadic, with occasional autosomal dominant pattern of familial transmission. To date, three gene mutations that cause CDLS have been identified, including NIPBL, SMC1A and SMC3 genes.<sup>16</sup> Our patient mimicked CDLS by exhibiting many features seen in that disorder, such as the dysmorphic features, developmental delay, and ACC. Thus, when considering the diagnosis of 3-HiB-uria, it is reasonable to include CDLS in the differential, and molecular studies may be necessary. The biochemical and molecular basis of 3-HiB-uria is poorly understood. A deficiency in 3-hydroxyisobutyrate dehydrogenase has been suggested as the most likely cause of the disorder; however, recent enzymatic and molecular studies did not support this.<sup>1</sup>

In summary, we report a rare case of 3-HiB-uria with post-mortem examinations. The neuropathology shared some features seen in other inborn errors of metabolism. Novel findings included diffuse symmetric deep white matter changes, most probably due to dysmyelination/leukodystrophy, selective neuronal damage in putamen and globus pallidus, and partial ACC of anterior, instead of classically posterior. The underlining mechanisms for these changes are under investigation.

#### ACKNOWLEDGEMENT

The authors thank Richard Taylor, CT, HT (ASCP) for technical support. We thank Lynette G. Sheffield, PhD and Jenny Libien, MD, PhD for reviewing the manuscript.

#### REFERENCES

- Loupatty FJ, van der Steen A, Ijlst L, Ruiten JP, Ofman R, Baumgartner MR, et al. Clinical, biochemical, and molecular findings in three patients with 3-hydroxyisobutyric aciduria. *Mol Genet Metab*. 2006;87(3):243-8.
- Sasaki M, Iwata H, Sugai K, Fukumizu M, Kimura M, Yamaguchi S. A severely brain-damaged case of 3-hydroxyisobutyric aciduria. *Brain Dev*. 2001;23(4):243-5.
- Shield JP, Gough R, Allen J, Newbury-Ecob R. 3-Hydroxyisobutyric aciduria: phenotypic heterogeneity within a single family. *Clin Dysmorphol*. 2001;10(3):189-91.
- Sasaki M, Kimura M, Sugai K, Hashimoto T, Yamaguchi S. 3-Hydroxyisobutyric aciduria in two brothers. *Pediatr Neurol*. 1998;18(3):253-5.
- Boulat O, Benador N, Girardin E, Bachmann C. 3-hydroxyisobutyric aciduria with a mild clinical course. *J Inher Metab Dis*. 1995;18(2):204-6.
- Chitayat D, Meagher-Villemure K, Mamer OA, O'Gorman A, Hoar DI, Silver K, et al. Brain dysgenesis and congenital intracerebral calcification associated with 3-hydroxyisobutyric aciduria. *J Pediatr*. 1992;121(1):86-9.
- Ko FJ, Nyhan WL, Wolff J, Barshop B, Sweetman L. 3-Hydroxyisobutyric aciduria: an inborn error of valine metabolism. *Pediatr Res*. 1991;30(4):322-6.
- Sasaki M, Yamada N, Fukumizu M, Sugai K. Basal ganglia lesions in a patient with 3-hydroxyisobutyric aciduria. *Brain Dev*. 2006;28(9):600-3.
- Agamanolis DP. Disorders of amino acid metabolism. In: Golden JA, Harding BN. *Pathology and genetics: developmental neuropathology*. Basel: ISN Neuropath Press; 2004. p. 303-10.
- Schönberger S, Schweiger B, Schwahn B, Schwarz M, Wendel U. Dysmyelination in the brain of adolescents and young adults with maple syrup urine disease. *Mol Genet Metab*. 2004;82(1):69-75.
- Swaiman KF. Aminoacidopathies and organic acidemias resulting from deficiency of enzyme activity and transport abnormalities. In: Swaiman KF, Ashwal, S, editors. *Pediatric neurology, principles and practice*. 3rd ed. St. Louis: Mosby; 1999. p. 377-410.
- Menkes JH. Metabolic diseases of the nervous system. In: Menkes JH, Harvey BS, editors. *Child neurology*. 6th ed. Philadelphia: Lippincott Williams & Wilkins; 2000. p. 33-56.
- Viegas CM, da Costa Ferreira G, Schuck PF, Tonin AM, Zanatta A, de Souza Wyse AT, et al. Evidence that 3-hydroxyisobutyric acid inhibits key enzymes of energy metabolism in cerebral cortex of young rats. *Int J Dev Neurosci*. 2008;26(3-4):293-9.
- Funk CBR, Prasad AN, Frosk P, Sauer S, Kolker S, Greenberg CR, et al. Neuropathological, biochemical and molecular findings in a glutaric acidemia type 1 cohort. *Brain*. 2005;128(4):711-22.
- Hayashi M, Sakamoto K, Kurata K, Nagata J, Satoh J, Morimatsu Y. Septo-optic dysplasia with cerebellar hypoplasia in Cornelia de Lange syndrome. *Acta Neuropathol*. 1996;92(6):625-30.
- Deardorff MA, Kaur M, Yaeger D, Rampuria A, Korolev S, Pie J, et al. Mutations in cohesin complex members SMC3 and SMC1A cause a mild variant of cornelia de Lange syndrome with predominant mental retardation. *Am J Hum Genet*. 2007;80(3):485-94.